

# Implant Planning in a Case With Sotos Syndrome

Laura Lago, DDS, PhD\*

Luis Da Silva, MD, PhD

Noelia Fernández-Formoso, DDS, PhD

Benito Rilo, MD, PhD

## INTRODUCTION

Sotos syndrome, also called cerebral gigantism due to cranial overgrowth, is characterized by fast growth in the first stage of life. It is usually transmitted by autosomal dominant inheritance; nevertheless, recessive forms have been reported in the literature. Cole and Hughes<sup>1</sup> established 4 principal criteria: overgrowth with advanced bone age, macrocephaly, characteristic facial appearance, and learning difficulties. Recently, mutations and deletions in the gene NSD1 have been identified as the main cause of the syndrome. The prevalence has been estimated to be 1 per 10–50 000.<sup>2</sup> The oral findings are varied: high-arched palate, premature eruption of teeth, mandibular prognathism, agenesia, supernumerary teeth, and limited mouth opening.<sup>3</sup>

This report describes the planning of oral rehabilitation of a patient with Sotos syndrome presenting with multiple dental agenesia. To our knowledge, there have been few cases of Sotos syndrome with agenesia described in the literature.<sup>2,4</sup> Replacement of the missing teeth by implants depends both on the patient's clinical condition due to the underlying disorder and on the cooperation of the patient since this syndrome is sometimes accompanied by mental retardation.

## DESCRIPTION OF THE CASE

A 28-years-old man was referred to the Prosthodontic Department, Faculty of Medicine and Odontology, Santiago de Compostela University, Spain, for oral rehabilitation. A detailed medical report stated that the patient had Sotos syndrome. The patient exhibited characteristic facial features, with a prominent forehead, receding hairline, hypertelorism, tapered mandible, and facial flushing. Although the patient was very tall, his mental development was delayed with respect to his chronological age.

Since the patient had reached adulthood and the growth phase had ended, it was possible to plan the most important aspect of the rehabilitation: the replacement of missing components. In this regard, study of the morphology and bone availability seemed to be the first factor to consider, for which bimaxillary cone-beam computerized tomography was performed. This showed the absence of the following teeth: Nos. 4, 5, 14, 20, 21, 24, 25, 28, and 29 (Figure 1). Measurements of bone height and width in areas with agenesia were also taken; the results (in millimeters) are presented in the Table.

In all edentulous areas, there was adequate bone availability in both height and width for the placement of implants of standard dimensions (4.1-mm Ø and 10-mm length). Another noteworthy aspect of the case was the presence in the mandible of a marked concavity in the molar zone corresponding to the submandibular fossa, as well as the position of the inferior alveolar nerve very close to the inferior border of the mandible (Figure 1).

Although there are no references in the literature regarding the use of implants in patients with Sotos syndrome, the cooperation of the patient is valued despite the mental retardation, as is the passage of adequate time since bone growth ended. An implant was placed in the area of the mandibular symphysis to replace the 2 missing central mandibular incisors, because of the mesiodistal dimensions of the edentulous area. The postoperative period was uneventful (without complications), and at 2 months after surgery, prosthetic rehabilitation began (Figure 2). After 1-year follow-up, in later phases, treatment of the remaining agenesia will continue.

## DISCUSSION

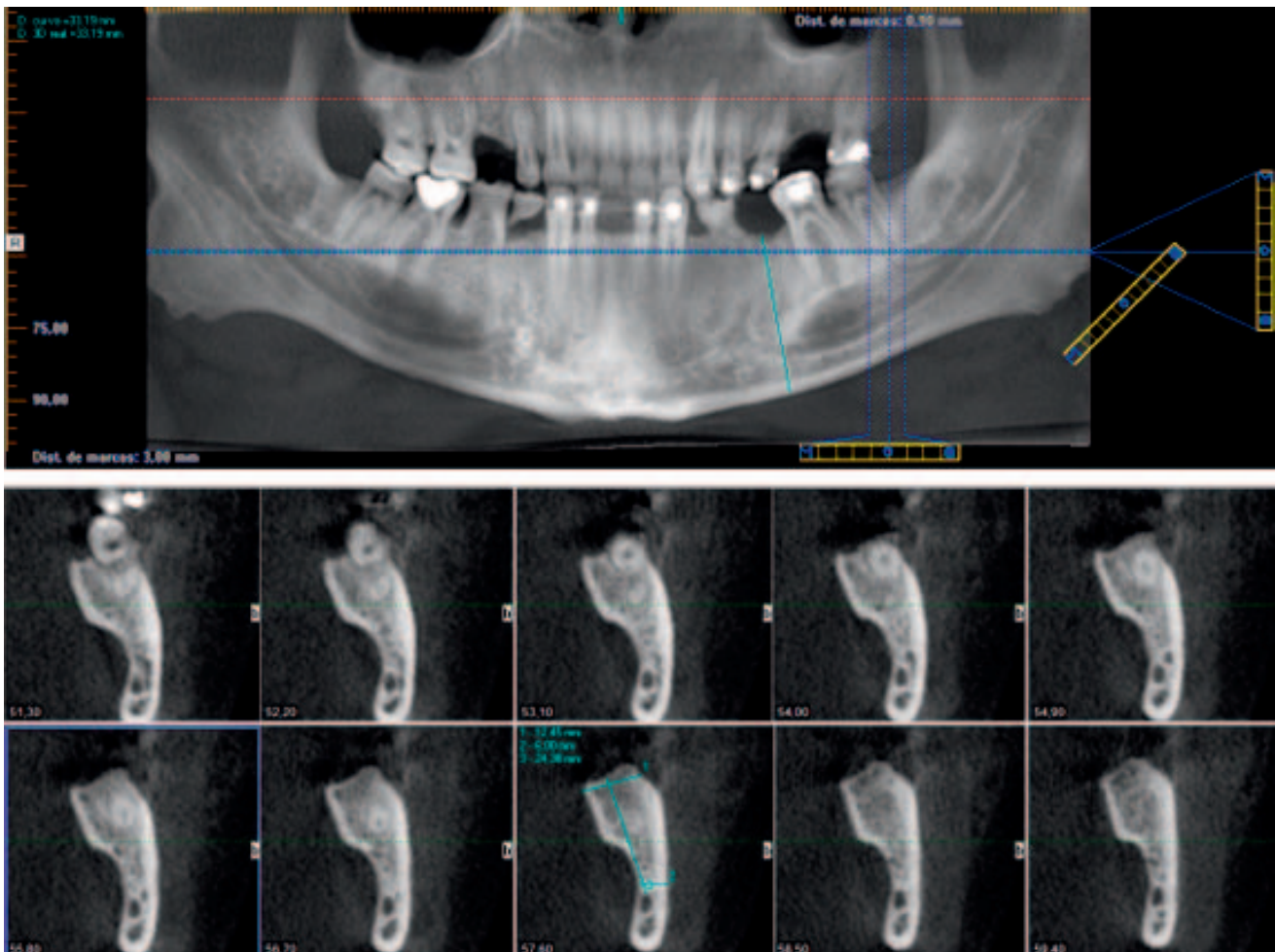
It is important to consider that the need for restoration in patients with agenesia occurs at an early age, which implies that the adjacent teeth remain intact, making an implant the treatment of choice. To our knowledge, there are no reports in the literature concerning implant rehabilitation in this type of patient. Treatment with implants requires, among other factors, sufficient bone volume, and we know that after the extraction of a permanent tooth, the bone crest undergoes a reduction of 35% in the buccolingual width within the first 3 months postextraction.<sup>5</sup> However, there are few data on changes after the loss or extraction of primary teeth. Studies on healthy edentulous subjects have reported bony dimensions in the posterior mandibular sector of 12.09 to 11.71 mm in height (from the crest to the cortex of the mandibular canal) and a bone width in the same area of 7.08 to 9.8 mm.<sup>6</sup>

Approximately 3% of the population presents with agenesia of the second lower premolar (P2). With regard to bone availability in these patients, a study by Bertl et al<sup>7</sup> reported dimensions of a mandibular height of  $29 \pm 2.5$  mm in control subjects and 27.8 mm for subjects with agenesia of the second lower premolar, regardless of whether the second deciduous molar is present or not. Nickenig et al<sup>8</sup> reported a height of 25.7 mm in the case of edentulous subjects. Regarding the buccolingual width, the same authors<sup>8</sup> reported a width in the coronal zone of 7.6 mm for edentulous subjects. Meanwhile, Bertl et al<sup>7</sup> reported a width of 10 mm in the

Department of Prosthodontics, Faculty of Medicine and Dentistry, Santiago de Compostela University, Santiago de Compostela, Spain.

\* Corresponding author, e-mail: lagogonzalezlaura@gmail.com

<https://doi.org/10.1563/aaaid-joi-D-18-00181>



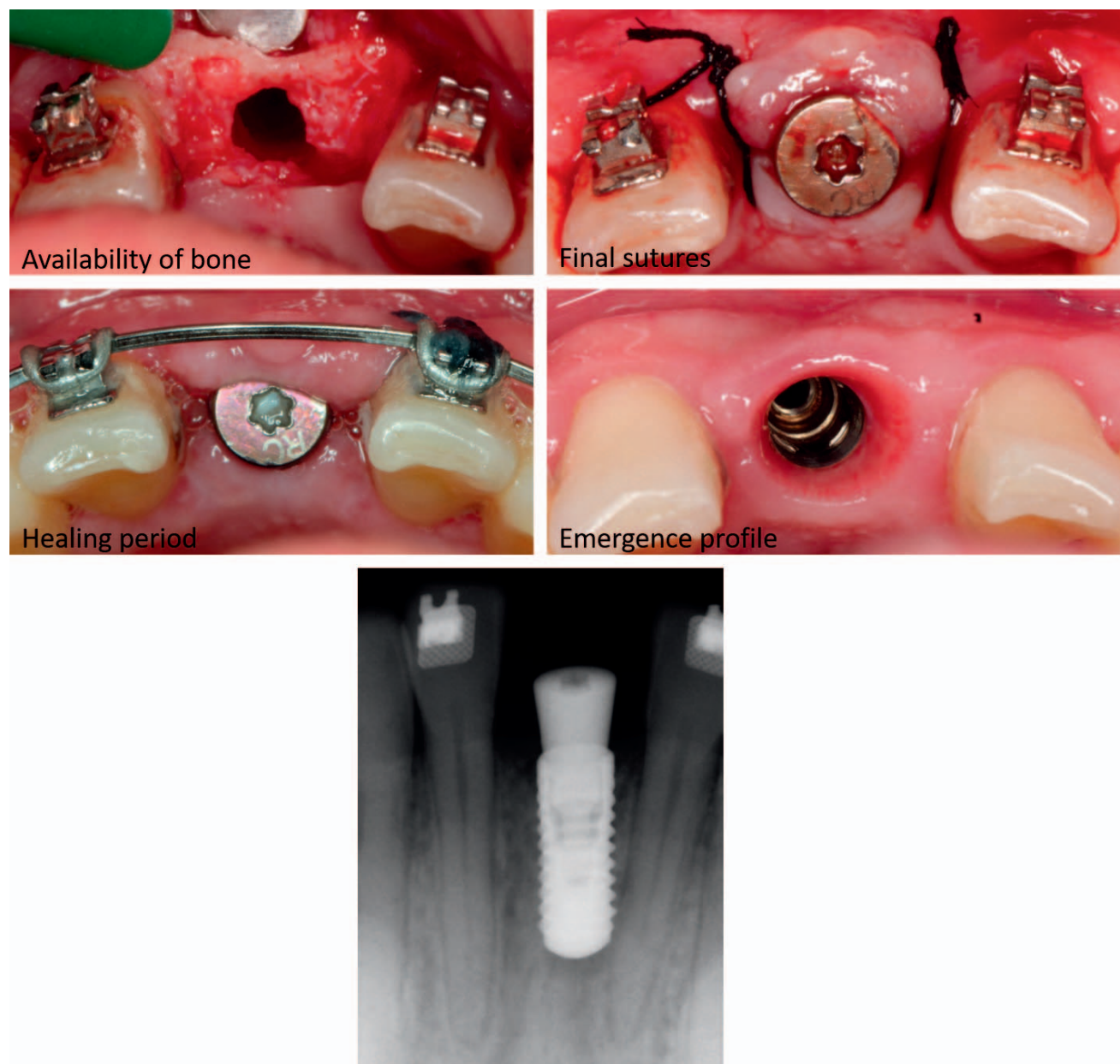
**FIGURE 1.** Cone-beam computerized tomography for dental implant planning. Concavity in the molar zone and inferior alveolar nerve very close to the inferior cortical mandibular.

coronal zone of the crest in the control group, 9.5 mm in subjects with agenesis but the presence of the second deciduous molar, and 8.5 mm in subjects with nonmolar agenesis. Thus, the authors stated that the placement of an implant ( $\varnothing$  3.5 mm) without any added regenerative technique

is possible in 84% of subjects with agenesis who retain the deciduous molar but only in 56% of cases with agenesis and absence of the deciduous molar. In our patient, the figures, both in height and width, were higher than the averages presented in the literature, both in dentate and edentulous subjects. This is probably due to the pathological process itself with bone overgrowth, which in these locations favors the placement of implants.

Another point of interest is to establish the presence of the submandibular fossa, a concavity in the lingual aspect of the mandible in the molar region where part of the submandibular gland is located. When the pit is very pronounced, it can impede the placement of implants in that area because of the possibility of perforating the cortex.<sup>9</sup> Although its presence and depth are very variable, it has been quantified from 0 mm (no concavity) to dimensions between 1.28–1.44 mm at a distance of 10 mm from the foramen according to the measurement of de Souza et al.<sup>6</sup> In our case, using the same measurement system, the values were 6.71–7.06 mm. In contrast, Nickenig et al.,<sup>8</sup> using a different measurement system, offered depth values of the concavity in the molar region of 3.7 mm and applying their parameters recorded figures of 12.61 mm on the right side and 9.60 mm on the left side. It is interesting to note the

TABLE Measurements of bone height and width in areas with agenesis (mm)			
	Bone Crest Width, mm	Bone Crest Height, mm	Distance to Alveolar Nerve, mm
Maxilla			
No. 4	10.24	20.62	
No. 5	8.59	26.81	
No. 14	8.42	18.5	
Jawbone			
No. 20	10.82	37.37	23.52
No. 21	12	37.05	22.44
No. 24			
No. 25			
No. 28	10.27	35.11	21.91
No. 29	13.31	37.82	20.42



**FIGURE 2.** Emergence profile after osseointegration period.

possible association between the depth of the concavity and a deeper position of the inferior alveolar nerve, which we also observed in our study.

In complex cases such as the one described in the present report, with agenesis and both presence and absence, at the same time, of the primary teeth, it is difficult to clearly define when a deciduous tooth should be extracted and replaced by an implant.<sup>10</sup> Logically, given that it is not advisable to place an implant until facial growth is complete, in most cases treatment should not proceed to rehabilitation until the age of 20 years, and instead, the aim of treatment should be to retain the primary tooth until then. It should be noted that in these patients, growth in height and weight tends to normalize upon reaching puberty, probably because of the fusion of the

epiphyses,<sup>1</sup> so the disorder should not prevent patient rehabilitation using implants. The main limitation of the described study is the single case; therefore, the findings are not supported by enough strong evidence. More studies with a major follow-up period and more cases are necessary.

#### NOTE

The authors have no conflicts of interest to declare.

#### REFERENCES

1. Cole TR, Hughes HE. Sotos syndrome: a study of the diagnostic criteria and natural history. *J Med Genet.* 1994;31:20–32.

2. Callanan AP, Anand P, Sheehy EC. Sotos syndrome with hypodontia. *Int J Pediatr Dent.* 2016;16:143–146.
3. Raitz R, Laragnoit A. Supernumerary teeth and dental management in Sotos syndrome. *J Dent Child.* 2009;76:246–250.
4. Takei K, Sueishi K, Yamaguchi H, Ohtawa Y. Dentofacial growth in patients with Sotos syndrome. *Bull Tokyo Dent Coll.* 2007;48:73–85.
5. Schropp L, Wenzel A, Kostopoulos L, Karring T. Bone healing and soft tissue contour changes following single-tooth extraction: a clinical and radiographic 12-month prospective study. *Int J Periodontics Restorative Dent.* 2003;23:313–323.
6. de Souza LA, Souza Picorelli Assis NM, Ribeiro RA, Pires Carvalho AC, Devito KL. Assessment of mandibular posterior regional landmarks using cone-beam computed tomography in dental implant surgery. *Ann Anat.* 2016;205:53–59.
7. Bertl K, Bertl MH, Heimel P, et al. Alveolar bone resorption after primary tooth loss has a negative impact on straightforward implant installation in patients with agenesis of the lower second premolar. *Clin Oral Implants Res.* 2018;29:155–163.
8. Nickenig HJ, Wichmann M, Eitner S, Zoller JE, Krepel M. Lingual concavities in the mandible: a morphological study using cross-sectional analysis determined by CBCT. *J Craniomaxillofac Surg.* 2015;43:254–259.
9. Braut V, Bornstein MM, Kuchler U, Buser D. Bone dimensions in the posterior mandible: a retrospective radiographic study using cone beam computed tomography. Part 2—analysis of edentulous sites. *Int J Periodontics Restorative Dent.* 2014;34:639–647.
10. Bergendal B. When should we extract deciduous teeth and place implants in young individuals with tooth agenesis. *J Oral Rehabil.* 2008;35:55–63.