

# A Sinus Floor Reaugmentation Technique Around an Apically Exposed Implant Into the Maxillary Sinus

Daisuke Ueno, DDS, PhD<sup>1,2\*</sup>  
 Noriko Banba, DDS<sup>2</sup>  
 Akira Hasuike, DDS, PhD<sup>3</sup>  
 Kazuhiko Ueda, DDS, PhD<sup>4</sup>  
 Toshiro Kodama, DDS PhD<sup>2</sup>

Sinus floor augmentation (SFA) is the most predictable treatment option in the atrophic posterior maxilla. However, exposure of the apical implant body into the maxillary sinus cavity is an occasionally observed phenomenon after SFA. Although most penetrating dental implants remain completely asymptomatic, they may induce recurrent rhinosinusitis or implant loss. Removal of the implant should be considered if there is significant implant exposure that results in prolonged treatment and increased costs. This case report demonstrates a recovery approach using sinus floor reaugmentation without implant removal in a patient with an apically exposed implant into the maxillary sinus cavity.

**Key Words:** sinus floor augmentation, dental implants, complication, apically exposed implant

## INTRODUCTION

Exposure of an apical implant body into the maxillary sinus cavity is an occasional phenomenon in implant treatment with sinus floor augmentation (SFA). Insufficient elevation of the Schneiderian membrane and insufficient bone graft volume can result in this scenario. Perforation of the Schneiderian membrane is the most common intraoperative complication in maxillary SFA, and this may bring about leakage of graft materials into the sinus cavity. According to a systematic review, mean prevalence of membrane perforation is 19.5% in lateral SFA.<sup>1</sup> Since a transcresal approach with a socket-lifting technique is a blind and technique-sensitive approach, it has a higher risk of iatrogenic membrane perforation due to the elevation height.<sup>2</sup> Furthermore, insufficient bone filling or the use of faster bioresorbable bone substitute materials may lead to significant and unpredictable bone resorption as well as implant penetration into the sinus cavity.

Several case reports have documented migrated dental implants with the sinus remaining completely asymptomatic.<sup>3,4</sup> However, it has been reported that exposure of the apical implant body into the sinus may result in recurrent rhinosinusitis.<sup>5</sup> In addition, a confined implant/bone osseointegrated area can potentially cause implant loss. Therefore, removal of

the implant should be considered if there is significant implant penetration. However, increased surgical time, treatment duration, and costs are required. In addition, bone fracture or destruction of the surrounding bone may occur. As a way to overcome these problems, this case report demonstrates proper sinus floor reaugmentation around an apically exposed implant into the maxillary sinus cavity.

## CLINICAL CASE REPORT

A 63-year-old male patient was introduced to our clinic for occlusal rehabilitation of the maxillary right molar region in December 2016. One implant had been placed with a transcresal sinus lift in the #UNS2 (#2) region in a private practice about 10 years prior to his visit; however, the implant was not functional by the superstructure due to abutment mobility issues beginning approximately 4 years earlier.

The patient was introduced to our clinic from his former private practice because of the inconvenience this condition caused him. The implant abutment had already been removed at the first visit to our clinic. The #UNS3 (#3) was extracted for severe localized periodontal lesions and tooth fracture, and healing was proceeding well 2 months after the extraction (Figure 1). However, cone beam computerized tomography (CBCT) images confirmed inadequate bone volume for implant placement in #3 (Figure 2). In addition, only 4–5 mm of attachment was observed between the #2 implant and the surrounding bone. The implant body was apically exposed into the maxillary sinus. Since the vertical bone height (2 mm) at site #3 was not enough for implant placement, SFA was planned prior to the implant placement. Vertical bone gain of more than 10 mm was required; therefore, the Schneiderian membrane had to be elevated extensively. Consequently, elevation of the

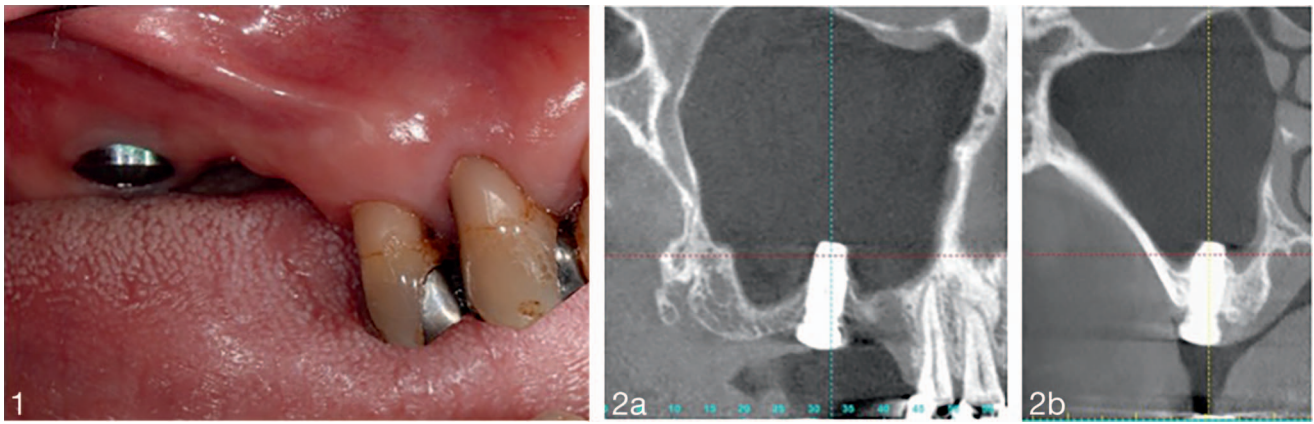
<sup>1</sup> Ueno Dental Clinic, Akitakata, Hiroshima, Japan.

<sup>2</sup> Department of Implantology and Periodontology, Kanagawa Dental University, School of Dentistry, Yokohama, Japan.

<sup>3</sup> Department of Periodontology, Nihon University School of Dentistry, Tokyo, Japan.

<sup>4</sup> Department of Crown and Bridge Prosthodontics, School of Life Dentistry at Niigata, The Nippon Dental University, Niigata, Japan.

\* Corresponding author, e-mail: ueno\_dent@yahoo.co.jp  
<https://doi.org/10.1563/aaaid-joi-D-18-00271>

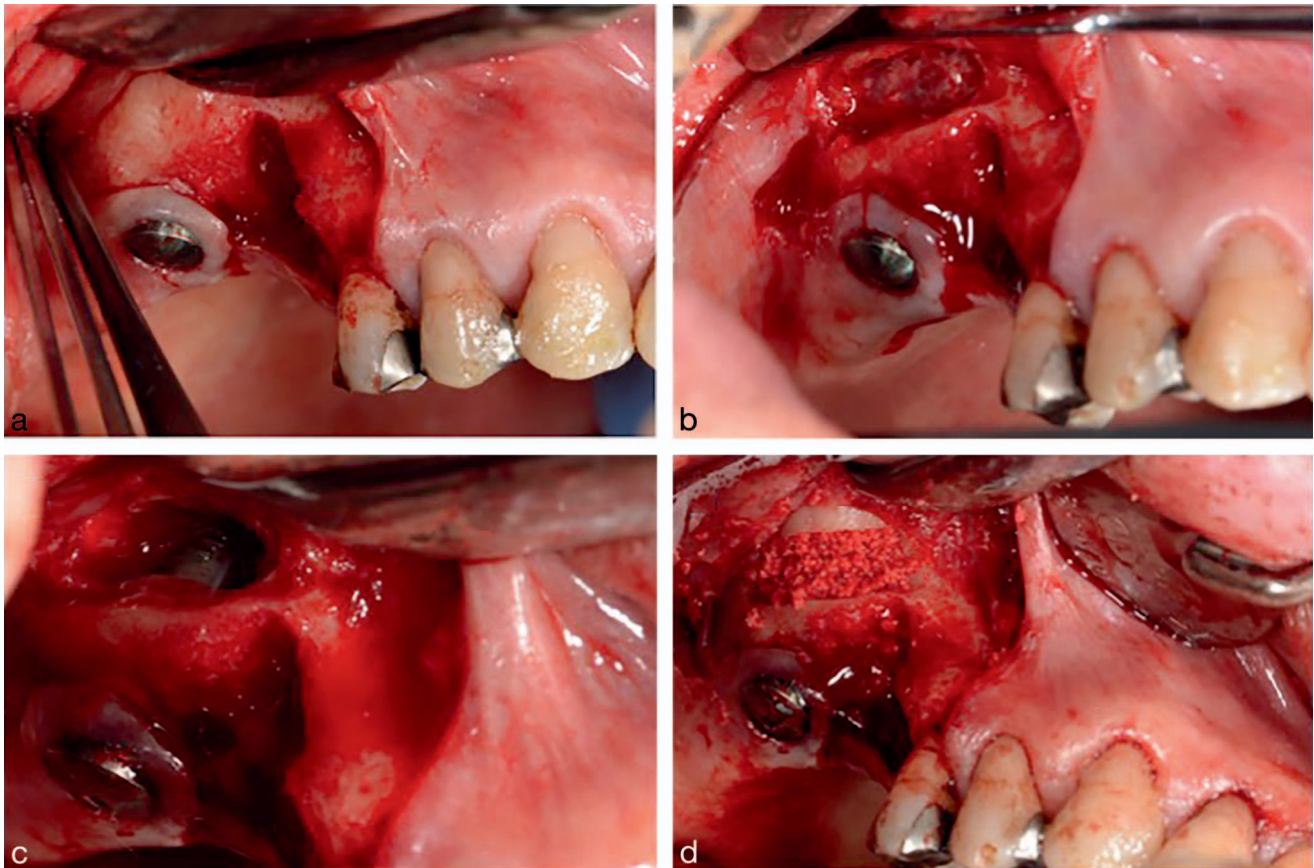


**FIGURES 1 AND 2. FIGURE 1.** Preoperative intraoral image. **FIGURE 2.** Preoperative panoramic (a) and coronal (b) cone beam computed tomography images.

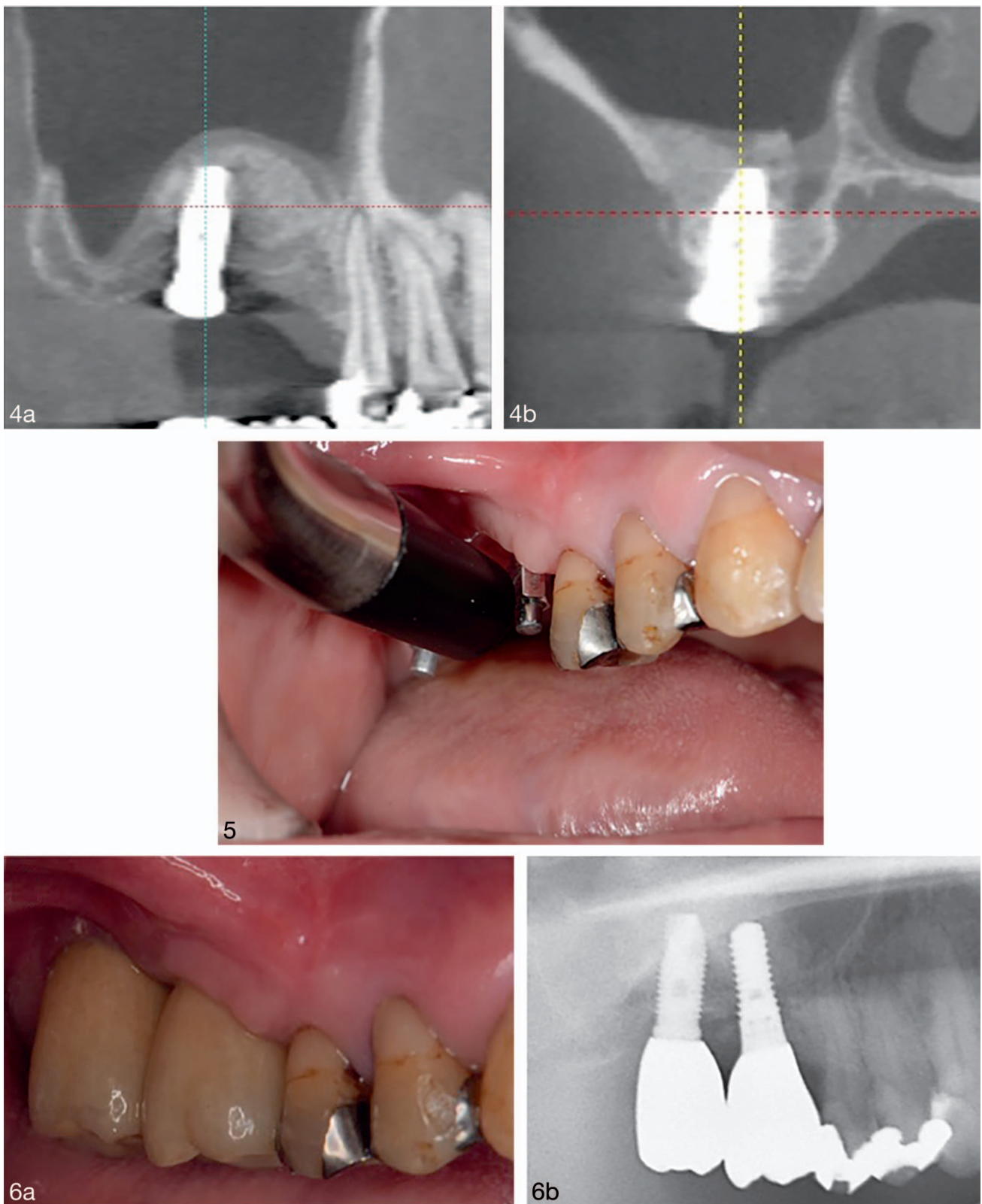
Schneiderian membrane was planned at site #3 and at the site #2 implant.

After administration of intravenous sedation and local anesthesia, a midcrestal incision was made from site #3 to the interproximal aspects of #2. The incision was extended to #4 intrasulcally and the distal side extrasulcally to the maxillary pad. Vertical release incisions were made at the mesiobuccal

angle of #4 and the distobuccal angle to the maxillary pad (Figure 3a). The buccal wall of the maxillary sinus was exposed after the elevation of a mucoperiosteal flap. Lateral bone resorption was observed at site #3. A piezoelectric device (VarioSurg, Nakanishi, Tochigi, Japan) with a diamond-coated round bur was used with copious saline irrigation to create the window of the maxillary sinus. Then, the Schneiderian



**FIGURE 3.** Sinus floor augmentation in an apically exposed implant in the right maxillary sinus: (a) After elevation of flaps, a residual extraction socket was observed at site #3. (b) The lateral window was made with piezoelectric surgery. (c) The Schneiderian membrane was elevated from the bone and exposed implant. (d) Bone augmentation was performed with synthetic hydroxyapatite.



**FIGURES 4–6.** **FIGURE 4.** Panoramic (a) and coronal (b) cone beam computed tomography images 5 months after sinus floor augmentation. **FIGURE 5.** Measurement of implant stability quotient 4 months after implant placement. **FIGURE 6.** Intraoral (a) and radiographic (b) images 6 months after occlusal loading.

membrane was gently elevated from the residual bone and apically exposed implant using a sinus lift elevator (Figure 3b). Since the angle between the maxillary sinus floor and the axis of the implant body was steep (about 90° arc), and the projection was narrow (implant diameter of 5.0 mm), a sinus lift elevator (Stoma Tinti Sinus Lift Elevator, Stoma, Emmingen-Liptingen, Germany) with a small spoon and severe bend was used to separate the palatal Schneiderian membrane. The exposed implant body was wiped with saline-soaked gauze (Figure 3c).

A 3-mm perforation of the Schneiderian membrane occurred, and the perforation was covered with a sheet-like collagen sponge (TERUDERMIS, Olympus Terumo Biomaterials, Tokyo, Japan). Then, the sinus cavity was grafted with synthetic hydroxyapatite (Neo Bone, MMT Co, Ltd, Osaka, Japan) mixed with venous blood (Figure 3d).

The residual extraction socket at #3 was also filled with hydroxyapatite, and the graft sites were covered with resorbable collagen membrane (Bio-Guide, Geistlich Biomaterials, Wolhusen, Switzerland). The mucoperiosteal flaps were sutured without tension. No complications—such as postoperative epistaxis—occurred during the healing period.

Five months after SFA, CBCT showed that more than 10 mm radiographic bone gain was observed vertically in #2 and #3, respectively (Figure 4). The apically exposed implant body of #2 seemed to be completely covered by bone substitute material. A 10-mm long, 4.1-mm diameter implant (Straumann Tapered Effect Implant, Straumann, Basel, Switzerland) was placed with transcresal sinus lift at site #3, and the insertion torque was 35 Ncm. The postsurgical course was uneventful. Four months after implant placement, abutment-connection surgery was performed. The values of the implant stability quotient of the implants in #3 and #2 were 75 and 70, respectively (Figure 5). After loading by provisional crown, full-contour zirconia crowns were fixed to each implant as the screw-retained superstructure. All implants were functioning well 6 months after occlusal loading without obvious radiographic bone loss (Figure 6).

## DISCUSSION

To the best of our knowledge, this case report is the first to describe a sinus floor reaugmentation technique in a patient with an apically exposed implant body into the sinus cavity. The insufficient bone volume area around the apically exposed implant was radiographically filled by bone graft material and is functioning well after occlusal loading.

Several case reports have documented migrated dental implants while the sinus remains completely asymptomatic.<sup>3,4</sup> However, implant penetration into the sinus cavity may alter nasal airflow and can irritate the nasal mucosa.<sup>5</sup> In addition, nasal clearance can be disturbed by implant blockage of the mucociliary pathway, giving rise to inflammation,<sup>6</sup> and may cause recurrent rhinosinusitis.<sup>7</sup> Zhong et al<sup>8</sup> evaluated the effects of implant exposure into the sinus cavity with a penetrating depth of 1–3 mm on osseointegration and sinus health in a dog model. After a 5-month healing period, penetrating depths of 1 and 2 mm were fully covered with newly formed membrane and partially covered with new bone growth. In contrast, if a penetrating depth of over 3 mm is

exposed in the sinus cavity and shows no membrane and bone coverage, expression of recurrent sinusitis should be considered.

A confined implant/bone osseointegrated area caused by exposure of an implant is a risk factor for implant loss. Recently, several multicenter, randomized, controlled clinical trials have been compared marginal bone-level changes and the survival of short and standard-length implants.<sup>9,10</sup> Both short and standard-length implants lead to a stable marginal bone level and high implant survival rate. However, no evidence was observed for cases of short implants of less than 6 mm.

Thus, sinus floor reaugmentation is considered in patients with a very short contact height between the bone and osseointegrated implant. In addition, removal of the implant should be considered in patients with implant mobility or rhinosinusitis.

The key to the success of sinus floor reaugmentation technique in a patient with an apically exposed implant body is prevention of a larger perforation during elevation of the Schneiderian membrane. The angle between the axis of the implant body and the sinus floor is almost 90° arc. Since attachment to the Schneiderian membrane and implant body is generally not firm, the membrane should be gently elevated using a small-spoon sinus lift elevator with a severe bend. Conversely, attachment between residual bone and the Schneiderian membrane is often firm in re-elevation cases because of scar formation. Thus, caution should be taken to avoid a large membrane perforation.

Surface decontamination is indispensable for bone regeneration and reosseointegration. Previously, several decontamination systems—such as chemical, mechanical, laser, and photodynamic therapies—have been reported in peri-implantitis.<sup>11</sup> However, the evidence for reosseointegration onto a previously exposed implant surface is still nonexistent. Because apically exposed implants in the maxillary sinus do not contain accumulations of dental plaque and calculus, the situation is different from that of peri-implantitis-contaminated implants. Cleaning accessibility is difficult on the palatal side of the implant. Regarding the surgical accessibility and the possibility of residual chemical agents in the maxillary sinus, chemical and laser therapies are not considered to be effective in this instance.

## ABBREVIATIONS

CBCT: cone beam computerized tomography  
SFA: sinus floor augmentation

## NOTE

The authors report no conflicts of interest related to this report.

## REFERENCES

1. Pjetursson BE, Tan WC, Zwahlen M, Lang NP. A systematic review of the success of sinus floor elevation and survival of implants inserted in combination with sinus floor elevation. *J Clin Periodontol*. 2008;35:216–240.
2. Chan HL, Oh TJ, Fu JH, Benavides E, Avila-Ortiz G, Wang HL. Sinus

augmentation via transcrestal approach: a comparison between the balloon and osteotome technique in a cadaver study. *Clin Oral Implants Res.* 2013;24:985–990.

3. Galindo P, Sanchez-Fernandez E, Avila G, Cutando A, Fernandez JE. Migration of implants into the maxillary sinus: two clinical cases. *Int J Oral Maxillofac Implants.* 2005;20:291–295.

4. Kluppel LE, Santos SE, Olate S, Freire Filho FW, Moreira RW, de Moraes M. Implant migration into maxillary sinus: description of two asymptomatic cases. *Oral Maxillofac Surg.* 2010;14:63–66.

5. Levin L, Herzberg R, Dolev E, Schwartz-Arad D. Smoking and complications of onlay bone grafts and sinus lift operations. *Int J Oral Maxillofac Implants.* 2004;19:369–373.

6. Watelet JB, Bachert C, Gevaert P, Van Cauwenberge P. Wound healing of the nasal and paranasal mucosa: a review. *Am J Rhinol.* 2002;16:77–84.

7. Raghoobar GM, Weissenbruch R, Vissink A. Rhino-sinusitis related to

endosseous implants extending into the nasal cavity. A case report. *Int J Oral Maxillofac Surg.* 2004;33:312–314.

8. Zhong W, Chen B, Liang X, Ma G. Experimental study on penetration of dental implants into the maxillary sinus in different depths. *J Appl Oral Sci.* 2013;21:560–566.

9. Zadeh HH, Guljé F, Palmer PJ, et al. Marginal bone level and survival of short and standard-length implants after 3 years: an open multi-center randomized controlled clinical trial. *Clin Oral Implants Res.* 2018;29:894–906.

10. Felice P, Barausse C, Pistilli V, Piattelli M, Ippolito DR, Esposito M. Posterior atrophic jaws rehabilitated with prostheses supported by 6 mm long × 4 mm wide implants or by longer implants in augmented bone. 3-year post-loading results from a randomised controlled trial. *Eur J Oral Implantol.* 2018;1:175–187.

11. Mellado-Valero A, Buitrago-Vera P, Solá-Ruiz MF, Ferrer-García JC. Decontamination of dental implant surface in peri-implantitis treatment: a literature review. *Med Oral Patol Oral Cir Bucal.* 2013;18:e869–e876.