

Surgical Restorative Decision Algorithm for Edentulous Condition in Implant Dentistry With Emphasis on Bone Augmentation

Len Tolstunov, DDS, DMD¹⁻³

Ridge preservation and bone augmentation techniques in implant dentistry are designed to preserve and augment existing alveolar ridge to prepare it for implant treatment. Bone stock is an essential component for a long-term success of dental implants. This article provides a prosthetically driven step-by-step surgical restorative decision tree algorithm to diagnose and treat an edentulous condition in implant dentistry.

Key Words: ridge augmentation, bone grafting, ridge preservation, bone loss, distraction osteogenesis, block graft, guided bone regeneration, ridge split expansion, horizontal and vertical bone deficiency

INTRODUCTION

Alveolar bone grafting can be divided into ridge preservation (RP) and ridge augmentation (RA). Ridge preservation (prophylactic treatment) is comprised of hard and soft tissue grafting procedures that intend to preserve the existing ridge volume *within* its bony envelope. These surgical procedures are usually performed at the time of tooth extraction with the goal to minimize surrounding tissue loss after the tooth loss. Most of the time, this surgical approach tends to involve a particulate bone grafting material placed in internal or inlay fashion between bony walls into a tooth socket. This approach is intended to decrease or eliminate need for larger bone augmentation procedures later. Advanced periodontal bone loss around failing tooth or teeth may require more complex ridge preservation techniques. Ridge preservation techniques are usually immediate and simultaneous (*static* surgical concept) but can involve a *dynamic* incremental approach, like in the forced eruption technique.

Ridge augmentation (therapeutic approach) is comprised of hard and soft tissue grafting procedures that intend to increase (augment) the alveolar ridge volume *beyond* the existing skeletal envelope. These surgical procedures are usually performed at the edentulous state of horizontally, vertically, or volumetrically deficient alveolar ridges. The surgical techniques tend to involve either an onlay (external) or inlay (interpositional) approach with a particulate or block bone grafting that are usually done in immediate *static* fashion. It can also involve a bone distraction method that progresses in an incremental *dynamic* fashion.

An accepted objective of both successful ridge preservation and ridge augmentation techniques is to place dental implant or implants in a restoratively driven fashion 3- to 6 months after the bone grafting procedure into mature bone and soft tissue housing. Immediate implantation is also a common practice in selected cases.

If ridge preservation techniques in implant dentistry are often easily understood, ridge or bone augmentation methods vary widely and can be confusing. Many surgical mistakes are made due to incorrect diagnosis of an edentulous condition that leads to a substandard treatment protocol. Team concept with collaboration of surgical and restorative colleagues helps to eliminate these mistakes.

When deciding what surgical restorative implant treatment protocol should be used, 3 approaches can be suggested: (1) restorative only (bridge, denture), (2) immediate surgical restorative (implant/bone graft followed by restoration), and (3) staged (delayed) surgical restorative (bone graft, followed by implant, followed by restoration). If a surgical approach is chosen, surgeon's knowledge, skills, and preferences will ultimately dictate the particular bone augmentation technique. This article outlines the surgical restorative implant-driven algorithm that can help to diagnose an edentulous condition and guide the implant team towards the best possible treatment plan for a particular patient.

A flow diagram below based on 10 diagnostic questions (Qs) can help in differential diagnosis and surgical restorative treatment planning of a partial or full edentulous condition with emphasis on bone augmentation in implant dentistry (Figure 1).

Explanation to the flowchart:

Q1: The beginning of the algorithm starts with a simple question: Does every missing tooth have to be replaced? Missing maxillary second molar or mandibular incisor may not always need replacement if both function and esthetics are not compromised.

Q2: Fixed bridge with a 5+ years of functional prognosis might be a better choice if both adjacent teeth have

¹ Oral and Maxillofacial Surgery private practice, San Francisco, Calif.

² Oral and Maxillofacial Surgery, University of the Pacific, School of Dentistry, San Francisco, Calif.

³ Oral and Maxillofacial Surgery, University of California-San Francisco, School of Dentistry, San Francisco, Calif.

Corresponding author, e-mail: Tolstunov@yahoo.com
<https://doi.org/10.1563/aaid-joi-D-18-00315>

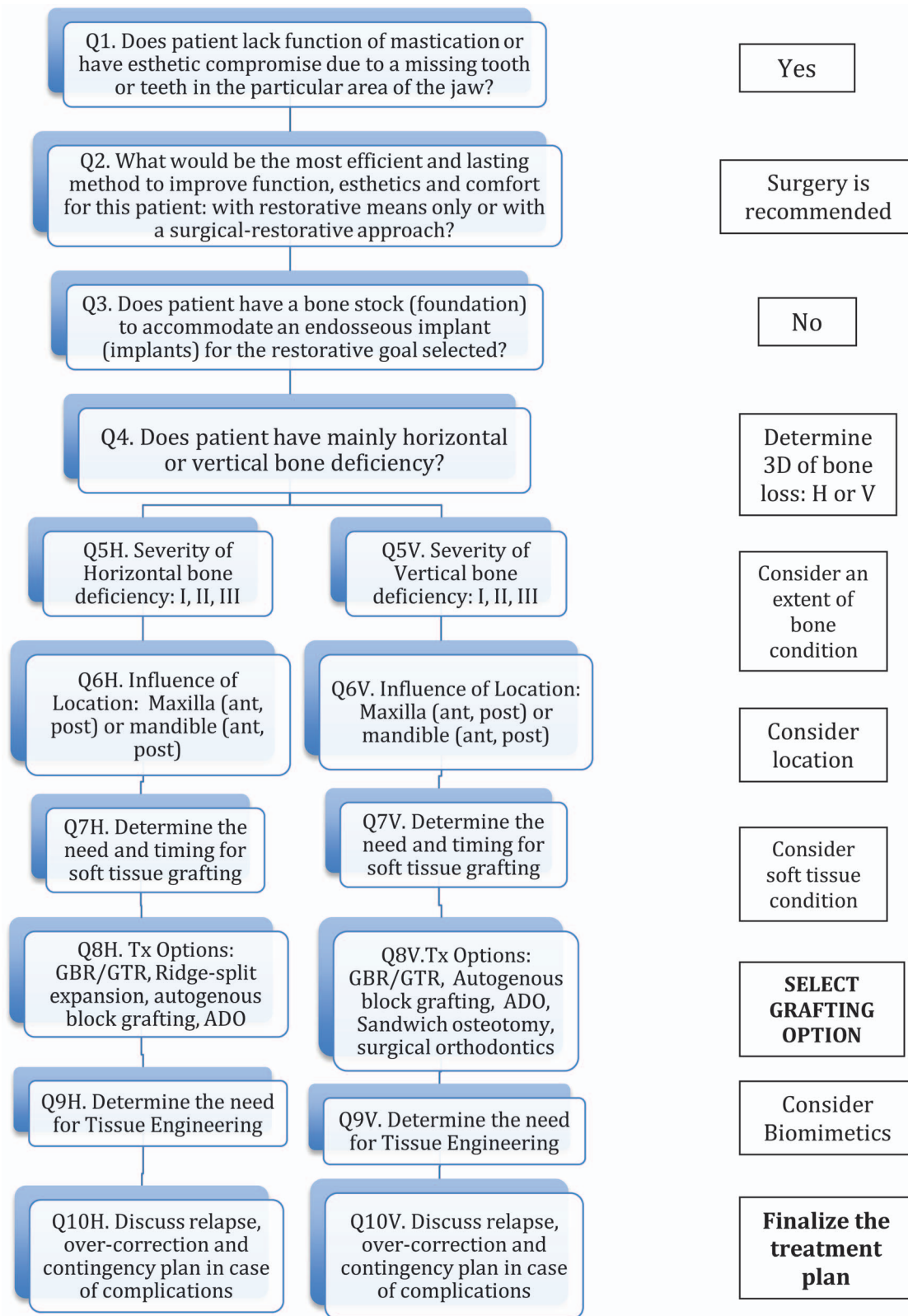


FIGURE 1. Surgical-restorative decision algorithm of the edentulous condition in implant dentistry.

restorations and an edentulous area demonstrates severe bone atrophy (especially, vertical deficiency) requiring extensive surgical procedure(s).

Q3: An important diagnostic question to answer by the surgical practitioner: If surgery is indicated due to lack of bone stock to accommodate an implant or implants.

Q4: Algorithm splits here and follows surgical techniques that have different dimensional goals: vertical bone augmentation (VBA) based on vertical bone defect (VBD) vs horizontal bone augmentation (HBA) based on horizontal bony defect (HBD), or both—3D bone augmentation with horizontal and vertical components. Use of cone beam computerized tomography is strongly recommended at this stage for the proper bone stock assessment.

Q5: Doctor should contemplate the final outcome: placement of a dental fixture inside sufficient bone stock. To accomplish this goal, an operator should consider having the alveolar ridge with a minimum bone stock of $7 \times 7 \times 12$ to accommodate placement of the most common dental implant fixture of 4 mm in diameter and 10 mm in length. Larger size implants would require more bone availability and greater bone augmentation in case of bone atrophy. Anterior maxilla (esthetic zone) and posterior mandible (inferior alveolar nerve proximity) usually benefits from the idealized bone configuration ($10 \times 10 \times 12$). Use of short implants is always a good alternative in indicated cases.

Alveolar Bone Classification by Deficiency (ABCD) (Tolstunov)

HBD (WIDTH compromise): types

0. No HBD is present; bone is intact ($10 \times 10 \times 12$)
- I. Mild HBD = 7 to 9 mm is present (location specific: esthetic zone)
- II. Moderate HBD = 4 to 7 mm is present
- III. Severe HBD = less than 4 mm is present

VBD (HEIGHT compromise): types

0. No VBD is present; bone is intact ($10 \times 10 \times 12$)
- I. Mild VBD = 9 to 11 mm is present (location specific: inferior alveolar nerve)
- II. Moderate VBD = 5 to 8 mm is present
- III. Severe VBD = less than 5 mm is present

Variants of alveolar bone loss:

1. Patient has mainly *horizontal* bone deficiency (I, II, or III),
2. Patient has mainly *vertical* bone deficiency (I, II, or III),
3. Patient has a *combination* bone defect: I/I or II/I, or III/III, and so on, where the first number indicates horizontal deficiency and the second vertical.

Example: patient's posterior maxillary ridge has 6 mm of edentulous ridge width and 9 mm of the alveolar height from the alveolar crest to the sinus floor. This will be classified as type II/I bone defect according to Tolstunov ABCD classification. It means that a surgeon should concentrate mainly on correction of the HBD (from 6 to 10 mm) also attempting to improve bone height through the sinus lift in a staged or simultaneous fashion trying to achieve 10 width \times 10 height stock of bone. Use of short implants is always a good alternative in indicated cases.

Q6: Location can modify the proposed treatment plan due

to maxillary sinus or inferior alveolar canal proximity in posterior maxilla or mandible or parameters of esthetics (ie, smile line) in anterior maxilla. A specific edentulous location should help the doctor to select a particular implant design (straight wall vs tapered, internal vs eternal hex).¹

Q7: Soft tissue quality and quantity should be assessed at this point and should be included, if missing, into the treatment plan. Soft tissue grafting (STG) can be done after or, sometimes, prior to bone grafting.

Q8: Bone deficiency of the edentulous ridge and experience and skills of an operator will determine the proper methods of bone augmentation: particulate (GBR/GTR) vs block (ABB) graft, resorbable membranes vs non-resorbable/Ti mesh, onlay vs inlay (RSEP), alveolar distraction osteogenesis (ADO) vs segmental sandwich osteotomy (SSO).²⁻⁵

Q9: Additional enhancers of healing response (biomimetics) in complex or host immunodeficiency cases should be considered (PRF, PRP, BMA, BMP-2) now.

Q10: It is always important to ask yourself: What if? (intraoperative or postoperative complications) and consider contingency plan at this stage of the decision tree algorithm.

CONCLUSION

A rationale for a particular bone augmentation procedure in oral implantology originates from the very beginning—patient's consultation—using clinical and radiographic data. Patient complaints (symptoms) as well as objective signs of an oral condition lead to diagnosis and a treatment plan. Restorative and surgical doctors' knowledge, skills, and preferences will ultimately dictate the particular bone augmentation technique.

Limitations of this algorithm include new and constantly updated surgical bone grafting techniques as well as, of course, preferences of each doctor based on training and acquired skill-set. This algorithm is not for everybody; as well, it is not all comprehensive in encompassing every possible dental scenario related to failing or missing teeth. Patients' desires and wishes may also significantly alter the proposed treatment. Complex full-arch reconstruction surgical techniques, like "All-On-4," zygomatic and pterygoid implant options will require special surgical and restorative diagnostic criteria and technical skills outside the scope of this article. Yet, this article provides a good starting point for logical approach to diagnosis and treatment planning of most edentulous conditions with emphasis on bone augmentation in implant rehabilitation.

The 10 specific treatment questions (Qs) outlined previously can help restorative and surgical specialists follow a targeted decision tree algorithm to determine the best surgical restorative plan for the edentulous condition. If an implant treatment is indicated, this algorithm can help to choose the appropriate bone augmentation technique for a particular patient in a logical manner.

ABBREVIATIONS

ABB: autogenous block bone graft
 ADO: alveolar distraction osteogenesis
 BMA: bone marrow aspirate

BMP: bone morphogenetic protein
CBCT: cone-beam computed tomography
CSL: crestal sinus lift
GBR: guided bone regeneration
GTR: guided tissue regeneration
HBA: horizontal bone augmentation
HBD: horizontal bone deficiency
LSL: lateral sinus lift
PRF: platelet-rich fibrin
PRP: platelet-rich plasma
RSEP: ridge-split expansion procedure
SSO: segmental sandwich osteotomy
STG: soft tissue graft
TE: tissue engineering
VBA: vertical bone augmentation
VBD: vertical bone deficiency

REFERENCES

1. Drago CJ. Rates of osseointegration of dental implants with regard to anatomic location. *J Prosthodont.* 1992;1:29–31.
2. Aghaloo TL, Moy PK. Which hard tissue augmentation techniques are the most successful in furnishing bony support for implant placement. *Int J Oral Maxillofac Implants.* 2007;22:49–70.
3. Esposito M, Grusovin MG, Coulthard P, Worthington HV. The efficacy of various bone augmentation procedures for dental implants: a Cochrane systematic review of randomized controlled clinical trials. *Int J Oral Maxillofac Implants.* 2006;21:696–710.
4. Simion M, Jovanovic SA, Tinti C, Benfenati SP. Long- term evaluation of osseointegrated implants inserted at the time or after vertical ridge augmentation. A retrospective study on 123 implants with 1-5 year follow-up. *Clin Oral Implants Res.* 2001;12:35–45.
5. Urban IA, Jovanovic S, Lozada JL. Vertical ridge augmentation using guided bone regeneration (GBR) in three clinical scenarios prior to implant placement: a retrospective study of 35 patients 12 to 72 months after loading. *Int J Oral Maxillofac Implants.* 2009;24:502–510.