

Successful in utero stem cell transplantation in X-linked severe combined immunodeficiency

Alessandra Magnani,^{1,2,*} Jean-Marie Jouannic,^{3,*} Jérémie Rosain,^{4,5} Aurélie Gabrion,^{1,2} Fabien Touzot,⁶ Cécile Roudaut,^{1,2} Sven Kracker,² Nizar Mahlaoui,^{5,7,8} Antoine Toubert,^{9,11} Emmanuel Clave,^{9,10} Elisabeth A. Macintyre,^{12,13} Isabelle Radford-Weiss,¹⁴ Marion Alcantara,^{12,13} Elisa Magrin,^{1,2} Brigitte Ternaux,¹ Jennifer Nisoy,¹ Laure Caccavelli,^{1,2} Anne-Marie Darras,³ Capucine Picard,^{4,5,7,15} Stéphane Blanche,^{5,7} and Marina Cavazzana^{1,2,5}

¹Department of Biotherapy, Necker-Enfants Malades University Hospital, Assistance Publique-Hôpitaux de Paris, Paris, France; ²Laboratory of Human Lymphohematopoiesis, INSERM Unité Mixte de Recherche (UMR) 1163, Imagine Institute, Paris, France; ³Department of Fetal Medicine, Armand Trousseau Hospital, Assistance Publique-Hôpitaux de Paris, Sorbonne University, Paris, France; ⁴Study Center for Primary Immunodeficiencies, Assistance Publique-Hôpitaux de Paris, Necker-Enfants Malades University Hospital, Paris, France; ⁵Paris Descartes-Sorbonne Paris Cité University, Imagine Institute, Paris, France; ⁶Department of Immunology-Allergy-Rheumatology, Centre Hospitalier Universitaire Sainte-Justine, University of Montreal, Montreal, QC, Canada; ⁷Department of Pediatric Immunology, Hematology and Rheumatology, Necker-Enfants Malades University Hospital, Assistance Publique-Hôpitaux de Paris, Paris, France; ⁸French National Reference Center for Primary Immune Deficiencies, Necker-Enfants Malades University Hospital, Assistance Publique-Hôpitaux de Paris, Paris, France; ⁹Université Paris Diderot, Sorbonne Paris Cité, Institut Universitaire d'Hématologie, Paris, France; ¹⁰INSERM UMR1160, Alloimmunity-Autoimmunity-Transplantation, Paris, France; ¹¹Laboratoire d'Immunologie et d'Histocompatibilité, Hôpital Saint-Louis, Assistance Publique-Hôpitaux de Paris, Paris, France; ¹²Université Paris Descartes Sorbonne Cité, Institut Necker-Enfants Malades, INSERM U1151, Paris, France; ¹³Laboratory of Onco-Hematology, Assistance Publique-Hôpitaux de Paris, Necker-Enfants Malades University Hospital, Paris, France; ¹⁴Department of Cytogenetics, Assistance Publique-Hôpitaux de Paris, Necker-Enfants Malades University Hospital, Paris, France; and ¹⁵Laboratory of Lymphocyte Activation and Susceptibility to EBV Infection, INSERM UMR 1163, Imagine Institute, Paris, France

Key Points

- IUT enables rapid immune reconstitution and avoids many clinical and economic problems; however, the indication is still limited.
- IUT may be a treatment option in select cases, eg, fetuses exposed to a significant infectious risk, where a matched sibling donor exists.

Introduction

X-linked severe combined immunodeficiency (SCID-X1) is a rare disorder caused by defects in the *IL2RG* gene coding for the common γ chain (a cytokine receptor subunit common to at least 6 different interleukin receptors). The standard treatment of SCID-X1 is allogeneic hematopoietic stem cell transplantation (HSCT).

Here, we report on a successful in utero transplantation (IUT) in a SCID-X1 fetus via the ultrasound-guided intravascular infusion of hematopoietic stem cells (HSCs) into the umbilical vein. The patient (36 months old at the time of writing) is the third child of a woman carrying an *IL2RG* mutation. Prenatal tests (performed at gestational week 10 because of the fetus' male sex) predicted a T^-B^+ SCID caused by a hemizygous c.697delA mutation (p.Ser233ValfsX40). The patient's 4-year-old sister was found to be HLA matched, and postnatal HSCT was scheduled. At a standard serologic screening visit at the end of the first trimester of pregnancy, the mother was diagnosed with a primary *Toxoplasma gondii* infection. The decision to perform IUT was taken to avoid the potentially serious consequences of late maternofetal transmission of *Toxoplasma*.¹ After the provision of the parents' written, informed consent and approval by the French regulatory authorities, bone marrow-derived HSCs were harvested. Immunoselected CD34⁺ cells (15×10^6) and a preparation of CD34⁻ cells containing 8×10^6 T lymphocytes were infused into the umbilical vein at gestational week 25. The result of a polymerase chain reaction (PCR) assay for toxoplasmosis in the amniotic fluid was negative. In line with current French guidelines, the mother was treated with spiramycin until delivery.

Methods

Prenatal genetic testing (targeted Sanger sequencing of *IL2RG* exon 5 and flanking microsatellites study) was performed on genomic DNA extracted from a chorionic villus sample. Signal-joint and β -chain T-cell receptor excision circles (TRECs) were quantified using a real-time quantitative PCR assay, as described previously.² Chimerism was studied using (1) fluorescence in situ hybridization and X- and Y-chromosome-specific probes according to the manufacturer's protocol (Cytocell, Cambridge, United Kingdom) and (2) real-time quantitative

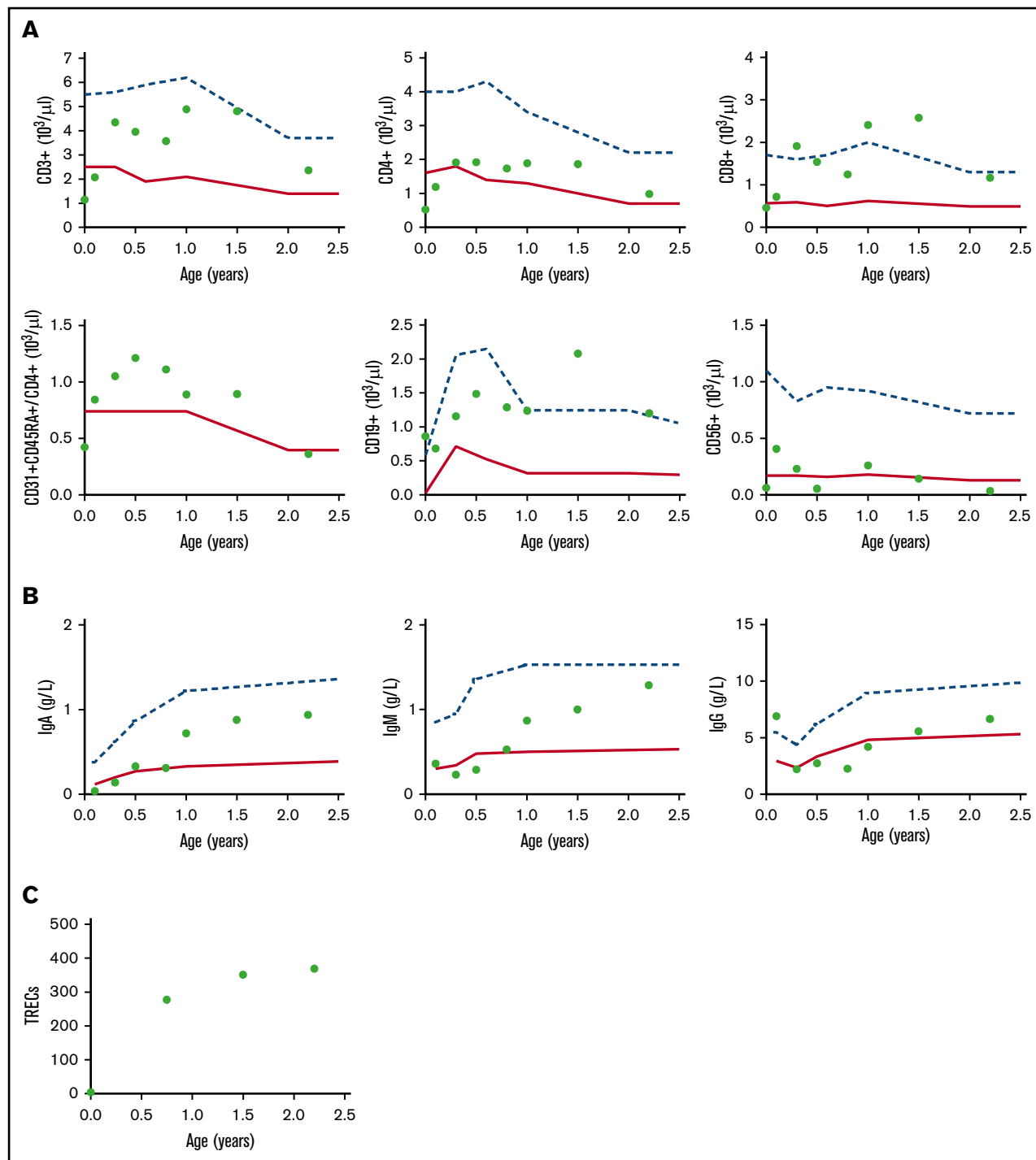


Figure 1. Immune reconstitution after birth. (A) CD3⁺, CD4⁺, CD8⁺, CD31⁺CD45RA⁺CD4⁺, CD19⁺, and CD56⁺ cell counts. (B) Immunoglobulin A (IgA), IgM, and IgG reconstitution. (C) TRECs. Dots correspond to the values recorded. The lower and upper boundaries of the age-specific normal range are indicated by solid and dashed lines, respectively.

PCR assays for donor- and recipient-specific single-nucleotide polymorphisms (KMRtype and KMRtrack chimerism monitoring reagents; GenDx).³ The T-cell receptor γ repertoire was assessed using single-tube, EuroClonality-inspired multiplex PCR, as described elsewhere.^{4,5} The IUT was performed by ultrasound-guided infusion into the umbilical vein.⁶

Prior to the in utero engraftment, the procedure was approved by the French Competent Authority, investigators have complied with the applicable regulatory requirements and the ethical principles that have their origin in the Declaration of Helsinki. They provided a documented patient information sheet to the family, and informed consent was duly signed prior to engraftment. The investigators

Table 1. Hematopoietic and immune reconstitution in the peripheral blood after birth

	At birth	3 wk	3 mo	Age-matched reference values (for <6 mo)	6 mo	12 mo	19 mo	27 mo	Age-matched reference values (for last follow-up)
Hemoglobin, g/dL	16.6	12.8	10.9	10-14	10.5	11.4	12.5	11.5	11.5-13.5
Platelets, $\times 10^9/L$	293	452	671	175-500	485	403	414	261	175-500
Neutrophils, $\times 10^9/L$	—	5.7	4.2	1.0-9.0	2.5	1.9	—	2	1.5-8.5
Lymphocytes, $\times 10^9/L$	2.1	3.4	5.8	2-13.5	5.5	6.4	7.2	3.6	3-9.5
CD3 ⁺ , %	55	61	75	53-84	72	75	67	65	56-75
CD4 ⁺ , %	25	35	33	35-64	35	29	26	27	28-47
CD8 ⁺ , %	22	21	33	12-28	28	37	36	32	16-30
CD4 ⁺ CD45RA ⁺ , %	96	89	75	88-95	85	96	72	52	73-86
CD31 ⁺ CD45RA ⁺ CD4 ⁺ , %	81	71	55	60-72	63	47	48	37	57-65
CD4 ⁺ CCR7 ⁺ CD95 ⁺ , %	87	—	14.3	NA	—	—	—	—	NA
CD8 ⁺ CCR7 ⁺ CD95 ⁺ , %	90	—	3.46	NA	—	—	—	—	NA
CD19 ⁺ , %	41	20	20	6-32	27	19	29	33	7.6-28.2
CD16 ⁺ CD56 ⁺ , %	3	12	4	4-18	1	4	2	1	4-17
PHA T-cell proliferation, CPM/ 10^3	21.5	—	—	>50	136	65	48	—	>50
Tetanus toxoid T-cell proliferation, CPM/ 10^3	—	—	—	>10	—	5.8	72	—	>10

CPM, counts per minute; NA, not available; PHA, phytohemagglutinin.

received an institutional review board's favorable opinion of the written informed consent form.

Please see supplemental Methods for a more detailed description of the methods used.

Results and discussion

No adverse events were observed during or after the cell infusion. The course of pregnancy was uneventful, and a healthy baby (birth weight, 3930 g; height, 52 cm; head circumference, 36 cm) was born at term.

Peripheral blood samples were analyzed at birth and at several time points thereafter as part of our routine posttransplant care. Immune reconstitution was tracked over time (Figure 1; Table 1). A high proportion of CD4⁺ cells coexpressed the CD45RA antigen, suggesting the presence of effective de novo thymopoiesis (Figure 1; Table 1). The cord blood predominantly contained naive T cells (CCR7⁺CD45RA⁺CD45RO⁻) with a memory stem cell phenotype (CD95⁺) (Table 1; supplemental Figure 1). It is noteworthy that the low TREC level at birth increased gradually over time (Figure 1). The β -chain TREC level and intrathymic proliferation were similar to those observed in healthy infant donors (<4.5 years of age) in our establishment, suggesting that posttransplantation thymopoiesis was normal.

The postnatal clinical course was uneventful, and the baby was discharged 5 days after birth. No restrictions were placed on the baby's everyday life, and he was breastfed. The presence of normal neutrophil, hemoglobin, and platelet counts from birth onwards testified to a normal hematopoiesis (Table 1). The patient did not require red blood cell or platelet transfusions.

The circulating T lymphocyte count rose steadily, and the subset counts normalized between 1 and 3 months after birth. The memory T-cell count and TREC level increased progressively, in line with

exposure to the environment and as immune reconstitution continued (Figure 1; Table 1). In vitro lymphoproliferative responses to common T-cell mitogens and alloantigens normalized by 6 and 19 months, respectively (Table 1). A polyclonal T-cell receptor γ repertoire was observed at 12 months (supplemental Figure 2). Congenital toxoplasmosis was ruled out by negative serologic assay results.

The B-cell count was normal from birth onwards. Immunoglobulin production increased over time and had normalized by month 6 (Figure 1). An assessment of the B-cell subset distribution at last follow-up showed the presence of CD27⁺IgD⁻ switched memory B cells and CD27⁺IgD⁺ marginal zone B cells, although the proportions (1% and 2% of the CD19⁺ cells, respectively) were lower than age-matched reference values. Postvaccination antibody titers measured several months after immunization were normal for diphtheria and tetanus and partially positive for *Pneumococcus* antigens (supplemental Table 1). Immunoglobulin replacement therapy was not required at any time, and a normal subset of follicular helper T cells was observed (supplemental Figure 3). In order to determine the origin of the patient's circulating B cells, we characterized the donor-recipient chimerism in sorted blood subpopulations. The T cells proved to be donor derived, while the circulating B cells, monocytes, and neutrophils were recipient derived (supplemental Table 2).

At present, the patient is healthy; no signs of graft-versus-host-disease have been detected, and hospitalization has never been required.

Here, we report a successful IUT in a fetus with SCID-X1. Transplantation led to sustained, protective immune reconstitution soon after birth and yielded normal numbers of functional circulating T cells with a polyclonal repertoire. We observed that memory stem cells were prevalent at birth; the low TREC levels in these cells⁷ might explain why the initially low value rose

progressively in parallel with T-cell recovery, demonstrating effective thymopoiesis. This finding is in line with the dynamic thymopoiesis observed after early postnatal HSCT in SCID (evidencing normal thymic function in the complete absence of infections) and reports in which HSCT early in life leads to a higher thymic output and a higher survival rate.⁹ The low observed natural killer cell count was similar to that obtained after HSCT in the absence of conditioning. Post-IUT B-cell reconstitution in SCID is still subject to debate.⁹ Interestingly, our patient displayed normal immunoglobulin levels and did not require immunoglobulin replacement therapy, although the circulating B cells were recipient derived.

As reported in the literature, IUT has several potential advantages; it avoids the problems associated with postnatal transplantation and may induce donor-specific tolerance.¹⁰⁻¹³ However, clinical experience with IUT is limited by the lack of sustained donor engraftment and the risks associated with the procedure. The best results have been obtained in SCID-X1, thanks to the healthy cells' large selective advantage. In the present case, an HLA-identical donor was available; most of the IUTs reported in the literature are haploidentical transplants, which are more complex and may have a less satisfactory outcome.¹² In IUT, donor cells can be infused into the peritoneum or umbilical vein; the latter procedure is much more efficient but more technically demanding.

As suggested elsewhere, IUT is a potential treatment for certain congenital disorders.¹³ Furthermore, IUT could be usefully combined with more specific, less toxic conditioning methods, such as the antibody-mediated depletion of recipient HSCs.^{14,15}

In conclusion, IUT via ultrasound-guided cell infusion was safe. It enabled rapid immune reconstitution and avoided many clinical and health economic problems. However, the risks associated with the

procedure and the high success rate achieved by early postnatal transplantation limit the indication for IUT. Nevertheless, this procedure may be a treatment option in selected cases, such as fetuses exposed to a significant risk of infectious disease.

Acknowledgments

The authors acknowledge the patient and his family and thank Amélie Trinquand and Loic Chentout for excellent technical assistance. S.K. is a staff researcher at the Centre National de la Recherche Scientifique.

Authorship

Contribution: M.C., S.B., J.-M.J., C.P., and A.M. provided family care and follow-up, designed the study, and collected and analyzed the data; J.-M.J., M.C., S.B., A.-M.D., A.M., E.M., B.T., and J.N. prepared and performed the transplantation; C.P. and J.R. performed prenatal genetic diagnoses; C.P., J.R., M.C., A.M., F.T., A.G., C.R., and S.K. performed immunological assessments; A.M. and M.C. wrote the paper; A.M., M.C., C.P., S.B., J.-M.J., J.R., F.T., S.K., N.M., A.T., E.C., E.M., and I.R.-W. critically reviewed the manuscript; A.T. and E.C. performed the TREC analysis; E.M., M.A., and I.R.W. performed the chimerism analysis; and N.M. and L.C. provided clinical data and technical support.

Conflict-of-interest disclosure: The authors declare no competing financial interests.

ORCID profiles: A.M., 0000-0002-0674-9288; F.T., 0000-0002-0889-4905.

Correspondence: Alessandra Magnani, Biotherapy Department, Necker-Enfants Malades University Hospital, 149 Rue de Sèvres, 75015 Paris, France; e-mail: alessandra.magnani@aphp.fr.

References

1. Fallahi S, Rostami A, Nourollahpour Shiadeh M, Behniafar H, Paktinat S. An updated literature review on maternal-fetal and reproductive disorders of *Toxoplasma gondii* infection. *J Gynecol Obstet Hum Reprod*. 2018;47(3):133-140.
2. Arruda LCM, Malmegrim KCR, Lima-Júnior JR, et al. Immune rebound associates with a favorable clinical response to autologous HSCT in systemic sclerosis patients. *Blood Adv*. 2018;2(2):126-141.
3. Alizadeh M, Bernard M, Danic B, et al. Quantitative assessment of hematopoietic chimerism after bone marrow transplantation by real-time quantitative polymerase chain reaction. *Blood*. 2002;99(12):4618-4625.
4. Derriex C, Trinquand A, Bruneau J, et al. A single-tube, EuroClonality-inspired, TRG clonality multiplex PCR aids management of patients with enteropathic diseases, including from formaldehyde-fixed paraffin-embedded tissues. *J Mol Diagn*. 2019;21(1):111-122.
5. Langerak AW, Groenen PJ, Brüggemann M, et al. EuroClonality/BIOMED-2 guidelines for interpretation and reporting of Ig/TCR clonality testing in suspected lymphoproliferations. *Leukemia*. 2012;26(10):2159-2171.
6. Daffos F, Capella-Pavlovsky M, Forestier F. Fetal blood sampling during pregnancy with use of a needle guided by ultrasound: a study of 606 consecutive cases. *Am J Obstet Gynecol*. 1985;153(6):655-660.
7. Gattinoni L, Lugli E, Ji Y, et al. A human memory T cell subset with stem cell-like properties. *Nat Med*. 2011;17(10):1290-1297.
8. Admiraal R, de Koning CCH, Lindemans CA, et al. Viral reactivations and associated outcomes in the context of immune reconstitution after pediatric hematopoietic cell transplantation. *J Allergy Clin Immunol*. 2017;140(6):1643-1650.e9.
9. Bartolomé J, Porta F, Lafranchi A, et al. B cell function after haploidentical in utero bone marrow transplantation in a patient with severe combined immunodeficiency. *Bone Marrow Transplant*. 2002;29(7):625-628.
10. Wengler GS, Lanfranchi A, Frusca T, et al. In-utero transplantation of parental CD34 haematopoietic progenitor cells in a patient with X-linked severe combined immunodeficiency (SCIDX1). *Lancet*. 1996;348(9040):1484-1487.
11. Flake AW, Roncarolo MG, Puck JM, et al. Treatment of X-linked severe combined immunodeficiency by in utero transplantation of paternal bone marrow. *N Engl J Med*. 1996;335(24):1806-1810.

12. Pirovano S, Notarangelo LD, Malacarne F, et al. Reconstitution of T-cell compartment after in utero stem cell transplantation: analysis of T-cell repertoire and thymic output. *Haematologica*. 2004;89(4):450-461.
13. Vrecenak JD, Flake AW. In utero hematopoietic cell transplantation—recent progress and the potential for clinical application. *Cytotherapy*. 2013; 15(5):525-535.
14. Kim AG, Vrecenak JD, Boelig MM, et al. Enhanced in utero allogeneic engraftment in mice after mobilizing fetal HSCs by $\alpha 4\beta 1/7$ inhibition. *Blood*. 2016; 128(20):2457-2461.
15. Witt RG, Kreger EM, Buckman LB, et al. Systemic multilineage engraftment in mice after in utero transplantation with human hematopoietic stem cells. *Blood Adv*. 2018;2(1):69-74.