

# Post-dural puncture headache: pathogenesis, prevention and treatment

D. K. Turnbull<sup>1\*</sup> and D. B. Shepherd<sup>1 2</sup>

<sup>1</sup>Academic Anaesthetic Unit, University of Sheffield, K Floor, Royal Hallamshire Hospital, and  
<sup>2</sup>Jessop Hospital for Women, Sheffield S10 2JF, UK

\*Corresponding author. E-mail: toleytiger@yahoo.co.uk

Spinal anaesthesia developed in the late 1800s with the work of Wynter, Quincke and Corning. However, it was the German surgeon, Karl August Bier in 1898, who probably gave the first spinal anaesthetic. Bier also gained first-hand experience of the disabling headache related to dural puncture. He correctly surmised that the headache was related to excessive loss of cerebrospinal fluid (CSF). In the last 50 yr, the development of fine-gauge spinal needles and needle tip modification, has enabled a significant reduction in the incidence of post-dural puncture headache. Though it is clear that reducing the size of the dural perforation reduces the loss of CSF, there are many areas regarding the pathogenesis, treatment and prevention of post-dural puncture headache that remain contentious. How does the microscopic pattern of collagen alignment in the spinal dura affect the dimensions of the dural perforation? How do needle design, size and orientation influence leakage of CSF through the dural perforation? Can pharmacological methods reduce the symptoms of post-dural puncture headache? By which mechanism does the epidural blood patch cure headache? Is there a role for the prophylactic epidural blood patch? Do epidural saline, dextran, opioids and tissue glues reduce the rate of CSF loss? This review considers these contentious aspects of post-dural puncture headache.

*Br J Anaesth* 2003; **91**: 718–29

**Keywords:** anaesthetic techniques, subarachnoid; analeptics, caffeine; complications, dural puncture; complications, headache

## History

Spinal anaesthesia developed in the late 1800s. In 1891, Wynter and Quincke<sup>95</sup> aspirated cerebrospinal fluid (CSF) from the subarachnoid space for the treatment of raised intracranial hypertension associated with tuberculous meningitis. The catheters and trochars used were probably about 1 mm in diameter and would certainly have led to a post-dural puncture headache. However, all Quincke and Wynters' subjects died soon after.

In 1895, John Corning, a New York physician specializing in diseases of the mind and nervous system, proposed that local anaesthesia of the spinal cord with cocaine may have therapeutic properties.<sup>50</sup> Corning injected cocaine 110 mg at the level of the T11/12 interspace in a man to treat habitual masturbation. Despite being accredited with the first spinal anaesthetic, it is unlikely from his description and the dose of cocaine that his needle entered the subarachnoid space.<sup>82</sup> In August 1898, Karl August Bier,<sup>137</sup> a German surgeon, injected cocaine 10–15 mg into the subarachnoid space of seven patients, himself and

his assistant, Hildebrandt. Bier, Hildebrandt and four of the subjects all described the symptoms associated with post-dural puncture headache. Bier surmised that the headache was attributable to loss of CSF. By the early 1900s, there were numerous reports in the medical literature of the application of spinal anaesthesia using large spinal needles.<sup>75</sup> Headache was reported to be a complication in 50% of subjects. At that time, the headache was said to resolve within 24 h.

Ether anaesthesia was introduced into obstetric practice in 1847, shortly after Morton's public demonstration. Despite the obvious advantages of regional anaesthesia for the relief of labour pain, it was not until a Swiss obstetrician in 1901 used intrathecal cocaine for the relief of pain in the second stage of labour that regional anaesthesia for obstetrics was popularized.<sup>49</sup> Though both vomiting and a high incidence of post-dural puncture headache were noted, it was the high mortality rate in Caesarean deliveries performed under spinal anaesthesia (1 in 139) that led to the abandonment of this technique in the 1930s. The period from 1930 to 1950 has often been referred to as the 'dark

ages of obstetric anaesthesia', when natural childbirth and psychoprophylaxis were encouraged.

In 1951, Whitacre and Hart<sup>59</sup> developed the pencil-point needle, based on the observations of Greene<sup>53</sup> in 1926. Developments in needle design since that time have led to a significant reduction in the incidence of post-dural puncture headache. However, dural puncture headache remains a disabling complication of needle insertion into the subarachnoid space.

## Pathophysiology of dural puncture

### *Anatomy of the spinal dura mater*

The spinal dura mater is a tube extending from the foramen magnum to the second segment of the sacrum. It contains the spinal cord and nerve roots that pierce it. The dura mater is a dense, connective tissue layer made up of collagen and elastic fibres. The classical description of the spinal dura mater is of collagen fibres running in a longitudinal direction.<sup>53</sup> This had been supported by histological studies of the dura mater.<sup>93</sup> Clinical teaching based upon this view of the dura recommends that a cutting spinal needle be orientated parallel rather than at right angles to these longitudinal dural fibres. Orientating the needle at right angles to the parallel fibres, it was said would cut more fibres. The cut dural fibres, previously under tension, would then tend to retract and increase the longitudinal dimensions of the dural perforation, increasing the likelihood of a post-spinal headache. Clinical studies had confirmed that post-dural puncture headache was more likely when the cutting spinal needle was orientated perpendicular to the direction of the dural fibres. However, recent light and electron microscopic studies of human dura mater have contested this classical description of the anatomy of the dura mater.<sup>102</sup> These studies describe the dura mater as consisting of collagen fibres arranged in several layers parallel to the surface. Each layer or lamellae consists of both collagen and elastic fibres that do not demonstrate specific orientation.<sup>43</sup> The outer or epidural surface may indeed have dural fibres arranged in a longitudinal direction, but this pattern is not repeated through successive dural layers. Recent measurements of dural thickness have also demonstrated that the posterior dura varies in thickness, and that the thickness of the dura at a particular spinal level is not predictable within an individual or between individuals.<sup>102</sup> Dural perforation in a thick area of dura may be less likely to lead to a CSF leak than a perforation in a thin area, and may explain the unpredictable consequences of a dural perforation.

### *Cerebrospinal fluid*

CSF production occurs mainly in the choroid plexus, but there is some evidence of extrachoroidal production. About 500 ml of CSF is produced daily ( $0.35 \text{ ml min}^{-1}$ ). The CSF

volume in the adult is approximately 150 ml, of which half is within the cranial cavity. The CSF pressure in the lumbar region in the horizontal position is between 5 and 15 cm H<sub>2</sub>O. On assuming the erect posture, this increases to over 40 cm H<sub>2</sub>O. The pressure of the CSF in children rises with age, and may be little more than a few cm H<sub>2</sub>O in early life.

### *Dura mater and response to trauma*

The consequences of perforation of the spinal or cranial dura are that there will be leakage of CSF. Neurosurgical experience of dural perforation is that even minor perforations need to be closed, either directly or through the application of synthetic or biological dural graft material. Failure to close the dural perforation may lead to adhesions, continuing CSF leak, and the risk of infection. There are few experimental studies of the response of the dura to perforation.<sup>70</sup> In 1923, it was noted that deliberate dural defects in the cranial dura of dogs took approximately one week to close. The closure was facilitated through fibroblastic proliferation from the cut edge of the dura. Work published in 1959<sup>70</sup> dismissed the notion that the fibroblastic proliferation arose from the cut edge of the dura. This study maintained that the dural repair was facilitated by fibroblastic proliferation from surrounding tissue and blood clot. The study also noted that dural repair was promoted by damage to the pia arachnoid, the underlying brain and the presence of blood clot. It is therefore possible that a spinal needle carefully placed in the subarachnoid space does not promote dural healing, as trauma to adjacent tissue is minimal. Indeed, the observation that blood promotes dural healing agrees with Gormley's original observation that bloody taps were less likely to lead to a post-dural puncture headache as a consequence of a persistence CSF leak.<sup>51</sup>

### *Needle tip deformation and dural perforation*

It has been proposed that contact with bone during insertion may lead to spinal needle tip deformation.<sup>67,90</sup> Damaged needle tips could lead to an increase in the size of the subsequent dural perforation. Recent *in vivo* studies have demonstrated that the cutting type spinal needle is more likely to be deformed after bony contact than comparable sized pencil-point needles.<sup>90</sup> However, no *in vivo*<sup>67</sup> or *in vitro* work has yet demonstrated an increase in the size of dural perforation where damaged needles are used.

### *Consequences of dural puncture*

Puncture of the dura has the potential to allow the development of excessive leakage of CSF. Excess loss of CSF leads to intracranial hypotension and a demonstrable reduction in CSF volume.<sup>52</sup> After the development of post-dural puncture headache, the presence of a CSF leak has been confirmed with radionuclide cisternography,<sup>100</sup>

radionuclide myelography, manometric studies, epiduroscopy and direct visualization at laminectomy. The adult subarachnoid pressure of 5–15 cm H<sub>2</sub>O is reduced to 4.0 cm H<sub>2</sub>O or less.<sup>100</sup> The rate of CSF loss through the dural perforation<sup>29</sup> (0.084–4.5 ml s<sup>-1</sup>) is generally greater than the rate of CSF production (0.35 ml min<sup>-1</sup>), particularly with needle sizes larger than 25G.<sup>29 101</sup>

Gadolinium-enhanced MRI, in the presence of a post-dural puncture headache, frequently demonstrates ‘sagging’ of the intracranial structures. The MRI may or may not demonstrate meningeal enhancement.<sup>56</sup> The meningeal enhancement is attributable to vasodilatation of thin-walled vessels in response to the intracranial hypotension. Histological studies have confirmed that the vasodilatation of meningeal vessels is unrelated to an inflammatory response.<sup>56</sup>

Although the loss of CSF and lowering of CSF pressure is not disputed, the actual mechanism producing the headache is unclear. There are two possible explanations. First, the lowering of CSF pressure causes traction on the intracranial structures in the upright position. These structures are pain sensitive, leading to the characteristic headache. Secondly, the loss of CSF produces a compensatory venodilatation *vis-à-vis* the Monro–Kellie doctrine.<sup>52</sup> The Monro–Kellie doctrine, or hypothesis, states that the sum of volumes of the brain, CSF, and intracranial blood is constant. The consequence of a decrease in CSF volume is a compensatory increase in blood volume. The venodilatation is then responsible for the headache.

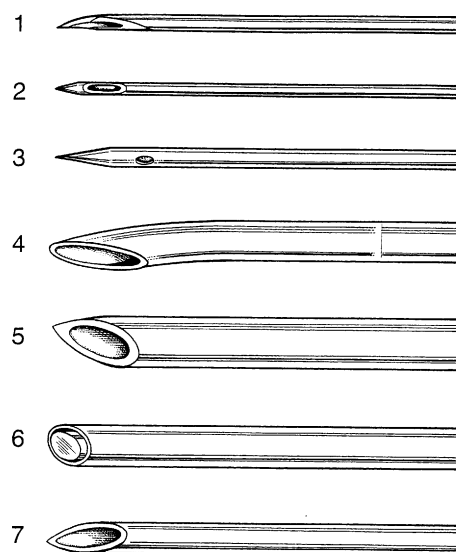
## Incidence

The incidence of post-dural puncture headache was 66% in 1898.<sup>137</sup> This alarmingly high incidence of post-spinal headache was likely attributable to the use of large gauge, medium bevel, cutting spinal needles (needles 5, 6 and 7, Fig. 1). In 1956, with the introduction of 22G and 24G needles, the incidence was estimated to be 11%.<sup>132</sup>

Today the use of fine gauge pencil-point needles, such as the Whitacre and Sprotte<sup>®</sup> has produced a greater reduction in the incidence of post-dural puncture headache, which varies with the type of procedure and patients involved. It is related to the size and design of the spinal needle used (Fig. 1; Table 1),<sup>36</sup> the experience of the personnel performing the dural puncture,<sup>35</sup> and the age and sex of the patient.

## Spinal anaesthesia

Anaesthetists have been active in attempting to reduce the incidence of post-spinal headache. Reducing the size of the spinal needle has made a significant impact on the incidence of post-spinal headache. The incidence is ~40% with a 22G needle; 25% with a 25G needle;<sup>4 44</sup> 2%–12% with a 26G Quincke needle;<sup>4 45</sup> and <2% with a 29G needle.<sup>47</sup> However, technical difficulties leading to failure of the



**Fig 1** Graphical representations of epidural (needle 4) and spinal needle tip design. Note the large orifice and conical tip of the Sprotte<sup>®</sup> Needle 2, compared with the small orifice and diamond tip of the Whitacre Needle 3. Needles 5, 6 and 7 were provided by the Sheffield Anaesthetic Museum and are an indication of the style of spinal needles used in the past. 1, 26G Atraucan<sup>®</sup> Double Bevel Design; 2, 26G Sprotte<sup>®</sup> Style Pencil Point; 3, 22G Whitacre Style Pencil Point; 4, 16G Tuohy Needle; 5, 17G Barkers Spinal Needle; 6, Large Gauge Spinal Needle; 7, 18G Crawford Needle.

**Table 1** Relationship between needle size and incidence of post-dural puncture headache

Needle tip design	Needle gauge	Incidence of post-dural puncture headache (%)
Quincke	22	36 <sup>128</sup>
Quincke	25	3–25 <sup>47</sup>
Quincke	26	0.3–20 <sup>45 107</sup>
Quincke	27	1.5–5.6 <sup>25 69</sup>
Quincke	29	0–2 <sup>45 47 69</sup>
Quincke	32	0.4 <sup>46</sup>
Sprotte	24	0–9.6 <sup>13 107</sup>
Whitacre	20	2–5 <sup>17</sup>
Whitacre	22	0.63–4 <sup>17 112</sup>
Whitacre	25	0–14.5 <sup>13 98</sup>
Whitacre	27	0 <sup>25</sup>
Atraucan	26	2.5–4 <sup>115 131</sup>
Tuohy	16	70 <sup>26</sup>

spinal anaesthetic are common with needles of 29G or smaller.<sup>47</sup> In 1951, Whitacre and Hart<sup>59</sup> introduced the ‘atraumatic’ spinal needle (needle 3, Fig. 1). This design offered the handling characteristics of larger needles with a low incidence of post-spinal headache (Table 1). Needle modifications since that time, such as the Sprotte<sup>®119</sup> and Atraucan<sup>®63</sup> needles, promise further reductions in post-spinal headache.

## Diagnostic lumbar puncture

The acceptance of small gauge needles for diagnostic lumbar puncture has been slow to develop. Until recently,

diagnostic lumbar puncture was commonly performed with a 20G or even 18G medium bevel cutting needle with a high incidence of post-spinal headache. A recent publication promoted the virtues of a 20G needle for reducing the incidence of dural puncture headache!<sup>125</sup> Though anaesthetists are in general critical of the use of large gauge needles for lumbar puncture,<sup>105</sup> neurologists maintain that adequate flow of CSF can only be achieved with spinal needles of 22G or greater.<sup>18</sup>

### *Obstetrics*

The parturient is at particular risk of dural puncture and the subsequent headache because of their sex, young age, and the widespread application of epidural anaesthesia.<sup>44</sup> In parturients receiving epidural anaesthesia, the incidence of dural puncture is between 0 and 2.6%.<sup>104</sup> The incidence is inversely related to the experience of the anaesthetist,<sup>80</sup> and is said to be reduced by orientation of the needle bevel parallel to the dural fibres.<sup>87</sup> Loss of resistance to air confers a higher risk of dural puncture than loss of resistance to fluid.<sup>105</sup> After a dural puncture with a 16G Tuohy needle, up to 70% of subjects will report symptoms related to low CSF pressure.<sup>26</sup> Despite the high incidence of headache consequent upon dural puncture with a Tuohy needle, the anaesthetist needs to consider a differential diagnosis, as intracranial haematoma,<sup>65</sup> or tumour<sup>38</sup> presenting with similar symptoms to, or in association with, a post-dural puncture headache have been described.

In the presence of a known dural puncture, it is often recommended that pushing in the second stage should be avoided.<sup>88</sup> The evidence to support this assertion is far from conclusive, and anger from the parturient about the medicalization of her labour is best avoided.<sup>26 133</sup>

### *Children*

Post-dural puncture headache is reported as uncommon in children.<sup>14</sup> Although low CSF pressure or other physiological differences have been proffered as reasons to explain the low incidence in children, it is likely that a low reporting rate is the explanation. Groups that have explored the incidence of post-spinal headaches in children have found rates comparable to young adults.<sup>73</sup>

## **Prevention**

Spinal needles have undergone numerous modifications in recent years, the aim being to reduce the incidence of dural puncture headache. The principal factor responsible for the development of a dural puncture headache is the size of the dural perforation. Other factors such as the shape of the dural perforation and the orientation of the spinal needle have a less significant role.

### *Needle size*

Large spinal needles will clearly produce large dural perforations where the likelihood of a dural puncture headache is high. Conversely, the smaller needles produce small dural perforations with a lower incidence of headache. Fine gauge spinal needles, 29G or smaller, are technically more difficult to use,<sup>64</sup> and for spinal anaesthesia at least, are associated with a high failure rate.<sup>45</sup> A balance has to be struck between the risks of dural puncture headache and technical failure. 25G, 26G and 27G<sup>69</sup> needles probably represent the optimum needle size for spinal anaesthesia. Neurologists argue that for the purposes of aspiration of CSF and measurement of CSF pressure, 22G needles are the smallest practical needles.

### *Needle orientation*

There are many clinical,<sup>79 87</sup> and laboratory,<sup>36 101</sup> studies that lend credence to the hypothesis that perpendicular orientation of the bevel of a spinal or epidural needle leads to a reduction in the incidence of post-dural puncture headache.

### *Needle design*

Over the years since Quincke and Bier, a large number of needle designs have been introduced. The Quincke type is the standard needle with a medium cutting bevel and the orifice at the needle tip (needle 7, Fig. 1). In 1926, Greene<sup>53</sup> proposed a needle tip design with a non-cutting edge that would separate the dural fibres to avoid post-dural puncture headache. In 1951, the Whitacre needle was introduced and, in 1987, the Sprotte needle. The generic term for these needles is pencil-point or atraumatic, though in truth they are neither. The Whitacre needle (needle 3, Fig. 1) has a diamond shaped tip, and the Sprotte needle (needle 2, Fig. 1) tip is conical. The orifice is up to 0.5 mm from the needle tip. Clinical and laboratory<sup>29</sup> studies have confirmed that pencil-point needles produce fewer post-dural puncture headaches than medium bevel cutting needles. However, there are disadvantages. Paraesthesia has been observed with the pencil-point needles.<sup>115</sup> The reason may lie in the distance from the tip of the needle to the orifice. The tip has to be passed at least 0.5 mm into the subarachnoid space before the orifice enters the subarachnoid space. The tip then has the opportunity to impinge upon the stretched cauda equina. Giving credence to this hypothesis, paraesthesia is uncommon with the short bevel needles or the Atraucan<sup>®</sup> needle.<sup>115</sup>

The problem of low CSF flow and paraesthesia seen with the pencil-point needles has promoted the search for novel needle designs. The Atraucan<sup>®</sup> (needle 1, Fig. 1) has recently been marketed. It has an orifice at the tip of the needle. The Atraucan<sup>®</sup> has a narrow cutting tip and an atraumatic bevel. Initial reports of these needles are promising as regards ease of use and low dural puncture headache rate.<sup>115</sup>

### Operator skill level and fatigue

It has been suggested that the incidence of inadvertent dural puncture during epidural anaesthesia is inversely related to operator experience.<sup>104</sup> However, sleep deprivation, operator fatigue and the effect of night work may be a confounding variable producing the higher incidence of inadvertent dural puncture in junior personnel performing epidural analgesia.

## Presentation of dural puncture headache

### Onset

Headache and backache are the dominant symptoms that develop after accidental dural puncture. Ninety per cent of headaches will occur within 3 days of the procedure,<sup>104</sup> and 66% start within the first 48 h.<sup>76</sup> Rarely, the headache develops between 5 and 14 days after the procedure. Headache may present immediately after dural puncture.<sup>133</sup> However, this is rare, and its occurrence should alert the physician to alternative causes.

### Symptoms

Headache is the predominant, but not ubiquitous presenting complaint.<sup>83</sup> The headache is described as severe, 'searing and spreading like hot metal'.<sup>133</sup> The common distribution is over the frontal and occipital areas radiating to the neck and shoulders. The temporal, vertex and nuchal areas are reported less commonly as the site of discomfort, although neck stiffness may be present. The pain is exacerbated by head movement, and adoption of the upright posture, and relieved by lying down. An increase in severity of the headache on standing is the *sine qua non* of post-dural puncture headache.

Other symptoms associated with dural puncture headache include nausea, vomiting, hearing loss,<sup>78</sup> tinnitus, vertigo, dizziness and paraesthesia of the scalp, and upper<sup>108</sup> and lower limb pain. Visual disturbances such as diplopia or cortical blindness have been reported.<sup>132</sup> Cranial nerve palsies are not uncommon.<sup>16</sup> Two cases of thoracic back pain without headache have been described.<sup>37</sup> Neurological symptoms may precede the onset of grand mal seizures. Intracranial subdural haematomas, cerebral herniation and death,<sup>39</sup> have been described as a consequence of dural puncture. Unless a headache with postural features is present, the diagnosis of post-dural puncture headache should be questioned, as other serious intracranial causes for headache must be excluded.<sup>3</sup>

### Diagnosis

The history of accidental or deliberate dural puncture and symptoms of a postural headache, neck ache and the presence of neurological signs, usually guide the diagnosis. Where there is doubt regarding the diagnosis of post-dural

**Table 2** Differential diagnosis of post-dural puncture headache

Viral, chemical or bacterial meningitis <sup>106</sup>
Intracranial haemorrhage <sup>65 94 104</sup>
Cerebral venous thrombosis <sup>10</sup>
Intracranial tumour <sup>3 38</sup>
Non-specific headache <sup>44</sup>
Pituitary apoplexy <sup>77</sup>
Cerebral infarction
Uncal herniation <sup>39 97</sup>
Sinus headache
Migraine <sup>76</sup>
Drugs (e.g. caffeine, amphetamine)
Pre-eclampsia

puncture headache, additional tests may confirm the clinical findings. A diagnostic lumbar puncture may demonstrate a low CSF opening pressure or a 'dry tap', a slightly raised CSF protein, and a rise in CSF lymphocyte count. An MRI may demonstrate: diffuse dural enhancement, with evidence of a sagging brain; descent of the brain, optic chiasm, and brain stem; obliteration of the basilar cisterns; and enlargement of the pituitary gland.<sup>85</sup> CT myelography, retrograde radionuclide myelography, cisternography, or thin section MRI<sup>130</sup> can be used to locate the spinal source of the CSF leak.

### Differential diagnosis

The diagnosis of post-dural puncture headache is frequently clear from the history of dural puncture and the presence of a severe postural headache. However, it is important to consider alternative diagnoses (Table 2) as serious intracranial pathology may masquerade as a post-dural puncture headache. Clinicians should remember that intracranial hypotension can lead to intracranial haemorrhage through tearing of bridging dural veins,<sup>65 94</sup> and a delay in diagnosis and treatment can be dangerous. Diagnoses that may masquerade as post-dural puncture headache include intracranial tumours,<sup>3 38</sup> intracranial haematoma,<sup>32 40</sup> pituitary apoplexy,<sup>77</sup> cerebral venous thrombosis,<sup>122 134</sup> migraine, chemical or infective meningitis,<sup>106</sup> and non-specific headache. It has been estimated that 39% of parturients report symptoms of a headache unrelated to dural puncture following delivery.<sup>120</sup>

### Duration

The largest follow-up of post-dural puncture headache is still that of Vandam and Dripps in 1956.<sup>132</sup> They reported that 72% of headaches resolved within 7 days, and 87% had resolved in 6 months (Table 3). The duration of the headache has remained unchanged since that reported in 1956.<sup>26</sup> In a minority of patients the headache can persist.<sup>133</sup> Indeed, case reports have described the persistence of headache for as long as 1–8 yr after dural puncture.<sup>80</sup> It is interesting to note that even post-dural puncture headaches of this duration have been successfully treated with an epidural blood patch.<sup>72</sup>

**Table 3** Estimated rate of spontaneous recovery from post-dural puncture headache<sup>26 80 132</sup>

Duration (days)	Percentage recovery
1–2	24
3–4	29
5–7	19
8–14	8
3–6 weeks	5
3–6 months	2
7–12 months	4

## Treatment

### Overview

The literature regarding the treatment of post-dural puncture headache often involves small numbers of patients, or uses inappropriate statistical analysis. Studies observing the effects of treatments in post-dural puncture headache often fail to recognize that, with no treatment, over 85% of post-dural puncture headaches will resolve within 6 weeks (Table 3).

### Psychological

Patients who develop post-dural puncture headache may reveal a wide range of emotional responses from misery and tears to anger and panic. It is important both from a clinical and medico-legal point of view, to discuss the possibility of headache before a procedure is undertaken that has a risk of this complication. Even so, this discussion will not prepare the patient for the sensations he or she feels should the headache develop.<sup>133</sup> Obstetric patients are particularly unfortunate should they develop this complication, as they expect to feel well and happy and to be able to look after their new baby. It is important to give the mother a thorough explanation of the reason for the headache, the expected time course, and the therapeutic options available. Regular review is essential to monitor the course and therapeutic manoeuvres undertaken.

### Simple

Bed rest has been shown to be of no benefit.<sup>118</sup> Supportive therapy such as rehydration, acetaminophen, non-steroidal anti-inflammatory drugs, opioids, and antiemetics may control the symptoms and so reduce the need for more aggressive therapy,<sup>89</sup> but do not provide complete relief.<sup>44</sup>

### Posture

If a patient develops a headache, they should be encouraged to lie in a comfortable position. The patient will often have identified this, without the intervention of an anaesthetist. There is no clinical evidence to support the maintenance of the supine position before or after the onset of the headache

as a means of treatment.<sup>68</sup> The prone position has been advocated, but it is not a comfortable position for the post-partum patient. The prone position raises the intra-abdominal pressure, which is transmitted to the epidural space and may alleviate the headache. A clinical trial of the prone position following dural puncture failed to demonstrate a reduction in post-dural puncture headache.<sup>55</sup>

### Abdominal binder

A tight abdominal binder raises the intra-abdominal pressure. The elevated intra-abdominal pressure is transmitted to the epidural space and may relieve the headache. Unfortunately, tight binders are uncomfortable and are seldom used in current practice. There are few units that would recommend this approach.<sup>86</sup>

### Pharmacological treatment

The aim of management of post-dural puncture headache is to: (i) replace the lost CSF; (ii) seal the puncture site; and (iii) control the cerebral vasodilatation.

A number of therapeutic agents have been suggested for the management of post-dural puncture headache. The main problem in choosing the most appropriate one is the lack of large, randomized, controlled clinical trials.

### DDAVP, ACTH

A report in 1964 identified 49 methods for treating post-spinal headache.<sup>127</sup> There appears to be no limit to the imagination of physicians in treatments offered for post-spinal headache. However, there is a lack of statistical data to support their ideas. Regarding DDAVP (desmopressin acetate), intramuscular administration before lumbar puncture was not shown to reduce the incidence of post-dural puncture headache.<sup>57</sup> ACTH (adrenocorticotrophic hormone)<sup>21</sup> has been administered as an infusion ( $1.5 \mu\text{g kg}^{-1}$ ), but inadequate statistical analysis prevents assessment of the value of ACTH.

### Caffeine

Caffeine is a central nervous system stimulant that amongst other properties produces cerebral vasoconstriction. I.V. caffeine 0.5 g was recommended as a treatment of post-dural puncture headache in 1944.<sup>62</sup> It is available in an oral and i.v. form. The oral form is well absorbed with peak levels reached in 30 min. Caffeine crosses the blood–brain barrier and the long half-life of 3–7.5 h allows for infrequent dosing schedules.

The most frequently quoted work on the treatment of post-dural puncture headache with caffeine is that of Sechzer.<sup>113 114</sup> He evaluated the effects of one or two 0.5 g doses of i.v. caffeine on subjects with established post-dural puncture headache. There are some statistical and methodological flaws in this study, but it was concluded that i.v.

caffeine is an effective therapy for post-dural puncture headache.

#### *Dose*

The dose now recommended for the treatment of post-dural puncture headache is 300–500 mg of oral or i.v. caffeine once or twice daily.<sup>12,66</sup> One cup of coffee contains about 50–100 mg of caffeine and soft drinks contain 35–50 mg. The LD<sub>50</sub> for caffeine is of the order of 150 mg kg<sup>-1</sup>. However, therapeutic doses have been associated with central nervous system toxicity,<sup>9</sup> and atrial fibrillation.

#### *Mode of action*

It is assumed that caffeine acts through vasoconstriction of dilated cerebral vessels.<sup>12</sup> If cerebral vasodilatation were the source of the pain, cerebral vasoconstriction might limit the pain experienced. Indeed, it has been demonstrated that caffeine causes a reduction in cerebral blood flow,<sup>116</sup> but this effect is not sustained. Caffeine therapy is simple to administer compared with the technical skills required to perform an epidural blood patch. Were caffeine as successful as suggested by previous reports, it would no doubt be widely advocated. However, a North American hospital survey of the treatment of post-dural puncture headache identified that most hospital practitioners had abandoned the use of caffeine as they had found it ineffective.<sup>8</sup> The effects of caffeine on post-dural puncture headache seem, at best, temporary.<sup>12</sup> In addition, caffeine is not a therapy without complications,<sup>9</sup> and does not restore normal CSF dynamics, thus leaving the patient at risk from the serious complications associated with low CSF pressure.

#### *Sumatriptan*

The treatment for migranous headaches has focused on modification of cerebral vascular tone. Sumatriptan is a 5-HT<sub>1D</sub> receptor agonist that promotes cerebral vasoconstriction, in a similar way to caffeine.<sup>123</sup> Sumatriptan is advocated for the management of migraine and recently, for post-dural puncture headache. There have been only a few case reports where sumatriptan was used successfully to manage post-dural puncture headache.<sup>61</sup> However, a recent controlled trial found no evidence of benefit from Sumatriptan for the conservative management of post-dural puncture headache.<sup>23</sup>

#### *Epidural blood patch*

##### *History*

After the observation that 'bloody taps' were associated with a reduced headache rate,<sup>51</sup> the concept of the epidural blood patch has developed. The theory is that the blood, once introduced into the epidural space, will clot and occlude the perforation, preventing further CSF leak. The high success rate and the low incidence of complications have established the epidural blood patch as the standard

against which to evaluate alternative methods to treat post-dural puncture headache.

#### *Technique*

The presence of fever, infection on the back, coagulopathy, or patient refusal are contraindications to the performance of an epidural blood patch.<sup>1</sup> As a precautionary measure, a sample of the subject's blood should be sent to microbiology for culture.<sup>27</sup> With the patient in the lateral position, the epidural space is located with a Tuohy needle at the level of the supposed dural puncture or an intervertebral space lower. The operator should be prepared for the presence of CSF within the epidural space. Up to 30 ml of blood is then taken from the patient's arm and injecting slowly through the Tuohy needle. Should the patient describe lancinating pain of dermatomal origin the procedure must be stopped.<sup>27</sup> There is no consensus as to the precise volume of blood required. Most practitioners now recognise that the 2–3 ml of blood originally described by Gormley is inadequate, and that 20–30 ml of blood is more likely to guarantee success.<sup>27</sup> Larger volumes, up to 60 ml,<sup>97</sup> have been used successfully in cases of spontaneous intracranial hypotension. At the conclusion of the procedure, the patient is asked to lie still for one<sup>1,33</sup> or, preferably, 2 h,<sup>81</sup> and is then allowed to walk.

#### *Contraindications*

Contraindications include those that normally apply to epidurals, but include a raised white cell count, pyrexia and technical difficulties. Limited experience with HIV-positive patients suggest that it is acceptable providing no other bacterial or viral illnesses are active.<sup>126</sup> Epidural blood patch following diagnostic lumbar puncture in the oncology patient raises the potential for seeding the neuroaxis with neoplastic cells. One case has been reported of a successful patch without complications,<sup>109</sup> and one case<sup>11</sup> where the risks of central nervous system (CNS) seeding of leukaemia were considered to outweigh the benefits of an epidural blood patch.

#### *The blood patch*

Using either radiolabelled red cells<sup>124</sup> or an MRI scan,<sup>7</sup> several studies have reported the degree of spread of the epidural blood patch. After injection, blood is distributed caudally and cephalad regardless of the direction of the bevel of the Tuohy needle. The blood also passes circumferentially around to the anterior epidural space. The thecal space is compressed and displaced by the blood. In addition, the blood passes out of the intervertebral foramina and into the paravertebral space. The mean spread of 14 ml of blood is six spinal segments cephalad and three segments caudad. Compression of the thecal space for the first 3 h, and a presumed elevation of subarachnoid pressure, may explain the rapid resolution of the headache. Compression of the thecal sac is not, however, sustained and maintenance of the therapeutic effect is likely to be attributable to the presence of the clot eliminating the CSF leak. It has been observed that CSF acts as a procoagulant,

accelerating the clotting process.<sup>24</sup> At 7–13 h, there is clot resolution leaving a thick layer of mature clot over the dorsal part of the thecal sac. Animal studies have demonstrated that 7 days after the administration of an epidural blood patch, there is widespread fibroblastic activity and collagen formation.<sup>34,74</sup> Fortunately, the presence of blood does not initiate an inflammatory process and there is no evidence of axonal oedema, necrosis or demyelination.

#### *Outcome*

The technique has a success rate of 70–98% if carried out more than 24 h after the dural puncture.<sup>1</sup> If an epidural blood patch fails to resolve the headache, repeating the blood patch has a similar success rate. Failure of the second patch and repeating the patch for a third or fourth time has been reported. However, in the presence of persistent severe headache, an alternative cause should be considered.

#### *Complications*

Immediate exacerbation of symptoms and radicular pain have been described.<sup>136</sup> These symptoms do not persist and resolve with the administration of simple painkillers. Long-term complications of epidural blood patch are rare. A single case report of an inadvertent subdural epidural blood patch described non-postural, persistent headache and lower extremity discomfort.<sup>103</sup>

The issue of the effect of the blood patch on the success of subsequent epidurals has been addressed.<sup>2,60</sup> Though case reports describe limited spread of epidural analgesia<sup>99</sup> after previous epidural blood patch, a large retrospective study over a 12-yr period<sup>60</sup> found that subsequent epidural analgesia was successful in >96% of patients.

#### *Prophylactic epidural blood patch*

Where the known incidence of post-dural puncture headache is high, such as in the parturient, the use of a prophylactic epidural blood patch after accidental dural puncture, that is blood patching before the onset of symptoms, is an attractive option. Prophylactic patching has generally been dismissed as ineffective, but the evidence is conflicting. A controlled trial in post-myelogram headaches,<sup>54</sup> and one after spinal anaesthesia and after unintentional dural puncture with an epidural needle,<sup>22</sup> have confirmed the benefit of prophylactic patching. Those studies that have not supported the use of prophylactic patching may have used insufficient blood for the patch.<sup>22</sup> The pressure gradient between the thecal and epidural space may be high immediately after dural puncture and lead to patch separation from the site of the perforation. Blood patching at that time may therefore need a greater volume of blood to produce a successful patch compared with a late patch, where the CSF pressure may be lower.

#### *Chronic headache*

Patients may present with features of a post-spinal headache never having received an epidural or spinal injection. A report of six such cases, with headaches that had been present between 1 and 20 yr, showed complete relief of

headache following lumbar epidural blood patch.<sup>91</sup> It is interesting to speculate that these headaches may have been attributable to unidentified spontaneous intracranial hypotension.

#### *Epidural saline*

Concerns have been expressed about the potential danger of an autologous epidural blood patch for the treatment of post-dural puncture headache. The immediate resolution of the headache with a blood patch is attributable to thecal compression raising the CSF pressure. An epidural injection of saline would, in theory, produce the same mass effect, and restore normal CSF dynamics. As saline is a relatively inert and sterile solution, epidural saline bolus or infusion appears to be an attractive alternative. Regimens that have been advocated include: (i) 1.0–1.5 litre of epidural Hartmanns solution over 24 h, starting on the first day after dural puncture;<sup>28,84,121</sup> (ii) up to 35 ml h<sup>-1</sup> of epidural saline or Hartmanns solution for 24–48 h, or after development of the headache; (iii) a single 30 ml bolus of epidural saline after development of headache;<sup>5,84</sup> and (iv) 10–120 ml of saline injected as a bolus via the caudal epidural space.<sup>6,129</sup>

Advocates of an epidural saline bolus or infusion maintain that the lumbar injection of saline raises epidural and intrathecal pressure. Reduction in the leak would allow the dura to repair. However, observations of the pressures produced in the subarachnoid and epidural space show that, despite a large rise in epidural pressure, the consequent rise in subarachnoid pressure maintains the differential pressure across the dura. The pressure rise is also not sustained and is dissipated within 10 min.<sup>129</sup> The saline may induce an inflammatory reaction within the epidural space, promoting closure of the dural perforation. Histological studies have not demonstrated an inflammatory response following epidural Dextran 40 administration, however, in contrast to an autologous blood patch.<sup>74</sup> There is no reason to suppose that epidural saline is more likely to accelerate dural healing through a proinflammatory action than Dextran 40. Thus, there are no studies that are able to demonstrate either a sustained rise in CSF pressure or accelerated closure of the dural perforation after the administration of epidural saline. Whilst there are many case reports describing the success of epidural saline, comparative trials with epidural blood patches have not demonstrated the long-term efficacy of epidural saline placement.<sup>5</sup> It is difficult to conclude from the evidence therefore, that epidural saline administration will restore normal CSF dynamics. The administration of large volumes of epidural saline may result in intraocular haemorrhages through a precipitous rise in intracranial pressure.<sup>19</sup>

#### *Epidural dextran*

Despite the paucity of evidence to support epidural saline, some observers have considered the epidural administration



of Dextran 40.<sup>117</sup> Those studies that recommend Dextran 40, either as an infusion or as a bolus, conclude that the high molecular weight and viscosity of Dextran 40 slows its removal from the epidural space. The sustained tamponade around the dural perforation allows spontaneous closure. However, it is unlikely that Dextran 40 will act any differently to saline in the epidural space. Any pressure rise within the subarachnoid space would, like saline, be only transient. Histological inspection of the epidural space after administration of Dextran 40,<sup>74</sup> does not demonstrate any inflammatory response that would promote the healing process. The evidence for the administration of epidural Dextran to treat post-dural puncture headache is not proven and the theoretical argument to justify its use is poor.

### *Epidural, intrathecal and parenteral opioids*

A number of authors have advocated the use of epidural,<sup>42</sup> intrathecal<sup>20</sup> or parenteral morphine;<sup>41</sup> the majority of these reports are either case reports or inadequately controlled trials. Some of the studies used epidural morphine after the onset of headache, others used epidural or intrathecal morphine as prophylaxis or in combination with an intrathecal catheter.<sup>20</sup> A controlled trial of intrathecal fentanyl as prophylaxis found no evidence of a reduction in the incidence of post-spinal headache after dural puncture with a 25-gauge spinal needle.<sup>31</sup>

### *Fibrin glue*

Alternative agents to blood, such as fibrinous glue, have been proposed to repair spinal dural perforations.<sup>48</sup> Cranial dural perforations are frequently repaired successfully with it. In the case of lumbar dural perforation, the fibrin glue may be placed blindly or using CT-guided percutaneous injection.<sup>92</sup> There is, however, a risk of the development of aseptic meningitis with this procedure.<sup>111</sup> In addition, manufacturers have recently warned against the application of some types of tissue glue where it may be exposed to nervous tissue.<sup>110</sup>

### *Intrathecal catheters*

After accidental dural perforation with a Tuohy needle, it has been suggested that placement of a spinal catheter through the perforation may provoke an inflammatory reaction that will seal the hole. Evidence to support this claim is conflicting.<sup>30,135</sup> The mean age of the patients in some of the trials has been >50 yr, where the rate of post-dural puncture headache is low. Some trials have used spinal microcatheters, 26G–32G; others have placed 20G epidural catheters through an 18G Tuohy needle.

Histopathological studies in animals and humans with long-term intrathecal catheters confirm the presence of an inflammatory reaction at the site of the catheter. Comparison between the effects of a catheter left *in situ*

for 24 h and for several days or weeks would seem inappropriate.<sup>96</sup> If, after accidental dural puncture with a Tuohy needle, the insertion of an intrathecal catheter reduced the post-dural puncture headache rate, then it would be worth considering. However, neurological complications, such as cauda equina syndrome and infection, should preclude the use of intrathecal catheters.

### *Surgery*

There are case reports of persistent CSF leaks, that are unresponsive to other therapies, being treated successfully by surgical closure of the dural perforation.<sup>58</sup> This is clearly a last resort treatment.

## **Conclusions**

Post-dural puncture headache is a complication that should not to be treated lightly. There is the potential for considerable morbidity,<sup>10</sup> even death.<sup>39,104</sup> In the majority of cases, the problem will resolve spontaneously. In some patients, the headache lasts for months or even years.

Therapies that have been offered have not always arisen through the application of logic or reasoning. Gormley's observation that bloody taps were less likely to give rise to headaches, though probably incorrect,<sup>71</sup> has led to the widespread application of blood patching for the treatment of post-dural puncture headache. The benefit of prophylactic blood patching is not so clear but deserves consideration in those most at risk from a headache, such as the parturient, and after accidental dural perforation with a Tuohy needle. There are occasions when blood patches appear to be ineffective in treating the headache. It is wise to consider other causes of the headache before applying alternative therapeutic options. Surgical closure of the dural tear is an option of last resort.

## **References**

- 1 Abouleish E, Vega S, Blendinger I, Tio TO. Long-term follow-up of epidural blood patch. *Anesth Analg* 1975; **54**: 459–63
- 2 Abouleish E, Wadhwa RK, de la Vega S, Tan RN Jr, Lim Uy N. Regional analgesia following epidural blood patch. *Anesth Analg* 1975; **54**: 634–6
- 3 Alfery DD, Marsh ML, Shapiro HM. Post-spinal headache or intracranial tumor after obstetric anesthesia. *Anesthesiology* 1979; **51**: 92–4
- 4 Barker P. Headache after dural puncture. *Anaesthesia* 1989; **44**: 696–7
- 5 Bart AJ, Wheeler AS. Comparison of epidural saline placement and epidural blood placement in the treatment of post-lumbar-puncture headache. *Anesthesiology* 1978; **48**: 221–3
- 6 Baysinger CL, Menk EJ, Harte E, Middaugh R. The successful treatment of dural puncture headache after failed epidural blood patch. *Anesth Analg* 1986; **65**: 1242–4
- 7 Beards SC, Jackson A, Griffiths AG, Horsman EL. Magnetic resonance imaging of extradural blood patches: appearances from 30 min to 18 h. *Br J Anaesth* 1993; **71**: 182–8

- 8 Berger CW, Crosby ET, Grodecki W. North American survey of the management of dural puncture occurring during labour epidural analgesia. *Can J Anaesth* 1998; **45**: 110–14
- 9 Bolton VE, Leicht CH, Scanlon TS. Postpartum seizure after epidural blood patch and intravenous caffeine sodium benzoate. *Anesthesiology* 1989; **70**: 146–9
- 10 Borum SE, Naul LG, McLeskey CH. Postpartum dural venous sinus thrombosis after postdural puncture headache and epidural blood patch. *Anesthesiology* 1997; **86**: 487–90
- 11 Bucklin BA, Tinker JH, Smith CV. Clinical dilemma: a patient with postdural puncture headache and acute leukemia. *Anesth Analg* 1999; **88**: 166–7
- 12 Camann WR, Murray RS, Mushlin PS, Lambert DH. Effects of oral caffeine on postdural puncture headache. A double-blind, placebo-controlled trial. *Anesth Analg* 1990; **70**: 181–4
- 13 Campbell DC, Douglas MJ, Pavy TJ, Merrick P, Flanagan ML, McMorland GH. Comparison of the 25-gauge Whitacre with the 24-gauge Sprotte spinal needle for elective Caesarean section: cost implications. *Can J Anaesth* 1993; **40**: 1131–5
- 14 Carbajal R, Simon N, Olivier-Martin M. Post-lumbar puncture headache in children. Treatment with epidural autologous blood (blood patch). *Arch Pediatr* 1998; **5**: 149–52
- 15 Carp H, Singh PJ, Vadhera R, Jayaram A. Effects of the serotonin-receptor agonist sumatriptan on postdural puncture headache: report of six cases. *Anesth Analg* 1994; **79**: 180–2
- 16 Carrero EJ, Agusti M, Fabregas N, Valdeoriola F, Fernandez C. Unilateral trigeminal and facial nerve palsies associated with epidural analgesia in labour. *Can J Anaesth* 1998; **45**: 893–7
- 17 Carrie LE. Whitacre and pencil-point needles: some points to consider. *Anaesthesia* 1990; **45**: 1097–8
- 18 Carson D, Serpell M. Choosing the best needle for diagnostic lumbar puncture. *Neurology* 1996; **47**: 33–7
- 19 Clark CJ, Whitwell J. Intraocular haemorrhage after epidural injection. *Br Med J* 1961; **1**: 1612–13
- 20 Cohen S, Amar D, Pantuck EJ, Singer N, Divon M. Decreased incidence of headache after accidental dural puncture in caesarean delivery patients receiving continuous postoperative intrathecal analgesia. *Acta Anaesthesiol Scand* 1994; **38**: 716–18
- 21 Collier BB. Treatment for post-dural puncture headache. *Br J Anaesth* 1994; **72**: 366–7
- 22 Colonna-Romano P, Shapiro BE. Unintentional dural puncture and prophylactic epidural blood patch in obstetrics. *Anesth Analg* 1989; **69**: 522–3
- 23 Connelly NR, Parker RK, Rahimi A, Gibson CS. Sumatriptan in patients with postdural puncture headache. *Headache* 2000; **40**: 316–19
- 24 Cook MA, Watkins-Pitchford JM. Epidural blood patch: a rapid coagulation response. *Anesth Analg* 1990; **70**: 567–8
- 25 Corbey MP, Bach AB, Lech K, Frorup AM. Grading of severity of postdural puncture headache after 27-gauge Quincke and Whitacre needles. *Acta Anaesthesiol Scand* 1997; **41**: 779–84
- 26 Costigan SN, Sprigge JS. Dural puncture: the patients' perspective. A patient survey of cases at a DGH maternity unit 1983–1993. *Acta Anaesthesiol Scand* 1996; **40**: 710–14
- 27 Crawford JS. Experiences with epidural blood patch. *Anaesthesia* 1980; **35**: 513–15
- 28 Crawford JS. The prevention of headache consequent upon dural puncture. *Br J Anaesth* 1972; **44**: 598–600
- 29 Cruickshank RH, Hopkinson JM. Fluid flow through dural puncture sites. An *in vitro* comparison of needle point types. *Anaesthesia* 1989; **44**: 415–18
- 30 Denny N, Masters R, Pearson D, Read J, Sihota M, Selander D. Postdural puncture headache after continuous spinal anaesthesia. *Anesth Analg* 1987; **66**: 791–4
- 31 Devcic A, Sprung J, Patel S, Kettler R, Maitra-D'Cruze A. PDPH in obstetric anaesthesia: comparison of 24-gauge Sprotte and 25-gauge Quincke needles and effect of subarachnoid administration of fentanyl. *Reg Anesth* 1993; **18**: 222–5
- 32 Diemunsch P, Balabaud VP, Petiau C, et al. Bilateral subdural hematoma following epidural anaesthesia. *Can J Anaesth* 1998; **45**: 328–31
- 33 DiGiovanni AJ, Dunbar BS. Epidural injections of autologous blood for postlumbar-puncture headache. *Anesth Analg* 1970; **49**: 268–71
- 34 DiGiovanni AJ, Galbert MW, Wahle WM. Epidural injection of autologous blood for postlumbar-puncture headache. II. Additional clinical experiences and laboratory investigation. *Anesth Analg* 1972; **51**: 226–32
- 35 Dittmann M, Schaefer HG, Renkl F, Greve I. Spinal anaesthesia with 29 gauge Quincke point needles and post-dural puncture headache in 2378 patients. *Acta Anaesthesiol Scand* 1994; **38**: 691–3
- 36 Dittmann M, Schafer HG, Ulrich J, Bond-Taylor W. Anatomical re-evaluation of lumbar dura mater with regard to postspinal headache. Effect of dural puncture. *Anaesthesia* 1988; **43**: 635–7
- 37 Dunbar SA, Katz NP. Post-dural puncture thoracic pain without headache: relief with epidural blood patch. *Can J Anaesth* 1995; **42**: 221–3
- 38 Dutton DA. A 'postspinal headache' associated with incidental intracranial pathology. *Anaesthesia* 1991; **46**: 1044–6
- 39 Eerola M, Kaukinen L, Kaukinen S. Fatal brain lesion following spinal anaesthesia. Report of a case. *Acta Anaesthesiol Scand* 1981; **25**: 115–16
- 40 Eggert SM, Eggers KA. Subarachnoid haemorrhage following spinal anaesthesia in an obstetric patient. *Br J Anaesth* 2001; **86**: 442–4
- 41 Eldor J. Opiate treatment of post-dural puncture headache. *Acta Anaesthesiol Scand* 1995; **39**: 1140
- 42 Eldor J, Guedj P, Cotev S. Epidural morphine injections for the treatment of postspinal headache. *Can J Anaesth* 1990; **37**: 710–11
- 43 Fink BR, Walker S. Orientation of fibers in human dorsal lumbar dura mater in relation to lumbar puncture. *Anesth Analg* 1989; **69**: 768–72
- 44 Flaatten H, Rodt S, Rosland J, Vamnes J. Postoperative headache in young patients after spinal anaesthesia. *Anaesthesia* 1987; **42**: 202–5
- 45 Flaatten H, Rodt SA, Vamnes J, Rosland J, Wisborg T, Koller ME. Postdural puncture headache. A comparison between 26- and 29-gauge needles in young patients. *Anaesthesia* 1989; **44**: 147–9
- 46 Frumin MJ. Spinal anaesthesia using a 32-gauge needle. *Anesthesiology* 1969; **30**: 599–60
- 47 Geurts JW, Haanschoten MC, van Wijk RM, Kraak H, Besse TC. Post-dural puncture headache in young patients. A comparative study between the use of 0.52 mm (25-gauge) and 0.33 mm (29-gauge) spinal needles. *Acta Anaesthesiol Scand* 1990; **34**: 350–3
- 48 Gil F, Garcia-Aguado R, Barcia JA, et al. The effect of fibrin glue patch in an *in vitro* model of postdural puncture leakage. *Anesth Analg* 1998; **87**: 1125–8
- 49 Gogarten W, Van Aken H. A century of regional analgesia in obstetrics. *Anesth Analg* 2000; **91**: 773–5
- 50 Gorelick PB, Zych D. James Leonard Corning and the early history of spinal puncture. *Neurology* 1987; **37**: 672–4
- 51 Gormley JB. Treatment of post-spinal headache. *Anesthesiology* 1960; **21**: 565–6
- 52 Grant R, Condon B, Hart I, Teasdale GM. Changes in intracranial CSF volume after lumbar puncture and their relationship to post-LP headache. *J Neurol Neurosurg Psychiatry* 1991; **54**: 440–2

- 53 Greene HM. Lumbar puncture and the prevention of post puncture headache. *JAMA* 1926; **86**: 391–2
- 54 Gutterman P, Bezier HS. Prophylaxis of postmyelogram headaches. *J Neurosurg* 1978; **49**: 869–71
- 55 Handler CE, Smith FR, Perkin GD, Rose FC. Posture and lumbar puncture headache: a controlled trial in 50 patients. *J R Soc Med* 1982; **75**: 404–7
- 56 Hannerz J, Ericson K, Bro Skejo HP. MR imaging with gadolinium in patients with and without post-lumbar puncture headache. *Acta Radiol* 1999; **40**: 135–41
- 57 Hansen PE, Hansen JH. DDAVP, a synthetic analogue of vasopressin, in prevention of headache after lumbar puncture and lumbar pneumoencephalography. *Acta Neurol Scand* 1979; **60**: 183–8
- 58 Harrington H, Tyler HR, Welch K. Surgical treatment of post-lumbar puncture dural CSF leak causing chronic headache. Case report. *J Neurosurg* 1982; **57**: 703–7
- 59 Hart JR, Whitacre RG. Pencil point needle in the prevention of post-spinal headache. *JAMA* 1951; **147**: 657–8
- 60 Hebl JR, Horlocker TT, Chantigian RC, Schroeder DR. Epidural anaesthesia and analgesia are not impaired after dural puncture with or without epidural blood patch. *Anesth Analg* 1999; **89**: 390–4
- 61 Hodgson C, Roitberg-Henry A. The use of sumatriptan in the treatment of postdural puncture headache. *Anaesthesia* 1997; **52**: 808
- 62 Holder HG. Reactions after spinal anaesthesia. *JAMA* 1944; **124**: 56–7
- 63 Holst D, Mollmann M, Ebel C, Hausman R, Wendt M. *In vitro* investigation of cerebrospinal fluid leakage after dural puncture with various spinal needles. *Anesth Analg* 1998; **87**: 1331–5
- 64 Hoskin MF. Spinal anaesthesia—the current trend towards narrow gauge atraumatic (pencil point) needles. Case reports and review. *Anaesth Intens Care* 1998; **26**: 96–106
- 65 Jack TM. Post-partum intracranial subdural haematoma: a possible complication of epidural analgesia. *Anaesthesia* 1979; **34**: 176–80
- 66 Jarvis AP, Greenawalt JW, Fagraeus L. Intravenous caffeine for postdural puncture headache. *Anesth Analg* 1986; **65**: 316–17
- 67 Jokinen MJ, Pitkanen MT, Lehtonen E, Rosenberg PH. Deformed spinal needle tips and associated dural perforations examined by scanning electron microscopy. *Acta Anaesthesiol Scand* 1996; **40**: 687–90
- 68 Jones RJ. The role of recumbency in the prevention and treatment of postspinal headache. *Anesth Analg* 1974; **53**: 788–95
- 69 Kang SB, Goodnough DE, Lee YK, et al. Comparison of 26- and 27-G needles for spinal anesthesia for ambulatory surgery patients. *Anesthesiology* 1992; **76**: 734–8
- 70 Keener EB. An experimental study of reactions of the dura mater to wounding and loss of substance. *J Neurosurg* 1959; **16**: 424–47
- 71 Khan KJ, Stride PC, Cooper GM. Does a bloody tap prevent postdural puncture headache? *Anaesthesia* 1993; **48**: 628–9
- 72 Klepstad P. Relief of postural post-dural puncture headache by an epidural blood patch 12 months after dural puncture. *Acta Anaesthesiol Scand* 1999; **43**: 964–6
- 73 Kokki H, Heikkinen M, Turunen M, Vanamo K, Hendolin H. Needle design does not affect the success rate of spinal anaesthesia or the incidence of postpuncture complications in children. *Acta Anaesthesiol Scand* 2000; **44**: 210–13
- 74 Lander CJ, Korbon GA. Histopathologic consequences of epidural blood patch and epidurally administered Dextran 40. *Anesthesiology* 1988; **69**: A410
- 75 Lee JA. Arthur Edward James Barker 1850–1916. British pioneer of regional analgesia. *Anaesthesia* 1979; **34**: 885–91
- 76 Leibold RA, Yealy DM, Coppola M, Cantees KK. Post-dural-puncture headache: characteristics, management, and prevention. *Ann Emerg Med* 1993; **22**: 1863–70
- 77 Lennon M, Seigne P, Cunningham AJ. Pituitary apoplexy after spinal anaesthesia. *Br J Anaesth* 1998; **81**: 616–18
- 78 Lybecker H, Andersen T. Repetitive hearing loss following dural puncture treated with autologous epidural blood patch. *Acta Anaesthesiol Scand* 1995; **39**: 987–9
- 79 Lybecker H, Moller JT, May O, Nielsen HK. Incidence and prediction of postdural puncture headache. A prospective study of 1021 spinal anaesthetics. *Anesth Analg* 1990; **70**: 389–94
- 80 MacArthur C, Lewis M, Knox EG. Accidental dural puncture in obstetric patients and long term symptoms. *Br Med J* 1992; **304**: 1279–82
- 81 Martin R, Jourdain S, Clairoux M, Tetrault JP. Duration of decubitus position after epidural blood patch. *Can J Anaesth* 1994; **41**: 23–5
- 82 Marx GF. The first spinal anesthesia. Who deserves the laurels? *Reg Anesth* 1994; **19**: 429–30
- 83 McGrady EM, Freshwater JV. 'Spinal' headache—with no headache. *Anaesthesia* 1991; **46**: 794
- 84 Moir DD. Recent advances in pain relief in childbirth. II: regional anaesthesia. *Br J Anaesth* 1971; **43**: 849–57
- 85 Mokri B, Parisi JE, Scheithauer BW, Piepgras DG, Miller GM. Meningeal biopsy in intracranial hypotension: meningeal enhancement on MRI. *Neurology* 1995; **45**: 1801–7
- 86 Mosavy SH, Shafei M. Prevention of headache consequent upon dural puncture in obstetric patient. *Anaesthesia* 1975; **30**: 807–9
- 87 Norris MC, Leighton BL, DeSimone CA. Needle bevel direction and headache after inadvertent dural puncture. *Anesthesiology* 1989; **70**: 729–31
- 88 Okell RW, Sprigge JS. Unintentional dural puncture. A survey of recognition and management. *Anaesthesia* 1987; **42**: 1110–13
- 89 Ostheimer GW, Palahniuk RJ, Shnider SM. Epidural blood patch for post-lumbar-puncture headache. *Anesthesiology* 1974; **41**: 307–8
- 90 Parker RK, White PF. A microscopic analysis of cut-bevel versus pencil-point spinal needles. *Anesth Analg* 1997; **85**: 1101–4
- 91 Parris WC. Use of epidural blood patch in treating chronic headache: report of six cases. *Can J Anaesth* 1987; **34**: 403–6
- 92 Patel MR, Caruso PA, Yousuf N, Rachlin J. CT-guided percutaneous fibrin glue therapy of cerebrospinal fluid leaks in the spine after surgery. *Am J Roentgenol* 2000; **175**: 443–6
- 93 Patin DJ, Eckstein EC, Harum K, Pallares VS. Anatomic and biomechanical properties of human lumbar dura mater. *Anesth Analg* 1993; **76**: 535–40
- 94 Pavlin DJ, McDonald JS, Child B, Rusch V. Acute subdural hematoma—an unusual sequela to lumbar puncture. *Anesthesiology* 1979; **51**: 338–40
- 95 Pearce JM. Walter Essex Wynter, Quincke, and lumbar puncture. *J Neurol Neurosurg Psychiatry* 1994; **57**: 179
- 96 Peyton PJ. Complications of continuous spinal anaesthesia. *Anaesth Intens Care* 1992; **20**: 417–25
- 97 Pleasure SJ, Abosch A, Friedman J, et al. Spontaneous intracranial hypotension resulting in stupor caused by diencephalic compression. *Neurology* 1998; **50**: 1854–7
- 98 Quaynor H, Tronstad A, Heldaas O. Frequency and severity of headache after lumbar myelography using a 25-gauge pencil-point (Whitacre) spinal needle. *Neuroradiology* 1995; **37**: 553–6
- 99 Rainbird A, Pfitzner J. Restricted spread of analgesia following epidural blood patch. *Anaesthesia* 1983; **38**: 481–4
- 100 Rando TA, Fishman RA. Spontaneous intracranial hypotension: report of two cases and review of the literature. *Neurology* 1992; **42**: 481–7

- 101 Ready LB, Cuplin S, Haschke RH, Nessly M. Spinal needle determinants of rate of transdural fluid leak. *Anesth Analg* 1989; **69**: 457–60
- 102 Reina MA, de Leon-Casasola OA, Lopez A, De Andres J, Martin S, Mora M. An *in vitro* study of dural lesions produced by 25-gauge Quincke and Whitacre needles evaluated by scanning electron microscopy. *Reg Anesth Pain Med* 2000; **25**: 393–402
- 103 Reynolds AF Jr, Hameroff SR, Blitt CD, Roberts WL. Spinal subdural epiarachnoid hematoma: a complication of a novel epidural blood patch technique. *Anesth Analg* 1980; **59**: 702–3
- 104 Reynolds F. Dural puncture and headache. *Br Med J* 1993; **306**: 874–6
- 105 Reynolds F, O'Sullivan G. Lumbar puncture and headache. 'Atraumatic needle' is a better term than 'blunt needle'. *Br Med J* 1998; **316**: 1018
- 106 Roberts SP, Petts HV. Meningitis after obstetric spinal anaesthesia. *Anaesthesia* 1990; **45**: 376–7
- 107 Ross AWW, Greenhalgh C, McGlade DP, et al. The Sprotte needle and post-dural puncture headache following caesarean section. *Anaesth Intens Care* 1993; **21**: 280–3
- 108 Schabel JE, Wang ED, Glass PS. Arm pain as an unusual presentation of postdural puncture intracranial hypotension. *Anesth Analg* 2000; **91**: 910–12
- 109 Scher CS, Amar D, Wollner N. Extradural blood patch for post-lumbar puncture headaches in cancer patients. *Can J Anaesth* 1992; **39**: 203–4
- 110 Schlag MG, Hopf R, Redl H. Convulsive seizures following subdural application of fibrin sealant containing tranexamic acid in a rat model. *Neurosurgery* 2000; **47**: 1463–7
- 111 Schlenker M, Ringelstein EB. Epidural fibrin clot for the prevention of post-lumbar puncture headache: a new method with risks. *J Neurol Neurosurg Psychiatry* 1987; **50**: 1715
- 112 Sears DH, Leeman MI, Jassy LJ, O'Donnell LA, Allen SG, Reisner LS. The frequency of postdural puncture headache in obstetric patients: a prospective study comparing the 24-gauge versus the 22-gauge Sprotte needle. *J Clin Anesth* 1994; **6**: 42–6
- 113 Sechzer PH. Post-spinal anesthesia headache treated with caffeine. Evaluation with demand method. Part 2. *Curr Ther Res* 1979; **26**: 440–8
- 114 Sechzer PH, Abel L. Post-spinal anesthesia headache treated with caffeine. Evaluation with demand method. Part 1. *Curr Ther Res* 1978; **24**: 307–12
- 115 Sharma SK, Gambling DR, Joshi GP, Sidawi JE, Herrera ER. Comparison of 26-gauge Atraucan and 25-gauge Whitacre needles: insertion characteristics and complications. *Can J Anaesth* 1995; **42**: 706–10
- 116 Shenkin HA, Novack P. Clinical implications of recent studies on cerebral circulation in man. *Arch Neurol Psychiatry* 1954; **71**: 148–59
- 117 Souron V, Hamza J. Treatment of postdural puncture headaches with colloid solutions: an alternative to epidural blood patch. *Anesth Analg* 1999; **89**: 1333–4
- 118 Spriggs DA, Burn DJ, French J, Cartlidge NE, Bates D. Is bed rest useful after diagnostic lumbar puncture? *Postgrad Med J* 1992; **68**: 581–3
- 119 Sprotte G, Schedel R, Pajunk H. An 'atraumatic' universal needle for single-shot regional anesthesia: clinical results and a 6 year trial in over 30 000 regional anesthetics. *Reg Anaesth* 1987; **10**: 104–8
- 120 Stein G, Morton J, Marsh A, et al. Headaches after childbirth. *Acta Neurol Scand* 1984; **69**: 74–9
- 121 Stevens RA, Jorgensen N. Successful treatment of dural puncture headache with epidural saline infusion after failure of epidural blood patch. *Acta Anaesthesiol Scand* 1988; **32**: 429–31
- 122 Stocks GM, Wooller DJ, Young JM, Fernando R. Postpartum headache after epidural blood patch: investigation and diagnosis. *Br J Anaesth* 2000; **84**: 407–10
- 123 Susman JL. Sumatriptan: a new serotonin agonist for the treatment of migraine headache. *Am Fam Physician* 1993; **47**: 645–7
- 124 Szeinfeld M, Ihmeidan IH, Moser MM, Machado R, Klose KJ, Serafini AN. Epidural blood patch: evaluation of the volume and spread of blood injected into the epidural space. *Anesthesiology* 1986; **64**: 820–2
- 125 Thomas SR, Jamieson DR, Muir KW. Randomised controlled trial of atraumatic versus standard needles for diagnostic lumbar puncture. *Br Med J* 2000; **321**: 986–90
- 126 Tom DJ, Gulevich SJ, Shapiro HM, Heaton RK, Grant I. Epidural blood patch in the HIV-positive patient. Review of clinical experience. San Diego HIV Neurobehavioral Research Center. *Anesthesiology* 1992; **76**: 943–7
- 127 Tourtellotte WW, Haerer AF, Heller GL, Somers JE. Lumbar puncture headaches. Springfield, Illinois: Charles C. Thomas, 1964
- 128 Tourtellotte WW, Henderson WG, Tucker RP, Gilland O, Walker JE, Kokman E. A randomized, double-blind clinical trial comparing the 22 versus 26 gauge needle in the production of the post-lumbar puncture syndrome in normal individuals. *Headache* 1972; **12**: 73–8
- 129 Usubiaga JE, Usubiaga LE, Brea LM, Goyena R. Effect of saline injections on epidural and subarachnoid space pressure and relation to postspinal anesthesia headache. *Anesth Analg* 1967; **46**: 293–6
- 130 Vakharia SB, Thomas PS, Rosenbaum AE, Wasenko JJ, Fellows DG. Magnetic resonance imaging of cerebrospinal fluid leak and tamponade effect of blood patch in postdural puncture headache. *Anesth Analg* 1997; **84**: 585–90
- 131 Vallejo MC, Mandell GL, Sabo DP, Ramanathan S. Postdural puncture headache: a randomized comparison of five spinal needles in obstetric patients. *Anesth Analg* 2000; **91**: 916–20
- 132 Vandam LD, Dripps RD. Long-term follow up of patients who received 10 098 spinal anesthetics. *JAMA* 1956; **161**: 586–91
- 133 Weir EC. The sharp end of the dural puncture. *Br Med J* 2000; **320**: 127–8
- 134 Wilder-Smith E, Kothbauer-Margreiter I, Lammler B, Sturzenegger M, Ozdoba C, Hauser SP. Dural puncture and activated protein C resistance: risk factors for cerebral venous sinus thrombosis. *J Neurol Neurosurg Psychiatry* 1997; **63**: 351–6
- 135 Wilhelm S, Standl T, Burmeister M, Kessler G, Schulte am Esch J. Comparison of continuous spinal with combined spinal-epidural anesthesia using plain bupivacaine 0.5% in trauma patients. *Anesth Analg* 1997; **85**: 69–74
- 136 Woodward WM, Levy DM, Dixon AM. Exacerbation of post-dural puncture headache after epidural blood patch. *Can J Anaesth* 1994; **41**: 628–31
- 137 Wulf HF. The centennial of spinal anesthesia. *Anesthesiology* 1998; **89**: 500–6