

# Metaplastic Carcinoma of the Breast

Elizabeth McKinnon, MD; Philip Xiao, MD

• **Metaplastic carcinoma of the breast is a rare but aggressive type of breast cancer that has been recognized as a unique pathologic entity by the World Health Organization. Morphologically, it is characterized by the differentiation of neoplastic epithelium into squamous cells and/or mesenchymal-looking elements (squamous cells, spindle cells, cartilage or bone, etc). It shares many similarities with invasive ductal carcinoma and benign lesions on mammography, which further complicates the diagnosis. Treatment for metaplastic breast carcinoma is relatively unknown because of the rarity of the disease, but studies suggest that removal of the tumor and adjuvant radiation therapy has the greatest benefit.**

(*Arch Pathol Lab Med.* 2015;139:819–822; doi: 10.5858/arpa.2013-0358-RS)

Metaplastic carcinoma of the breast (MCB) was first described in 1973 by Huvos et al<sup>1</sup> and was defined as a mammary carcinoma with mixed epithelial and sarcomatoid components. The histologic classification of metaplastic carcinoma is primarily based on the morphologic findings of tumor cell types: purely epithelial (squamous, adenosquamous and spindle cell carcinomas) or mixed epithelial and mesenchymal (carcinoma with chondroid/osseous metaplasia and carcinosarcoma) components.<sup>2</sup> Recently, there has been an increase in diagnoses, most likely due to the increased cognizance of MCB by pathologists.<sup>3,4</sup> Today, MCB represents 0.25% to 1% of all breast cancers diagnosed annually.<sup>5,6</sup> The prognosis and treatment of MCB is overall unknown, and compared with patients with invasive ductal carcinoma (IDC), patients with MCB have larger, higher-grade tumors with less hormone receptor positivity and less involvement of the regional lymph nodes.<sup>7,8</sup> Additionally, compared with patients with IDC, patients with MCB have worse outcomes in 5-year survival rates, ranging from 49% to 68%.<sup>6,7</sup> In this article, we will discuss clinicopathologic presentation, pathologic features, differential diagnosis, treatment options, and prognosis of this rare type of breast cancer.

Accepted for publication May 21, 2014.

From the Department of Pathology, The Brooklyn Hospital Center/NewYork–Presbyterian Healthcare System, Brooklyn, New York. Dr McKinnon is currently located at the Department of Pathology, Duke University Medical Center, Durham, North Carolina.

The authors have no relevant financial interest in the products or companies described in this article.

Reprints: Philip Xiao, MD, Department of Pathology, The Brooklyn Hospital Center/NewYork–Presbyterian Healthcare System, 121 Dekalb Ave, Brooklyn, NY 11201 (e-mail: philipqxiao@yahoo.com).

## CLINICOPATHOLOGIC PRESENTATION

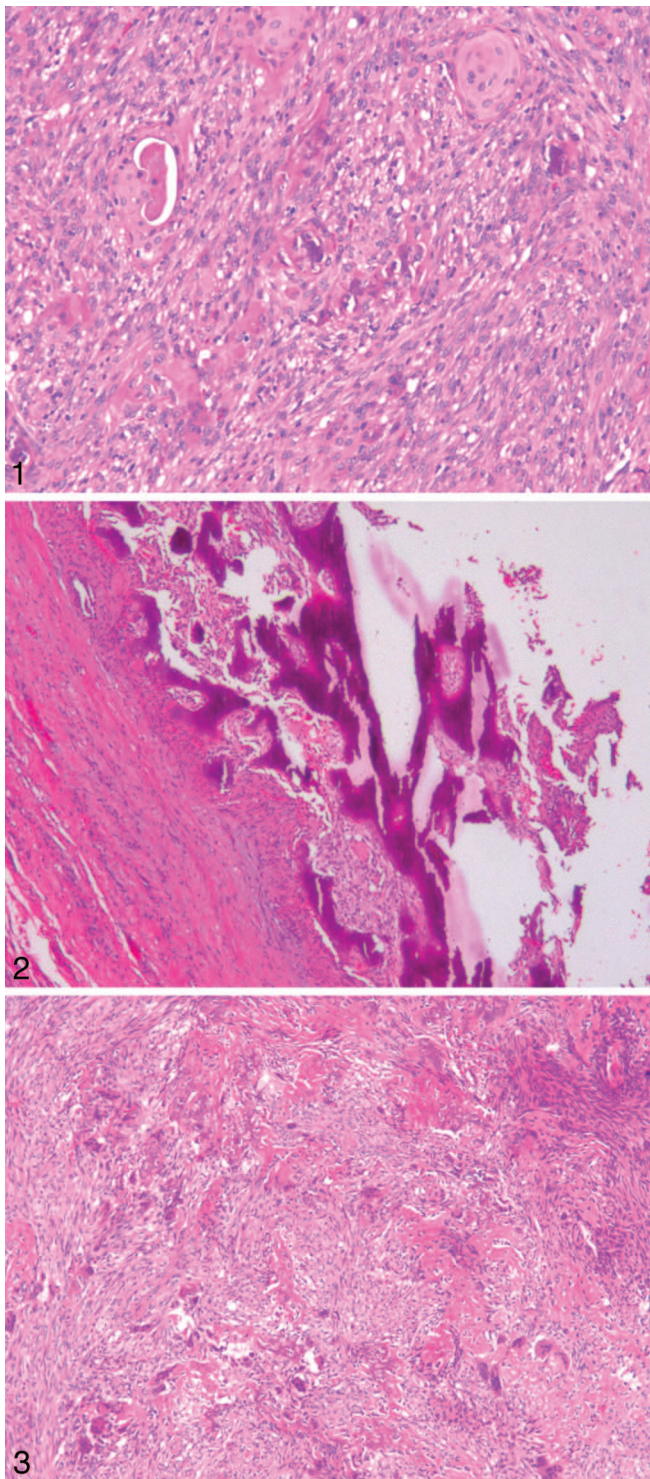
Metaplastic carcinoma of the breast often presents as a palpable breast mass in women older than 50 years.<sup>1,9</sup> Mammographic, sonographic, and magnetic resonance imaging characteristics of MCB can be similar to IDC and benign lesions. Imaging can show an irregular or circumscribed palpable mass with spiculated portion on mammography and solid irregular mass or mixed cystic mass on ultrasound. Previous literature suggests that MCB can appear like benign masses with circumscribed, round, or oval masses on mammogram and lobular, circumscribed, hypoechoic solid mass with posterior acoustic enhancement on ultrasound, or with T2 hyperintensity on magnetic resonance imaging.<sup>7</sup> Additionally, lesions are often not calcified.<sup>10</sup>

Metaplastic carcinomas of the breast are characterized by large tumor size and rapid growth, and they are usually estrogen receptor, progesterone receptor, and HER2/neu negative. Axillary lymph node involvement varies in range from about 8% to 40% of cases.<sup>1,10</sup> There is a high potential for metastatic spread to the lung and bone tissue via the vasculature rather than by way of the lymphatics.<sup>11</sup> There is a noteworthy increased risk of tumor recurrence and a worse prognosis with MCB compared with invasive lobular carcinoma and IDC. Predictors associated with worse prognosis of MCB include age younger than 39 years at presentation, tumor invasion of the skin, and squamous cell carcinoma spread to the lymph nodes. Some studies suggest that the subtype of MCB does not affect outcome of the disease.<sup>11</sup> Other studies conclude that fibromatosis-like spindle cell tumors have a more favorable outcome, and that tumors with predominantly sarcomatous morphology have a low likelihood of axillary metastasis.<sup>12,13</sup>

## PATHOLOGIC FEATURES

Metaplastic carcinoma of the breast is composed of a mixed group of malignant neoplasms containing both glandular and nonglandular patterns with epithelial and/or mesenchymal components.<sup>14</sup> The World Health Organization classifies MCB into an epithelial type and a mixed type with further classification into 5 additional subtypes.<sup>11</sup> The renowned Wargotz and Norris classification, as described in their 1989–1990 studies,<sup>8</sup> differentiates MCB into 5 subtypes: spindle cell, squamous cell, matrix-producing, carcinosarcoma, and MCB with osteoclastic giant cells.

The spindle cell subtype as described by Wargotz et al<sup>15</sup> is the most common. It predominantly demonstrates poorly cohesive sheets of atypical spindle cells (Figure 1). It often appears like low-grade sarcoma or the formation of granulation tissue.<sup>13</sup> The squamous cell subtype demon-



**Figure 1.** Microscopic examination revealed tumor composed of malignant spindle cells and squamous epithelial cells (hematoxylin-eosin, original magnification  $\times 10$ ).

**Figure 2.** Microscopic examination revealed tumor cells in a background of osseous stromal matrix with spindle component (hematoxylin-eosin, original magnification  $\times 10$ ).

**Figure 3.** Microscopic examination revealed tumor cells showing osteoclastic giant cell features (hematoxylin-eosin, original magnification  $\times 10$ ).

strates infiltrating squamous cell carcinoma with eosinophilic cytoplasm and polygonal cells.<sup>16</sup> Metaplastic carcinoma of the breast can be transformed from low-grade adenosquamous carcinoma to osteosarcomatoid and spindle cell morphology.<sup>17</sup> The matrix-producing subtype contains frank carcinoma with transformation to cartilaginous matrix or osseous stromal matrix (Figure 2) with no spindle component.<sup>18</sup> The carcinosarcoma subtype contains both malignant epithelium and neoplastic stromal components.<sup>18</sup> Lastly, the MCB with osteoclastic giant cells subtype displays intraductal or infiltrating carcinoma, adjoining or mixed with either spindle cell or sarcomatous stroma, and it contains osteoclastic giant cells (Figure 3).<sup>19,20</sup>

The molecular pathogenesis of MCB should be noted when discussing the complexities of the tumor. Currently, there is no specific, pathognomonic mutation for MCB, and it is unknown if somatic mutations cause the differentiation that allows for MCB subtypes.<sup>21</sup> However, noted mutations have been well publicized, including mutations in the *TP53* gene and the phosphatidylinositol-4,5-bisphosphate 3-kinase, catalytic subunit alpha (*PIK3CA*) gene. *PIK3CA* mutations are more likely to be found in hormone-receptor-positive and HER2/neu-positive breast cancers, but they are more common in MCB than in other triple-negative breast cancers.<sup>21</sup> Metaplastic carcinomas of the breast similarly show positivity to CD44 and negativity for CD24, which suggests that the tumor cells act like stem cells.<sup>22</sup> Other noteworthy genetic abnormalities, such as losses of *PTEN* and cyclin-dependent kinase inhibitor 2A, have been found repeatedly in MCB.<sup>21</sup> The overexpression of the epidermal growth factor receptor gene (*EGFR*) has been reported in MCBs with squamous metaplasia and spindle cell morphology.<sup>23</sup> Moreover, MCBs are part of the receptor-negative subgroups characterized by low expression of GATA3-regulated genes and the genes that are responsible for cell-cell adhesion as well as epithelial-to-mesenchymal transition and stem cell-like features. This suggests that MCB arises from a breast epithelial precursor that is relatively chemoresistant. This not only adds to the uniqueness of these tumors but also suggests the need for novel treatments.<sup>23</sup>

### DIFFERENTIAL DIAGNOSIS

MCB is a rare type of breast cancer that contains different portions of carcinoma and sarcomatoid components, but it differs from typical adenocarcinoma in several clinicopathologic aspects.<sup>24</sup> In the literature, MCB is often contrasted with the more common breast tumor IDC. Both have similar features on mammogram, but they differ in many characteristics. In general, MCB is considered more aggressive and as having a lower incidence of axillary node involvement with a generally larger tumor size. The incidence of triple-negative breast cancer is remarkably higher in MCB than in IDC. Previous studies suggest that the triple negativity feature of MCB is associated with its worse patient outcomes.<sup>25</sup> A much larger percentage of MCB cases as opposed to IDC cases were stage IV at patient presentation. This result may suggest that MCB is much more aggressive than other types of breast cancer.<sup>26</sup>

Other differential diagnoses in terms of the histopathologic features of MCB include myoepithelial carcinoma of the breast, myofibroblastic tumors, phyllodes tumors, primary breast sarcoma, nodular fasciitis, fibromatosis, pleomorphic adenoma, and adenomyoepithelioma.

Both MCB and myoepithelial carcinoma can contain infiltrating spindle cells and variable cell types and can demonstrate triple negativity. Both tumors may also have ducts with prominent myoepithelial cells at the periphery and show diffuse S100 positivity. Because MCB and myoepithelial carcinoma are so histologically similar and behave similarly, it is very difficult to differentiate the two.<sup>27</sup>

Phyllodes tumors are mostly benign breast lesions that resemble fibroadenomas, but additionally there are hypercellular mesenchymal elements arranged in a pattern resembling a leaf. These tumors may also contain spindle cells and share MCB's positivity of vimentin and actin (in nonsquamous types only). The spindle component of MCB may be positive for high-molecular-weight keratin and p63, but phyllodes tumors are negative for these components. Additionally, MCB contains malignant epithelium with squamous differentiation, and phyllodes tumors contain benign epithelium with squamous metaplasia in the epithelial component only and not in the stromal component.

Primary breast sarcoma is an equally rare malignancy when compared with MCB. It has similarity on mammogram, but in contrast, sarcoma will not show epithelial components or display keratin positivity.<sup>8</sup> Additionally, primary breast sarcoma should be diagnosed only after thorough sectioning and with negative stains for p63, broad-spectrum keratin, and high-molecular-weight keratin. This may rule out MCB, which does show keratin and p63 positivity.

Nodular fasciitis is a proliferative lesion containing fibroblasts and myofibroblasts in myxoid stroma. It is a rapidly growing neoplasm that is well circumscribed and contains prominent vasculature. It is very rare in the breast and although it can be a differential diagnosis for MCB, it should be diagnosed only after thorough sectioning and with negative keratin stains, including high-molecular-weight keratin. As mentioned previously, MCB is primarily a breast tumor that shows positivity with keratin stains. Nodular fasciitis shows no keratin positivity.

Fibromatosis is a general term for a proliferation of benign-appearing fibroblasts and myofibroblasts with infiltrative growth but no metastasis. Much like nodular fasciitis, it is locally aggressive but also very rare in the breast, and it should be diagnosed only after thorough sectioning and with negative keratin stains, including high-molecular-weight keratin.

Pleomorphic adenoma is the most common type of salivary gland tumor. Much like MCB, it is mixed in tissue origin and composed of mesenchymal and epithelial cells, and it also shows keratin positivity. Pleomorphic adenoma is very rare in the breast, it does not have infiltrating margins, and the epithelial component is not malignant.

Adenomyoepithelioma contains a histologically bland epithelial component and stroma. The stroma also shows myoepithelial differentiation only. In contrast, the glandular component of MCB, if present, is histologically malignant, except in low-grade spindle cell metaplastic carcinoma. It may also have squamous differentiation. The stromal component may be bland or histologically malignant, and may resemble a variety of sarcomas or low-grade fibrous proliferation.

## TREATMENT AND PROGNOSIS

The optimal treatments for MCB are relatively unknown, but current surgical therapy practices are comparable with

those of IDC.<sup>8</sup> Surgical treatment and axillary staging parallel those of IDC with the use of breast conservation therapy, and this is appropriate for a select group of patients. Traditional chemotherapy and hormonal therapies for IDC are the current standard for MCB, but future treatments are being considered as well. Novel strategies have emerged to target the nonepithelial component of MCB.<sup>8,28</sup> One such method is the use of ifosfamide and etoposide for the carcinosarcoma subtype of MCB.<sup>29</sup> In a recent evaluation of patients with sarcomatoid MCB, Hennessy et al<sup>28</sup> reported no recurrence in 3 patients who had received doxorubicin and ifosfamide as treatment. Lastly, regardless of the type of surgery used to eradicate the tumor, adjuvant radiation should be considered as part of the multimodality therapy for MCB patients. Additional studies suggest that for MCB patients with tumors 5 cm or larger or having greater than 4 metastatic axillary lymph nodes, undergoing mastectomy and radiation therapy is beneficial, and this approach should certainly be used.<sup>7</sup> Clinical trials and prospective studies for standard therapies for patients with MCB are difficult to accomplish because of the rarity of the disease.<sup>26</sup> Future studies with molecular techniques are currently being analyzed for genetic or epigenetic aberrations that might provide insight into the basis of the heterogeneity of the MCB. These efforts may one day identify novel therapies and realize the potential of targeted treatment in patients with MCB.<sup>21</sup>

## CONCLUSION

Metaplastic carcinoma of the breast is a rare type of breast cancer that is typically more aggressive and can be subcategorized mainly based on the pathologic findings. Metaplastic carcinoma of the breast can mimic IDC as well as benign lesions on mammography, but MCB is characterized by rapid growth and large size that is not usually seen with more common breast cancer tumors. Pathologic tissue diagnosis is essential to distinguish MCB from other breast cancers in order to institute proper and prompt treatment. The treatment for MCB depends on size and number of axillary nodes involved, but studies show that adjuvant radiation therapy provides benefits and should be used.

## References

1. Huvos AG, Lucas JC Jr, Foote FW Jr. Metaplastic breast carcinoma: rare form of mammary cancer. *N Y State J Med.* 1973;73:1078–1082.
2. Reis-Filho JS, Lakhani SR, Gobbi H, Sneige N. Metaplastic carcinomas. In: Lakhani SR, Ellis IO, Schnitt SJ, Tan PH, van de Vijver MJ, eds. *WHO Classification of Tumours of the Breast.* Lyon, France: IARC Press; 2012:48–52.
3. Pezzi CM, Patel-Pareikh L, Cole K, Franco J, Klimberg VS, Bland K. Characteristics and treatment of metaplastic breast cancer: analysis of 892 cases from the National Cancer Data Base. *Ann Surg Oncol.* 2007;14(1):166–173.
4. Barnes PJ, Boutilier R, Chiasson D, Rayson S. Metaplastic breast carcinoma: clinical-pathologic characteristics and HER2/neu expression. *Breast Cancer Res Treat.* 2005;91(2):173–178.
5. Leddy R, Irshad A, Rumboldt T, Cluver A, Campbell A, Ackerman S. Review of metaplastic carcinoma of the breast: imaging findings and pathological features. *J Clin Imaging Sci.* 2012;2(1):21.
6. Oberman HA. Metaplastic carcinoma of the breast: a clinicopathologic study of 29 patients. *Am J Surg Pathol.* 1987;11(12):918–929.
7. Lai HW, Tseng LM, Chang TW, et al. The prognostic significance of metaplastic carcinoma of the breast (MCB)—a case controlled comparison study with infiltrating ductal carcinoma. *Breast.* 2013; 22(5):968–973.
8. Shah DR, Tseng WH, Martinez SR. Treatment options for metaplastic breast cancer. *ISRN Oncol.* 2012;70:61–62.
9. Shin HJ, Kim HH, Kim SM, et al. Imaging features of metaplastic breast carcinoma with chondroid differentiation of the breast. *AJR Am J Roentgenol.* 2007;188(3):691–696.
10. Günhan-Bilgen I, Memiş A, Üstün EE, Zekioglu O, Özdemir N. Metaplastic carcinoma of the breast: clinical, mammographic, and sonographic findings with histopathologic correlation. *AJR Am J Roentgenol.* 2002;178:1421–1425.

11. Luini A, Aguilar M, Gatti G, et al. Metaplastic carcinoma of the breast, an unusual disease with worse prognosis: the experience of the European Institute of Oncology and review of the literature. *Breast Cancer Res Treat.* 2007;101(3):349–353.
12. Davis WG, Hennessy B, Babiera G, et al. Metaplastic sarcomatoid carcinoma of the breast with absent or minimal overt invasive carcinomatous component: a misnomer. *Am J Surg Pathol.* 2005;29(11):1456–1463.
13. Carter MR, Hornick JL, Lester S, Fletcher CD. Spindle cell (sarcomatoid) carcinoma of the breast: a clinicopathologic and immunohistochemical analysis of 29 cases. *Am J Surg Pathol.* 2006;30(3):300–309.
14. Brenner JR, Turner RR, Schiller V, Arndt R, Giuliano A. Metaplastic carcinoma of the breast: report of three cases. *Am Cancer Soc.* 1998;82:1082–1087.
15. Wargotz ES, Deos PH, Norris HJ. Metaplastic carcinomas of the breast, II: spindle cell carcinoma. *Hum Pathol.* 1989;20(8):732–740.
16. Wargotz ES, Norris HJ. Metaplastic carcinomas of the breast, IV: squamous cell carcinoma of ductal origin. *Cancer.* 1990;65(2):272–276.
17. Chuthapisith S, Warnnisorn M, Amornpinyokiat N, Pradnivat K, Angsusiha T. Metaplastic carcinoma of the breast with transformation from adenosquamous carcinoma to osteosarcomatoid and spindle cell morphology. *Oncol Lett.* 2013;6:728–732.
18. Wargotz ES, Norris HJ. Metaplastic carcinomas of the breast, I: matrix-producing carcinoma. *Hum Pathol.* 1989;20(7):628–635.
19. Wargotz ES, Norris HJ. Metaplastic carcinomas of the breast, V: metaplastic carcinoma with osteoclastic giant cells. *Hum Pathol.* 1990;21(11):1142–1150.
20. Tse GM, Tan PH, Lui PC, Chaiwun B, Law BK. Metaplastic carcinoma of the breast: a clinicopathological review. *J Clin Pathol.* 2006;59(10):1079–1083.
21. Weigelt B, Eberle C, Cowell CF, Ng CK, Reis-Filho JS. Metaplastic breast carcinoma: more than a special type. *Nat Rev Cancer.* 2014;14:147–148.
22. Hennessy BT, Angulo-Gonzalez A, Stemke-Hale K, et al. Characterization of naturally-occurring breast cancer subset enriched in epithelial-to-mesenchymal transition and stem cell characteristics. *Cancer Res.* 2009;69(10):4116–4124.
23. Reis-Filho JS, Pinheiro C, Lambros MB, et al. EGFR amplification and lack of activating mutations in metaplastic breast carcinomas. *J Pathol.* 2006;209(4):445–453.
24. Park HS, Park S, Kim J, et al. Clinicopathologic features and outcomes of metaplastic breast carcinoma: comparison with invasive ductal carcinoma of the breast. *Yonsei Med J.* 2010;51(6):864–869.
25. Beatty JD, Atwood M, Tickman R, Reiner M. Metaplastic breast cancer: clinical significance. *Am J Surg.* 2006;191(5):657–664.
26. Poggi MM, Danforth DN, Scuito LC, et al. Eighteen-year results in the treatment of early breast carcinoma with mastectomy versus breast conservation therapy: the National Cancer Institute randomized trial. *Cancer.* 2003;98(4):697–702.
27. Buza N, Zekry N, Charpin C, Tavassoli FA. Myoepithelial carcinoma of the breast: a clinicopathological and immunohistochemical study of 15 diagnostically challenging cases. *Virchows Arch.* 2010;457(3):337–345.
28. Hennessy BT, Giordano S, Broglio K, et al. Biphasic metaplastic sarcomatoid carcinoma of the breast. *Ann Oncol.* 2006;17(4):605–613.
29. Brown-Glaberman U, Graham A, Stopeck A. A case of metaplastic carcinoma of the breast responsive to chemotherapy with ifosfamide and etoposide: improved antitumor response by targeting sarcomatous features. *Breast J.* 2010;16(6):663–665.