

Sex Dimorphism of the Brain in Male-to-Female Transsexuals

Ivanka Savic¹ and Stefan Arver²

¹Stockholm Brain Institute, Department of Clinical Neuroscience and ²Department of Medicine Karolinska University Hospital, Karolinska Institute, Stockholm, Sweden

Address correspondence to Ivanka Savic, Stockholm Brain Institute, Karolinska Institutet, Department of Clinical Neuroscience, Retziusväg 8, 171 78 Stockholm, Sweden. E-mail: ivanka.savic-berglund@ki.se.

Gender dysphoria is suggested to be a consequence of sex atypical cerebral differentiation. We tested this hypothesis in a magnetic resonance study of voxel-based morphometry and structural volumetry in 48 heterosexual men (HeM) and women (HeW) and 24 gynephillic male to female transsexuals (MtF-TR). Specific interest was paid to gray matter (GM) and white matter (WM) fraction, hemispheric asymmetry, and volumes of the hippocampus, thalamus, caudate, and putamen. Like HeM, MtF-TR displayed larger GM volumes than HeW in the cerebellum and lingual gyrus and smaller GM and WM volumes in the precentral gyrus. Both male groups had smaller hippocampal volumes than HeW. As in HeM, but not HeW, the right cerebral hemisphere and thalamus volume was in MtF-TR larger than the left. None of these measures differed between HeM and MtF-TR. MtF-TR displayed also singular features and differed from both control groups by having reduced thalamus and putamen volumes and elevated GM volumes in the right insular and inferior frontal cortex and an area covering the right angular gyrus. The present data do not support the notion that brains of MtF-TR are feminized. The observed changes in MtF-TR bring attention to the networks inferred in processing of body perception.

Keywords: brain, gender dysphoria, MRI, sex dimorphism, VBM, volumetry

Introduction

Transsexuality is defined as a gender-identity disorder, characterized by the firm conviction of belonging to the opposite sex, which often leads to a request for sex-reassignment surgery (Blanchard 1993; Cohen-Kettenis and Gooren 1999). Most of the current hypotheses for this condition presume a sex atypical differentiation of the brain, due to genetic, and/or an early organizational effect of testosterone during the fetal development (Giedd et al. 1997; Green and Keverne 2000; van Goozen et al. 2002; Bentz et al. 2007; Swaab 2007). These hypotheses also presume that the perception of the own sex is linked to sexual differentiation of the brain and that in transsexuals this perception differs from the body phenotype. Such a discrepancy is believed to be possible because sex differentiation of the brain occurs later in development than sex differentiation of genitals (Swaab 2007). This scenario is supported by several postmortem studies showing that male to female (MtF-TR) transsexuals, like females, have a smaller volume, and number of neurons in the bed nucleus of the stria terminalis (BSTc) compared with male controls—differences, which seem not to be influenced by sex hormone levels in adulthood (Zhou et al. 1995; Kruijver et al. 2000). Recently, Garcia-Falgueras and Swaab (2008) also found “feminized” size

of INAH3 in MtF-TR (Berglund et al. 2008). While being intriguing, these findings are limited by the inherent pitfalls of postmortem studies. Our group recently employed in vivo investigations and found that smelling of 2 putative pheromones, which in heterosexual subjects normally leads to a sex differentiated activation of the hypothalamus, causes a sex atypical activation in estrogen naïve MtF-TR (Berglund et al. 2008). This observation corroborated with previous anatomical findings in transsexuals but provided no information as to whether and how the hypothalamic networks, which in animal studies are shown to be involved in “sexual behavior,” would be also engaged in the perception of “sexual identity.” Understanding the biology of gender dysphoria requires consideration of additional cerebral networks identified as sexually dimorphic than the hypothalamus. Considering that the sense of discomfort with sex characteristics of the own body is the main feature of gender dysphoria, it is important to also investigate the cerebral networks reported to be involved in own body perception and perception of self. Luders et al. recently addressed some of these issues by an explorative voxel-based morphological (VBM) analysis of the gray matter (GM) fractions. They found that GM volume in the putamen was more pronounced in MtF-TR than in male and female controls, particularly on the right side (Luders, Sanchez, et al. 2009). While the GM in the putamen did not differ significantly between male and female controls, these data, nevertheless, emphasized the possibility that gender dysphoria could be associated with an altered anatomy also in brain regions located outside the hypothalamus.

Previous studies with magnetic resonance (MR) have shown sex dimorphic features in several brain regions. In general, women are reported to have larger volumes of the hippocampus (Filipek et al. 1994), caudate nucleus (Filipek et al. 1994; Murphy et al. 1996; Giedd et al. 1997, 2006), and the anterior cingulate gyrus (Paus et al. 1996). In contrast, the relative volumes of the amygdala (Raz et al. 1995; Giedd et al. 1997, 2006; Neufang et al. 2009) are found to be larger in men. Studies with VBM indicate that sex dimorphism exists also in regional GM and white matter (WM) volumes. With some exceptions (Goldstein et al. 2001; Carne et al. 2006), men are reported to have larger GM volumes in the mesial temporal lobe, the cerebellum, and lingual gyrus (Good et al. 2001; Carne et al. 2006), whereas several authors detected larger GM volumes in the precentral gyrus, the right inferior parietal, and orbitofrontal cortex in women (Nopoulos et al. 2000; Good et al. 2001; Luders et al. 2005; Luders, Gaser, et al. 2009). There are also reports of larger GM volumes in women in the dorsolateral prefrontal cortex (Schlaepfer et al. 1995). Finally, sex differences have been found in hemispheric asymmetry. In general, the asymmetry in adults is rightward in the frontal and temporal lobe and leftward in the posterior temporal and

occipito-parietal regions (Toga and Thompson 2003). Among studies explicitly comparing the entire hemispheres most, although not all, suggest that the right hemisphere is larger in men (Filipek et al. 1994; Yucel et al. 2001; Kovalev et al. 2003; Carne et al. 2006; Savic and Lindstrom 2008).

Whereas VBM provides explorative analyses of regional gray and WM volumes in the cortex, volumes of the subcortical nuclei are more reliably evaluated with MR volumetry. The 2 methods are, thus, complementary. In the present study, they were employed in tandem to investigate whether cerebral gray and WM fractions, as well as the volume of structures previously suggested to be sex dimorphic may differ between MtF-TR, male, and female controls. Three issues were addressed specifically:

- Does the volume of the hippocampus, caudate, and putamen differ between MtF-TR and controls and is this difference found in relation to male or female controls?
- Does the overall or regional GM and WM volume in MtF-TR differ from controls and is this difference in line with the hypothesis of sex atypical cerebral differentiation in gender dysphoria?
- Are the volumes of the right and left cerebral hemisphere in MtF-TR asymmetric, as they are in heterosexual males but not females?

Only nonhomosexual, transsexual subjects were included. The rationale was the following: Although there is still an ongoing discussion about the classification of transsexual individuals (Blanchard et al. 1987, 1989; Lawrence 2005; Smith et al. 2005), the general view is that there are 2 fundamentally different types of transsexualism: homosexual and nonhomosexual (Blanchard et al. 1987). Homosexual MtF-TR are erotically attracted to the same biological sex and denoted as “androphilic” MtF-TR in the literature. They differ from those attracted to the opposite biological sex (“gynephilic” MtF-TR) and those who are not sexually attracted to other persons; The 2 latter groups are referred to as autogynephilic by the so called Blanchard’s classification (Blanchard 1989; Smith et al. 2005). Blanchard reported that homosexual transsexuals are usually younger at initial presentation and with more pronounced and frequent childhood femininity (Blanchard 1989). Homosexual transsexuals have also been found to be shorter, lighter, and lighter in proportion to their height, also in relation to men in the general population, whereas nonhomosexual transsexuals have been found to be similar in height as controls (Blanchard et al. 1995).

In a previous study, we found that homosexual healthy men differ in certain aspects of cerebral anatomy and function from heterosexual male controls (Savic et al. 2005; Berglund et al. 2006; Savic and Lindstrom 2008). Considering that homosexuality and transsexuality are two different phenomena with presumably different underlying neurobiology, and positing that MtF-TR would have feminized brain, we deemed it relevant to first investigate only nonhomosexual MtF-TR and avoid possible confounds related to homosexuality.

Materials and Methods

Subjects

Twenty-four heterosexual male controls (HeM, age 33 ± 6 years, range 26–48 years), 24 heterosexual female controls (HeW, age 35 ± 6 years,

range 32–46 years), and 24 MtF-TR (age 32 ± 7 years, range 21–51 years), were investigated with MRI. Only right-handed (Oldfield 1971), unmedicated, and healthy subjects were included. Exclusion criteria were history of severe systemic disease, any psychiatric (other than gender dysphoria), or neurological disorder, drug abuse including anabolic steroids or psychiatric medication, and use of hormonal contraceptives in women and hormone supplement in MtF-TR. All subjects provided written informed consent and received reimbursement after participation. The study was approved by the Regional Ethical Review Board at the Karolinska Institute, and written informed consent was obtained from each subject.

Transsexual subjects were recruited from the Karolinska University Hospital. Diagnostic assessment of gender identity disorder followed the International Classification of Disorders 10th edition A plus criteria for transsexualism (F64.0), American Psychiatric Association Task Force on DSM-IV 1994, and was made after several semistructured interviews with two mental health professionals (psychologist and psychiatrist) according to the clinical routine at the Karolinska University Hospital. The diagnostic criteria were as follows:

- 1) A desire to live and be accepted as a member of the opposite sex, usually accompanied by a sense of discomfort with the subject’s anatomical sex and a wish to have surgery and hormonal treatment to make the body as congruent as possible with the body of the preferred sex.
- 2) The transsexual identity has existed for at least 2 years.
- 3) The syndrome cannot be explained by any other psychiatric disorder or by chromosomal abnormality. Thus, any evidence of an abnormal male phenotype or genotype (i.e., hypospadias, cryptorchidism, micropenis, and chromosome complement other than 46XY) excluded enrollment to the study.

MtF transsexuals were evaluated to be free of psychosis according to the Diagnostic and Statistical Manual of the American Psychiatric Association, 4th Edition (DSM-IV; 13) by a specially trained psychiatrist and included a Structured Questionnaire for DSM-IV Axis I and II Structured Clinical Interview for DSM-IV (SCID-I and II) (American Psychiatric Publishing Inc, Arlington, 1997). Chromosome analysis (karyotyping), clinical examination, and testosterone assessment confirmed that the MtF-TR were genetically and phenotypically males.

Sexual orientation was assessed using the Kinsey Heterosexual/Homosexual scale (0 = exclusively heterosexual, 6 = exclusively homosexual) for the type of sexual contacts, sexual fantasies, and attraction (Kinsey et al. 2003). In addition to scoring themselves on the Kinsey scale (which is based on self-identification), the subjects also participated in interviews regarding 3D of sexual orientation (fantasy, romantic attraction, and sexual behavior) over consecutive 5-year historical time periods, from age 16 to the present (Chung 1996). All decisions about subjects’ sexual orientation were made in ignorance of the subjects’ MR data as described previously (Berglund et al. 2006, 2008; Savic and Lindstrom 2008).

Seventeen of the recruited MtF-TRs conveyed at the time of the scan experienced of only female sexual partners (and rated Kinsey 0–2), the remaining 7 reported that they never had a sexual partner but stated clear attraction to women and not men. The MtF-TR were, thus, nonhomosexual, attracted to women, and will throughout the manuscript be referred to as gynephilic (Smith et al. 2005) (autogynephilic according to Blanchard’s classification). All reported a relatively early (usually at puberty) awareness of gender dysphoria.

None of the subjects had a history of neurological or psychiatric disorders (other than gender dysphoria) or brain injury. Before inclusion, a detailed history was obtained from each subject, including possible use of unregulated hormone supplements and synthetic steroids not prescribed by a physician. All the subjects declared that they had never received hormonal treatment nor were they on any medication at the time of the study. Their statement was deemed reliable and confirmed by repeated tests of hormonal levels, which were significantly lower than those of HeW and not significantly altered compared with the values of HeM (Table 1).

The 3 groups were matched for educational level (number of school years) (14 ± 2 years HeM, 15 ± 3 years HeW, and 15 ± 2 years MtF-TR).

Table 1
Hormone levels

Group	S-testosterone, active (nmol/L)	S-testosterone total (nmol/L)	S-prolactin (mg/L)	S-FSH (U/L)	S-LH (U/L)	S-oestradiol (pmol/L)
MtF-TR	9.3 ± 1.0	15.2 ± 5.7	7.8 ± 2.5	4.3 ± 3.1	3.9 ± 2.1	69 ± 50
HeM	7.8 ± 2.4	11.8 ± 3.2	8.4 ± 5.7	4.4 ± 1.9	5.1 ± 2.3	49 ± 37
HeW	1.0 ± 3.2	2.9 ± 3.8	9.6 ± 3.6	13.6 ± 26.1	10.4 ± 11.8	141 ± 3

Note: FSH, follicle stimulating hormone; LH, luteinizing hormone. Plasma oestradiol level in the transsexual patients ranged between 12 and 120 pmol/L, in HeW between 31 and 382 pmol/L, and in HeM between 4 and 93 pmol/L. Plasma oestradiol was significantly higher and testosterone significantly lower in HeW in relation to both HeM and MtF-TR and HeM (one-way ANOVA with Scheffe's post hoc test. $F = 16-51$; $P < 0.0001$ for all the comparisons). Values are expressed as means and standard deviations. Hormone values were measured with appropriate Coat-A-Count RIA (Diagnostics Product Corporation), according to manufacturer's instructions.

MR Acquisition

Structural images were acquired on a GE 1.5-T Sigma 5.X scanner (General Electric), including 3D-weighted T_1 Spoiled GRASS sequence (SPGR) images with 1-mm sections as described previously (Ciumas and Savic 2006). Briefly, the MRI protocol consisted of axial T_2 -weighted fast spin echo images (effective time echo [TE] = 56 ms, time repetition [TR] = 2500 ms, field of view [FOV] = 24 cm, 23 slices of 3-mm thickness), and axial T_1 -weighted 3D spoiled GRASS images (SPGR, TE = 7 ms, TR = 23 ms, FOV = 24 cm, flip angle = 50°, 124–156 slice partitions of 1-mm thickness, 2 NEX).

Voxel-Based Morphometry

Voxel-based morphometry (Ashburner 2007) was performed using the Gaser toolbox (<http://dbm.neuro.uni-jena.de/vbm/>) with SPM 5 (The Wellcome Department of Imaging Neuroscience, University College London; www.fil.ion.ucl.ac.uk/spm/) and Matlab 7.3 (Math Works). The VBM preprocessing included 5 steps:

- 1) Check for scanner artifacts and gross anatomical abnormalities for each subject.
- 2) Set of image origin at the anterior commissure AC.
- 3) Use of Hidden Markov Random Field option in the segmentation of the VBM5 toolbox to minimize the noise level of the segmentation.
- 4) Use of DARTEL toolbox for a high-dimensional normalization protocol. We followed John Ashburner's chapter in its standard version including the Montreal Neurological Institute (MNI) space transformation (Ashburner 2007). To restore original volume information within each voxel, voxel values in the segmented images were modulated (multiplied) by the Jacobian determinants derived from the spatial normalization step. The analysis of modulated data allowed direct comparisons of regional differences in the amount of each tissue type.
- 5) Check for homogeneity across sample and use the standard version of the smoothing (8 mm). After preprocessing, smoothed modulated normalized data were obtained and used for the statistical analysis. These smoothed modulated GM volumes are hereafter referred to as GM, WM, and cerebrospinal fluid (CSF).

Delineation of Volumes of Interest

Homologous volumes of interest (VOIs) were delineated manually in the hippocampus, caudate, and putamen—regions, which in previous studies have been suggested to be sexually dimorphic. Furthermore, the thalamus volume was delineated post hoc to the VBM analysis because it showed a significant group difference in this region (see Results). The set of VOIs also included the right and left cerebral hemisphere to allow evaluation of possible hemispheric asymmetries.

All the volumes were delineated on original, unreformatted T_1 images using MRIcro software (www.sph.sc.edu/comd/rorden/micro.html) by 2 investigators, who were uninformed about the identity of the subjects, their sex, and their sexual identity. Values presented in Results and Table 2 were generated by investigator 1, who analyzed all the data (investigator 2 analyzed structural volumes from 15 randomized subjects in each study group). VOIs were outlined according to previously described protocols (Ciumas and Savic 2006; Helms et al. 2006; Savic and Lindstrom 2008).

Table 2

Structural volumes

Region	Female controls, N = 24	Male controls, N = 24	MTF transsexuals, N = 23
R Caudate	4.2 ± 0.4	4.8 ± 0.4	4.9 ± 0.6
L Caudate	4.3 ± 0.4	4.9 ± 0.6	4.8 ± 0.6
R Putamen	4.4 ± 0.4	5.0 ± 0.7	4.5 ± 0.6 ^a
L Putamen	4.3 ± 0.4	4.9 ± 0.8	4.5 ± 0.6 ^b
R Hippocampus	3.1 ± 0.5	3.4 ± 0.4	3.2 ± 0.6 ^c
L Hippocampus	3.2 ± 0.4	3.2 ± 0.3	3.0 ± 0.6 ^d
R Thalamus	6.6 ± 0.7	7.6 ± 0.9	6.9 ± 0.8 ^e
L Thalamus	6.4 ± 0.6	7.1 ± 0.8	6.5 ± 0.7 ^f
Total tissue volume	1201 ± 89 ^g	1384 ± 101	1335 ± 122
Total brain volume	1425 ± 146 ^g	1657 ± 123	1654 ± 165
Total GM volume	675 ± 44 ^g	785 ± 61	780 ± 44
Total WM volume	442 ± 45 ^g	520 ± 46	506 ± 72
Right hemisphere	557 ± 36 ^g	621 ± 33	598 ± 33
Left hemisphere	558 ± 35 ^g	613 ± 38	592 ± 33

Note: Structural volumes in the respective subject group. Numbers express cm³ (mean and standard deviation). Significance levels for the caudate, putamen, hippocampus, and thalamus are calculated on the basis of VOI/total brain tissue ratios. a–h indicate group difference.

^aLower in MtF-TR in relation to HeM $P = 0.03$ and HeW $P = 0.006$.

^bLower in MtF-TR in relation to HeM $P = 0.003$ and HeW $P = 0.02$.

^cLower in MtF-TR in relation to HeW, $P = 0.002$.

^dHigher in HeW in relation to MtF-TR $P < 0.0001$ and HeM $P = 0.0006$.

^eLower in MtF-TR in relation to HeM $P = 0.016$ and to HeW $P = 0.04$.

^fLower in MtF-TR in relation to HeM $P = 0.03$ and to HeW $P = 0.013$.

^gLower in HeW in relation to both HeM and MtF-TR, $P < 0.0001$.

The Hippocampus

In summary, the hippocampus was traced according to the protocol of Watson et al. (1992). The posterior boundary of the hippocampus was defined as the first image in which the crus of the fornix became visible. The superior boundary consisted of the alveus; the lateral boundary was the inferior corn of the lateral ventricle; the ambient cistern was the medial boundary, whereas the WM of the parahippocampal gyrus represented the inferior boundary. The hippocampus VOI included the tail of the hippocampus.

The Caudate Nucleus

The caudate nuclei were traced separately according to Raz et al. (2005). The lateral ventricle was used as the medial boundary; the subcallosal fasciculus served as the anterior boundary, the stria terminalis was the posterior boundary (identified by a change in signal intensity relative to the caudate nucleus), and the anterior limb of the internal capsule served as the lateral boundary. The region of interest included the head, the body of the caudate, and the tail (excluding the portion that turned anterior). The nucleus accumbens was excluded as well.

The Putamen

The delineation of the putamen started in the first slice where it became visible laterally to the caudate. The superior boundary was defined by the corona radiata, the internal capsule was the medial border, and the lateral border was the external capsule. The posterior limit was the point at which the putamen was no longer visible in the corona radiata. The lower limit was just above the amygdala,

excluding nucleus accumbens, when the operator could see the most inferior aspect of the third ventricle, and the chiasmatic cistern was no longer visible.

The Thalamus

The 2 thalami were disconnected between the 2 smallest cross-sections through the massa intermedia in the sagittal plane. The thalamus volumes included the centromedian, ventral anterior, ventral lateral, ventral posterior, lateral posterior, lateral dorsal, and medial dorsal nuclei, the pulvinar and the anterior nuclear group, the midline nuclei, the intralaminar, centrolateral, and the reticular nucleus. The borders of the thalamus were determined by anatomical landmarks as described by Kretschmann and Weinrich (1995) and using the Duvernoy atlas. The anterior border was defined at the level of the anterior end of the third ventricle and the interthalamic adhesion. The inferior margin was defined as the superior border of the midbrain structures, and the medial margin was the wall of the third ventricle and the interthalamic adhesion. The lateral margin of the thalamus was defined as the medial border of the posterior limb of the internal capsule, and the superior margin as the body of the lateral ventricle. The posterior border was demarcated as the section showing the fornices in their entire width in the coronal plane. The medial and lateral geniculate bodies were excluded.

The cerebral hemispheres were delineated on every second coronal slice of the individual MR images. The same coronal section was displayed in parallel windows to avoid overlapping demarcation. Cerebral hemispheres were divided at the midline in the coronal plane by a hand-drawn line connecting the measured midpoint of the corpus callosum with the midpoint of the hypothalamus, third ventricle, and cerebral aqueduct (Savic and Lindstrom 2008). The respective VOI included ventricles and ended in the caudal direction at the level of the superior colliculum, as described previously. Thus, the subcortical regions, brainstem, and cerebellum were separated from the remaining brain and not included.

The hippocampus was delineated on coronal images, the other structures on horizontal sections. All the volumes were then viewed and corrected on coronal, horizontal as well as sagittal images.

Venous blood samples were collected in the morning to assess plasma levels of sex hormones (Chemical Laboratory Diagnostics at the Karolinska University Hospital).

Statistical Analysis

Age and education difference, as well as difference in the total intracranial volume (TIV), calculated as (GM + WM + CSF), and the total tissue volume (GM + WM) was tested with one way analysis of variance (ANOVA), using group as the factor of variance ($P < 0.05$). One way ANOVA was also employed for group comparisons in total GM and WM volumes but using the intracranial volume as covariate.

VBM

Group differences in regional GM and WM volume were tested with flexible factorial design in SPM5 (voxel threshold $P < 0.001$, minimum cluster size 0.4 cm^3) using age and the total GM volume or total WM volume, as a covariate of no interest (the latter to adjust for individual age differences and potential sex dimorphism in the whole GM and WM volume, respectively). The coordinates are reported in MNI space.

Structural Volumes

Group differences in brain tissue volume (sum of total GM and WM) and total brain volumes (sum of GM, WM, and CSF) were tested with separate one-way ANOVAs using group as the factor of variance and Fischer's post hoc test ($P < 0.05$). The mean relative values of the 2 homologous VOIs for each type of structure were employed as input function for evaluations of possible group differences in relative structural volumes (VOI/brain ratios) (separate one way ANOVAs with group as the between factor and age as covariate; $P < 0.0125$, after Bonferroni correction for the 4 separate regions).

Asymmetry in hemispheric volumes and in the homologous volumes of the hippocampus, caudate, putamen, and thalamus was first tested in each group with paired *t* tests ($P < 0.01$ because of the Bonferroni correction for the 5 investigated regions). Possible group differences in asymmetry indices (right/left hemisphere, right/left structural volume) were then evaluated using one-way ANOVA ($P < 0.01$ with Bonferroni correction for the 5 comparisons), and Fisher's post hoc test ($P < 0.05$). The interrater variability was calculated using simple regression (Pearson's coefficient)

Results

The groups did not differ in age or education, and no significant difference was detected between HeM and MtF-TR in sex hormone levels (Table 1). No gross anatomical abnormalities were found as judged by an experienced neuroradiologist. One subject (MtF-TR) was excluded because of movement artifacts during the scan. After the segmentation and normalization, no outlier was found when checking for homogeneity, and no further subjects had to be excluded from the analysis.

Group difference was found in the total brain tissue volume (degrees of freedom [df] = 2, $F = 17.8$, $P < 0.0001$, one way ANOVA), which was smaller in HeW compared than in HeM and MtF-TR ($P < 0.0001$, Fischer's post hoc test); no difference was found between HeM and MtF-TR ($P = 0.726$, Table 2). HeW had also smaller TIV compared with the 2 male groups (df = 2, $F = 3.7$, $P = 0.029$, Table 2), whereas no group difference was found in the total GM or total WM volume, when using TIV as covariate (df = 2, $F = 1.5$, $P = 0.24$, and df = 2, $F = 1.5$, $P = 0.23$, respectively, Table 2).

Voxel-Based Morphometry

Differences between HeM and HeW were found in several regions (Table 3, Fig. 1). The GM volume in the lingual gyrus, the cerebellum, right putamen, and left amygdala and perirhinal cortex was larger in HeM. HeW, on the other hand, showed larger GM and WM volumes in the precentral gyrus.

None of these differences were reproduced when comparing HeM with MtF-TR. Differences between MtF-TR and controls were found, instead, in several other regions (Table 3, Fig. 1) and in relation to both HeM and HeW. They were constituted by increases in GM volume in MtF-TR in the right temporo-parietal junction (around the angular gyrus and in the posterior portion of the superior temporal gyrus), the right inferior frontal and insular cortex, and decreases in GM volumes in the thalamus. Post hoc recalculation with false discovery rate ($P < 0.05$) did not change the results.

Structural Volumetry

Differences in regional structural volumes were detected in the:

- relative "thalamus volume" (df = 2, $F = 5.6$, $P = 0.005$), which was smaller in MtF-TR than in HeM ($P = 0.005$) as well as HeW ($P = 0.010$);
- relative "putamen volume," which, again, was smaller in MtF-TR than in both control groups ([df = 2, $F = 5.8$, $P = 0.004$]; $P = 0.001$ for MtF-TR vs. HeM and $P = 0.002$ for MtF-TR vs. HeW, Fischer's post hoc test). Neither the thalamus nor the putamen volume differed between HeM and HeW;
- relative "hippocampus volume" (df = 2, $F = 6.5$, $P = 0.003$), which was larger in HeW compared with both

Table 3

Group differences in GM and WM volumes

Region	GM volume			WM volume		
	Z level	Size, cm ³	Coordinates	Z level	Size, cm ³	Coordinates
Male controls—female controls						
L amygdala + entorhinal cortex	4.7	1.4	−17, −2, −21			
R putamen	4.0	3.2	29, −2, −2			
R lingual gyrus	4.0	2.4	11, −63, −9			
Cerebellum	5.1	4.8	27, −90, −22			
R superior temporal gyrus				3.8	0.8	47, −42, 16
Female controls—male controls						
Precentral gyrus	4.2	0.8	6, −8, 48	5.1, 4.7	8.8, 6.3	−30, 0, 29; 29, −8, 45
Subcallosum (BA 24, 32)	3.9	3.6	−16, 22, −18			
R middle frontal gyrus	4.1	2.2	46, 38, 17			
MTF transsexuals—male controls						
R superior temporal gyrus + angular gyrus ^a	5.4	3.1	49, −40, 18			
R insular cortex + parts of inferior frontal gyrus	5.8	3.4	39, 15, −16			
Male controls—MTF transsexuals						
Thalamus ^b	4.3	1.9	13, −28, 5			
R frontal WM				4.2	4.5	13, 45, 32
MTF transsexuals—females						
R insular cortex + inferior frontal gyrus	5.5	2.5	41, 16, −12			
R superior temporal gyrus + angular gyrus ^a	5.2	3.0	52, −33, 16			
Lingual gyrus	5.1	2.5	10, −89, −22			
Cerebellum	4.6	1.4	−30, −90, −24			
Females—MTF transsexuals						
Thalamus	5.6	2.7	−1, −13, 5			
Pre and postcentral gyrus	3.9	1.4	−39, −20, 44			
Precentral gyrus	4.1	1.4	−4, −11, 49			
Frontal WM (precentral gyrus)				4.3	3.3	29, −2, 30

Note: Values calculated using height threshold at $P = 0.001$, minimum cluster size 100 voxels (0.4 cc), corrected $P < 0.05$. Values in italics are calculated at $P = 0.001$, corrected $P < 0.1$, and illustrate trend values. MNI coordinates indicate the peak value and the indicated regions coverage of the respective cluster. R, right; L, left.

^aCovers posterior portion of the superior temporal gyrus, the angular gyrus, and a portion of the inferior parietal cortex.

^bCovers parts of the L caudate.

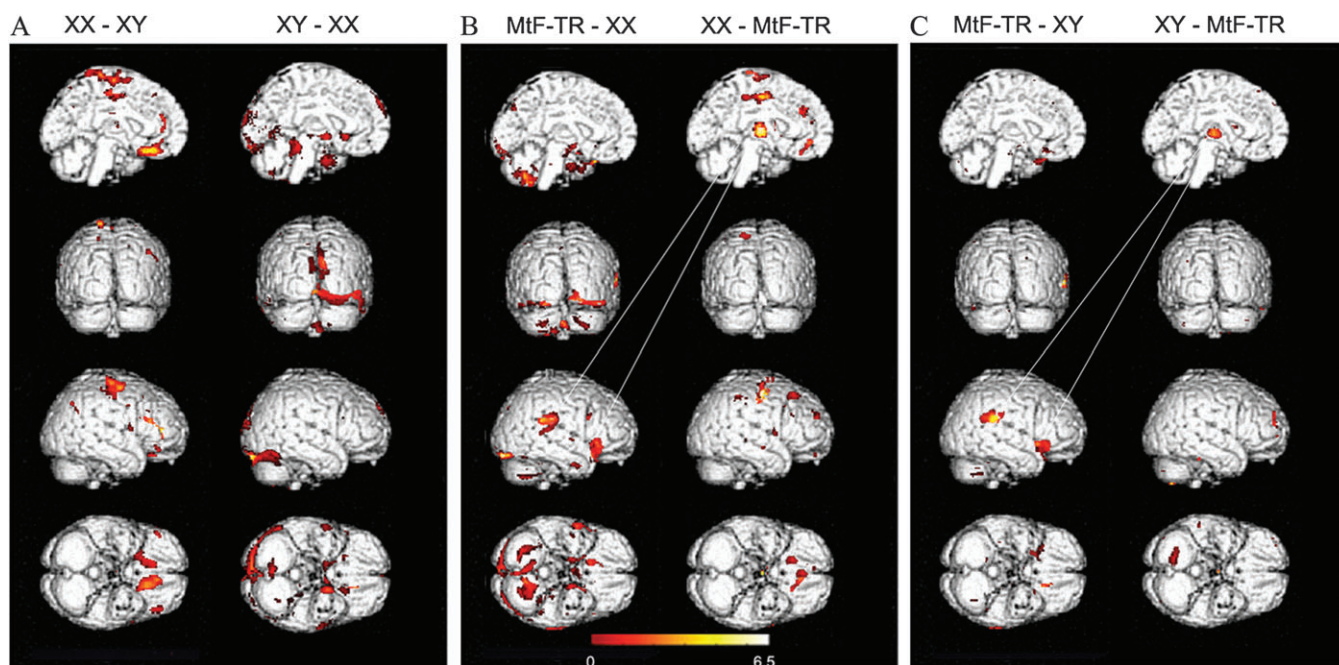


Figure 1. Group differences in regional GM volume. Colored clusters were calculated from the following group comparisons: (A) HeW-HeM (left), HeM-HeW (right). (B) MtF-TR-HeW (left), HeW-MtF-TR (right). (C) MtF-TR—HeM (left), HeM-MtF-TR (right). Contrast calculated at T corresponding to $P = 0.001$ at pixel level, $P < 0.05$ corrected, minimum cluster size 0.4 cm³. Clusters are superimposed on the standard brain, SPM5. The scale is arbitrary showing T -values between 0 and 6.5. The lines indicate the 3 regions in which the gray matter fraction differed between transsexuals and controls. Notably, these regions were similar independently of whether the controls were men or women.

HeM ($P = 0.01$) and MtF-TR ($P = 0.0012$); this difference was mainly driven by the left hippocampus. No difference was found between MtF-TR and HeM.

No group difference was detected in the caudate volume ($df = 2$, $F = 1.97$, $P = 0.14$). Table 2 shows values from both sides to illustrate possible effect of side on the overall comparisons.

Interrater reliability ranged from 0.76 to 0.96 (0.76 for the hippocampus, 0.89 the thalamus, 0.95 the cerebral hemispheres, and 0.96 the caudate and putamen).

Structural Asymmetries

A significant rightward asymmetry was detected in the hemispheric volume in both HeM ($P = 0.002$) and MtF-TR ($P = 0.006$), whereas the 2 hemispheres were symmetrical in HeW ($P = 0.701$) (Table 2). This difference was significant ($[df = 2, F = 4.8, P = 0.0016, \text{one way ANOVA}]$, $P = 0.006$ for the comparison between HeM and HeW, and $P = 0.008$ for the comparison between MtF-TR and HeW, Fischer's post hoc test). Rightward asymmetries were detected in HeM and MtF-TR but not in HeW also in the thalamus ($P = 0.008$ for HeM and $P = 0.010$ for MtF-TR; $P = 0.160$ for HeW) and in HeM in the hippocampus ($P = 0.010$; the corresponding P value for MtF-TR was 0.065 and for HeW 0.470). Whereas the asymmetry index (right/left side) for the hippocampus differed significantly between the groups ($df = 2, F = 6.6, P = 0.002$; $P = 0.001$ for HeW vs. HeM and $P = 0.009$ for HeW vs. MtF-TR, Fischer's post hoc test), no significant group difference was detected in the thalamus index ($df = 2, F = 1.04, P = 0.35$) (Table 2). None of the groups showed asymmetry in the caudate or putamen.

Discussion

Tentative sex dimorphic features were investigated in a group of healthy MtF-TR in relation to age and education matched right-handed heterosexual male and female controls. Contrary to the primary hypothesis, no sex-atypical features with signs of "feminization" were detected in the transsexual group. Instead, we found significant volume reductions of the thalamus and putamen in MtF-TR and significant increases in GM volumes in an area covering the right angular gyrus and posterior portion of the superior temporal gyrus and in the right insular and inferior frontal cortex.

The volumetry measures primarily included structures previously reported to be sexually dimorphic (Filipek et al. 1994; Raz et al. 1995, 2001, 2004, 2005; Giedd et al. 1997; Neufang et al. 2009). In addition, we investigated the thalamus volume post hoc to the VBM analysis and the putamen volumetry due to the recent finding of GM volume increase in MtF-TR in this region (Luders, Sanchez, et al. 2009). Although sex differences have been described also in the amygdala and cingulate gyrus, these structures were not included in the analysis because the identification of anatomical landmarks in these regions is less reliable, especially when using a 1.5-T scanner.

The presently observed sex differences in controls are congruent with those described in several previous publications. The VBM findings adhere with Good et al. (2001) and Luders et al. (2005), who detected greater relative amounts of GM (volume and concentration, respectively) in the prefrontal gyri and in the inferior frontal cortex in female brains (the latter increase was in the present study detected only at $P < 0.1$ corrected). They are also compatible with Good et al. (2001) and Chen et al. (2007), who reported that men have a larger GM volume in the inferior and mesial temporal cortex, the cerebellum, and the right occipital and lingual gyri. Congruent with previous reports is also the present finding of a significantly elevated hippocampus volume in HeW (Filipek et al. 1994; Murphy et al. 1996; Giedd et al. 1997, 2006). Finally,

in accordance with our earlier observations (Savic and Lindstrom 2008), the hemispheric volumes were symmetrical in HeW but not HeM (Table 2). This agreement with several earlier observations of sex dimorphism in male and female controls adds validity to the present findings in MtF-TR even when considering that the sample size was relatively low. These findings argue against a sex atypical dimorphism in MtF-TR, at least in those who are not androphillic.

VBM data from MtF-TR has previously been published only by Luders, Sanchez, et al. (2009), who did not find any clear signs of cerebral feminization either. They detected, however, an elevated GM volume in the right putamen in MtF-TR in relation to both female and male controls. Our study converges on their findings only when carrying out small volume correction ($z = 2.7$, size 0.3 cc, MNI coordinate $-25, 0, -1$, $P = 0.037$ for MtF-TR vs. HeM; $z = 3.3$, size 0.5 cc, MNI coordinate $-20, -1, 0$, $P = 0.037$ for MtF-TR vs. HeW). However, we also investigated putamen's structural volume and found that it was significantly reduced in MtF-TR in relation to both HeM and HeW, which supports the hypothesis that gender dysphoria may be associated with changes in this structure.

MR volumetry outside the hypothalamus has, to the best of our knowledge, hitherto not been reported in transsexuals, and the presently observed reductions of the thalamus and putamen volumes in MtF-TR have no precedents. Neither have increases of GM volumes in the temporoparietal junction, and the insular and inferior frontal cortex been described earlier. These findings need further validation with larger samples, and their origin is currently unknown. Any interpretation must, therefore, proceed cautiously and can at this point only be highly speculative.

The principal feature of gender dysphoria is a strong and persistent identification with the opposite sex and a strong discomfort with one's birth sex, often with a feeling of being trapped in the wrong body (Becker and Mester 1996). There is no evidence that this feeling is caused by a general sensory deficit in transsexual persons. Own body and self-perception is, according to current literature, related to both sensory and cognitive processes (Northoff et al. 2006). Sensory processes include perception of physical stimuli from one's own body, which depends on sensory and motor feedback mechanisms by means of which the consequences of the movements/actions are related to the own person (Gallagher and Frith 2003). The cognitive component of own body perception encompasses propositional knowledge about one's self and incorporates episodic and autobiographical memories (Rekkas and Constable 2005). Several studies propose that own body perception involves networks in the temporo-parietal, inferior parietal cortex, the inferior frontal, and insular cortex (Blanke et al. 2002, 2004; Adamovich et al. 2009; Hodzic et al. 2009), and their connections with the putamen and thalamus (Leichnetz 2001). Thus, theoretically, the experience of dissociation of the self from the body may be a result of failure to integrate complex somatosensory and memory processes executed by these networks. Such disintegration accords with the present findings and could, perhaps, explain recent observation of poorer parietal cortex activation during a spatial orientation task in MtF-TR compared with male controls (Carillo et al. 2010). However, it is difficult to explain how such disintegration can be linked to a dysphoria restricted to the own body's sex characteristics. Moreover, even if a link exists, it is uncertain whether the here observed morphometric

features in transsexual patients underpin their gender identity or are a consequence of being transsexual. One highly speculative thought is that the enlargement of the GM volume in the insular and inferior frontal cortex and the superior temporal-angular gyrus could derive from a constant rumination about the own body. Brain tissue enlargement has been detected in response to training, and GM enlargement of the insular cortex has been reported in response to meditation, which involves mental focusing on the own body (Holzel et al. 2008; Luders, Toga, et al. 2009; Vestergaard-Poulsen et al. 2009). Alternatively, entirely other variables may be independently affecting both the expression of a transsexual identity and the neuroanatomy in transsexuals leading to the observed association between both. Of note is also that regional GM and WM is a composite measure of different microunits, such as neuronal bodies, dendrites, synapses, axons, myelin, glia cells, and others, and an enlargement or reduction of GM volume cannot be directly translated to function. It should be emphasized that the present data, being focused on extra hypothalamic structures, do not disapprove previous reports about sex-atypical hypothalamic dimorphism in transsexuals (Swaab et al. 1992; Zhou et al. 1995). Furthermore, they were generated exclusively from investigations of nonhomosexual, gynephillic MtF-TR. The issue of possible cerebral difference between gynephillic and androphillic (homosexual) MtF-TR and also between androphillic MtF-TR and homosexual healthy men is of special interest and needs to be addressed separately in future studies. Additional studies of the relationship between brain structure and function in transsexual persons and also extending the material to female to male transsexuals are necessary to more precisely interpret the present observations.

Methodological Strengths and Limitations

A few methodological aspects deserve a comment. First of all, one may argue that our limited sample size could hamper reliable detection of group differences. However, as already mentioned, differences were found between HeM and HeW in regions previously reported to be sexually dimorphic, and similar differences were also detected between MtF-TR and HeW but not between MtF-TR and HeM. Consequently, it is difficult to disregard the present findings simply on the basis of group size. Another potential methodological concern is difference in brain size. Because of their larger brains, the outer brain limits in men are farther away from the center of the coil in the MR scanner and, therefore, could be located in less homogenous parts of the field. As a consequence, sex differences in GM volumes in the most peripheral parts from the center of the brain (frontal pole, pre- and postcentral gyrus, occipital pole) could be a potential confound. This in turn could result in lower signal intensity in these locations leading to regionally decreased GM in male subjects. While our findings of lower GM volume in the precentral gyrus in men could be in agreement with this assumption they are incompatible with the enlarged GM volume in the lingual gyrus in men and the fact that other structures located far from the center of the coil, such as the frontal pole, did not show a lower GM volume in HeM or MtF-TR. Furthermore, when comparing GM between females and males of matched brain size larger regional GM volumes were still demonstrated in females (Luders, Gaser, et al. 2009). Also of note is that the whole brain volume did not differ between MtF-TR and HeM in the present study.

The differences observed in our age-matched samples of adults might not be reproduced in older subjects.

MR volumetry was applied as a complement to VBM because of its higher sensitivity to detect regional changes. VBM, on the other hand, allowed explorative analyses, and by using the 2 methods in tandem, it was possible to extend previous information about brain and gender dysphoria by adding data from several cortical and subcortical regions outside the hypothalamus. That the present set of VOIs was reliably delineated is suggested by the high interrater reliability, and the congruence between the present and previously reported volume measures.

While changes in the thalamus were detected with both VBM and structural volumetry, they were found in the putamen only with the latter approach. A similar disparity has been described earlier (Ciumas and Savic 2006) and is not surprising, as the 2 methods may show different results in regions with well-defined structural landmarks but a poor gray-WM contrast. In such regions, volumetric measures are usually more reliable.

Finally, we would like to emphasize that at variance to previous reports, the investigated study groups were homogeneous with respect to sexual orientation. This is essential considering that structural differences have been detected between homo and heterosexual persons (Savic and Lindstrom 2008). Also, the testosterone and estrogen levels were tested at the time of the scan in each patient and showed that levels in MtF-TR were significantly lower than those in women but not different from male controls (Table 1), making it improbable that the transsexual subjects were using estrogen substitution (although this could not be explicitly excluded separately for each individual due to the inherently high variability of plasma estrogen).

Conclusions

The present study does not support the dogma that MtF-TR have atypical sex dimorphism in the brain but confirms the previously reported sex differences in structural volumes, gray, and WM fractions. The observed differences between MtF-TR and controls raise the question as to whether gender dysphoria may be associated with changes in multiple structures and involve a network (rather than a single nodal area).

Notes

VINNOVA, Swedish Research Council, and Center for Gender Medicine at Karolinska Institute are acknowledged for financial support. We are indebted to Dr Carolina Ciumas, Alexander Berglund, and Claudija Espino for drawing of regions and Elodie André for some technical assistance. *Conflict of Interest:* None declared.

References

- Adamovich SV, August K, Merians A, Tunik E. 2009. A virtual reality-based system integrated with fmri to study neural mechanisms of action observation-execution: a proof of concept study. *Restor Neurol Neurosci.* 27:209–223.
- Ashburner J. 2007. A fast diffeomorphic image registration algorithm. *Neuroimage.* 38:95–113.
- Becker D, Mester R. 1996. Further insights into transsexualism. *Psychopathology.* 29:1–6.
- Bentz EK, Schneeberger C, Hefler LA, van Trotsenburg M, Kaufmann U, Huber JC, Tempfer CB. 2007. A common polymorphism of the SRD5A2 gene and transsexualism. *Reprod Sci.* 14:705–709.

- Berglund H, Lindstrom P, Dhejne-Helmy C, Savic I. 2008. Male-to-female transsexuals show sex-atypical hypothalamus activation when smelling odorless steroids. *Cereb Cortex*. 18:1900–1908.
- Berglund H, Lindstrom P, Savic I. 2006. Brain response to putative pheromones in lesbian women. *Proc Natl Acad Sci U S A*. 103:8269–8274.
- Blanchard R. 1989. The classification and labeling of nonhomosexual gender dysphorias. *Arch Sex Behav*. 18:315–334.
- Blanchard R. 1993. Varieties of autogynephilia and their relationship to gender dysphoria. *Arch Sex Behav*. 22:241–251.
- Blanchard R, Clemmensen LH, Steiner BW. 1987. Heterosexual and homosexual gender dysphoria. *Arch Sex Behav*. 16:139–152.
- Blanchard R, Dickey R, Jones CL. 1995. Comparison of height and weight in homosexual versus nonhomosexual male gender dysphorics. *Arch Sex Behav*. 24:543–554.
- Blanke O, Landis T, Spinelli L, Seeck M. 2004. Out-of-body experience and autoscopia of neurological origin. *Brain*. 127:243–258.
- Blanke O, Ortigue S, Landis T, Seeck M. 2002. Stimulating illusory own-body perceptions. *Nature*. 419:269–270.
- Carillo BG, Gómez-Gil E, Rametti G, Junque C, Gomez A, Karadi K, Sgovio S, Guillamon A. 2010. Cortical activation during mental rotation in male-to-female and female-to-male transsexuals under hormonal treatment. *Psychoneuroendocrinology*. 35(8):1213–1222.
- Carne RP, Vogrin S, Litewka L, Cook MJ. 2006. Cerebral cortex: an MRI-based study of volume and variance with age and sex. *J Clin Neurosci*. 13:60–72.
- Chen X, Sachdev PS, Wen W, Anstey KJ. 2007. Sex differences in regional gray matter in healthy individuals aged 44–48 years: a voxel-based morphometric study. *Neuroimage*. 36:691–699.
- Chung YB, Katayama M. 1996. Assessment of sexual orientation in lesbian/gay/bisexual studies. *J Homosex*. 30:49–62.
- Ciomas C, Savic I. 2006. Structural changes in patients with primary generalized tonic and clonic seizures. *Neurology*. 67:683–686.
- Cohen-Kettenis PT, Gooren LJ. 1999. Transsexualism: a review of etiology, diagnosis and treatment. *J Psychosom Res*. 46:315–333.
- Filipek PA, Richelme C, Kennedy DN, Caviness VS Jr. 1994. The young adult human brain: an MRI-based morphometric analysis. *Cereb Cortex*. 4:344–360.
- Gallagher HL, Frith CD. 2003. Functional imaging of “theory of mind”. *Trends Cogn Sci*. 7:77–83.
- Garcia-Falgueras A, Swaab DF. 2008. A sex difference in the hypothalamic uncinate nucleus: relationship to gender identity. *Brain*. 131:3132–3146.
- Giedd JN, Castellanos FX, Rajapakse JC, Vaituzis AC, Rapoport JL. 1997. Sexual dimorphism of the developing human brain. *Prog Neuropsychopharmacol Biol Psychiatry*. 21:1185–1201.
- Giedd JN, Clasen LS, Lenroot R, Greenstein D, Wallace GL, Ordaz S, Molloy EA, Blumenthal JD, Tossell JW, Stayer C, et al. 2006. Puberty-related influences on brain development. *Mol Cell Endocrinol*. 254–255:154–162.
- Goldstein JM, Seidman LJ, Horton NJ, Makris N, Kennedy DN, Caviness VS Jr, Faraone SV, Tsuang MT. 2001. Normal sexual dimorphism of the adult human brain assessed by in vivo magnetic resonance imaging. *Cereb Cortex*. 11:490–497.
- Good CD, Johnsrude I, Ashburner J, Henson RN, Friston KJ, Frackowiak RS. 2001. Cerebral asymmetry and the effects of sex and handedness on brain structure: a voxel-based morphometric analysis of 465 normal adult human brains. *Neuroimage*. 14:685–700.
- Green R, Keverne EB. 2000. The disparate maternal aunt-uncle ratio in male transsexuals: an explanation invoking genomic imprinting. *J Theor Biol*. 202:55–63.
- Helms G, Ciomas C, Kyaga S, Savic I. 2006. Increased thalamus levels of glutamate and glutamine (Glx) in patients with idiopathic generalised epilepsy. *J Neurol Neurosurg Psychiatry*. 77:489–494.
- Hodzie A, Kaas A, Muckli L, Stirn A, Singer W. 2009. Distinct cortical networks for the detection and identification of human body. *Neuroimage*. 45:1264–1271.
- Holzel BK, Ott U, Gard T, Hempel H, Weygandt M, Morgen K, Vait D. 2008. Investigation of mindfulness meditation practitioners with voxel-based morphometry. *Soc Cogn Affect Neurosci*. 3:55–61.
- Kinsey AC, Pomeroy WR, Martin CE. 2003. Sexual behavior in the human male. *Am J Public Health*. 93:894–898.
- Kovalev VA, Kruggel F, von Cramon DY. 2003. Gender and age effects in structural brain asymmetry as measured by MRI texture analysis. *Neuroimage*. 19:895–905.
- Kretschmann HJ, Weinrich W. 1995. Comprehensive and specialty practice-related education in preclinical teaching exemplified by neuroanatomy. *Med Klin (Munich)*. 90:166–169.
- Kruijver FP, Zhou JN, Pool CW, Hofman MA, Gooren LJ, Swaab DF. 2000. Male-to-female transsexuals have female neuron numbers in a limbic nucleus. *J Clin Endocrinol Metab*. 85:2034–2041.
- Lawrence AA. 2005. Sexuality before and after male-to-female sex reassignment surgery. *Arch Sex Behav*. 34:147–166.
- Leichnetz GR. 2001. Connections of the medial posterior parietal cortex (area 7m) in the monkey. *Anat Rec*. 263:215–236.
- Luders E, Gaser C, Narr KL, Toga AW. 2009. Why sex matters: brain size independent differences in gray matter distributions between men and women. *J Neurosci*. 29:14265–14270.
- Luders E, Narr KL, Thompson PM, Woods RP, Rex DE, Jancke L, Steinmetz H, Toga AW. 2005. Mapping cortical gray matter in the young adult brain: effects of gender. *Neuroimage*. 26:493–501.
- Luders E, Sanchez FJ, Gaser C, Toga AW, Narr KL, Hamilton LS, Vilain E. 2009. Regional gray matter variation in male-to-female transsexualism. *Neuroimage*. 46:904–907.
- Luders E, Toga AW, Lepore N, Gaser C. 2009. The underlying anatomical correlates of long-term meditation: larger hippocampal and frontal volumes of gray matter. *Neuroimage*. 45:672–678.
- Murphy DG, DeCarli C, McIntosh AR, Daly E, Mentis MJ, Pietrini P, Szczepanik J, Schapiro MB, Grady CL, Horwitz B, et al. 1996. Sex differences in human brain morphometry and metabolism: an in vivo quantitative magnetic resonance imaging and positron emission tomography study on the effect of aging. *Arch Gen Psychiatry*. 53:585–594.
- Neufang S, Specht K, Hausmann M, Gunturkun O, Herpertz-Dahlmann B, Fink GR, Konrad K. 2009. Sex differences and the impact of steroid hormones on the developing human brain. *Cereb Cortex*. 19:464–473.
- Nopoulos P, Flaum M, O’Leary D, Andreasen NC. 2000. Sexual dimorphism in the human brain: evaluation of tissue volume, tissue composition and surface anatomy using magnetic resonance imaging. *Psychiatry Res*. 98:1–13.
- Northoff G, Heinzel A, de Greck M, Bermpohl F, Dobrowolny H, Panksepp J. 2006. Self-referential processing in our brain—a meta-analysis of imaging studies on the self. *Neuroimage*. 31:440–457.
- Oldfield RC. 1971. The assessment and analysis of handedness: the Edinburgh inventory. *Neuropsychologia*. 9:97–113.
- Paus T, Tomaiuolo F, Otaky N, MacDonald D, Petrides M, Atlas J, Morris R, Evans AC. 1996. Human cingulate and paracingulate sulci: pattern, variability, asymmetry, and probabilistic map. *Cereb Cortex*. 6:207–214.
- Raz N, Gunning-Dixon F, Head D, Rodrigue KM, Williamson A, Acker JD. 2004. Aging, sexual dimorphism, and hemispheric asymmetry of the cerebral cortex: replicability of regional differences in volume. *Neurobiol Aging*. 25:377–396.
- Raz N, Gunning-Dixon F, Head D, Williamson A, Acker JD. 2001. Age and sex differences in the cerebellum and the ventral pons: a prospective MR study of healthy adults. *ANJR Am J Neuroradiol*. 22:1161–1167.
- Raz N, Lindenberger U, Rodrigue KM, Kennedy KM, Head D, Williamson A, Dahle C, Gerstorf D, Acker JD. 2005. Regional brain changes in aging healthy adults: general trends, individual differences and modifiers. *Cereb Cortex*. 15:1676–1689.
- Raz N, Torres IJ, Acker JD. 1995. Age, gender, and hemispheric differences in human striatum: a quantitative review and new data from in vivo MRI morphometry. *Neurobiol Learn Mem*. 63:133–142.
- Rekkas PV, Constable RT. 2005. Evidence that autobiographic memory retrieval does not become independent of the hippocampus: an fMRI study contrasting very recent with remote events. *J Cogn Neurosci*. 17:1950–1961.

- Savic I, Berglund H, Lindstrom P. 2005. Brain response to putative pheromones in homosexual men. *Proc Natl Acad Sci U S A*. 102:7356-7361.
- Savic I, Lindstrom P. 2008. PET and MRI show differences in cerebral asymmetry and functional connectivity between homo- and heterosexual subjects. *Proc Natl Acad Sci U S A*. 105:9403-9408.
- Schlaepfer TE, Harris GJ, Tien AY, Peng L, Lee S, Pearlson GD. 1995. Structural differences in the cerebral cortex of healthy female and male subjects: a magnetic resonance imaging study. *Psychiatry Res*. 61:129-135.
- Smith YL, van Goozen SH, Kuiper AJ, Cohen-Kettenis PT. 2005. Transsexual subtypes: clinical and theoretical significance. *Psychiatry Res*. 137:151-160.
- Swaab DF. 2007. Sexual differentiation of the brain and behavior. *Best Pract Res Clin Endocrinol Metab*. 21:431-444.
- Swaab DF, Gooren LJ, Hofman MA. 1992. Gender and sexual orientation in relation to hypothalamic structures. *Horm Res*. 2(Suppl 38):51-61.
- Toga AW, Thompson PM. 2003. Mapping brain asymmetry. *Nat Rev Neurosci*. 4:37-48.
- van Goozen SH, Slabbekoorn D, Gooren LJ, Sanders G, Cohen-Kettenis PT. 2002. Organizing and activating effects of sex hormones in homosexual transsexuals. *Behav Neurosci*. 116:982-988.
- Vestergaard-Poulsen P, van Beek M, Skewes J, Bjarkam CR, Stubberup M, Bertelsen J, Roepstorff A. 2009. Long-term meditation is associated with increased gray matter density in the brain stem. *Neuroreport*. 20:170-174.
- Watson C, Andermann F, Gloor P, Jones-Gotman M, Peters T, Evans A, Olivier A, Melanson D, Leroux G. 1992. Anatomic basis of amygdaloid and hippocampal volume measurement by magnetic resonance imaging. *Neurology*. 42:1743-1750.
- Yucel M, Stuart GW, Maruff P, Velakoulis D, Crowe SF, Savage G, Pantelis C. 2001. Hemispheric and gender-related differences in the gross morphology of the anterior cingulate/paracingulate cortex in normal volunteers: an MRI morphometric study. *Cereb Cortex*. 11:17-25.
- Zhou JN, Hofman MA, Gooren LJ, Swaab DF. 1995. A sex difference in the human brain and its relation to transsexuality. *Nature*. 378:68-70.