

How I treat central venous access device–related upper extremity deep vein thrombosis

Anita Rajasekhar¹ and Michael B. Streiff^{2,3}

¹Division of Hematology/Oncology, Department of Medicine, University of Florida, Gainesville, FL; and ²Division of Hematology, Department of Medicine and ³Department of Pathology, Johns Hopkins University School of Medicine, Baltimore, MD

Central venous access device (CVAD)-related thrombosis (CRT) is a common complication among patients requiring central venous access as part of their medical care. Complications of CRT include pulmonary embolism, recurrent deep venous thrombosis, loss of central venous access, and postthrombotic syndrome. Patient-, device-, and treatment-related factors can influence the risk of CRT. Despite numerous randomized controlled trials, the clinical benefit of

pharmacologic thromboprophylaxis for the prevention of CRT remains to be established. Therefore, minimizing patient exposure to known risk factors is the best available approach to prevent CRT. Venous duplex is recommended for the diagnosis of CRT. Anticoagulation for at least 3 months or the duration of the indwelling CVAD is recommended for treatment of CRT. Thrombolysis should be considered for patients at low risk for bleeding who have limb-threatening

thrombosis or whose symptoms fail to resolve with adequate anticoagulation. CVAD removal should be considered for patients with bacteremia, persistent symptoms despite anticoagulation, and if the CVAD is no longer needed. Superior vena cava filters should be avoided. Prospective studies are needed to define the optimal management of patients with or at risk for CRT. (*Blood*. 2017;129(20):2727-2736)

Introduction

Central venous access devices (CVADs) are essential to the care of many patients. CVADs facilitate the delivery of medications and blood products and provide venous access for hemodialysis, apheresis, and laboratory blood draws. CVADs can be inserted directly into a central vein, tunneled through subcutaneous tissues for more permanent access, or placed peripherally and threaded to a central location (eg, peripherally inserted central catheters [PICCs]). CVAD-related thrombosis (CRT) is the most common noninfectious complication of CVAD insertion. CRT is important because it leads to interruptions of therapy, increases the cost of care, and can precipitate chronic venous occlusion and loss of vascular access, postthrombotic syndrome (PTS), and, rarely, pulmonary embolism (PE). There are limited randomized controlled trials (RCTs) focused on the management of CRT so most recommendations are based on observational studies or extrapolation from studies of non-CVAD–related lower extremity deep vein thrombosis (LEDVT). In this article, we highlight 3 commonly encountered case scenarios to provide insight into the management of CRT in adults. Thrombotic complications of hemodialysis and apheresis catheters, nonthrombotic complications of CVAD, and CRT in pediatric patients will not be discussed.

Case 1

A 26-year-old male with a history of IV drug use is admitted for endocarditis. A PICC is inserted for IV antibiotics. Three weeks later, he presents with upper arm swelling and pain. On examination, his right upper arm is swollen, red, and tender, without signs of limb ischemia. A duplex ultrasound confirms a right upper extremity axillary vein deep

vein thrombosis (DVT). He is started on low–molecular-weight heparin (LMWH).

Case 2

A 45-year-old female with stage III colon adenocarcinoma has a left subclavian chest wall port placed for adjuvant chemotherapy. Two weeks after insertion, she develops swelling of the left upper arm and tenderness of the arm and neck on the side of the port. A duplex ultrasound confirms left subclavian vein thrombosis. She is started on LMWH.

Case 3

A 62-year-old male with a history of chronic obstructive lung disease is admitted to the intensive care unit (ICU) for respiratory failure due to bilateral pneumonia. Due to hemodynamic instability, a left subclavian vein central catheter is placed for IV access. Over a few days, he recovers with IV antibiotics. He is extubated on hospital day 5. On hospital day 7, he develops sudden pain and swelling of the left arm with bluish discoloration. On physical examination, his left arm is markedly swollen, violaceous, painful, and warm up to the axilla with livedo reticularis throughout. Duplex ultrasound reveals a large occlusive thrombus involving the brachial, axillary, and subclavian veins. He is not on any antiplatelet agents. His complete blood count as well as renal and hepatic function tests are normal. He has no current or prior history of bleeding. He is started on IV unfractionated heparin with no improvement.

How should these 3 patients be managed?

Submitted 20 August 2016; accepted 4 February 2017. Prepublished online as *Blood* First Edition paper, 3 April 2017; DOI 10.1182/blood-2016-08-693671.

© 2017 by The American Society of Hematology

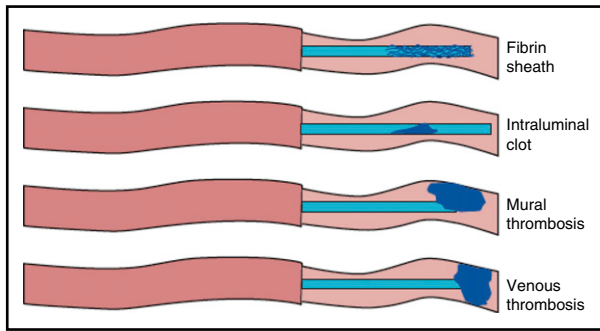


Figure 1. Type of CVAD-related thrombotic occlusions. Adapted from Baskin et al.¹

Pathophysiology

CVADs predispose patients to venous thrombosis because they impact each component of Virchow's triad: stasis, hypercoagulability, and endothelial injury. CVAD insertion results in local vessel wall injury, activating the coagulation and proinflammatory cascades. Continuous friction of CVADs against the vessel wall as well as turbulent inflow from the catheter and the toxic effects of some medications promote ongoing endothelial injury and thrombus formation. In addition, the presence of CVADs in the vessel lumen slows blood flow, leading to stasis. Finally, the synthetic materials used to construct CVADs likely activate coagulation as evidenced by the development of fibrin sheaths and catheter-associated thrombus soon after CVAD insertion.¹

Thrombus can form within, surrounding, or at the tip of the catheter (Figure 1). Fibrin sheaths, socklike structures that deposit on the external surface of the catheter, begin to form within 24 hours of insertion and can impair flow into and out of the catheter.¹ Intraluminal thrombus develops when blood refluxes into the catheter. These occlusions can be partial or complete and result from insufficient flushing, inadequate infusion rates, or frequent blood withdrawals. The majority of fibrin sheaths and intraluminal occlusions can be lysed with intraluminal instillation of 2 mg of alteplase. Mural thrombus forms on the vessel wall adjacent to the CVAD. CRT refers specifically to a DVT that partially or completely occludes the vein in which the catheter resides.¹

Epidemiology of CRT

The concept that upper extremity DVT (UEDVT) is rare and clinically insignificant is being reevaluated. Recent studies report that the incidence of UEDVT has more than doubled from <2% to 4% to 10% of all newly diagnosed DVTs.¹⁻⁵ The presence of CVAD is a strong independent risk factor for UEDVT (odds ratio [OR]: 14.0; 95% confidence interval [CI]: 5.9-33.2), and CRTs account for 50% to 90% of all UEDVTs.^{2,4-6} The incidence of CRT has been estimated at 0.4 to 1.0 per 10 000 persons.⁷ The majority of CRT occurs within 100 days of catheter placement.⁸

Risk factors for CRT

Many risk factors for CRT have been reported, but differences in study design, patient population, use of thromboprophylaxis, and outcome assessment have led to considerable variability in results. Risk factors for CRT can be grouped into device-, patient-, and treatment-related factors (Table 2).⁹⁻¹⁶ CRT risk varies by insertion site, with the femoral vein being the highest risk site, followed by the jugular vein and then the subclavian vein. In a multicenter RCT of 3027 adult ICU patients and 3471 CVAD insertions, symptomatic DVT was diagnosed more frequently with femoral vein catheters versus subclavian catheters (15 versus 5 cases, hazard ratio [HR]: 3.4 [95% CI: 1.2-9.3]) and jugular catheters (20 versus 9 cases, HR: 2.4 [95% CI: 1.1-5.4]) (pairwise comparisons).¹⁷ Similar findings have been noted in some^{18,19} but not all studies.²⁰ In their patient data-level meta-analysis of 5636 subjects with 425 CRTs, Saber et al²⁰ found that a subclavian insertion site was associated with a twofold increased risk of CRT compared with an upper arm insertion site. Unlike the previous studies, the meta-analysis by Saber et al²⁰ focused only on studies of cancer patients that primarily used tunneled Hickman catheters, ports, and PICCs as opposed to nontunneled central lines. In addition, only upper extremity sites were used in the included studies, and the median duration of insertion was 15 to 237 days compared with 5 to 11 days in the previous studies.¹⁷⁻²⁰

A meta-analysis of 11 studies found that PICCs were associated with a 2.5-fold higher risk of DVT than centrally-inserted venous catheters.²¹ Implanted ports were associated with a significantly lower

Table 1. Potential risk factors for CRT

Device-related factors	Patient-related factors	Treatment-related factors
Multiple insertion attempts ⁸	Malignancy Metastatic > localized ^{9,28}	Ongoing cancer therapy ^{3,22,25} Radiation therapy to the chest ⁹ Bolus (vs diluted) chemotherapy infusions ¹⁰ Antiangiogenic agents and platinum therapy ²⁹ Erythrocyte stimulating agents ²⁸
Catheter insertion site (femoral > jugular > subclavian) ^{6,11,17,20,28}	Recent trauma/surgery within 30 d ^{4,11}	
Large catheter size to vein diameter ratio ^{3,12}	History of VTE ^{11,20}	Parenteral nutrition ¹³
CVAD subtype (PICC > centrally inserted catheter > implanted port) ^{3,6,20,21}	End-stage renal disease ^{3,11,14}	Surgery ²⁵
Catheter infection ²⁴	Critically ill patients ²¹	
Improper catheter position (not at atriocaval junction) ²⁰	Systemic or catheter-related infection ^{4,24}	
No. of lumens and catheter size (6 F triple-lumen; >5 F double-lumen; >4 F single-lumen) ^{11,22,28}	Older age ¹⁹	
CVAD material (polyethylene or polyvinylchloride > silicone or polyurethane) ¹⁵	Immobilization within 30 d ⁴	
Previous CVAD ^{6,28}	Inherited thrombophilia ^{16,27,28}	

Table 2. Clinical outcomes of RCTs of CVAD thromboprophylaxis

Reference	Intervention	Thrombosis, n/N (%)	P	Symptomatic thrombosis, n/N (%)	P	Major bleeding, n/N (%)	P	Clinically relevant nonmajor bleeding, n/N (%)	P
30	Control	15/40 (37.5)	$P < .001$	13/40 (32.5)	NR	0/13	NR	0/29	NR
	Warfarin, 1 mg/d	4/42 (9.5)		4/42 (9.5)		1/16 (6)		3/55 (5.5)	
31	Control	8/13 (62)	$P = .002$	NR	NR	0/115	NR	0/43	NR
	Dalteparin, 2500 U/d	1/16 (6)		0/108		1/45 (2.2)			
32	Control		$P = .03$	15/115 (13)	NR	0/24	NR	0/29	NR
	Warfarin, 1 mg/d			5/108 (5)		0/130		3/55 (5.5)	
33	Control		$P = .42$	3/29 (10.3)	NR	1/21 (4.8)	NR	1/45 (2.2)	NR
	Warfarin, 1 mg/d			7/55 (12.8)		0/130		1/45 (2.2)	
34	Control		$P = .48$	5/43 (11.6)	NR	0/155	NR	0/43	NR
	Warfarin, 1 mg/d			8/45 (17.8)		0/155		1/45 (2.2)	
35	Warfarin, 1 mg/d	4/24 (16.7)	$P = .48$	2/24 (8.3)	NR	0/155	NR	0/43	NR
	Nadroparin, 2850 U/d	6/21 (28.8)		1/21 (4.8)		1/45 (2.2)			
36	Enoxaparin, 40 mg/d	22/155 (12.9)	RR: 0.78 (95% CI: 0.47-1.31); $P = .35$	2/155 (1.3)	RR: 0.32 (95% CI: 0.07-1.66)	0/155	NR	0/43	NR
	Placebo	28/155 (14.2)		6/155 (3.9)		0/155		1/45 (2.2)	
37	Warfarin, 1 mg/d		$P = .88$	6/130 (4.6)	HR: 1.20; (95% CI: 0.37-3.94)	0/130	NR	0/43	NR
	Placebo			5/125 (4)		3/125 (2.4)		1/45 (2.2)	
38	Dalteparin, 5000 U/d	21/294 (7.1)	NR	11/294 (3.7)	OR: 1.09 (95% CI: 0.37-3.19)	1/294 (0.3)	NR	2/56 (4)	NR
	Placebo	11/145 (7.6)		5/145 (3.4)		1/145 (0.7)		2/57 (4)	
39	Nadroparin, 2850 U	7/41 (17)	$P = .49$	0/41	NR	0/56	NR	2/56 (4)	NR
	Placebo	4/46 (9)		1/46 (2.2)		0/57		2/57 (4)	
40	Warfarin, 1 mg/d		RR: 0.99 (95% CI: 0.57-1.72), $P = .98$	24/408 (5.9)	RR: 0.99 (95% CI: 0.57-1.72), $P = .98$	7/408 (1.7)	RR: 6.93 (95% CI: 0.86-56.08), $P = .07$	2/56 (4)	NR
	No warfarin			24/404 (5.9)		1/404 (0.25)		2/57 (4)	
41	Warfarin (INR 1.5-2.0)		$P < .01$ (vs control)	13/473 (2.7)	RR: 0.38 (95% CI: 0.20-0.71), $P = .002$	16/473 (3.4)	RR: 2.28 (95% CI: 0.95-5.48), $P = .09$	0/29	NR
	Warfarin, 1 mg/d			34/471 (7.2)		7/471 (1.5)		0/29	
42	Acenocoumarin, 1 mg/d	24/114 (21.1)	$P = .57$	1/114 (0.9)	$P = .57$	0/114	NR	0/29	NR
	Dalteparin, 5000 U/d	48/120 (37.5)		3/120 (2.5)		0/120		0/29	
43	Control	57/114 (50)	$P = .05$ (vs control)	3/114 (2.6)	RR: 0.55 (95% CI: 0.31-0.96), $P = .0357$ (comparison of warfarin/LMWH vs control)	0/134	NR	0/43	NR
	Warfarin, 1 mg/d	8/134 (6)		0/134		0/134		0/43	
44	Prophylactic dose LMWH	14/138 (10)	$P = .0357$ (comparison of warfarin/LMWH vs control)	3/138 (2.2)	RR: 0.55 (95% CI: 0.31-0.96), $P = .0357$ (comparison of warfarin/LMWH vs control)	0/138	NR	0/43	NR
	Control	20/135 (14)		9/135 (6.7)		0/135		0/43	

NR, not reported.

Table 3. Summary of recommendations by clinical guidelines on the prevention and treatment of CRT

Guideline	Prevention	Treatment
ACCP 2012 ⁴⁴ , 2016 ^{49*}	In outpatients with cancer and indwelling CVAD, suggest against routine prophylaxis with LMWH or LDUH (grade 2B) or VKAs (grade 2C).	In patients with acute UEDVT: Recommend parenteral anticoagulation (LMWH, fondaparinux, IV UFH, or SC UFH) over no anticoagulation (grade 1B). Suggest LMWH or fondaparinux over IV UFH (grade 2C) and over SC UFH (grade 2B). Suggest anticoagulant therapy alone over thrombolysis (grade 2C). If thrombolysis is administered, recommend the same intensity and duration of anticoagulant therapy compared with nonthrombolysis patients (grade 1B). Suggest that the CVAD not be removed if it is functional and there is an ongoing need for the catheter (grade 2C). If CVAD is removed, 3 mo of anticoagulation is recommended over a longer duration of therapy in noncancer patients (grade 1B). The same approach is suggested in cancer patients (grade 2C). If CVAD is not removed, anticoagulation is recommended over stopping after 3 mo of treatment in cancer patients (grade 1C). The same approach is suggested in noncancer patients (grade 2C).
American Society of Clinical Oncology 2013 ⁴⁵	In cancer patients with CVADs: Routine thromboprophylaxis is not recommended. Routine CVAD flushing with saline is recommended. Data are insufficient to recommend routine thrombolytics to prevent catheter occlusion.	In cancer patients with CRT: t-PA is recommended to restore patency and preserve catheter function. CVAD removal is recommended if thrombosis does not respond to fibrinolytic therapy or if fibrinolytic or anticoagulation therapy is contraindicated. 3-6 mo of anticoagulant therapy with LMWH or LMWH followed by warfarin (INR, 2.0-3.0) is recommended for treatment of symptomatic CRT.
European Society for Medical Oncology 2015 ^{48†}	In cancer patients with CVADs: Routine thromboprophylaxis is not recommended. Prophylaxis with thrombolytic agents is not recommended (grade I, A). Saline flushing is recommended (grade III, C).	In cancer patients with CRT: LMWH is preferred over VKA (grade II, A). Anticoagulation treatment should be continued for the length of time the catheter is in use (grade III, C). If CVAD is nonfunctional, the CVAD should be removed after a short course (3-5 d) of anticoagulation (grade I, A). LMWH alone or LMWH followed by warfarin should be used for a minimum of 3-6 mo (grade I, C). After treatment of CRT, prophylactic doses of anticoagulation should be continued as long as the CVAD remains indwelling (grade I, C). Thrombolytic therapy is not routinely recommended (grade I, B).
International Guideline 2013 ^{46‡}	In cancer patients with CVADs: Routine thromboprophylaxis is not recommended (grade 1A). Catheters should be inserted on the right side, in the jugular vein, with catheter tip in the junction of the SVC and the right atrium (grade 1A).	In cancer patients with CRT: Anticoagulation is recommended for a minimum 3 mo. LMWHs are suggested but VKA can also be used. CVAD removal is not required if functional, well positioned, and not infected. Whether or not the CVAD is removed, no standard approach in terms of duration of anticoagulation is established (best clinical practice).

LDUH, low-dose unfractionated heparin; SC, subcutaneous; t-PA, tissue plasminogen activator; UFH, unfractionated heparin.

*Levels of evidence and grades of recommendation adapted from the ACCP-modified GRADE approach.⁷⁵

†Levels of evidence and grades of recommendation adapted from the Infectious Diseases Society of America-US Public Health Service Grading System.

‡Levels of evidence and grades of recommendations are based on the international GRADE approach.^{76,77}

§Levels of evidence and grading of recommendations are based on the NCCN categories of evidence and consensus.⁴⁷

Table 3. (continued)

Guideline	Prevention	Treatment
National Comprehensive Cancer Network 2013 ⁴⁷ §	In cancer patients with CVADs: Routine thromboprophylaxis is not recommended (grade 2A).	In cancer patients with CRT: Anticoagulation is recommended for as long as the CVAD remains indwelling. If the CVAD is removed, at least 3 mo of anticoagulation is recommended. Consider CVAD removal if symptoms persist, if the CVAD is nonfunctional, or if it is no longer necessary. Consider catheter-directed thrombolysis in select cases.

LDUH, low-dose unfractionated heparin; SC, subcutaneous; t-PA, tissue plasminogen activator; UFH, unfractionated heparin.

*Levels of evidence and grades of recommendation adapted from the ACCP-modified GRADE approach.⁷⁵

†Levels of evidence and grades of recommendation adapted from the Infectious Diseases Society of America-US Public Health Service Grading System.

‡Levels of evidence and grades of recommendations are based on the international GRADE approach.^{76,77}

§Levels of evidence and grading of recommendations are based on the NCCN categories of evidence and consensus.⁴⁷

risk for CRT compared with PICCs (OR: 0.43 [95% CI: 0.23-0.80]).²⁰ Larger PICCs (6 French [F] triple-lumen: 8.8%; >5 F double-lumen 2.9%; >4 F single-lumen: 0.6%) and brachial and cephalic vein insertion sites were associated with a greater risk for symptomatic CRT.^{3,22} Catheter tips dwelling above the proximal superior vena cava (SVC) have a sevenfold higher risk of CRT compared with catheter tips located closer to the right atrium.^{20,23} An indwell time of >2 weeks also increases the risk of CRT.²⁴

Patient-related factors also influence CRT risk. Older age and body mass index have been associated with increased risk, whereas sex and ethnicity have not.^{19,25} Cancer and ICU patients are at increased risk as are patients with CVAD-related infections.^{21,25,26} The presence of inherited thrombophilia as well as a personal history of venous thromboembolism (VTE) increase the risk of CRT.^{3,20,21,27} Treatment-related risk factors for CRT include chemotherapy and surgery, whereas therapeutic anticoagulation reduces the risk of thrombosis (relative risk [RR]: 0.47; 95% CI: 0.23-0.99).^{3,19,22,25}

Prevention of CRT

Prevention practices should target patient-, treatment-, and device-related risk factors for CRT (Table 1). For example, clinicians should use the smallest caliber catheter possible, ensure proper catheter tip location, and remove CVADs when they are no longer needed. Measures to prevent catheter-related infections can reduce CRT risk. Although flushing or locking catheters with heparin or saline has been standard practice for years, data demonstrating the effectiveness of these practices is lacking.²⁸ Anticoagulant thromboprophylaxis to prevent CRT has been the subject of multiple clinical trials (Table 2).³⁰⁻⁴² Early studies suggested that fixed low-dose warfarin (1 mg/d) or LMWH (dalteparin: 2500 U/d) was associated with reduced rates of CRT in cancer patients.^{30,31} However, more recent larger, prospective RCTs have failed to confirm these benefits.³⁵⁻³⁷

The WARP study, a large, open-label, multicenter RCT of CVAD thromboprophylaxis in cancer patients found that fixed low-dose warfarin (1 mg/d) did not reduce the rate of CRT (RR: 0.99; 95% CI: 0.57-1.72) compared with no warfarin. However, dose-adjusted warfarin (international normalized ratio [INR]: 1.5-2.0) was associated with a significant reduction in CRT (RR: 0.38; 95% CI: 0.20-0.71) compared with fixed-dose warfarin, albeit at the cost of a trend toward increased major bleeding (3.4% vs 1.5%; OR: 2.28;

95% CI: 0.95-5.48; *P* = .09).⁴⁰ Randomized controlled trials comparing LMWH with placebo have not demonstrated any benefit of thromboprophylaxis.^{36,38,39} A meta-analysis of CVAD thromboprophylaxis in cancer patients noted a reduction in symptomatic DVT with heparin and a reduction in asymptomatic DVT with vitamin K antagonists (VKAs), but no impact on infections, bleeding, or mortality, with low to moderate quality of evidence due to heterogeneous patient populations and low event rates.⁴³ Therefore, current evidence-based guidelines do not recommend routine thromboprophylaxis for cancer or noncancer patients with CVADs (Table 3).⁴⁴⁻⁴⁸ In our practice, we do not routinely use thromboprophylaxis in cancer patients with CVADs beyond standard catheter care, including the use of heparin or saline flushes.

Presentation

The majority of CRT patients are asymptomatic or present with CVAD dysfunction (inability to infuse or aspirate from the catheter) or fever from a CVAD-associated infection. Symptomatic CRT occurs in 1% to 5% of patients and typically presents with discomfort, edema, or discoloration at the catheter insertion site or in the ipsilateral upper extremity. Venous collaterals may be visible in the neck, arm, or chest. Septic thrombophlebitis can herald progression to CRT. Therefore, clinicians should examine the catheter entry site for signs of CVAD-related infection. CVADs are the most common nonmalignant cause of SVC syndrome, so facial or neck swelling, plethora, pain, headaches, or head fullness should prompt investigation for CRT.^{1,28}

Diagnosis

Clinical diagnosis of CRT is unreliable.⁵⁰ To standardize and optimize the clinical evaluation, Constans et al⁵¹ developed a clinical prediction rule to assess the pretest probability of UEDVT. The Constans clinical decision score uses a combination of 4 factors that were found to be associated with the risk of UEDVT. The presence of an IV device (pacemaker or central venous catheter) (1 point), localized pain (1 point), unilateral edema (1 point), or an alternative plausible cause for symptoms (−1 point) is used to calculate the

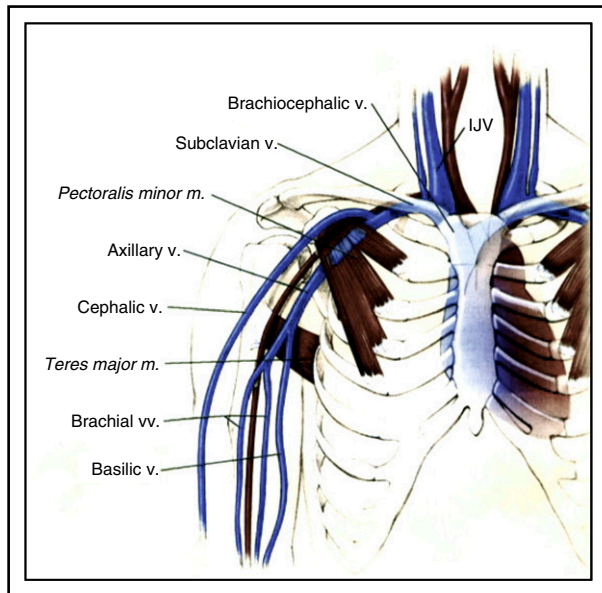


Figure 2. Schematic drawing of the venous anatomy of the upper extremity. IJV, internal jugular vein; m, muscle; v., vein; vv., veins. Adapted from Rumack et al.⁷⁴

Constans score. In a prospective management study of 406 patients, an unlikely Constans clinical decision score (0-1 point) in conjunction with a negative D-dimer was associated with a failure rate of 0% at 3 months follow-up (95% CI: 0.0%-4.2%).⁵² If these results are confirmed, this algorithm may become the standard diagnostic approach to UEDVT.

Although the reference standard for diagnosis of UEDVT is contrast venography, venous duplex ultrasonography remains the first-line diagnostic test for CRT. A systematic review of 793 patients from 17 studies with UEDVT reported a sensitivity and specificity of 97% and 96% for compression ultrasound, 84% and 94% for Doppler ultrasound, and 91% and 93% for duplex ultrasound, although the studies were small and heterogeneous.⁵³ Because the thoracic cavity and clavicle interfere with Doppler flow assessment and compression of the brachiocephalic and subclavian veins and the SVC (Figure 2), computed tomographic venography should be considered in patients with a negative ultrasound and high clinical suspicion of UEDVT. In patients with suspected UEDVT, the American College of Chest Physicians (ACCP) guideline recommends duplex ultrasound over other initial tests, including highly sensitive D-dimer or venography (grade 2C). If the ultrasound is negative and clinical suspicion remains high, additional testing with D-dimer, serial duplex ultrasound, or venography is advocated (grade 2C).⁵⁴

Treatment

The rationale for treatment of CRT is to reduce symptoms, preserve catheter function, minimize progressive/recurrent thromboembolism, and prevent PTS. Treatment strategies include catheter removal, anticoagulation, catheter-directed pharmacomechanical thrombolysis/thrombectomy, or surgical thrombectomy. Given the lack of level 1 data, recommendations are largely based on the results of LEDVT/PE treatment trials.

Anticoagulation

The preferred treatment of CRT is anticoagulation without CVAD removal. In a prospective, multicenter cohort study of 74 cancer patients, Kovacs et al⁵⁵ found that dalteparin/warfarin without CVAD removal was associated with no recurrence or extension of UEDVT and 3 major bleeding episodes (4%). In a retrospective cohort of 89 cancer patients treated with 1 month of full-dose LMWH (eg, dalteparin: 200 U/kg per day) followed by intermediate-dose LMWH (eg, dalteparin: 150 U/kg per day), Delluc et al⁵⁶ reported no recurrent DVT/PE and 2 major bleeds (3.7/100 patient-years [95% CI: -0.1 to 9.0]) during a median duration of anticoagulation of 124 days (range: 40-1849 days). In an analysis of CRT patients from the RIETE (Registro Informatizado de Enfermedad TromboEmbólica [Computerized Registry of Patients with Venous Thromboembolism]) registry, the incidence of recurrent DVT/PE and major bleeding was 7.0 per 100 patient-years and 8.9 per 100 patient-years, respectively. The incidence of fatal PE (1.85/100 patient-years) and bleeding (2.32/100 patient-years) were similar. A treatment duration of >90 days was associated with a 77% lower RR for recurrent DVT/PE.⁵⁷ In a systematic review of CRT, 7% experienced recurrent UEDVT or LEDVT and 2.8% suffered a PE. Major hemorrhage occurred in 4.9% of patients.²⁹

The results of these studies and RCTs of LEDVT and/or PE treatment serve as the evidence basis for the recommendations of 5 major evidence-based guidelines (Table 3). In general, the guidelines recommend initial anticoagulation for CRT involving proximal upper extremity deep veins (eg, axillary, subclavian, etc) rather than CVAD removal unless anticoagulation is contraindicated. Thromboembolic complications associated with DVTs distal to the axillary vein (eg, brachial vein) are less frequent. However, in the event that a CRT involving a distal arm vein is diagnosed and the CVAD is not removed, we would strongly consider using at least prophylactic doses of anticoagulation to prevent thrombus progression. If the CVAD is removed, we would favor clinical surveillance without anticoagulation.

LMWH is the preferred agent for CRT in cancer patients. If symptoms fail to improve or if there is a catheter-associated infection, then CVAD

Table 4. Authors' recommendations for management of CRT

Prevention	Diagnosis	Treatment
Place CVAD in subclavian > jugular > femoral insertion site.	Ultrasound to confirm suspected thrombosis.	Anticoagulation for 3 mo or until CVAD removed (whichever is longer).
Place port > Hickman > PICC.	No ultrasound surveillance.	Thrombolysis for limb-threatening CRT or severe symptoms and failure to respond to AC.
Place smallest caliber catheter necessary.	CT (or MRI) venography to confirm suspected thrombosis in patients with negative venous ultrasound.	CVAD removal if AC contraindicated or infected or no longer needed (add AC if contraindication resolves).
Place catheter tip at SVC-RA junction.		Avoid SVC filter use.
Do not use anticoagulant thromboprophylaxis.		Graduated compression garment for symptomatic upper extremity PTS but not PTS prevention.

AC, anticoagulation; CT, computed tomographic; MRI, magnetic resonance imaging; RA, right atrium.

removal should be considered. The guidelines recommend a minimum of 3 months of anticoagulation for CRT over shorter or longer durations, regardless of CVAD removal. If the CVAD is not removed, then anticoagulation should continue as long as the CVAD remains in place, rather than stopping at 3 months of treatment.⁴⁵⁻⁴⁹ The most recent update of the ACCP guidelines in 2016 gave a grade 2B recommendation for dabigatran, rivaroxaban, apixaban, and edoxaban over VKA therapy based on the greater convenience and accumulating evidence that direct oral anticoagulant (DOACs) have similar efficacy in noncancer patients and an improved adverse event profile, particularly less intracranial bleeding. For noncancer patients who are not treated with a DOAC, VKA therapy is still recommended over LMWH (Grade 2C).⁴⁹ Although there are no published studies of DOACs in the treatment of CRT, we believe the results of large, prospective RCTs of DOACs in the treatment of LEDVT with or without PE support their consideration in the acute and long term treatment of non-cancer patients with CRT.⁵⁸⁻⁶²

One challenging scenario is anticoagulation in a patient with VTE and severe thrombocytopenia (<50 000 per μL). A recent abstract presented at the 2016 American Society of Hematology meeting retrospectively evaluated 3 anticoagulation strategies in such patients: (1) therapeutic dose anticoagulation with platelet transfusions to maintain a platelet count of >40 000 to 50 000 per μL , (2) no anticoagulation, and (3) reduced or prophylactic dose anticoagulation. At 100 days, clinically significant bleeding and recurrent VTE occurred in 27% and 2% of patients receiving any anticoagulation, respectively, vs 3% and 15% when anticoagulation was withheld, respectively. Eighty-five percent of bleeding events occurred before day 30, and 83% of recurrent VTEs were diagnosed after day 40. The median platelet count proximate to the bleeding event was 38 000 per μL . The authors concluded that the risk of bleeding outweighed the risk of recurrent VTE in the short term, whereas the risk of VTE exceeded the risk of bleeding at later time points.⁶³ Although these data warrant replication, we believe clinicians should consider dynamic risk-adapted anticoagulation strategies when treating CRT in patients with significant thrombocytopenia. Because the risk of PE is less with UEDVT, we favor holding anticoagulation or using only prophylactic dose anticoagulation until the platelet count recovers to >50 000 per μL .⁶³ A risk-adjusted approach is supported by the guidance document from the International Society of Thrombosis and Haemostasis.⁶⁴

Catheter removal

For CRT patients that no longer need central venous access, the 2016 ACCP guidelines recommend CVAD removal.⁴⁹ No specific recommendation is provided regarding the duration of anticoagulation prior to removal to minimize the risk of embolization. Reasons to remove the catheter include concomitant CVAD-related infection, failure of symptoms to resolve with anticoagulation alone, or no need for continued vascular access. Although there are no data to provide guidance, we believe an initial period of anticoagulation (at least 7 days if possible) prior to CVAD removal is preferred to prevent thromboembolism and should be considered on a case-by-case basis based on the location and size of the thrombus burden, the risk for embolization and related complications upon CVAD removal, as well as the risk of bleeding with anticoagulation and the potential complications resulting from delayed removal (ie, CVAD-associated sepsis).⁶⁵ Guidelines recommend at least 3 months of anticoagulation after CVAD removal.⁴⁵⁻⁴⁹

SVC filters

In patients with contraindications to anticoagulation, some have recommended insertion of a SVC filter. At present, no vena cava filter has

been specifically approved for deployment in the SVC. When used, an SVC filter is placed at the junction of the left and right brachiocephalic veins. A systematic review of 209 patients with UEDVT and SVC filter insertion revealed a 3.8% risk of major complications, including SVC perforation, cardiac tamponade, SVC thrombosis, aortic perforation, and pneumothorax.⁶⁶ The relative infrequency of PE and fatal PE associated with UEDVT and the morbidity and mortality associated with SVC filters indicate that filters should not be used for CRT except in the most extreme circumstances. In this setting, we would favor CVAD removal. In patients with acute proximal lower extremity CRT and an absolute contraindication to anticoagulation, an inferior vena cava filter can be considered.

Thrombolysis

Catheter-directed thrombolysis (CDT) with or without the use of percutaneous mechanical thrombectomy devices (PMT) is generally considered only in patients with limb-threatening CRT or in the presence of severe persistent symptoms despite anticoagulation. Support for the efficacy of CDT with or without PMT comes primarily from studies of extensive LEDVT. In patients with acute LEDVT, successful lysis of thrombus can be achieved in 80% to 90% subjects with CDT.⁶⁷ In the multicenter RCT CAVENT study, CDT was associated with a 28% absolute risk reduction of PTS compared with anticoagulation alone, although it is important to note that 5-year follow-up data were available for only 84% of the original study population.⁶⁸ In a retrospective cohort of 30 patients with acute UEDVT treated with CDT, Vik et al⁶⁹ achieved >90% clot lysis in 20 patients (67%) and >50% clot lysis in 29 patients (97%). No PE occurred, and major bleeding occurred in 3 (10%) patients.⁶⁹ In a retrospective series of 68 patients with UEDVT (33 associated with CVAD), Maleux et al⁷⁰ reported >90% clot lysis in 62 patients (91%) and major bleeding in 1 patient (fatal intracranial bleed) with metastatic cancer. Schindler et al used a regional infusion of urokinase (75-150 000 U/h for 24-96 hours) to treat 18 patients who developed CRT. Eight patients (44%) developed complete resolution of symptoms, and 9 patients (50%) achieved $\geq 50\%$ clot lysis. One patient (5.6%) developed a major gastrointestinal bleed.⁷¹

These data suggest that CDT with or without PMT can be considered in carefully selected patients. The 2016 ACCP guidelines recommend anticoagulant therapy alone over thrombolysis in patients with acute UEDVT that involves the axillary or more proximal veins (grade 2C). They suggest that thrombolysis be considered only in patients who meet all the following criteria: severe symptoms, extent of thrombus from subclavian to axillary vein, symptoms <14 days, good performance status, life expectancy ≥ 1 year, and low risk for bleeding.⁴⁹ Risk factors for bleeding include recent or active bleeding, recent major surgery/trauma, hepatic dysfunction, thrombocytopenia, a bleeding disorder, cardiopulmonary resuscitation, and lesions in organs at high risk for life-threatening bleeding (eg, brain metastasis). In selecting patients for CDT with or without PMT, careful attention must be paid to the risk/benefit profile of each patient.⁷² The timing of thrombolysis should be determined on a case-by-case basis, weighing the severity and extent of the patient's clot and their risk of bleeding. The duration and intensity of anticoagulation for CRT remain the same regardless of whether CDT is undertaken or not (grade 1B).⁴⁹

Complications of CRT

CRT is associated with a number of clinically relevant complications, including catheter dysfunction, recurrent DVT, PE, PTS, and anticoagulation-associated bleeding. In the RIETE registry, the rate

of recurrent (upper extremity and lower extremity) DVT during and after therapy was 2.83 and 2.88 per 100 patient years, respectively.⁵⁷ An important long-term consequence of recurrent CRT is the loss of central venous access, which can have significant implications for patient management and outcomes. Although PE is 4.6-fold more common with LEDVT than UEDVT, the frequency of symptomatic PE associated with UEDVT was 5.4% in 1 meta-analysis.⁶⁶ Among 558 patients with CRT in the RIETE registry, 45 cases (8.1%) were associated with initial symptomatic PE, including 1 fatal PE.⁵⁷

Risk factors for recurrent DVT/PE among patients with CRT in the RIETE registry included PE at presentation (HR: 2.41 [90% CI: 0.98-5.94]) and a creatinine clearance <60 mL/min (HR: 3.93 [90% CI: 2.00-7.70]). Age >65 years (HR: 0.23 [90% CI: 0.10-0.54]) and a duration of anticoagulation >90 days (HR: 0.23 [90% CI: 0.10-0.56]) were associated with a reduced risk of recurrent VTE, whereas the presence of transient risk factors was associated with a reduced risk of recurrent DVT (HR: 0.07 [90% CI: 0.01-0.45]). Most recurrent thrombotic events occurred within the first 2 months of therapy. After completion of anticoagulation, recurrent DVT/PE occurred at a rate of 1.4% to 1.8% per year.⁵⁷

CRT is also complicated by PTS. A 2006 meta-analysis found that the weighted mean frequency of PTS after UEDVT was 15% (range: 7% to 46%). Risk factors for PTS after UEDVT include residual thrombosis on ultrasound (HR: 4.0 [95% CI: 1.1-15.0]) and involvement of the axillary and subclavian veins (HR: 2.9 [95% CI: 0.8-10.7]). CRT may be associated with a lower risk of PTS compared with other UEDVT.⁷³ The 2016 ACCP guideline does not recommend the use of graduated compression stockings, sleeves, or bandages for patients with acute symptomatic UEDVT. However, in light of the limited data on the utility of these measures in patients with UEDVT, clinicians may consider these strategies in select patients in whom their benefits are judged to exceed their harms and costs (grade 2C).⁴⁹

Cases revisited

Case 1

This patient's right upper extremity swelling begins to decrease with initiation of LMWH. He needs a PICC for 3 more weeks to complete his course of antibiotics, so his CVAD is left in place. For long-term anticoagulation, he is switched to a DOAC. After completion of his antibiotics, his PICC is removed, and his DOAC is continued to complete a 3-month treatment course. His upper extremity swelling completely resolves.

Case 2

This patient suffered a provoked left subclavian vein DVT due to her CVAD, her stage III colon cancer, and chemotherapy. She has an ongoing need for central venous access. Therefore, anticoagulation alone is initiated. LMWH is the preferred agent for her malignancy-

associated VTE. Because she will continue to receive chemotherapy for at least 6 more months, her course of anticoagulation will continue until her CVAD is removed, and not for just 3 months.

Case 3

A diagnosis of phlegmasia cerulea dolens is made based on physical exam findings and confirmation of a large clot burden by ultrasound. To prevent potentially irreversible venous gangrene and subsequent limb loss, CDT is initiated. This patient fulfills criteria for thrombolysis, including large proximal upper extremity thrombosis, preserved hepatic and renal function, low risk for bleeding, and diagnosis within ≤14 days of symptom onset. After 24 hours of thrombolysis, his arm swelling is markedly improved. CDT is discontinued, and he is switched to LMWH. His CVAD is removed. He recovers from his pneumonia and is discharged on a DOAC to complete a 3-month course of therapy. He wears a graduated compression garment to manage symptoms from residual upper extremity swelling.

In conclusion, CRT is an increasingly common cause of venous thromboembolism. To reduce the risk of CRT, clinicians should use CVADs only when necessary and minimize patient exposure to known risk factors for thrombosis. Currently, there is no indication for routine anticoagulant thromboprophylaxis in patients with CVADs. Ultrasound remains the preferred imaging study for objective confirmation of CRT. Computed tomographic venography should be considered in patients with negative ultrasound studies in whom clinical suspicion of CRT remains high. Anticoagulation without CVAD removal remains the preferred approach to treatment. CVAD removal is appropriate when symptoms fail to resolve with anticoagulation or when the device is no longer needed or catheter-related bacteremia is present. Thrombolysis should be reserved for patients at low risk for bleeding who have extensive limb-threatening thrombosis or persistence of severe symptoms despite a trial of anticoagulation. SVC filters are likely associated with more complications than benefits and thus are not recommended. Our approach to the management of CVAD-related thrombosis is outlined in Table 4.

Authorship

Contribution: A.R. and M.B.S. participated equally in the drafting and revision of the manuscript.

Conflict-of-interest disclosure: M.B.S. has consulted for Bio2-Medical, CSL Behring, Janssen, and Merck; has received research support from Janssen, PCORI, Portola, and Roche; and has provided expert witness testimony for various legal cases involving management of anticoagulation and venous thromboembolism. A.R. declares no competing financial interests.

Correspondence: Michael B. Streiff, Johns Hopkins University School of Medicine, 1830 East Monument St, Suite 7300, Baltimore, MD 21205; e-mail: mstreiff@jhmi.edu.

References

- Baskin JL, Pui CH, Reiss U, et al. Management of occlusion and thrombosis associated with long-term indwelling central venous catheters. *Lancet*. 2009;374(9684):159-169.
- Muñoz FJ, Mismetti P, Poggio R, et al; RIETE Investigators. Clinical outcome of patients with upper-extremity deep vein thrombosis: results from the RIETE Registry. *Chest*. 2008;133(1):143-148.
- Evans RS, Sharp JH, Linford LH, et al. Risk of symptomatic DVT associated with peripherally inserted central catheters. *Chest*. 2010;138(4):803-810.
- Joffe HV, Kucher N, Tapson VF, Goldhaber SZ; Deep Vein Thrombosis (DVT) FREE Steering Committee. Upper-extremity deep vein thrombosis: a prospective registry of 592 patients. *Circulation*. 2004;110(12):1605-1611.
- Winters JP, Callas PW, Cushman M, Repp AB, Zakai NA. Central venous catheters and upper

- extremity deep vein thrombosis in medical inpatients: the Medical Inpatients and Thrombosis (MITH) Study. *J Thromb Haemost*. 2015;13(12):2155-2160.
6. Lee JA, Zierler BK, Zierler RE. The risk factors and clinical outcomes of upper extremity deep vein thrombosis. *Vasc Endovascular Surg*. 2012;46(2):139-144.
 7. Linnemann B, Lindhoff-Last E. Risk factors, management and primary prevention of thrombotic complications related to the use of central venous catheters. *Vasa*. 2012;41(5):319-332.
 8. Lee AY, Levine MN, Butler G, et al. Incidence, risk factors, and outcomes of catheter-related thrombosis in adult patients with cancer. *J Clin Oncol*. 2006;24(9):1404-1408.
 9. Verso M, Agnelli G, Kamphuisen PW, et al. Risk factors for upper limb deep vein thrombosis associated with the use of central vein catheter in cancer patients. *Intern Emerg Med*. 2008;3(2):117-122.
 10. Baglin TP, Boughton BJ. Central venous thrombosis due to bolus injections of antileukaemic chemotherapy. *Br J Haematol*. 1986;63(3):606-607.
 11. Malinoski D, Ewing T, Bhakta A, et al. Which central venous catheters have the highest rate of catheter-associated deep venous thrombosis: a prospective analysis of 2,128 catheter days in the surgical intensive care unit. *J Trauma Acute Care Surg*. 2013;74(2):454-460, discussion 461-462.
 12. Nifong TP, McDevitt TJ. The effect of catheter to vein ratio on blood flow rates in a simulated model of peripherally inserted central venous catheters. *Chest*. 2011;140(1):48-53.
 13. Kucher N. Clinical practice. Deep-vein thrombosis of the upper extremities. *N Engl J Med*. 2011;364(9):861-869.
 14. Marnejon T, Angelo D, Abu Abdou A, Gemmel D. Risk factors for upper extremity venous thrombosis associated with peripherally inserted central venous catheters. *J Vasc Access*. 2012;13(2):231-238.
 15. Gallieni M, Pittiruti M, Biffi R. Vascular access in oncology patients. *CA Cancer J Clin*. 2008;58(6):323-346.
 16. Martinelli I, Battaglioli T, Bucciarelli P, Passamonti SM, Mannucci PM. Risk factors and recurrence rate of primary deep vein thrombosis of the upper extremities. *Circulation*. 2004;110(5):566-570.
 17. Parienti JJ, Mongardon N, Mégarbane B, et al; 3SITES Study Group. Intravascular Complications of Central Venous Catheterization by Insertion Site. *N Engl J Med*. 2015;373(13):1220-1229.
 18. Merrer J, De Jonghe B, Golliot F, et al; French Catheter Study Group in Intensive Care. Complications of femoral and subclavian venous catheterization in critically ill patients: a randomized controlled trial. *JAMA*. 2001;286(6):700-707.
 19. Timsit JF, Farkas JC, Boyer JM, et al. Central vein catheter-related thrombosis in intensive care patients: incidence, risks factors, and relationship with catheter-related sepsis. *Chest*. 1998;114(1):207-213.
 20. Saber W, Moua T, Williams EC, et al. Risk factors for catheter-related thrombosis (CRT) in cancer patients: a patient-level data (IPD) meta-analysis of clinical trials and prospective studies. *J Thromb Haemost*. 2011;9(2):312-319.
 21. Chopra V, Anand S, Hickner A, et al. Risk of venous thromboembolism associated with peripherally inserted central catheters: a systematic review and meta-analysis. *Lancet*. 2013;382(9889):311-325.
 22. Chopra V, Fallouh N, McGuirk H, et al. Patterns, risk factors and treatment associated with PICC-DVT in hospitalized adults: A nested case-control study. *Thromb Res*. 2015;135(5):829-834.
 23. Luciani A, Clement O, Halimi P, et al. Catheter-related upper extremity deep venous thrombosis in cancer patients: a prospective study based on Doppler US. *Radiology*. 2001;220(3):655-660.
 24. van Rooden CJ, Rosendaal FR, Barge RM, et al. Central venous catheter related thrombosis in haematology patients and prediction of risk by screening with Doppler-ultrasound. *Br J Haematol*. 2003;123(3):507-512.
 25. Leung A, Heal C, Perera M, Pretorius C. A systematic review of patient-related risk factors for catheter-related thrombosis. *J Thromb Thrombolysis*. 2015;40(3):363-373.
 26. van Rooden CJ, Schippers EF, Barge RM, et al. Infectious complications of central venous catheters increase the risk of catheter-related thrombosis in hematology patients: a prospective study. *J Clin Oncol*. 2005;23(12):2655-2660.
 27. Dentali F, Gianni M, Agnelli G, Ageno W. Association between inherited thrombophilic abnormalities and central venous catheter thrombosis in patients with cancer: a meta-analysis. *J Thromb Haemost*. 2008;6(1):70-75.
 28. Geerts W. Central venous catheter-related thrombosis. *Hematology Am Soc Hematol Educ Program*. 2014;2014(1):306-311.
 29. Baumann Kreuziger L, Onwuemene O, Kolesar E, Crowther M, Lim W. Systematic review of anticoagulant treatment of catheter-related thrombosis. *Thromb Res*. 2015;136(6):1103-1109.
 30. Bern MM, Lokich JJ, Wallach SR, et al. Very low doses of warfarin can prevent thrombosis in central venous catheters. A randomized prospective trial. *Ann Intern Med*. 1990;112(6):423-428.
 31. Monreal M, Alastrue A, Rull M, et al. Upper extremity deep venous thrombosis in cancer patients with venous access devices—prophylaxis with a low molecular weight heparin (Fragmin). *Thromb Haemost*. 1996;75(2):251-253.
 32. Boraks P, Seale J, Price J, et al. Prevention of central venous catheter associated thrombosis using minidose warfarin in patients with haematological malignancies. *Br J Haematol*. 1998;101(3):483-486.
 33. Ratcliffe M, Broadfoot C, Davidson M, Kelly KF, Greaves M. Thrombosis, markers of thrombotic risk, indwelling central venous catheters and antithrombotic prophylaxis using low-dose warfarin in subjects with malignant disease. *Clin Lab Haematol*. 1999;21(5):353-357.
 34. Heaton DC, Han DY, Inder A. Minidose (1 mg) warfarin as prophylaxis for central vein catheter thrombosis. *Intern Med J*. 2002;32(3):84-88.
 35. Mismetti P, Mille D, Laporte S, et al; CIP Study Group. Low-molecular-weight heparin (nadroparin) and very low doses of warfarin in the prevention of upper extremity thrombosis in cancer patients with indwelling long-term central venous catheters: a pilot randomized trial. *Haematologica*. 2003;88(1):67-73.
 36. Verso M, Agnelli G, Bertoglio S, et al. Enoxaparin for the prevention of venous thromboembolism associated with central vein catheter: a double-blind, placebo-controlled, randomized study in cancer patients. *J Clin Oncol*. 2005;23(18):4057-4062.
 37. Couban S, Goodyear M, Burnell M, et al. Randomized placebo-controlled study of low-dose warfarin for the prevention of central venous catheter-associated thrombosis in patients with cancer. *J Clin Oncol*. 2005;23(18):4063-4069.
 38. Karthaus M, Kretzschmar A, Kröning H, et al. Dalteparin for prevention of catheter-related complications in cancer patients with central venous catheters: final results of a double-blind, placebo-controlled phase III trial. *Ann Oncol*. 2006;17(2):289-296.
 39. Niers TM, Di Nisio M, Klerk CP, Baarslag HJ, Büller HR, Biemond BJ. Prevention of catheter-related venous thrombosis with nadroparin in patients receiving chemotherapy for hematologic malignancies: a randomized, placebo-controlled study. *J Thromb Haemost*. 2007;5(9):1878-1882.
 40. Young AM, Billingham LJ, Begum G, et al; WARP Collaborative Group, UK. Warfarin thromboprophylaxis in cancer patients with central venous catheters (WARP): an open-label randomised trial. *Lancet*. 2009;373(9663):567-574.
 41. De Cicco M, Matovic M, Balestreri L, et al. Early and short-term acenocumarine or dalteparin for the prevention of central vein catheter-related thrombosis in cancer patients: a randomized controlled study based on serial venographies. *Ann Oncol*. 2009;20(12):1936-1942.
 42. Lavau-Denes S, Lacroix P, Maubon A, et al. Prophylaxis of catheter-related deep vein thrombosis in cancer patients with low-dose warfarin, low molecular weight heparin, or control: a randomized, controlled, phase III study. *Cancer Chemother Pharmacol*. 2013;72(1):65-73.
 43. Akl EA, Vasireddi SR, Gunukula S, et al. Anticoagulation for patients with cancer and central venous catheters. *Cochrane Database Syst Rev*. 2011;(4):CD006468.
 44. Kahn SR, Lim W, Dunn AS, et al. Prevention of VTE in nonsurgical patients: Antithrombotic Therapy and Prevention of Thrombosis, 9th ed: American College of Chest Physicians Evidence-Based Clinical Practice Guidelines. *Chest*. 2012;141(2 suppl):e195S-226S.
 45. Schiffer CA, Mangu PB, Wade JC, et al. Central venous catheter care for the patient with cancer: American Society of Clinical Oncology clinical practice guideline. *J Clin Oncol*. 2013;31(10):1357-1370.
 46. Debourdeau P, Farge D, Beckers M, et al. International clinical practice guidelines for the treatment and prophylaxis of thrombosis associated with central venous catheters in patients with cancer. *J Thromb Haemost*. 2013;11(1):71-80.
 47. Streiff MB, Bockenstedt PL, Cataland SR, et al; National comprehensive cancer network. Venous thromboembolic disease. *J Natl Compr Canc Netw*. 2013;11(11):1402-1429.
 48. Sousa B, Furlanetto J, Hutka M, et al; ESMO Guidelines Committee. Central venous access in oncology: ESMO Clinical Practice Guidelines. *Ann Oncol*. 2015;26(suppl 5):v152-v168.
 49. Kearon C, Akl EA, Ornelas J, et al. Antithrombotic therapy for VTE disease: CHEST Guideline and Expert Panel Report [published correction appears in *Chest*. 2016;150(4):988]. *Chest*. 2016;149(2):315-352.
 50. Grant JD, Stevens SM, Woller SC, et al. Diagnosis and management of upper extremity deep-vein thrombosis in adults. *Thromb Haemost*. 2012;108(6):1097-1108.
 51. Constans J, Salmi LR, Sevestre-Pietri MA, et al. A clinical prediction score for upper extremity deep vein thrombosis. *Thromb Haemost*. 2008;99(1):202-207.
 52. Kleinjan A, Di Nisio M, Beyer-Westendorf J, et al. Safety and feasibility of a diagnostic algorithm combining clinical probability, d-dimer testing, and ultrasonography for suspected upper extremity deep venous thrombosis: a prospective management study. *Ann Intern Med*. 2014;160(7):451-457.
 53. Di Nisio M, Van Sluis GL, Bossuyt PM, Büller HR, Porreca E, Rutjes AW. Accuracy of diagnostic

- tests for clinically suspected upper extremity deep vein thrombosis: a systematic review. *J Thromb Haemost.* 2010;8(4):684-692.
54. Bates SM, Jaeschke R, Stevens SM, et al. Diagnosis of DVT: Antithrombotic Therapy and Prevention of Thrombosis, 9th ed: American College of Chest Physicians Evidence-Based Clinical Practice Guidelines. *Chest.* 2012; 141(2 suppl):e351S-e418S.
 55. Kovacs MJ, Kahn SR, Rodger M, et al. A pilot study of central venous catheter survival in cancer patients using low-molecular-weight heparin (dalteparin) and warfarin without catheter removal for the treatment of upper extremity deep vein thrombosis (The Catheter Study). *J Thromb Haemost.* 2007;5(8):1650-1653.
 56. Delluc A, Le Gal G, Scarvelis D, Carrier M. Outcome of central venous catheter associated upper extremity deep vein thrombosis in cancer patients. *Thromb Res.* 2015;135(2):298-302.
 57. Baumann Kreuziger L, Cote L, Verhamme P, et al; RIETE Investigators. A RIETE registry analysis of recurrent thromboembolism and hemorrhage in patients with catheter-related thrombosis. *J Vasc Surg Venous Lymphat Disord.* 2015;3(3):243-250. e1.
 58. Schulman S, Kearon C, Kakkar AK, et al; RE-COVER Study Group. Dabigatran versus warfarin in the treatment of acute venous thromboembolism. *N Engl J Med.* 2009;361(24):2342-2352.
 59. Bauersachs R, Berkowitz SD, Brenner B, et al; EINSTEIN Investigators. Oral rivaroxaban for symptomatic venous thromboembolism. *N Engl J Med.* 2010;363(26):2499-2510.
 60. Büller HR, Prins MH, Lensin AW, et al; EINSTEIN-PE Investigators. Oral rivaroxaban for the treatment of symptomatic pulmonary embolism. *N Engl J Med.* 2012;366(14):1287-1297.
 61. Agnelli G, Buller HR, Cohen A, et al; AMPLIFY Investigators. Oral apixaban for the treatment of acute venous thromboembolism. *N Engl J Med.* 2013;369(9):799-808.
 62. Büller HR, Décousus H, Grosso MA, et al; Hokusai-VTE Investigators. Edoxaban versus warfarin for the treatment of symptomatic venous thromboembolism. *N Engl J Med.* 2013;369(15):1406-1415.
 63. Houghton DE, Laux JP, Key NS, Zakai NA, Shea TC, Moll S. Treatment of venous thromboembolism in patients with hematological malignancies and severe thrombocytopenia: a retrospective cohort analysis [abstract]. *Blood.* 2016;128(22). Abstract 531.
 64. Carrier M, Khorana AA, Zwicker J, Noble S, Lee AY; Subcommittee on Haemostasis and Malignancy for the SSC of the ISTH. Management of challenging cases of patients with cancer-associated thrombosis including recurrent thrombosis and bleeding: guidance from the SSC of the ISTH. *J Thromb Haemost.* 2013;11(9):1760-1765.
 65. Limone BL, Hernandez AV, Michalak D, Bookhart BK, Coleman CI. Timing of recurrent venous thromboembolism early after the index event: a meta-analysis of randomized controlled trials. *Thromb Res.* 2013;132(4):420-426.
 66. Owens CA, Bui JT, Knuttinen MG, Gaba RC, Carrillo TC. Pulmonary embolism from upper extremity deep vein thrombosis and the role of superior vena cava filters: a review of the literature. *J Vasc Interv Radiol.* 2010;21(6):779-787.
 67. Mewissen MW, Seabrook GR, Meissner MH, Cynamon J, Labropoulos N, Houghton SH. Catheter-directed thrombolysis for lower extremity deep venous thrombosis: report of a national multicenter registry. *Radiology.* 1999;211(1):39-49.
 68. Haig Y, Enden T, Grøtta O, et al; CaVenT Study Group. Post-thrombotic syndrome after catheter-directed thrombolysis for deep vein thrombosis (CaVenT): 5-year follow-up results of an open-label, randomised controlled trial. *Lancet Haematol.* 2016;3(2):e64-e71.
 69. Vik A, Holme PA, Singh K, et al. Catheter-directed thrombolysis for treatment of deep venous thrombosis in the upper extremities. *Cardiovasc Intervent Radiol.* 2009;32(5):980-987.
 70. Maleux G, Marchal P, Palmers M, et al. Catheter-directed thrombolytic therapy for thoracic deep vein thrombosis is safe and effective in selected patients with and without cancer. *Eur Radiol.* 2010;20(9):2293-2300.
 71. Schindler J, Bona RD, Chen HH, et al. Regional thrombolysis with urokinase for central venous catheter-related thrombosis in patients undergoing high-dose chemotherapy with autologous blood stem cell rescue. *Clin Appl Thromb Hemost.* 1999;5(1):25-29.
 72. Vedantham S, Piazza G, Sista AK, Goldenberg NA. Guidance for the use of thrombolytic therapy for the treatment of venous thromboembolism. *J Thromb Thrombolysis.* 2016;41(1):68-80.
 73. Elman EE, Kahn SR. The post-thrombotic syndrome after upper extremity deep venous thrombosis in adults: a systematic review. *Thromb Res.* 2006;117(6):609-614.
 74. Rumack CM, Wilson SR, Charboneau JW, Levine D. Diagnostic Ultrasound. 4th ed. Philadelphia, PA: Elsevier Mosby; 2011:1035.
 75. Guyatt G, Gutterman D, Baumann MH, et al. Grading strength of recommendations and quality of evidence in clinical guidelines: report from an American College of Chest Physicians Task Force. *Chest.* 2006;129(1):174-181.
 76. Guyatt GH, Oxman AD, Kunz R, et al; GRADE Working Group. Rating quality of evidence and strength of recommendations: going from evidence to recommendations. *BMJ.* 2008; 336(7652):1049-1051.
 77. Guyatt GH, Oxman AD, Vist GE, et al; GRADE Working Group. GRADE: an emerging consensus on rating quality of evidence and strength of recommendations. *BMJ.* 2008;336(7650):924-926.