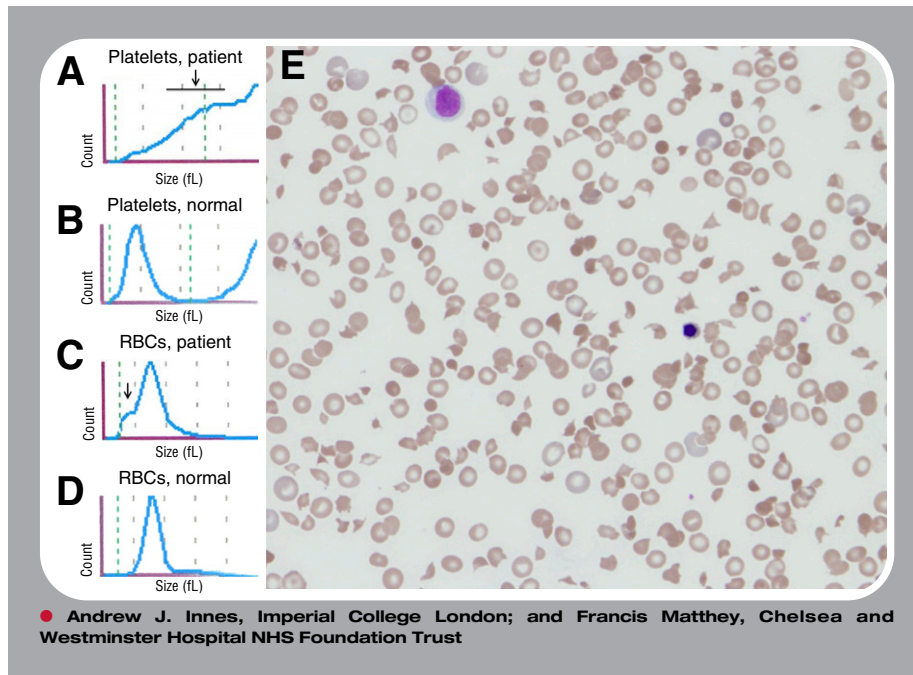


## Red cell fragments can mask severe thrombocytopenia



**A** 37-year-old man who had recently been treated for malaria while in Kenya presented with ongoing fevers and malaise as well as new headaches and hematuria. A complete blood count showed hemoglobin of 73 g/L, white blood count of  $14.7 \times 10^9/L$ , and platelets  $266 \times 10^9/L$ . There was also evidence of hemolysis (reticulocytosis, high lactate dehydrogenase, and hyperbilirubinemia) which, along with his history, was suggestive of severe malaria with blackwater fever. Importantly, although the platelet count by the impedance method seemed normal, the histograms were abnormal, with the presence of large particles in the platelet window (indicated by the black arrow in panel A [patient]; panel B, normal platelet count) and small particles in the red blood cell (RBC) window (indicated by the black arrow in panel C [patient]; panel D, normal platelet count). A peripheral blood smear (panel E; original magnification  $\times 40$ ; May-Grünwald-Giemsa stain) showed no malarial parasites but did show striking red cell changes, with polychromasia, florid fragmentation, microspherocytes, and severe thrombocytopenia. Platelet count by the optical method was  $20 \times 10^9/L$ , and the correct diagnosis of thrombotic thrombocytopenic purpura was made and subsequently confirmed with undetectable ADAMTS13 activity and an anti-ADAMTS13 antibody. Despite prompt treatment, the patient suffered cardiac arrest during plasma exchange and died.

The impedance method derives the platelet count from a continuous platelet/RBC histogram, which renders it susceptible to miscounting RBC fragments as platelets. Here, an optical platelet count and peripheral blood smear were critical in making the timely diagnosis of a life-threatening disease.