

controls immune suppression [Published correction appears in *Nature*. 2017; 542(7639):124]. *Nature*. 2016;539(7629): 437-442.

4. Weaver D, Spratt K, Pachter J, et al. Duvelisib inhibition of chemokines in patients with CLL (DUO study) and iNHL (DYNAMO study). *J Clin Oncol*. 2018; 36(suppl 15):12048.
5. O'Brien S, Patel M, Kahl BS, et al. Duvelisib, an oral dual PI3K- δ , γ inhibitor, shows clinical and pharmacodynamic activity in chronic lymphocytic leukemia and small lymphocytic lymphoma in a phase 1 study. *Am J Hematol*. 2018;93(11):1318-1326.
6. Jones JA, Robak T, Brown JR, et al. Efficacy and safety of idelalisib in combination with ofatumumab for previously treated chronic lymphocytic leukaemia: an open-label, randomised phase 3 trial. *Lancet Haematol*. 2017;4(3):e114-e126.
7. Sharman JP, Coutre SE, Furman RR, et al. Second interim analysis of a phase 3 study of idelalisib (ZYDELIG) plus rituximab (R)

for relapsed chronic lymphocytic leukemia (CLL): efficacy analysis in patient subpopulations with del(17p) and other adverse prognostic factors [abstract]. *Blood*. 2014;124(21). Abstract 330.

8. Coutre S, Barrientos J, Brown JR, et al. Safety of idelalisib in B-cell malignancies: integrated analysis of eight clinical trials [abstract]. *ASCO Meeting Abstracts*. 2015;33(suppl 15). Abstract e18030.
9. Brown J, Zelenetz A, Furman R, et al. Risk factors for grade 3/4 transaminase elevation in patients with chronic lymphocytic leukemia treated with idelalisib [abstract]. *Blood*. 2017; 130(suppl 1). Abstract 3016.
10. Lampson BL, Kasar SN, Matos TR, et al. Idelalisib given front-line for treatment of chronic lymphocytic leukemia causes frequent immune-mediated hepatotoxicity. *Blood*. 2016;128(2):195-203.

DOI 10.1182/blood-2018-10-879650

© 2018 by The American Society of Hematology

LYMPHOID NEOPLASIA

Comment on Perrot et al, page 2456

How deep is the myeloma iceberg?

Jesús F. San-Miguel and Bruno Paiva | Clínica Universidad de Navarra

In this issue of *Blood*, Perrot et al reveal that patients with multiple myeloma (MM) who are eligible for transplantation and have undetectable minimal residual disease (MRD) by next-generation sequencing (NGS) during maintenance therapy have excellent outcomes.¹

In 2016, the International Myeloma Working Group (IMWG) updated the response criteria and introduced definitions for MRD negativity based on NGS using the LymphoSIGHT platform (or validated equivalent method), flow cytometry using the EuroFlow standard operating procedure (or validated equivalent method), and positron emission tomography/computerized tomography (PET/CT).² Promising results using NGS were reported by Martínez-López et al in 2014,³ Korde et al in 2015,⁴ and Takamatsu et al in 2017.⁵ The results now reported by Perrot et al highlight the prognostic value of NGS-based MRD assessment in MM and establish it as the gold standard of molecular methods for evaluating treatment efficacy in this disease. NGS clearly superseded the applicability of allele-specific oligonucleotide polymerase chain reaction (ASO-PCR; >90% vs 60% to 75%, respectively),^{3,4,6} and the progression rate of patients

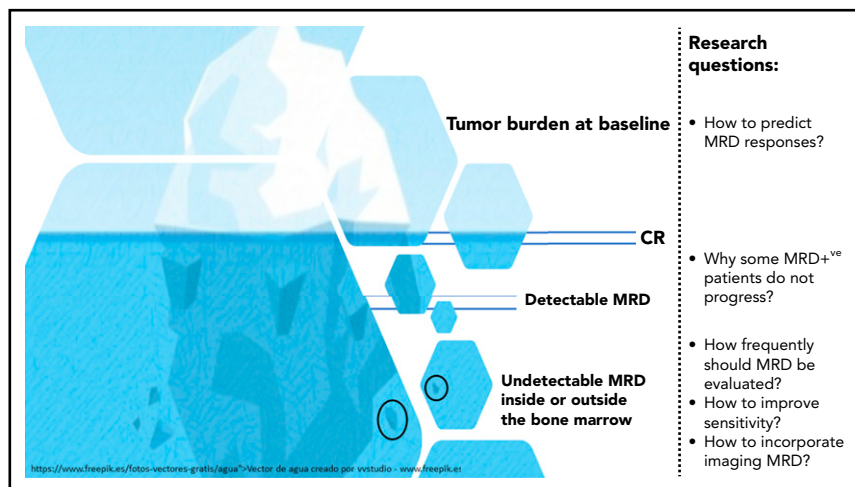
with undetectable MRD by NGS suggests a higher sensitivity of this method compared with ASO-PCR.⁶ Thus, the study by Perrot et al represents a milestone in NGS-based MRD, and it should stimulate complementary analyses to validate the other IMWG definitions for MRD negativity based on next-generation flow cytometry⁷ or PET/CT⁸ in large prospective series and assess whether these methods can match the ability of NGS to stratify risk in MM on the basis of patients' MRD status.

In this important study by Perrot et al, patients treated according to the Inter-groupe Francophone du Myélome (IFM) 2009 clinical trial⁹ who achieved undetectable MRD before maintenance therapy had an unprecedented reduction in the risk of progression and/or death of 78% after a median follow-up of 50 months. Furthermore, the benefit of

achieving MRD negativity was independent of treatment group (lenalidomide, bortezomib, and dexamethasone [RVD] vs transplant), cytogenetic risk profile, or International Staging System disease stage at diagnosis. These data confirm previous findings based on multiparameter flow cytometry (MFC)¹⁰ and have 2 relevant consequences. (1) Because the benefit of undetectable MRD is independent of treatment, MRD could potentially be used as a clinical and surrogate end point. This suggestion is supported by the IFM 2009 results because the higher rates of MRD negativity by NGS or MFC after transplantation correlated with the superiority of this arm vs RVD alone.⁹ (2) Risk is dynamic. Patients with high-risk disease at diagnosis may enjoy progression-free survival (PFS) similar to that of standard-risk patients upon the achievement of MRD negativity. Importantly, the opposite is also true; patients with standard-risk disease but with persistent MRD have a median PFS only ~12 months longer than that of patients with high-risk MM with persistent MRD.

In addition, patients who became MRD negative at the end of the 1-year maintenance regimen used in the IFM 2009 trial had outcomes similar to those who were already MRD negative before maintenance (supplemental Figure 8 in Perrot et al). These results suggest that achieving MRD responses with maintenance could be clinically relevant. At the same time, they also raise 2 important questions. (1) What would be the outcome of patients remaining or becoming MRD negative with more prolonged treatment? (2) How do we identify those patients who, despite remaining MRD positive, are benefiting from prolonged treatment because of surveillance of MRD clones?

Although a limitation of this study is the missing data (which the authors thoroughly addressed), perhaps the only sense of "slight disappointment" after its reading comes from the fact that, albeit at a much lower rate, patients with undetectable MRD continue to show a linear risk of relapse particularly after stopping treatment. Why have these patients progressed? Was the bone marrow sample inadequate? Was there extramedullary disease? How frequently should patients be monitored for MRD? How far does the limit of detection need to be pushed? How deep is the iceberg? (see figure).



Tumor burden in MM before and after therapy is illustrated here by an iceberg. The achievement of complete remission (CR) is represented by the disappearance of measurable disease above the surface. Below the surface, MRD detected by sensitive methods is clinically relevant because it increases the probability of disease progression. Despite having a risk that is significantly lower, patients with undetectable MRD continue to be at risk of disease progression, which underlies the fact that chemotherapy-resistant MM cells persist either inside or outside the bone marrow. Thus, several research questions (enumerated in the rightmost portion of the figure) remain to be addressed.

The MM-MRD community must continue working to answer these questions and build upon the seminal contribution made by Perrot et al in supporting the role of MRD as the most relevant clinical and surrogate end point.

Conflict-of-interest disclosure: J.F.S.-M. discloses participation in scientific advisory boards for Takeda, Janssen, Celgene, Novartis, Amgen, Bristol-Myers Squibb, Sanofi, Merck Sharp & Dohme, and Roche. B.P. discloses consulting fees from Celgene, Janssen, Merck, Novartis, and Takeda, funds for contracted research from Celgene, EngMab and Sanofi, and fees for non-continuing medical education/continuing education services from Amgen, Celgene, Janssen, and Takeda. ■

REFERENCES

- Perrot A, Lauwers-Cances V, Corre J, et al. Minimal residual disease negativity using deep sequencing is a major prognostic factor in multiple myeloma. *Blood*. 2018;132(23):2456-2464.
- Kumar S, Paiva B, Anderson KC, et al. International Myeloma Working Group consensus criteria for response and minimal residual disease assessment in multiple myeloma. *Lancet Oncol*. 2016;17(8):e328-e346.
- Martinez-Lopez J, Lahuerta JJ, Pepin F, et al. Prognostic value of deep sequencing method for minimal residual disease detection in multiple myeloma. *Blood*. 2014;123(20):3073-3079.
- Korde N, Roschewski M, Zingone A, et al. Treatment with carfilzomib-lenalidomide-dexamethasone with lenalidomide extension in patients with smoldering or newly diagnosed multiple myeloma. *JAMA Oncol*. 2015;1(6):746-754.
- Takamatsu H, Takezako N, Zheng J, et al. Prognostic value of sequencing-based minimal residual disease detection in patients with multiple myeloma who underwent autologous stem-cell transplantation. *Ann Oncol*. 2017;28(10):2503-2510.
- Puig N, Sarasquete ME, Balanzategui A, et al. Critical evaluation of ASO RQ-PCR for minimal residual disease evaluation in multiple myeloma. A comparative analysis with flow cytometry. *Leukemia*. 2014;28(2):391-397.
- Flores-Montero J, Sanoja-Flores L, Paiva B, et al. Next generation flow for highly sensitive and standardized detection of minimal residual disease in multiple myeloma. *Leukemia*. 2017;31(10):2094-2103.
- Moreau P, Attal M, Caillot D, et al. Prospective evaluation of magnetic resonance imaging and [¹⁸F]fluorodeoxyglucose positron emission tomography-computed tomography at diagnosis and before maintenance therapy in symptomatic patients with multiple myeloma included in the IFM/DFCI 2009 Trial: Results of the IMAJEM Study. *J Clin Oncol*. 2017;35(25):2911-2918.
- Attal M, Lauwers-Cances V, Hulin C, et al; IFM 2009 Study. Lenalidomide, bortezomib, and dexamethasone with transplantation for myeloma. *N Engl J Med*. 2017;376(14):1311-1320.
- Lahuerta JJ, Paiva B, Vidriales MB, et al; GEM (Grupo Español de Mieloma)/PETHEMA (Programa para el Estudio de la Terapéutica en Hemopatías Malignas) Cooperative Study Group. Depth of response in multiple myeloma: A pooled analysis of three PETHEMA/GEM clinical trials. *J Clin Oncol*. 2017;35(25):2900-2910.

DOI 10.1182/blood-2018-10-878637

© 2018 by The American Society of Hematology

MYELOID NEOPLASIA

Comment on Herrmann et al, page 2484

CiTE antibody for AML

Michael P. Rettig and John F. DiPersio | Washington University in St. Louis

In this issue of *Blood*, Herrmann et al¹ have developed a novel checkpoint inhibitory T-cell-engaging (CiTE) antibody for acute myeloid leukemia (AML) by fusing the extracellular domain of programmed cell death protein 1 (PD-1_{ex}) to a CD3 × CD33 bispecific T-cell engager (BiTE; see figure panels A-B). Incorporation of the PD-1_{ex} domain increased human T-cell activation and led to efficient cytotoxicity against CD33⁺/PD-L1⁺ cells in vitro and in a murine xenograft model. Importantly, the PD-1_{ex} domain is not sufficient to redirect T cells to PD-L1⁺ cells lacking the CD33 target. This preferential targeting of CD33⁺/PD-L1⁺ cells should reduce the immune-related adverse events associated with on-target/off-tumor effects of global checkpoint blockade with anti-PD1/PD-L1 monoclonal antibodies (mAbs).

T-cell recruiting antibody constructs like BiTEs are composed of the single-chain variable fragments (scFvs) of at least 2 antibodies of different specificities, one for a tumor-associated surface antigen, and the other for a surface antigen on an

effector cell, such as CD3ε on T cells (see figure panel A). Through their dual specificities, BiTEs bring tumor cells into close proximity to T-cell effectors in an HLA-independent fashion to form artificial synapses. These synapses induce activation