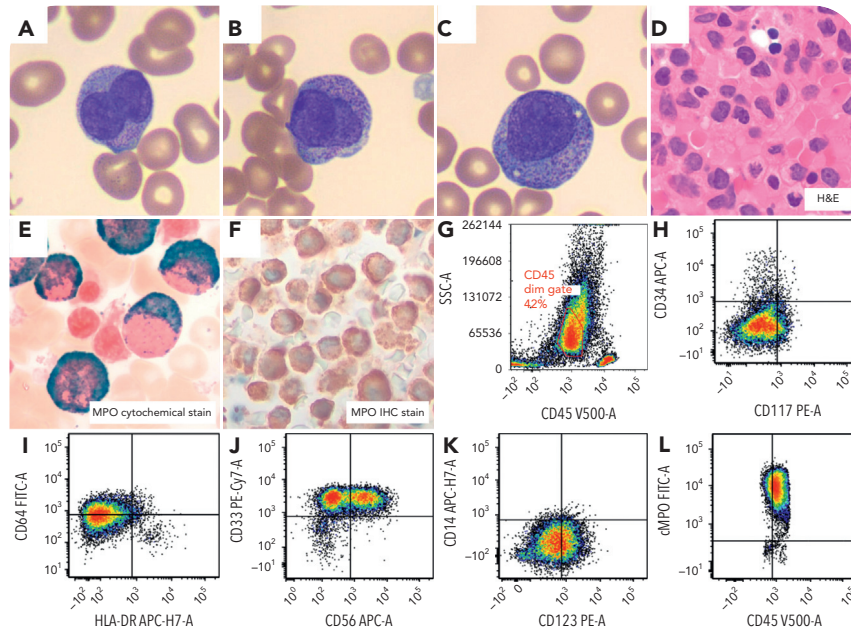


FISH-negative, karyotype-negative acute promyelocytic leukemia

Milagros L. Malaga, Universidad Católica de Santa María; and Luis F. Carrillo, Duke University



A 29-year-old woman with pancytopenia, worsening gum bleeding, bruising, and fatigue was referred for evidence of circulating blasts and concern for disseminated intravascular coagulation. Blood smear revealed atypical promyelocytes with bilobed nuclei and granules (panels A-C: Wright-Giemsa stain, 100× objective, original magnification ×1000). Bone marrow biopsy demonstrated increased promyelocytes (panel D: hematoxylin and eosin stain, 50× objective, original magnification ×500). Myeloperoxidase (MPO) cytochemical, and immunohistochemical stains were strongly positive (panels E-F: MPO cytochemistry, 100× objective, original magnification ×1000 [E]; immunohistochemistry, 50× objective, original magnification ×500 [F]). Flow-cytometry analysis showed a blast population with high side scatter merging with granulocytes and was CD34⁻, HLA-DR⁻, and MPO (bright⁺) (panels G-L). The findings were suggestive of acute promyelocytic leukemia (APL). The patient began to receive therapy with all-trans retinoic acid (ATRA). Fluorescence in situ

hybridization (FISH) analysis demonstrated 3 copies of the *RUNX1T1* locus (8q22) without translocation involving *PML::RARA*. The patient continued receiving ATRA therapy despite negative fusion. A FISH *RARA* break-apart probe revealed no rearrangement. Subsequent chromosome analysis showed an abnormal clone with trisomy 8 without t(15;17): 47,XX,+8[10]/46,XX[10]. A next-generation sequencing heme fusion panel detected *PML::RARA* fusion. The break-points in this case occur in the *bcr3* region of *PML* and the common intron 2 region of *RARA*. Diagnosis of APL was confirmed, and the patient began receiving arsenic trioxide therapy.

The mechanism resulting in the fusion event is likely a cryptic insertion. Such submicroscopic insertion events are a rare, but recurrent, mechanism of *PML::RARA* fusion formation with no reported associated morphologic or clinical differences.