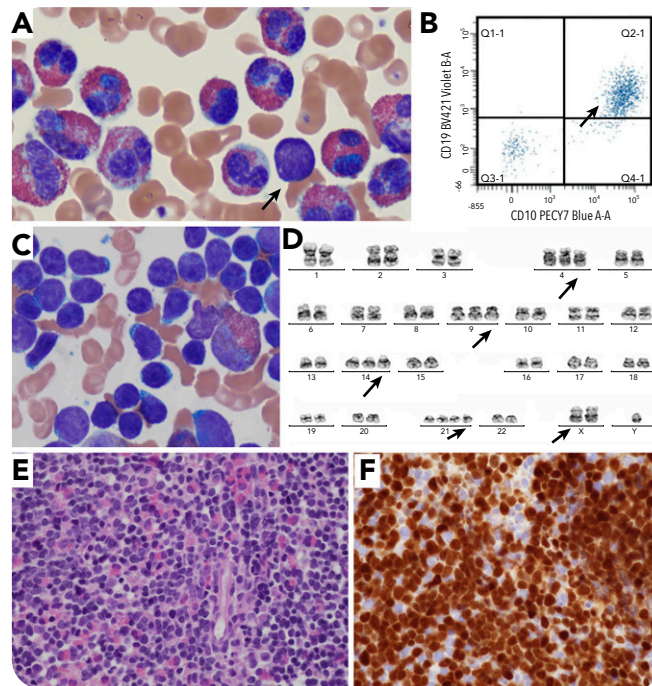


## Hyperdiploid B-lymphoblastic leukemia/lymphoma with hypereosinophilia and very few circulating lymphoblasts

Rahul Matnani and David Weissmann, Rutgers Robert Wood Johnson Medical School



A 13-year-old boy with autism spectrum disorder presented to the Emergency Department with left flank pain and hepatosplenomegaly. Laboratory workup showed an absolute eosinophil count of  $65\,280 \times 10^9/L$  and white blood cell count of  $88\,200 \times 10^9/L$  in the absence of anemia or thrombocytopenia. Peripheral smear review confirmed marked eosinophilia (75%) with very few (1%) circulating lymphoblasts (panel A; Wright-Giemsa, original magnification  $\times 100$ ), positive by flow cytometry for CD10 (bright) and CD19 (panel B), along with CD34, TDT, CD22, cCD79a, HLA-DR, CD9, CD58, and CD123. Bone marrow examination showed 70% to 80% involvement by B-lymphoblastic leukemia/lymphoma (B-ALL), with aspirate demonstrating sheets of blasts admixed with eosinophils/eosinophilic precursors (panel C; Wright-Giemsa, original magnification  $\times 100$ ). The core biopsy showed 70% to 80% B-ALL

lymphoblasts (panel E; hematoxylin and eosin, original magnification  $\times 40$ ), which are TDT positive (panel F; TDT, original magnification  $\times 40$ ), along with admixed eosinophils/eosinophilic precursors. The cytogenetic study showed high hyperdiploid karyotype:  $52,XY,+X,+4,+9,+14,+21,+21$  (panel D). The most common translocation  $t(5;14)(q31;q32)$  associated with B-ALL cases with hypereosinophilia, as well as relatively less common recurrent abnormalities such as translocation  $t(7;12)(q22;p13)$  and deletions involving 5q, 7q, were not identified.

The current study highlights the need for high suspicion of B-ALL and bone marrow examination in a hypereosinophilia case presenting with very few or no circulating lymphoblasts. The hyperdiploid karyotype is an example of cytogenetic diversity of B-ALL cases associated with hypereosinophilia.