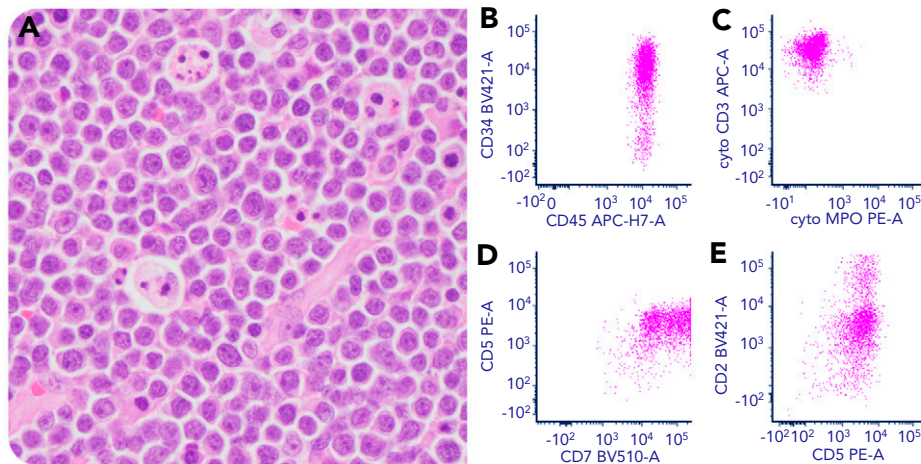


Posttransplant T lymphoblastic lymphoma mimicking Burkitt lymphoma

Jirong Mass and David C. Park, Columbia University Irving Medical Center



A 40-year-old man, 4 years status after single-lung transplant on tacrolimus, presented with cervical lymphadenopathy. A lymph node biopsy showed a diffuse monotonous infiltrate of medium-sized lymphoid cells with regular nuclei, finely clumped chromatin, multiple small basophilic nucleoli, and squared-off cytoplasmic borders in a starry-sky background highly reminiscent of Burkitt lymphoma (BL) (panel A, 40 \times objective, original magnification \times 400; hematoxylin and eosin stain). However, flow cytometry detected an abnormal immature T-cell population positive for CD34, cyCD3, CD2, CD5, CD7, and CD45 (panels B-E) but negative for CD10, terminal deoxynucleotidyl transferase, CD1a, and B-cell, myeloid (CD11c, CD13, CD33, and CD117) and other T-cell lineage-associated markers consistent with T lymphoblasts. Karyotype was abnormal: 46,XY,t(7;14)(p15;q32),del(9)(q21)[27]/46,XY[3]. Polymerase chain reaction analysis demonstrated a clonal T-cell

receptor β gene rearrangement. T lymphoblasts involved <10% of the bone marrow and peripheral blood cellularity. All Epstein-Barr virus (EBV) study results were negative. Staging positron emission tomography/computed tomography scan showed a 5-cm anterior mediastinal mass. The clinicopathologic findings supported a monomorphic T-cell posttransplant lymphoproliferative disorder, T lymphoblastic lymphoma (T-LBL), EBV negative. The patient completed a hyper-cyclophosphamide, vincristine, doxorubicin, and dexamethasone chemotherapy regimen and is in remission.

T-LBL after solid-organ transplant is particularly rare compared with BL. Furthermore, this case displayed histologic features highly suggestive of BL, a diagnostic pitfall, illustrating the importance of a multiparametric diagnostic approach.