

Null Results in Brief

Rectal Epithelial Apoptosis Does Not Predict Response to Sulindac Treatment or Polyp Development in Presymptomatic Familial Adenomatous Polyposis Patients¹

Josbert J. Keller,² G. Johan A. Offerhaus,
Linda M. Hyland, and Francis M. Giardiello

Department of Pathology, Academic Medical Center, 1105 AZ Amsterdam, The Netherlands [J. J. K., G. J. A. O.], and Department of Medicine, Johns Hopkins Medical Institutions, Baltimore, Maryland 21205 [L. M. H., F. M. G.]

Introduction

In normal colorectal epithelium, apoptosis occurs at the surface and proliferation is restricted to the lower base of the crypt. Inversion of this compartmentalization is an early event during the adenoma-carcinoma sequence (1).

FAP³ patients develop hundreds of adenomas and eventually colorectal carcinoma. The normal appearing colorectal mucosa of FAP patients is marked by altered cell kinetics with disturbance of the localization of proliferation and apoptosis (2, 3). Sulindac causes regression of adenomas in FAP patients (4), presumably through induction of apoptosis. We reported previously that sulindac decreases the ratio between apoptosis at the crypt base and at the surface apoptotic ratio (AR) in the normal rectal mucosa of FAP patients with adenoma regression on sulindac (5). One patient without reversal of the AR developed a “breakthrough carcinoma” during sulindac therapy, suggesting a potential role for this parameter as biomarker (5).

The hypothesis tested in the present study was that the change in AR is useful as an intermediate biomarker for response to sulindac treatment and adenoma development in presymptomatic FAP patients enrolled in a primary chemoprevention trial (6).

Materials and Methods

In a randomized trial, 41 FAP patients (confirmed by APC-mutational analysis) without colorectal adenomas were treated with sulindac 75–150 mg twice a day ($n = 21$) or placebo ($n = 20$; Ref. 6). The average age at enrollment was 14.3 years. Informed consent was obtained in accordance with the Johns Hopkins University Internal Review Board. At baseline and every 4 months, patients underwent sigmoidoscopy, and biopsies were taken. Representative rectal biopsies from normal mucosa, taken at baseline, and after 4 months and 2 years of

treatment were available from 32 patients. In the sulindac group, 4 of 15 and 6 of 15 patients developed adenomas at 4 months and 2 years of treatment, respectively. In the placebo group, 7 of 17 and 8 of 16 patients developed adenomas at 4 months and 2 years of treatment, respectively.

Apoptosis was assessed by one observer (J. J. K.) in a blinded fashion, counting apoptotic bodies in H&E sections, as described previously (5). The AI at the surface epithelium (AI_{surface}) and at the crypt base (AI_{crypt}; from the lowermost cell up to 20 cell positions along each side of the crypt) were assessed by dividing the number of apoptotic bodies by the number of cells. The AI_{overall} was calculated by adding the number of apoptotic bodies in both compartments, and dividing by the total number of cells. The AR was calculated as the AI_{crypt} divided by the AI_{surface}. The change in AI_{surface}, AI_{crypt}, AI_{overall}, and AR was expressed as [(post-treatment score + 1) – (pretreatment score + 1)]/(pretreatment score + 1). Comparisons between groups were made using the Mann-Whitney test. The effect of treatment was evaluated using the Wilcoxon test. All *P*s were two-sided. A *P* < 0.05 was considered statistically significant. The sample size of the clinical study was calculated (two-sided; 0.05 α ; and 80% power) to detect a difference of one SD in the number of polyps between treatment groups.

Results

In 88 biopsy samples of normal rectal mucosa, a total of 75,231 surface cells (mean, 854.9; SD, 367.0), 1,133 apoptotic bodies at the surface (mean, 12.9; SD, 8.0), 52,804 crypt cells (mean, 600.1; SD, 230.9), and 327 apoptotic bodies at the crypt (mean, 3.7; SD, 2.4) were counted. At baseline, the AR, AI_{surface}, AI_{crypt}, and AI_{overall} were not statistically significantly different between sulindac and placebo groups. At 4 months and 2 years of study, changes in these parameters were not significantly different between treatment groups. Also, at 4 months and 2 years of evaluation, there were no statistically significant differences in the AR, AI_{surface}, AI_{crypt}, and AI_{overall} between patients who developed colorectal adenomas and those who remained adenoma-free.

Discussion

Previously, we reported a relative increase in apoptosis at the surface compared with the crypt base (decreased AR, defined as: AI_{crypt}/AI_{surface}) in the normal rectal epithelium of FAP patients treated with sulindac (5). We hypothesized that alterations in the AR could serve as an intermediate biomarker to monitor sulindac treatment. However, the present investigation revealed no change in the AR in rectal epithelium of presymptomatic FAP patients on sulindac. Furthermore, apoptotic parameters failed to predict polyp development in either of the treatment arms.

Received 9/7/01; revised 10/26/01; accepted 11/16/01.

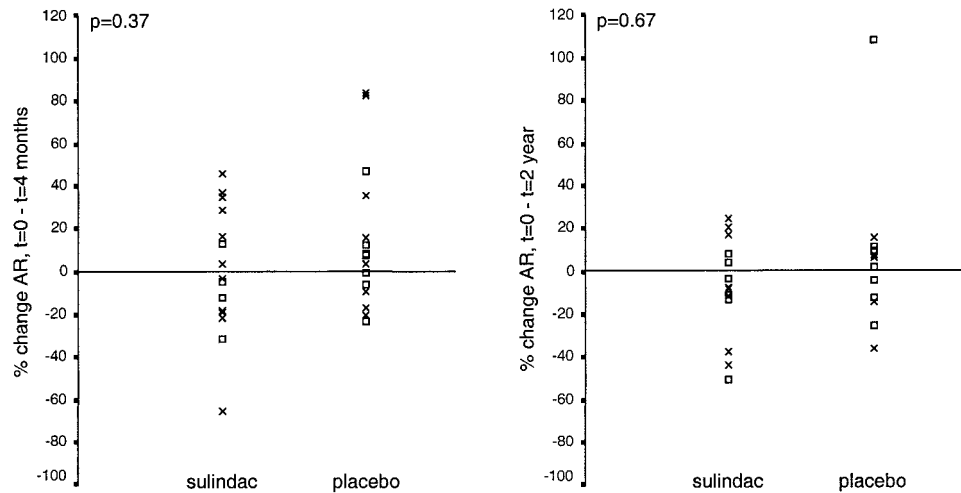
The costs of publication of this article were defrayed in part by the payment of page charges. This article must therefore be hereby marked *advertisement* in accordance with 18 U.S.C. Section 1734 solely to indicate this fact.

¹ This work was supported by a grant from The Netherlands Digestive Disease Foundation (WS 97-75); the Clayton Fund; the John G. Rangos, Sr. Charitable Foundation; Merck Company; and NIH Grant CA53801.

² To whom requests for reprints should be addressed, at Academic Medical Center, Department of Pathology, Meibergdreef 9, 1105 AZ Amsterdam, the Netherlands. E-mail: j.j.keller@amc.uva.nl.

³ The abbreviations used are: FAP, familial adenomatous polyposis; AR, apoptotic ratio; AI, apoptotic index.

Fig. 1. Percentage change in AR ($=AI_{\text{crypt}}/AI_{\text{surface}}$) in rectal epithelium of FAP patients after 4 months and after 2 years treatment with sulindac or placebo. The changes in AR of patients who developed adenomas are marked as \square ; the changes in AR of patients who did not develop adenomas are marked as \times .



The discrepancy between our previous study and the current investigation may be related to differences in study populations. In the former study, older FAP patients who had already developed adenomas were treated with sulindac, resulting in adenoma regression (4, 5). This investigation evaluated young, phenotypically negative FAP patients. The intestinal mucosa of FAP patients with adenomas harbors many macroscopically invisible dysplastic foci and may be considered transitional mucosa in which cell kinetics appear disturbed (2, 3). Our findings suggest that sulindac affects apoptosis in this type of epithelium and not in the mucosa of FAP patients without adenomas. However, neither macroscopic nor microscopic differences were appreciated between normal appearing mucosa of symptomatic and asymptomatic FAP patients.

The small sample size in this investigation may be considered a limitation. However, in contrast with our previous study, which evaluated fewer patients, the current investigation even failed to reveal a trend toward significance. Furthermore, using the above methodology, the observed heterogeneity in the "apoptotic response" (Fig. 1) precludes the use of apoptosis as a biomarker to monitor sulindac treatment or to predict adenoma development in presymptomatic FAP patients.

References

- Moss, S. F., Liu, T. C., Petrotos, A., Hsu, T. M., Gold, L. I., and Holt, P. R. Inward growth of colonic adenomatous polyps. *Gastroenterology*, 111: 1425–1432, 1996.
- Lipkin, M. Phase 1 and phase 2 proliferative lesions of colonic epithelial cells in diseases leading to colonic cancer. *Cancer*, 34: 878–888, 1974.
- Bedi, A., Pasricha, P. J., Akhtar, A. J., Barber, J. P., Bedi, G. C., Giardiello, F. M., Zehnbauser, B. A., Hamilton, S. R., and Jones, R. J. Inhibition of apoptosis during development of colorectal cancer. *Cancer Res.*, 55: 1811–1816, 1995.
- Giardiello, F. M., Hamilton, S. R., Krush, A. J., Piantadosi, S., Hyland, L. M., Celano, P., Booker, S. V., Robinson, C. R., and Offerhaus, G. J. Treatment of colonic and rectal adenomas with sulindac in familial adenomatous polyposis. *N. Engl. J. Med.*, 328: 1313–1316, 1993.
- Keller, J. J., Offerhaus, G. J., Polak, M., Goodman, S. N., Zahurak, M. L., Hyland, L. M., Hamilton, S. R., and Giardiello, F. M. Rectal epithelial apoptosis in familial adenomatous polyposis patients treated with sulindac. *Gut*, 45: 822–828, 1999.
- Giardiello, F. M., Yang, V. W., Hyland, L. M., Krush, A. J., Petersen, G. M., Trimbath, J. D., Piantadosi, S., Garrett, E., Geiman, D. E., Hubbard, W., Offerhaus, G. J., and Hamilton, S. R. Primary chemoprevention of familial adenomatous polyposis with sulindac. *N. Engl. J. Med.*, 346: 1054–1059, 2002.