

Increased Expression of Cyclooxygenase-2 Protein in 4-Nitroquinoline-1-oxide-induced Rat Tongue Carcinomas and Chemopreventive Efficacy of a Specific Inhibitor, Nimesulide¹

Hiroshi Shiotani, Ayumi Denda,² Kazuhiko Yamamoto, Wakashi Kitayama, Takehiro Endoh, Yasutaka Sasaki, Masahiro Tsutsumi, Masahito Sugimura, and Yoichi Konishi

Departments of Oncological Pathology [H. S., A. D., W. K., Y. S., M. T., Y. K.], and of Oral and Maxillofacial Surgery [H. S., K. Y., T. E., M. S.], Nara Medical University, Kashihara, Nara 634-8521, Japan

ABSTRACT

Expression of cyclooxygenase (COX)-2 protein in 4-nitroquinoline-1-oxide (4-NQO)-induced rat tongue lesions and the postinitiation chemopreventive potential of a selective COX-2 inhibitor, nimesulide (NIM), were examined in Fischer 344 male rats. NIM was administered in the diet at doses of 150, 300, and 600 ppm for 14 weeks after treatment with 25–35 ppm 4-NQO in the drinking water for 12 weeks. Western blot analysis revealed COX-2 protein to be barely expressed in the normal tongue epithelia, whereas it was increased ~6-fold in squamous cell carcinomas (SCCs). Immunohistochemically, COX-2 protein was diffusely present in SCCs and dysplasia but expressed only in basal cells in hyperplasia and papillomas. In basal cells of normal epithelia, it was also occasionally weakly stained. NIM dose-dependently decreased at doses of 150 and 300 ppm, the incidences of SCCs to 4 of 12 (33.3%) and 1 of 13 (7.7%) and their multiplicity to 0.33 ± 0.49 and 0.08 ± 0.28 per rat, respectively, as compared with 4-NQO alone group values of 9 of 11 (81.8%) and 1.00 ± 0.77 . A lesser decrease was observed with 600 ppm, the values being 5 of 12 (41.7%) and 0.50 ± 0.67 . NIM did not significantly affect the development of hyperplasias, dysplasias, and papillomas. These results clearly indicate chemopreventive potential of a selective COX-2 inhibitor against the postinitiation development of SCCs in rat tongue carcinogenesis.

INTRODUCTION

The incidence of oral cancer, the major site being the tongue, exhibits marked geographic variation, with the highest morbidity and mortality rates appearing in southern Asia where people have the habit of chewing betel quid and tobacco, but recently it has been increasing worldwide, particularly in young adults (1–3). Tobacco and alcohol intake have been postulated to be major causes (4). Despite recent advances in surgical procedures, radiotherapy and chemotherapy, oral cancer remains a major problem. One reason is the characteristic “field cancerization,” with relatively high frequencies of second primary cancers at different sites (2). Retinoids, either naturally occurring or synthetic derivatives of vitamin A, have been reported to prevent progression, recurrence, and appearance of new oral precancerous lesions like leukoplakia in humans; however, in clinical trials, synthetic retinoids, such as 13-*cis*-retinoic acid and *N*-(4-hydroxyphenyl)retinamide, (5–9), have exhibited toxicities or other side effects, which means that the search for other chemopreventive target molecules must continue (8–9).

Received 5/23/00; accepted 12/6/00.

The costs of publication of this article were defrayed in part by the payment of page charges. This article must therefore be hereby marked *advertisement* in accordance with 18 U.S.C. Section 1734 solely to indicate this fact.

¹ This work was supported in part by a Grant-in-Aid (09253104) for Scientific Research on Priority Areas and a Grant-in-Aid (10671898) for Scientific Research (C) from the Ministry of Education, Science, Sports and Culture of Japan; Grants-in-Aid (10-36 and S10-1) for Cancer Research from the Ministry of Health and Welfare of Japan; and 2nd-Term Comprehensive 10-Year Strategy for Cancer Control, Cancer Prevention from the Ministry of Health and Welfare of Japan.

² To whom requests for reprints should be addressed, at the Department of Oncological Pathology, Cancer Center, Nara Medical University, 840 Shijo-cho, Kashihara, Nara 634-8521, Japan. Phone: 81-744-22-3051; Fax: 81-744-25-7308; E-mail: adenda@nmu-gw.cc.naramed-u.ac.jp.

COXs,³ rate-limiting enzymes for producing prostanoids, consist of two isomers, COX-1 and -2, and have been postulated to be target molecules for NSAIDs (10–12). *COX-2*, in contrast to *COX-1*, which is a constitutively expressed housekeeping gene generally contributing to normal physiological functions in most tissues, is an inducible immediate early gene that has recently been postulated to be involved not only in inflammation but also in carcinogenesis, with impact on cell proliferation, differentiation, apoptosis, angiogenesis, metastasis, and immunological surveillance (10–13). In fact, evidence of up-regulated expression of COX-2 mRNA and protein in various human and animal tumor tissues such as colon, stomach, breast, skin, pancreas, lung, and urinary bladder, and prevention by specific COX-2 inhibitors of these carcinogenesis (12–23) as well as by double knockout of the *COX-2* gene of colon carcinogenesis in *APC* gene knockout mice (24), strongly support the hypothesis that COX-2 could be a chemopreventive target molecule (12–13).

Up-regulated expression of COX-2 in human SCCs of head and neck, including the tongue, has recently been reported (25). In the present study, the expression of COX-2 protein in a 4-NQO-induced rat tongue carcinogenesis model and the chemopreventive potential of the specific COX-2 inhibitor NIM were investigated.

MATERIALS AND METHODS

Chemicals. 4-NQO was obtained from Nacalai Tesque Inc. (Kyoto, Japan) and NIM from Helsinn Healthcare SA (Pambio Noranco, Switzerland). Mouse monoclonal antibody against rat COX-2 (COOH-terminal protein fragment corresponding to amino acids 368–604; C22420) and rabbit polyclonal antibody against synthetic peptides corresponding to COOH-terminal sequences of murine COX-2 (PG26), were obtained from Transduction Laboratories, Lexington, KY, and Oxford Biomedical Research Inc., Oxford, MI, respectively. Rabbit polyclonal antibody against rat COX-1 (C448 synthetic peptide) was obtained from IBL, Gunma, Japan, and trypsin inhibitor type II-S from Sigma Chemical CO, St. Louis, MO.

Animals, Diet, and Drinking Water. Fischer 344 male rats (Japan SLC Inc., Hamamatsu, Japan), 6 weeks old at the commencement of the experiments, were housed, three to a plastic cage, with hardwood chips for bedding, in an air-conditioned room with a 12-h light/12-h dark cycle. Drinking water containing 4-NQO was prepared twice a week by dissolving the carcinogen in distilled water and was given in light-opaque bottles. Diets containing NIM 150, 300, or 600 ppm were prepared once a week by mixing the compound with a powdered basal diet CE-2 (Japan Clea Co., Ltd., Tokyo, Japan) and were given to the animals in stainless steel containers. The diet and water were available *ad libitum*, and body weights and food consumption were measured weekly.

Specimens Used for Western Blot and Immunohistochemical Analyses. Forty-four animals were divided into two groups. Group 1 (38 rats) was given drinking water containing 10 ppm 4-NQO and the basal diet for 24 weeks, and group 2 (6 rats) served as a control without 4-NQO. All of the animals were killed under ether anesthesia 24 weeks after the commencement of the exper-

³ The abbreviations used are: COX, cyclooxygenase; NSAID, nonsteroidal anti-inflammatory drug; 4-NQO, 4-nitroquinoline-1-oxide; NIM, nimesulide; SCC, squamous cell carcinoma; EGF, epidermal growth factor; EGFR, EGF receptor; TBS, Tris-buffered saline; TBS-T, TBS containing 0.1% Tween 20.

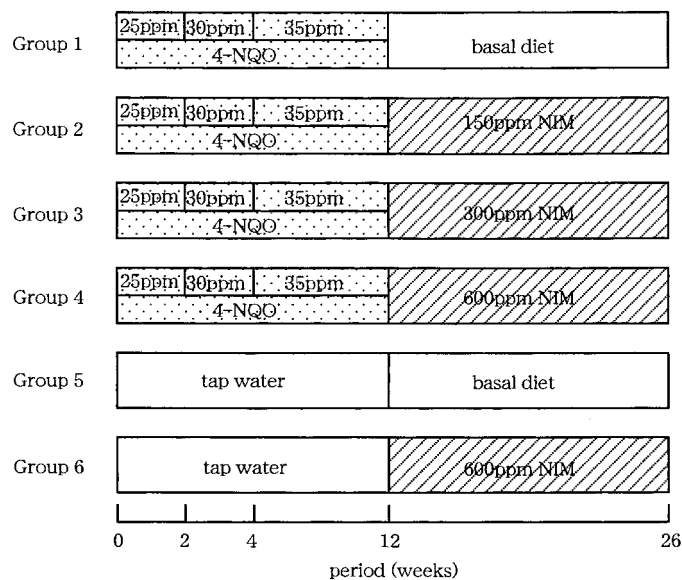


Fig. 1. Experimental protocol for the examination of the chemopreventive potential of NIM.

iment. Their tongues were longitudinally cut into three slices after fixation in 10% phosphate-buffered formalin for 48 h, routinely embedded in paraffin, and serially sectioned at 3–4 μm . The sections were used for immunohistochemistry and H&E staining. Relatively large tongue tumors from five rats in group 1 were excised using a scalpel, frozen in liquid nitrogen, and submitted to Western blot analysis after histological diagnosis. Normal tongue epithelium, exfoliated according to the method of Telsler *et al.* (26), was also submitted as a control for the Western blot analysis. Briefly, fresh normal tongues from two rats of group 2 were longitudinally cut into three slices after roughly removing muscle layers and were incubated in 10 volumes of a PBS-EDTA inhibitor solution (pH 7.4) [0.05 M ($\text{Na}_2\text{H/KH}_2$), PO_4 , 0.15 M NaCl, 20 mM EDTA, 100 $\mu\text{g/ml}$ soybean trypsin inhibitor] at 37°C for 2 h, and then overnight in a fresh PBS-EDTA inhibitor solution at 4°C. The tongue epithelium was peeled off from the muscle layers using fine forceps, and stored at -80°C until use. Partitions were fixed in 10% phosphate-buffered formalin and submitted to H&E staining.

Western Blot Analysis. Particulate fractions were obtained from the tongue samples basically according to the method of Liu *et al.* (27). Briefly, the frozen tissues were homogenized in ice-cold homogenization buffer [50 mM Tris-HCl (pH 8.0), 2 mM octyl glucoside, 10 mM EDTA, 1 mM diethyldithiocarbamic acid, 1 mM phenylmethylsulfonyl fluoride, 1 mM sodium vanadate, 60 $\mu\text{g/ml}$ soybean trypsin inhibitor, 2 $\mu\text{g/ml}$ leupeptin, and 2 $\mu\text{g/ml}$ pepstatin], all from Sigma Chemical Co., and then centrifuged at $100,000 \times g$ for 1 h at 4°C using a Beckman TLA-100.2 rotor (Beckman Instruments Inc., Palo Alto, CA). The resultant crude pellets were further homogenized in the same buffer as mentioned above (except with 20 mM Tris, 45 mM octyl glucoside, 50 mM EDTA, and 0.1 mM diethyldithiocarbamic acid) and were sonicated for 20 s several times using an ultrasonic cell disruptor (Heat System Ultrasonics, Farmingdale, NY). The sonicates were centrifuged at $13,000 \times g$ for 25 min at 4°C, and the resultant supernatants were stored at -80°C until use. Protein concentrations were determined using Coomassie Brilliant Blue G-250 solution (Nacalai Tesque, Kyoto, Japan).

Supernatant samples containing 100 μg protein were mixed 1:1 with sample buffer [4% SDS, 20% glycerol, 12% β -mercaptoethanol, 0.05% bromophenol blue, and 100 mM Tris-HCl (pH 6.8)], boiled for 5 min, electrophoresed using a 4.75% stack and a 10% running polyacrylamide gel, and electrophoretically transferred to polyvinylidene difluoride membranes (IPVH000 10; Millipore, Bedford, MA). The membranes were blocked with 5% nonfat dry milk in 0.05 M TBS-T (pH 7.6) and were incubated with primary antibodies to COX-2 (PG26) and COX-1 for 1 h at dilutions of 1:1000 or 1:80 in TBS-T. Secondary horseradish peroxidase-linked sheep antimouse and donkey antirabbit (Amersham Life Science Inc., Tokyo) IgG antibodies were then used, and the membranes were analyzed by the enhanced chemiluminescence detection

system (Amersham Life Science Inc.). COX-2 and COX-1 proteins from sheep placenta and ram seminal vesicles (Cayman Chemical Company, Ann Arbor, MI), respectively, were used as COX-2- and COX-1-positive controls.

Immunohistochemical Analysis. For the immunohistochemical COX-2 analysis, paraffin sections were deparaffinized, treated with 0.05% protease XXVII (Sigma Chemical Co.) in 50 mM TBS (pH 7.6) at 37°C for 5 min for the antigen retrieval, blocked with 0.3% H_2O_2 in methanol for 45 min and incubated with a primary antibody to COX-2 (C22420) (1:100 dilution in TBS) for 2 h. Immunoreactivity was detected using a Dako LSAB2 kit for use with rat specimens (Dako Co., Carpinteria, CA) and 3,3'-diaminobenzidine hydrochloride (Sigma Chemical Co.) followed by counterstaining with Mayer's hematoxylin. Immunohistochemical COX-1 analysis was basically the same as for COX-2, except that antigens were retrieved by microwaving for 50 min in 0.01 M citrate buffer (pH 6.0), and that after blocking nonspecific binding with 5% normal goat serum in TBS-0.25% Triton X-100 for 20 min, tissues were incubated with a primary antibody to COX-1 (1:60 dilution in TBS-0.25% Triton X-100) with detection of immunoreactivity using a Vectastain Elite ABC kit (Vector Laboratories, Burlingame, CA). A nonimmune serum, mouse IgG1 (Dako Japan Inc., Kyoto) or rabbit IgG (Dako Japan Inc.), as well as antibodies preabsorbed with the antigens, were used as controls for the primary antibody binding. In the preabsorption experiment, COX-2 antibody was preabsorbed by incubating with 4 times molar ratios of COX-2 or COX-1 proteins from sheep placenta and ram seminal vesicles (Cayman Chemical Company), respectively, and COX-1 antibody with 4 times molar ratios of the antigen peptide (IBL, Gunma, Japan), at 4°C overnight.

Studies on the Chemopreventive Potential of NIM. The experimental protocol is shown in Fig. 1. Sixty animals were divided into six groups, with 11–13 rats each for groups 1–4 and 6 rats each for groups 5 and 6. Animals in

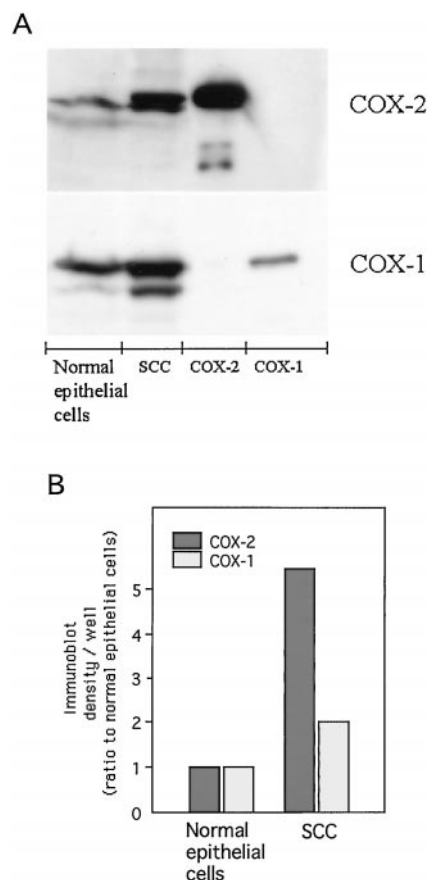


Fig. 2. Results of Western blot analysis of COX-2 and COX-1 protein expression in exfoliated normal tongue epithelium and pooled SCCs induced by giving 10 ppm 4-NQO in the drinking water for 24 weeks in rats. A, COX-2 (top) and COX-1 (bottom) protein expression. Anti-COX-2 (PG26) and COX-1 antibodies were used. Note positive control proteins for COX-2 (derived from sheep placenta) and COX-1 (derived from sheep seminal vesicles). B, densities of the bands in A expressed as ratios to the density of normal epithelium.

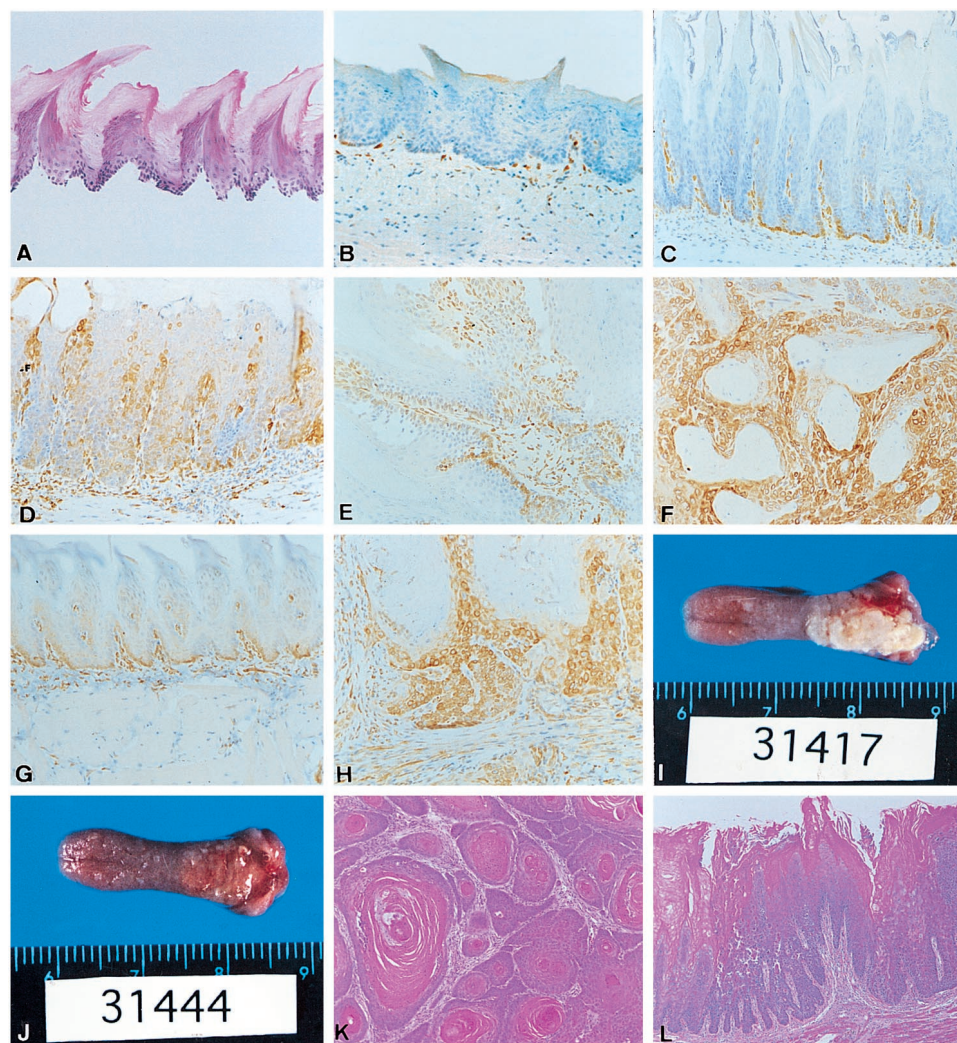


Fig. 3. A, exfoliated normal tongue epithelium, H&E staining; $\times 100$. B–H, immunohistochemical localization of COX-2 (B–F) and COX-1 (G–H) protein in normal tongue epithelium (B and G, $\times 100$) and examples of hyperplasia (C, $\times 100$), dysplasia (D, $\times 100$), papilloma (E, $\times 100$), and SCC (F and H, $\times 200$) induced in rats by giving 10 ppm 4-NQO in the drinking water for 24 weeks. I–L, representative macroscopic (I–J) and histological findings for tongue lesions (K–L) in rats given basal diet (group 1) or a diet containing 300 ppm NIM (group 3) for 14 weeks, after 25–35 ppm 4-NQO in the drinking water for 12 weeks. Tongue lesions seen in a rat from group 1 (I) and from group 3 (J). There are whitish protuberant large nodules in the dorsal posterior aspect of the base in (I) and diminished lesions in (J). Histological findings for a SCC in a rat from group 1 (K, H&E staining; $\times 100$) and dysplasia in a rat from group 3 (L, H&E staining; $\times 100$).

groups 1–4 were given 25–35 ppm 4-NQO in their drinking water for 12 weeks (25 ppm for the first 2 weeks, 30 ppm for the next 2 weeks, and 35 ppm for the other 8 weeks). Then, group 1 was fed the basal diet, and groups 2–4 received diets containing 150, 300, and 600 ppm, respectively, of NIM for 14 weeks. Animals in groups 5 and 6 served as controls and were given tap water for the first 12 weeks, followed by 600 ppm NIM and basal diet, respectively. All of the animals were killed under ether anesthesia 26 weeks after the commencement of the experiment. Their tongues were excised, fixed in 10% phosphate-buffered formalin for 48 h, and longitudinally cut into three slices. The livers and kidneys from all of the animals were also excised, weighed, and fixed. All of these tissues were routinely processed for embedding in paraffin and sectioned for H&E staining. The tongue lesions were histologically diagnosed by three experts independently, basically according to the criteria of WHO (28).

Statistical Analysis. Quantitative differences between group values were statistically analyzed using ANOVA with multiple comparison *post hoc* testing by Dunnnett, Student's *t*, χ^2 , or Fisher's exact test.

RESULTS

Western Blot Analysis for COX-2 and COX-1 Proteins. A representative Western blot from two separate analyses for COX-2 and COX-1 protein expression in exfoliated normal epithelium and pooled SCCs induced by 4-NQO in rat tongues is shown in Fig. 2A. The density of each band was quantified using NIH image, and the results are presented in Fig. 2B. Histological assessment of the exfoliated normal tongue epithelium revealed well-preserved architecture without muscle layers (Fig. 3A). The normal epithelial cells barely expressed COX-2 protein, whereas SCCs exhibited substantial binding of specific antibodies, ~ 6 -fold that of normal epithelial cells (Fig. 2). In contrast, COX-1 protein was highly expressed both in the normal epithelial cells and SCCs, with SCCs exhibiting ~ 2 -fold that of normal epithelial cells (Fig. 2).

Table 1 COX-2 immunohistochemical staining of tongue lesions in rats given 10 ppm 4-NQO in their drinking water for 24 weeks

Tongue lesions	Incidence (%)	No. of lesions examined	Staining with COX-2 antibody ^a				
			No. of lesions (%)				
			–	±	+	++	+++
Hyperplasia	22/33 (66.7)	29	0	14 (48.3)	14 (48.3)	1 (3.4)	0
Dysplasia	21/33 (63.6)	36	0	0	11 (30.6)	20 (55.6)	5 (13.9)
Papilloma	10/33 (30.3)	11	0	0	6 (54.5)	5 (45.5)	0
SCC	11/33 (33.3)	13	0	0	5 (38.5)	6 (46.2)	2 (15.4)

^a Staining: –, negative; ±, less than 10% of the area weakly positive; +, weakly positive; ++, moderately positive; +++, strongly positive.

Table 2 Experimental details for rats given 4-NQO for 12 weeks followed by NIM for 14 weeks^a

Group no.	Treatment	No. of rats (final)	Body weight (g)(final)	Organ weight (g) (ratio to body weight $\times 10^{-3}$)		Average water intake		Average food intake	
				Liver	Kidney	Water (ml/day/kg body weight)	4-NQO (mg/day/kg body weight)	Diet (g/day/kg body weight)	NIM (mg/day/kg body weight)
1	4-NQO alone	11	327 \pm 39	9.1 \pm 1.7 (27.6 \pm 2.18)	1.02 \pm 0.08 (3.15 \pm 0.28)	72.4 \pm 19.9	2.23 \pm 0.40	42.3 \pm 5.5	0
2	4-NQO + 150 ppm NIM	12	349 \pm 38	10.8 \pm 2.3 (29.7 \pm 4.7)	1.12 \pm 0.10 (3.24 \pm 0.23)	74.2 \pm 21.1	2.29 \pm 0.44	45.4 \pm 5.1	6.8 \pm 0.8
3	4-NQO + 300 ppm NIM	13	365 \pm 21	11.2 \pm 0.9 (30.7 \pm 1.3)	1.16 \pm 0.08 (3.20 \pm 0.22)	73.1 \pm 20.5	2.25 \pm 0.42	45.5 \pm 5.4	13.6 \pm 1.6
4	4-NQO + 600 ppm NIM	12	351 \pm 49	10.4 \pm 2.4 (30.4 \pm 3.9)	1.12 \pm 0.13 (3.24 \pm 0.23)	72.2 \pm 19.8	2.22 \pm 0.39	44.4 \pm 5.6	30.0 \pm 3.0
5	Water + basal diet	6	388 \pm 15	12.5 \pm 1.0 (32.2 \pm 2.5)	1.20 \pm 0.05 (3.09 \pm 0.14)	90.0 \pm 24.5	0	43.8 \pm 7.6	0
6	Water + 600 ppm NIM	6	392 \pm 13	11.2 \pm 0.6 (28.7 \pm 1.1)	1.09 \pm 0.04 (2.77 \pm 0.12)	86.5 \pm 22.5	0	44.4 \pm 6.5	26.0 \pm 4.1

^a Values are means \pm SD.

Immunohistochemical Analysis of COX-2 and COX-1 Proteins.

Results for COX-2 immunohistochemical staining of rat tongue lesions, induced by the administration of 10 ppm 4-NQO for 24 weeks, are summarized in Table 1. The staining was classified into five grades: – (negative), no staining; \pm , less than 10% of the area weakly positive; +, weakly positive; ++, moderately positive; and +++, strongly positive. In the normal epithelium, basal cells were occasionally weakly positive for COX-2 protein (Fig. 3B). In approximately 50% of the hyperplastic lesions (Fig. 3C) and 100% of squamous cell papillomas (Fig. 3E) examined, only basal cells were positive for COX-2 (Table 1). In contrast, in all of the dysplasias (Fig. 3D) and SCCs (Fig. 3F) examined, not only basal but also other tumor cells were moderately or strongly positive for COX-2 (Table 1). In SCCs, stromal cells were also moderately positive for COX-2 (Fig. 3F). In all cases, COX-2 protein was localized in the nuclear membrane and cytoplasm. With nonimmune serum, staining was negative (data not shown). Preabsorption of the COX-2 antibody with COX-2 but not COX-1 proteins abrogated the staining (data not shown). Immunohistochemistry further revealed that in the normal epithelium, cells in the basal strongly, as well as upper layers weakly, were positive for COX-1 protein (Fig. 3G). Similar stainability for COX-1 was obtained for hyperplasias, dysplasias, and papillomas (data not shown). In SCCs, tumor cells and stromal cells were strongly positive (Fig. 3H). In all cases COX-1 protein was localized in the cytoplasm and nuclear membrane. Nonimmune serum gave negative staining, and preabsorption of the COX-1 antibody with the antigen peptide abrogated the staining (data not shown).

Chemopreventive Potential of NIM. Data for body and organ weights and food intake are summarized in Table 2. NIM did not significantly affect the final body weights and liver and kidney weights at any doses. There were no significant differences in the

average intake of 4-NQO among the 4-NQO-treated groups, and intake of NIM was dose dependent.

Representative macroscopic tongue findings are shown in Fig. 3, I and J. The tongues from group 1 (4-NQO alone), especially in their dorsal posterior aspect of the base, exhibited whitish protuberant nodular lesions, varying in size from larger than 10 mm to smaller than 1 mm in diameter (Fig. 3I). Their numbers and sizes tended to be decreased in the groups treated with NIM, particularly in group 3 (4-NQO + 300 ppm NIM; Fig. 3J).

Data for incidences and numbers of histologically diagnosed tongue lesions and size distributions of SCCs are summarized in Table 3. Representative histological findings for SCCs and dysplasias developing in groups 1 and 3, respectively, are shown in Fig. 3, K and L. NIM at doses of 150 and 300 ppm, dose-dependently significantly decreased the incidence and multiplicity of SCCs but not those of hyperplasias, dysplasias, and papillomas (Table 3). The highest dose, 600 ppm NIM, also exhibited a tendency to decrease, but without statistical significance, the incidence, multiplicity, and size of SCCs, with the majority of SCCs being less than 3 mm in diameter (Table 3). No tongue lesions were observed in the animals without 4-NQO treatment, from groups 5 and 6.

Histopathological Findings of Other Organs. No histopathological lesions were observed in the livers and kidneys of rats given NIM with or without 4-NQO treatment. No macroscopic abnormalities were observed in other organs, and bleeding was not apparent in the gastrointestinal tract of NIM-treated animals.

DISCUSSION

The present study demonstrated up-regulation of COX-2 expression in precancerous lesions and SCCs, and preventive effects of the

Table 3 Effects of NIM on the development of tongue lesions in rats initiated by 4-NQO

Group no.	Treatment	Effective no. of rats ^a	Tongue lesions								Size distribution of SCCs (%) diameter (mm)		
			Incidence (%)				Multiplicity (no./rat)				<3	3–10	<10
			HP ^b	DP	PAP	SCC	HP	DP	PAP	SCC			
1	4-NQO alone	11	7 (63.6)	10 (90.9)	2 (22.2)	9 (81.8)	1.09 \pm 1.04	2.18 \pm 1.40	0.22 \pm 0.44	1.00 \pm 0.77	3 (27.3)	2 (18.1)	6 (54.5)
2	4-NQO + 150 ppm NIM	12	9 (75.0)	11 (91.7)	5 (41.7)	4 (33.3) ^c	1.50 \pm 1.17	1.83 \pm 1.19	0.42 \pm 0.51	0.33 \pm 0.49 ^c	1 (25.0)	2 (50.0)	1 (25.0)
3	4-NQO + 300 ppm NIM	13	11 (84.6)	13 (100)	3 (23.1)	1 (7.7) ^d	1.23 \pm 0.83	2.00 \pm 1.00	0.23 \pm 0.44	0.08 \pm 0.28 ^e	0	0	1 (100)
4	4-NQO + 600 ppm NIM	12	7 (58.3)	10 (83.3)	3 (25.0)	5 (41.7)	0.75 \pm 0.75	1.08 \pm 0.67	0.25 \pm 0.45	0.50 \pm 0.67	4 (66.7)	0	2 (33.3)

^a Based on histological examination.

^b HP, hyperplasia; DP, dysplasia; PAP, squamous cell papilloma.

^c Significantly different from Group 1 ($P < 0.05$).

^d Significantly different from Group 1 ($P < 0.0005$).

^e Significantly different from Group 1 ($P < 0.01$).

specific COX-2 inhibitor, NIM, in the postinitiation stage of rat tongue carcinogenesis induced by 4-NQO. NIM, a sulfonanilide class COX-2 inhibitor that can bind to the large catalytic moiety of COX-2 but not COX-1 (29), was earlier found to preferentially inhibit sheep placenta COX-2 activity *in vitro* in a time-dependent fashion, with an IC_{50} of 0.07 μ M at the peak time point (as compared with >100 or 300 μ M for ram seminal vesicle COX-1), and to possess much less adverse effects on the gastrointestinal tract than nonspecific NSAIDs (30–32). The average daily intake at 300 ppm NIM is 13.6 mg/kg body weight and ~4 times the maximum tolerated dose in humans of 200 mg per person per day (30).

The present results are the first, to the authors' knowledge, to provide direct evidence of involvement of COX-2 in rat tongue carcinogenesis, in line with the preventive effects of the NSAIDs piroxicam and indomethacin, reported earlier (8, 33), as well as with the suppressive effect of another selective COX-2 inhibitor, JTE-522, on the growth of a xenografted human oral SCC cell line in nude mice (34). The present preventive potential of 600 ppm being lower than that of 300 ppm NIM, without histological findings of tissue injury, may simply reflect variations within statistical uncertainty because of the relatively small numbers of animals, but it may be partly attributable to the existence of certain limited effective doses and warrants further study. Moreover, the lack of significant effects on the incidence and multiplicity of dysplasia, despite increased COX-2 protein expression, may suggest a most important role for the enzyme in the progression of dysplasia to SCC or roles of the enzyme expressed in the stromal cells. Discrepancies from the previous reports that indomethacin and piroxicam decreased the incidence of dysplasia or hyperplasia, as well as of SCC (33), might partly be attributable to the fact that, in the present study, these lesions had already developed by the time of cessation of the 4-NQO exposure, which at termination was at a much higher dose of 25–35 ppm than the 10 ppm used in the previous report. In this context, it should be noted that retinoids reportedly can cause regression of dysplastic lesions like leukoplakia in humans (5–7), probably because of stimulation of squamous cell differentiation and apoptosis (35). However, various degrees of dysplasia are included in the clinical descriptive term leukoplakia, with only 3–6% progressing to SCCs (28). Nevertheless, taking into account the possible involvement of inhibitory effects of retinoids on COX-2 expression in their cancer chemopreventive potential (36–37), we conclude that the lack of NIM impact on dysplasia clearly warrants further study.

COX-2 is known to be induced by cytokines and growth factors including transforming growth factor α and EGF, and mutated Ras activation (13, 36–39). In fact, mitogenic signaling through EGFR induces COX-2, probably through activation of the Ras-mitogen-activated protein kinase pathway, which can be prevented by a selective COX-2 inhibitor (39–40). When we take into account the evidence of elevated expression of EGFR with infrequent gene amplification in hyperplastic and dysplastic lesions, normal-looking epithelia adjacent to tumor, and SCCs during head and neck tumorigenesis, including the oral cavity in humans (41–43), we conclude that there is a possibility that EGFR is involved in COX-2 elevation, although the EGFR-immunohistochemical findings, particularly those of no distinction between hyperplasias and dysplasias, reported earlier (42), do not parallel the present COX-2 findings. The relatively low frequencies of Ha- but not Ki- nor N-ras mutations reported for 4-NQO-induced tongue (24%) as well as human oral SCCs (10–35%; 43–44), may suggest that mutated Ras activation is unlikely to play a major role in the induction of COX-2 in these lesions.

In conclusion, our present results clearly indicate COX-2 protein to be highly expressed in the dysplastic precancerous lesions and SCCs in 4-NQO-induced rat tongue carcinogenesis, and to play important

roles in the development of malignancies in this model, judging from the observed impact of the specific inhibitor NIM. The results, thus, provide that selective COX-2 inhibitors with less adverse effects on the gastrointestinal tract than nonspecific NSAIDs, could be promising candidates for chemopreventive agents active against human oral cancer.

ACKNOWLEDGMENTS

We are very grateful to Dr. Keiji Wakabayashi of Cancer Prevention Division, National Cancer Center Research Institute, Tokyo, Japan, for valuable discussions.

REFERENCES

- Moore, S. R., Johnson, N. W., Pierce, A. M., and Wilson, D. F. The epidemiology of tongue cancer: a review of global incidence. *Oral Dis.*, 6: 75–84, 2000.
- Johnson, N. Oral cancer: a worldwide problem. *FDI World*, 6: 19–21, 1997.
- Atula, S., Grenman, R., Laippala, P., and Syrjanen, S. Cancer of the tongue in patients younger than 40 years. A distinct entity? *Arch. Otolaryngol. Head Neck Surg.*, 122: 1313–1319, 1996.
- Macfarlane, G. J., Macfarlane, T. V., and Lowenfels, A. B. The influence of alcohol consumption on worldwide trends in mortality from upper aerodigestive tract cancers in men. *J. Epidemiol. Community Health*, 50: 636–639, 1996.
- Hong, W. K., Endicott, J., Itri, L. M., Doos, W., Batsakis, J. G., Bell, R., Fofonoff, S., Byers, R., Atkinson, E. N., Vaughan, C., Toth, B. B., Kramer, A., Dimery, I. W., Skipper, P., and Strong, S. 13-*cis*-Retinoic acid in the treatment of oral leukoplakia. *N. Engl. J. Med.*, 315: 1501–1505, 1986.
- Hong, W. K., Lippman, S. M., Itri, L. M., Karp, D. D., Lee, J. S., Byers, R., Schantz, S. P., Kramer, A. M., Lotan, R., Peters, L. J., Dimery, I. W., Brown, B. W., and Goepfert, H. Prevention of second primary tumors with isotretinoin in squamous cell carcinoma of the head and neck. *N. Engl. J. Med.*, 323: 795–801, 1990.
- Costa, A., De Palo, G., Decensi, A., Formelli, F., Chiesa, F., Nava, M., Camerini, T., Marubini, E., and Veronesi, U. Retinoids in cancer chemoprevention. Clinical trials with synthetic analogue fenretinide. *Ann. NY Acad. Sci.*, 768: 148–162, 1995.
- Tanaka, T. Chemoprevention of oral carcinogenesis. *B Oral Oncol. Eur. J. Cancer*, 31B: 3–15, 1995.
- Kelloff, G. J., Crowell, J. A., Steele, V., Lubet, R. A., Boone, C. W., Malone, W. A., Hawk, E. T., Lieberman, R., Lawrence, J. A., Kopelovich, L., Ali, I., Viner, J., and Sigman, C. Progress in cancer chemoprevention. *Ann. NY Acad. Sci.*, 889: 1–13, 1999.
- Marnett, L. J. Aspirin and the potential role of prostaglandins in colon cancer. *Cancer Res.*, 52: 5575–5589, 1992.
- Herschman, H. R. Regulation of prostaglandin synthase-1 and prostaglandin synthase-2. *Cancer Metastasis Rev.*, 13: 241–256, 1994.
- Shiff, S. J., and Rigas, B. Nonsteroidal anti-inflammatory drugs and colorectal cancer: evolving concepts of their chemopreventive actions. *Gastroenterology*, 113: 1992–1998, 1997.
- Williams, C. S., Mann, M., and DuBois, R. N. The role of cyclooxygenases in inflammation, cancer, and development. *Oncogene*, 18: 7908–7916, 1999.
- Kargman, S. L., O'Neill, G. P., Vickers, P. J., Evans, J. F., Mancini, J. A., and Jothy, S. Expression of prostaglandin G/H synthase-1 and -2 protein in human colon cancer. *Cancer Res.*, 55: 2556–2559, 1995.
- Reddy, B. S., Hirose, Y., Lubet, R., Steele, V., Kelloff, G., Paulson, S., Seibert, K., and Rao, C. V. Chemoprevention of colon cancer by specific cyclooxygenase-2 inhibitor, celecoxib, administered during different stages of carcinogenesis. *Cancer Res.*, 60: 293–297, 2000.
- Fukutake, M., Nakatsugi, S., Isoi, T., Takahashi, M., Ohta, T., Mamiya, S., Taniguchi, Y., Sato, H., Fukuda, K., Sugimura, T., and Wakabayashi, K. Suppressing effects of nimesulide, a selective inhibitor of cyclooxygenase-2, on azoxymethane-induced colon carcinogenesis in mice. *Carcinogenesis (Lond.)*, 19: 1939–1942, 1998.
- Restiäki, A., Honkanen, N., Jänkälä, H., Sipponen, P., and Härkönen, M. Expression of cyclooxygenase-2 in human gastric carcinoma. *Cancer Res.*, 57: 1276–1280, 1997.
- Müller-Decker, K., Kopp-Schneider, A., Marks, F., Seibert, K., and Fürstenberger, G. Localization of prostaglandin H synthase isozymes in murine epidermal tumors: suppression of skin tumor promotion by inhibition of prostaglandin H synthase-2. *Mol. Carcinog.*, 23: 36–44, 1998.
- Tucker, O. N., Dannenberg, A. J., Yang, E. K., Zhang, F., Teng, L., Daly, J. M., Soslow, R. A., Masferrer, J. L., Woerner, B. M., Koki, A. T., and Fahey, T. J., III. Cyclooxygenase-2 expression is up-regulated in human pancreatic cancer. *Cancer Res.*, 59: 987–990, 1999.
- Hida, T., Yatabe, Y., Achiwa, H., Muramatsu, H., Kozaki, K., Nakamura, S., Ogawa, M., Mitsudomi, T., Sugiura, T., and Takahashi, T. Increased expression of cyclooxygenase-2 occurs frequently in human lung cancers, specifically in adenocarcinomas. *Cancer Res.*, 58: 3761–3764, 1998.
- Kitayama, W., Denda, A., Yoshida, J., Sasaki, Y., Takahama, M., Murakawa, K., Tsujiuchi, T., Tsutsumi, M., and Konishi, Y. Increased expression of cyclooxygenase-2 protein in rat lung tumors induced by *N*-nitrosobis(2-hydroxypropyl)amine. *Cancer Lett.*, 148: 145–152, 2000.
- Kitayama, W., Denda, A., Okajima, E., Tsujiuchi, T., and Konishi, Y. Increased expression of cyclooxygenase-2 protein in rat urinary bladder tumors induced by

- N*-butyl-*N*-(4-hydroxybutyl)nitrosamine. *Carcinogenesis* (Lond.), 20: 2305–2310, 1999.
23. Okajima, E., Denda, A., Ozono, S., Takahama, M., Akai, H., Sasaki, Y., Kitayama, W., Wakabayashi, K., and Konishi, Y. Chemopreventive effects of nimesulide, a selective cyclooxygenase-2 inhibitor, on the development of rat urinary bladder carcinomas initiated by *N*-butyl-*N*-(4-hydroxybutyl)nitrosamine. *Cancer Res.*, 58: 3028–3031, 1998.
 24. Oshima, M., Dinchuk, J. E., Kargman, S. L., Oshima, H., Hancock, B., Kwong, E., Trzaskos, J. M., Evans, J. F., Taketo, M. M. Suppression of intestinal polyposis in APC^{Δ716} knockout mice by inhibition of cyclooxygenase 2 (COX-2). *Cell*, 87: 803–809, 1996.
 25. Chan, G., Boyle, J. O., Yang, E. K., Zhang, F., Sacks, P. G., Shah, J. P., Edelstein, D., Soslow, R. A., Koki, A. T., Woerner, B. M., Masferrer, J. L., and Dannenberg, A. J. Cyclooxygenase-2 expression is up-regulated in squamous cell carcinoma of the head and neck. *Cancer Res.*, 59: 991–994, 1999.
 26. Telser, A., Farbman, A. I., and Chacko, C. A low-molecular-weight soluble protein from bovine lingual epithelium. II. Purification and characterization. *J. Invest. Dermatol.*, 79: 286–292, 1982.
 27. Liu, X-H., and Rose, D. P. Differential expression and regulation of cyclooxygenase-1 and -2 in two human breast cancer cell lines. *Cancer Res.*, 56: 5125–5127, 1996.
 28. WHO collaborating center for oral precancerous lesions. Definition of leukoplakia and related lesions: an aid to studies on oral precancer. *Oral Surg., Oral Med. Oral Pathol.*, 46: 518–539, 1978.
 29. Kurumbail, R. G., Stevens, A. M., Gierse, J. K., McDonald, J. J., Stegman, R. A., Pak, J. Y., Gildehause, D., Miyashiro, J. M., Penning, T. D., Seibert, K., Isakson, P. C., and Stalling, W. C. Structural basis for selective inhibition of cyclooxygenase-2 by anti-inflammatory agents. *Nature* (Lond.), 384: 644–648, 1996.
 30. Davis, R., and Brogden, R. N. Nimesulide. An update of its pharmacodynamic and pharmacokinetic properties, and therapeutic efficacy. *Drugs*, 48: 431–454, 1994.
 31. Tavares, I. A., Bishai, P. M., and Bennett, A. Activity of nimesulide on constitutive and inducible cyclooxygenases. *Arzneim.-Forsch.* 45: 1093–1095, 1995.
 32. Vago, T., Bevilacqua, M., and Norbiato, G. Effects of nimesulide action time dependence on selectivity towards prostaglandin G/H synthase/cyclooxygenase activity. *Arzneim.-Forsch.*, 45: 1096–1098, 1996.
 33. Tanaka, T., Nishikawa, A., Mori, Y., Morishita, Y., and Mori, H. Inhibitory effects of non-steroidal anti-inflammatory drugs, piroxicam and indomethacin on 4-nitroquinoline 1-oxide-induced tongue carcinogenesis in male ACI/N rats. *Cancer Lett.*, 48: 177–182, 1989.
 34. Nishimura, G., Yanoma, S., Mizuno, H., Kawakami, K., and Tsukuda, M. A selective cyclooxygenase-2 inhibitor suppresses tumor growth in nude mouse xenografted with human head and neck squamous carcinoma cells. *Jpn. J. Cancer Res.*, 90: 1152–1162, 1999.
 35. Zhang, L-X., Mills, K. J., Dawson, M. I., Collins, S. J., and Letten, A. M. Evidence for the involvement of retinoic acid receptor PAR α -dependent signaling pathway in the induction of tissue transglutaminase and apoptosis. *J. Biol. Chem.*, 270: 6022–6029, 1995.
 36. Mestre, J. R., Subbaramaiah, K., Sacks, P. G., Schantz, S. P., Tanabe, T., Inoue, H., and Dannenberg, A. J. Retinoids suppress epidermal growth factor-induced transcription of cyclooxygenase-2 in human oral squamous carcinoma cells. *Cancer Res.*, 57: 2890–2895, 1997.
 37. Mestre, J. R., Chan, G., Zhang, F., Yang, E. K., Sacks, P. G., Boyle, J. O., Shah, J. P., Edelstein, D., Subbaramaiah, K., and Dannenberg, A. J. Inhibition of cyclooxygenase-2 expression. An approach to preventing head and neck cancer. *Ann. NY Acad. Sci.*, 889: 62–71, 1999.
 38. Subbaramaiah, K., Telang, N., Ramonetti, J. T., Araki, R., DeVito, B., Weksler, B. B., and Dannenberg, A. J. Transcription of cyclooxygenase-2 is enhanced in transformed mammary epithelial cells. *Cancer Res.*, 56: 4424–4429, 1996.
 39. Sheng, H., Williams, C. S., Shao, J., Liang, P., DuBois, R. N., and Beauchamp, R. D. Induction of cyclooxygenase-2 by activated *Ha-ras* oncogene in rat-1 fibroblasts and the role of mitogen-activated protein kinase pathway. *J. Biol. Chem.*, 273: 22120–22127, 1998.
 40. Coffey, R. J., Hawkey, C. J., Damstrup, L., Graves-Deal, R., Daniel, V. C., Dempsey, P. J., Chinery, R., Kirkland, S. C., DuBois, R. N., Jetton, T. L., and Morrow, J. D. Epidermal growth factor receptor activation induces nuclear targeting of cyclooxygenase-2, basolateral release of prostaglandins and mitogenesis in polarizing colon cancer cells. *Proc. Natl. Acad. Sci. USA*, 94: 657–662, 1997.
 41. Grandis, J. R., and Tweardy, D. J. Elevated levels of transforming growth factor α and epidermal growth factor receptor messenger RNA are early markers of carcinogenesis in head and neck cancer. *Cancer Res.*, 53: 3579–3584, 1993.
 42. Shin, D. M., Ro, J. Y., Hong, W. K., and Hittelman, W. N. Dysregulation of epidermal growth factor receptor expression in premalignant lesions during head and neck tumorigenesis. *Cancer Res.*, 54: 3153–3159, 1994.
 43. Saranath, D., Bhoite, L. T., and Deo, M. G. Molecular lesions in human oral cancer: the Indian scene. *Eur. J. Cancer B Oral Oncol.*, 29B: 107–112, 1993.
 44. Suzui, M., Yoshimi, N., Tanaka, T., and Mori, H. Infrequent *Ha-ras* mutations and absence of *Ki-ras*, *N-ras*, and *p53* mutations in 4-nitroquinoline 1-oxide-induced rat oral lesions. *Mol. Carcinog.*, 14: 284–298, 1995.