

Intestinal Microflora Are Necessary for Development of Spontaneous Adenocarcinoma of the Large Intestine in T-Cell Receptor β Chain and p53 Double-Knockout Mice

Shoichi Kado¹, Kazumi Uchida, Hideyuki Funabashi, Shin Iwata, Yuriko Nagata, Minoru Ando, Masaharu Onoue, Yoshiaki Matsuoka, Makoto Ohwaki, and Masami Morotomi

Yakult Central Institute for Microbiological Research, Kunitachi-shi, Tokyo, 186-8650, Japan

Abstract

This study was conducted to confirm the hypothesis that intestinal microflora are required for the development of adenocarcinoma in the colon of the TCR β and p53 double-knockout (TCR $\beta^{-/-}$ p53 $^{-/-}$) mouse. Germ-free TCR $\beta^{-/-}$ p53 $^{-/-}$ mice were produced. At 7 weeks of age, the animals were divided into two groups ($n = 10/\text{group}$), and one of these groups was conventionalized. Animals of both groups were subjected to histopathological examination for adenocarcinoma of the colon at 4 months of age. There was no development of adenocarcinoma of the colon among the germ-free mice, whereas in the conventionalized group, adenocarcinomas of the ileocecum and cecum were detected in 70% of animals. These results indicate the usefulness of the TCR $\beta^{-/-}$ p53 $^{-/-}$ mouse as a colon cancer animal model that develops spontaneous adenocarcinoma of the colon early in life, and suggest that intestinal microflora play a major role in the development of adenocarcinoma of the colon in this animal model.

Introduction

UC² is a nonspecific inflammatory disease of the large intestine placed, along with Crohn's disease, in the category of IBD. The incidence of colon cancer in patients with active IBD increases significantly with increasing duration of illness (1, 2).

TCR β is one of the molecules that constitute the T-cell receptor, and lack of this molecule results in homeostatic defects of the intestinal mucosal immune system. The TCR β gene-deficient (TCR $\beta^{-/-}$) mouse, which has been produced for the purpose of clarifying the mechanisms of T-cell genesis and differentiation (3–6), is known to develop inflammation of the intestinal tract and serves as an animal model for IBD that exhibits lesions analogous to those of UC in humans (7).

The p53 gene is the cause of Li-Fraumeni syndrome, which is characterized by hereditary, frequent occurrence of diverse malignant neoplasms (8), and is also an antioncogene (tumor suppressor gene) in which mutations frequently are detected in nonhereditary malignant tumors (9). The protein encoded by p53 functions to arrest the cell cycle in response to DNA damage or to induce apoptosis (10, 11). The p53 gene-deficient (p53 $^{-/-}$) mouse, produced to analyze the function of the p53 gene, has been reported to exhibit a high incidence of angiosarcoma and spontaneous development of malignant lymphomas of various organs (12, 13). In human UC-associated neoplasia, mutation in the p53 gene or overexpression of p53 protein is reported to occur commonly as an early event in the dysplasia-cancer sequence (14–20).

We previously noted a high incidence of spontaneous colorectal cancer early in life in TCR $\beta^{-/-}$ p53 $^{-/-}$ mice (21), which are derived from TCR $\beta^{-/-}$ mice (7), an IBD animal model, by mating them with p53 $^{-/-}$ mice (12, 13). IBD is generally thought to be an autoimmune disorder developing as a consequence of the breakdown of immune regulatory interactions in the gastrointestinal tract, but no antigen that induces IBD has been identified (22, 23). Studies reported in recent years have demonstrated that colitis does not develop in such IBD animal models as IL-2 $^{-/-}$ mice, IL-10 $^{-/-}$ mice, and TCR $\alpha^{-/-}$ mice when they are bred and maintained in a germ-free environment, thus indicating a possible important role of enteric bacterial antigens in the pathogenesis of colitis in these strains (24–26). Prompted by the possible inhibition of occurrence of colon cancer in germ-free TCR $\beta^{-/-}$ p53 $^{-/-}$ mice, which is presumed from the reported findings that intestinal microflora play an important role in the exacerbation of IBD, and from the fact that IBD constitutes an underlying disorder for adenocarcinoma of the colon, we examined the involvement of intestinal microflora in the development of adenocarcinoma of the colon in germ-free TCR $\beta^{-/-}$ p53 $^{-/-}$ mice, which we produced.

Materials and Methods

Animals. From TCR β - and p53-deficient mice supplied by Massachusetts Institute of Technology (Cambridge, MA), we derived a congenic strain by direct back-crossing with C57BL/6J mice as the genetic background. Germ-free TCR $\beta^{-/-}$ p53 $^{-/-}$ mice (germ-free mice) of the congenic C57BL/6J Tcrb^{tml/Mom} Trp53^{tml} strain (21), N4 generation origin, were prepared at the Central Institute for Experimental Animals (Kawasaki, Kanagawa, Japan).

Twenty 7-week-old germ-free mice were divided into two groups of 10 each. One group of mice was conventionalized by oral administration of fresh feces from specific pathogen-free C57BL/6J mice. Both groups of animals were housed in vinyl isolators. The germ-free mice were maintained in a germ-free environment, and the conventionalized mice were maintained in specific pathogen-free conditions; both had free access to 10 kGy-sterilized pellet diet (FR-1; Funabashi Farms Co., Ltd., Chiba, Japan) and sterilized (autoclaved at 126°C for 30 min) tap water.

Genotypes TCR β and p53 genes were assessed by the method described previously (21).

Pathological Examination. At 4 months of age, the animals were sacrificed by exsanguination by transection of the abdominal aorta and vena cava under ether anesthesia. All major organs were carefully examined for visible abnormalities at autopsy. The intestinal segment from the ileocecal junction to the rectum was resected and filled with 10% neutral-buffered formalin. The specimen was opened longitudinally, stained with 0.2% methylene blue for ~1 min, and examined for nodular masses under a stereomicroscope (Olympus SZ-10). The sites of all lesions thus noted were recorded, cut out, and subjected to histopathological examination. The nodular mass-free portion of the intestine, *i.e.*, the area extending from the middle colon to the rectum, was rolled up and processed for histological examination in a routine manner. The tissue sections were stained with H&E and examined microscopically for inflammatory lesions and their severity, according to the criteria of Berg *et al.* (27).

Received 10/17/00; accepted 1/31/01.

The costs of publication of this article were defrayed in part by the payment of page charges. This article must therefore be hereby marked *advertisement* in accordance with 18 U.S.C. Section 1734 solely to indicate this fact.

¹ To whom requests for reprints should be addressed, at Yakult Central Institute for Microbiological Research, 1796 Yaho, Kunitachi-shi, Tokyo, 186-8650 Japan. Phone: (042) 577-8973; Fax: (042) 577-3020; E-mail: shoichi-kado@yakult.co.jp.

² The abbreviations used are: UC, ulcerative colitis; IBD, inflammatory bowel disease; TCR β and TCR α , T-cell receptor β chain and α chain; IL, interleukin; $\beta_2\text{m}$, $\beta_2\text{-microglobulin}$.

Table 1 Effect of microflora on the development of intestinal adenocarcinoma in $TCR\beta^{-/-}$ $p53^{-/-}$ mice

Group	Incidence				No. of proliferative lesions/mouse ^d				
	HP ^b	LGD	HGD	AC	HP	LGD	HGD	AC	Total
Cvd mice ^c	6/10	7/10	5/10	7/10	0.9 ± 0.99	1.4 ± 1.17	0.5 ± 0.53	0.8 ± 0.83	3.6 ± 1.71
GF mice ^d	1/10	0/10	0/10	0/10	0.1 ± 0.32	0	0	0	0.1 ± 0.32

^a Mean ± SD.

^b HP, hyperplasia; LGD, low-grade dysplasia; HGD, high-grade dysplasia; AC, adenocarcinoma.

^c Conventionalized mice.

^d Germ-free mice.

Nodular masses in the colon were classified using the categories of hyperplasia, low-grade dysplasia, high-grade dysplasia, and adenocarcinoma. Hyperplasia was defined as elongated crypts with increased mitotic figures deep in the crypts and extending to the medial portion; low-grade dysplasia was defined as moderate structural atypia, such as branching and distortion of crypts along with moderate cellular atypia and with increased mitotic figures in the superficial layer of the crypts; high-grade dysplasia was defined as marked structural atypia and cellular atypia without submucosal invasion of neoplastic glands; and adenocarcinoma was defined as a lesion demonstrating the histological features of high-grade dysplasia with submucosal invasion of neoplastic glands.

Results

All mice in the conventionalized group were noted to have one to five nodular masses, with a mean of 3.6 lesions per animal. These lesions were located in the cecum to proximal colon, particularly in the ileocecum, in all animals, whereas no such lesion was found caudad in the segment from the middle colon to rectum. In contrast, a nodular mass was found in the ileocecum of 1 animal in the group of 10 germ-free mice.

Histological data obtained showed the following incidences of proliferative lesions in the conventionalized mouse group: hyperplasia, 60%; low-grade dysplasia, 70%; high-grade dysplasia, 50%; and adenocarcinoma, 70%. The mean number of lesions per animal by histological type in this group was 0.9 for hyperplasia, 1.4 for low-grade dysplasia, 0.5 for high-grade dysplasia, and 0.8 for adenocarcinoma (Table 1). The only nodular mass noted in an animal in the germ-free mouse group was hyperplasia (Fig. 1A). Mucosal erosion and sporadic inflammatory cell, mostly neutrophil, and infiltrates in the lamina propria and/or submucosa were noted in areas of high-grade dysplasia (Fig. 1B) and adenocarcinoma (Fig. 1C) as well as occasional low-grade dysplasia in conventionalized mice. In some areas of hyperplasia, there was accumulation of lymphocytes in the lamina propria.

The relative incidences of hyperplasia, low-grade dysplasia, high-grade dysplasia, and adenocarcinoma by site in the conventionalized animals were compared (Fig. 2). The incidence of high-grade dysplasia plus adenocarcinoma was as high as 81.8% in the ileocecum and as low as ~28.5% in the cecum, whereas it was 0% in the proximal colon. Hence, there were obvious differences in the distribution of these lesions among different sites.

Because the occurrence of proliferative lesions was thus confined to the region of intestine from the ileocecum to the proximal colon, histological examination was also made of slides prepared from the region extending from the middle colon to the rectum that had shown no gross evidence of abnormalities, to detect inflammatory changes. Mild colitis (colitis scores 1 and 2) characterized by epithelial hyperplasia in the mucosa and inflammatory cell infiltrates in the lamina propria composed primarily of mononuclear cells was noted in 90% of the conventionalized mice, whereas in the germ-free mice, no such changes were observed (Fig. 3 and Table 2).

Discussion

We previously reported that, in mice deficient in $TCR\beta$ and $p53$ genes, adenocarcinoma of the colon developed spontaneously and

early in life with a notable frequency (21). The present study disclosed that the development of adenocarcinoma of the colon was completely suppressed in such mice when the animals were maintained with a germ-free status, demonstrating strong involvement of intestinal mi-

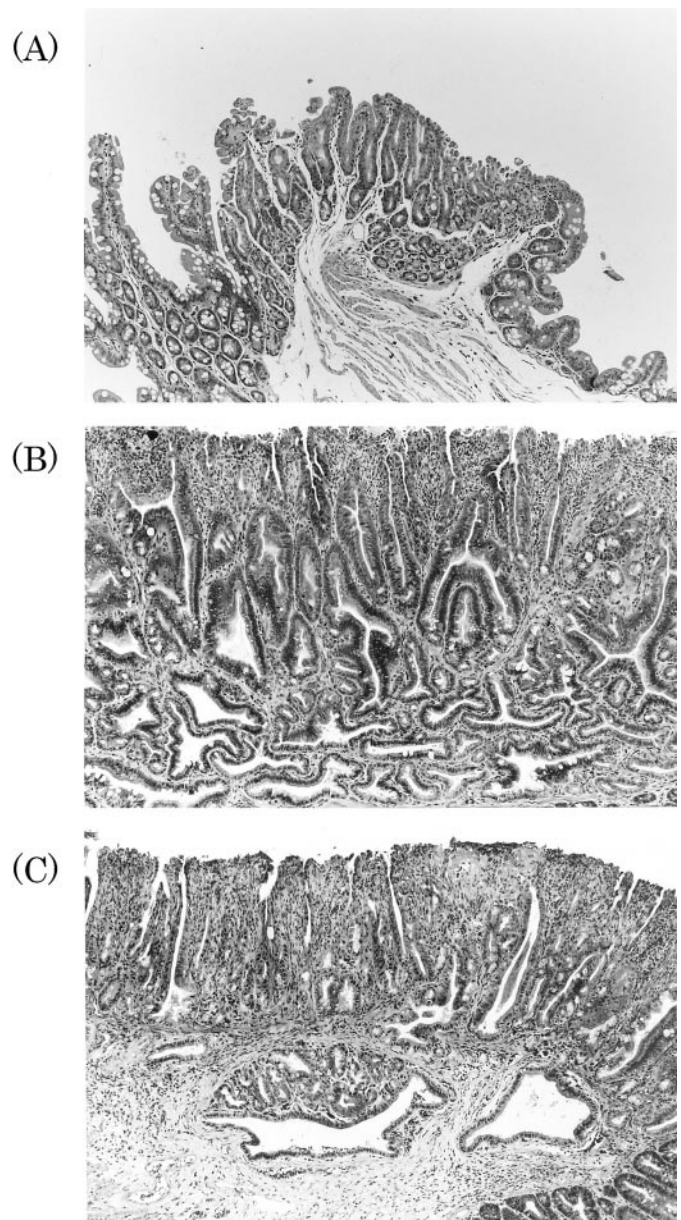


Fig. 1. Histopathology of proliferative lesions of ileocecum in germ-free (A) and conventionalized (B and C) $TCR\beta^{-/-}$ $p53^{-/-}$ mice. H&E staining; magnification, $\times 10$. A, epithelial hyperplasia. The crypts are elongated and largely parallel. B, high-grade dysplasia. Distortion and branching of the crypts, erosion and inflammation in the mucosa. C, invasive carcinoma. Note the neoplastic glands in the submucosa, transmural inflammation, and epithelial hyperplasia in the mucosa.

croflora in the development of neoplastic lesions in the colon in this mouse strain. The animals were sacrificed at 4 months of age in this study because mice of this strain are known to frequently develop lymphomas at or after the age of 4 months (21), resulting in a considerable decrease in survival rate. In fact, only two animals in each of the two groups developed mild lymphoma (data not shown), indicating that there is no evidence of any effect of intestinal microflora on the development of lymphoma at this stage. Further studies with longer experimental periods are needed to clarify the effect of microflora on lymphoma in these mice. The only study dealing with the relationship between spontaneous intestinal neoplasia and intestinal microflora was in an animal model for familial adenomatous polyposis, Apc^{Min} mice, reported by Dove *et al.* (28). These investigators indicated that intestinal microflora had no significant effect on the formation of adenomas in Apc^{Min} mice, based on the results of a similar experiment in germ-free *versus* conventionalized mice. It is of profound interest that the effect of intestinal microflora on neoplastic development varies substantially with differences in genetic background, and studies are needed to analyze the underlying mechanisms.

With the recent advances in gene manipulation techniques, a great variety of animal models that exhibit lesions similar to IBD have been introduced. Some of these models have been shown to develop colon cancer. Adenocarcinoma of the colon develops in 60% of $IL-10^{-/-}$ mice during the first 6 months of age, in 31% of $G\alpha_{12}^{-/-}$ mice between 15 and 36 weeks of age, and in 29% of $\beta_2m^{null} \times IL-2^{null}$ mice at 6–12 months of age (27, 29, 30). In $IL-2^{-/-}$, $IL-10^{-/-}$, and $TCR\alpha^{-/-}$ mice, among other IBD animal models, it is thought that intestinal microflora may play an important role in the spontaneous development of colitis in mice of these strains inasmuch as colitis does not occur when the animals are bred and maintained with a germ-free status (24–26). These reports and the present data suggest a possible major role of colitis induced by intestinal microflora in the formation of nodular masses and the development of adenocarcinoma of the colon in $TCR\beta^{-/-}$ $p53^{-/-}$ mice.

The adenocarcinomas observed in the conventionalized $TCR\beta^{-/-}$ $p53^{-/-}$ mice were confined to the ileocecum and cecum. Such a trend for localization of colon cancer has also been noted in other experimental models of knockout mice, *i.e.*, the colon and rectum in $IL-10^{-/-}$ mice, the proximal colon in $\beta_2m^{null} \times IL-2^{null}$ mice, and the cecum and all parts of the colon in $G\alpha_{12}^{-/-}$ mice (27, 29, 30). In the present series of conventionalized $TCR\beta^{-/-}$ $p53^{-/-}$ mice, practically equal numbers of nodular masses occurred in the ileocecum, cecum, and proximal colon, although no adenocarcinoma was found in the proximal colon.

Thus, $TCR\beta^{-/-}$ $p53^{-/-}$ mice, which develop adenocarcinoma of

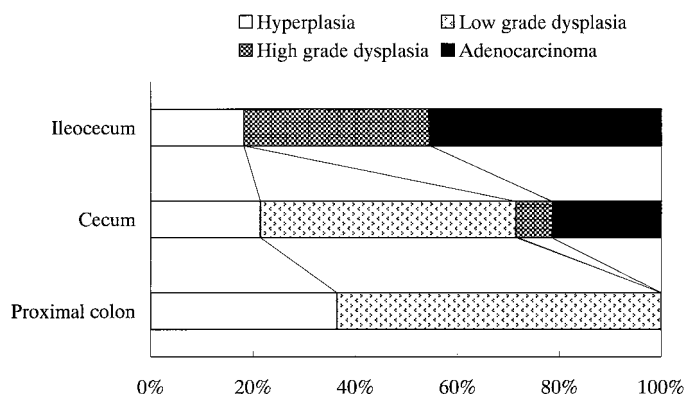


Fig. 2. Incidence and distribution of intestinal proliferative lesions in $TCR\beta^{-/-}$ $p53^{-/-}$ mice. Note that high-grade dysplasia and adenocarcinoma predominate in the majority of lesions of the ileocecum.

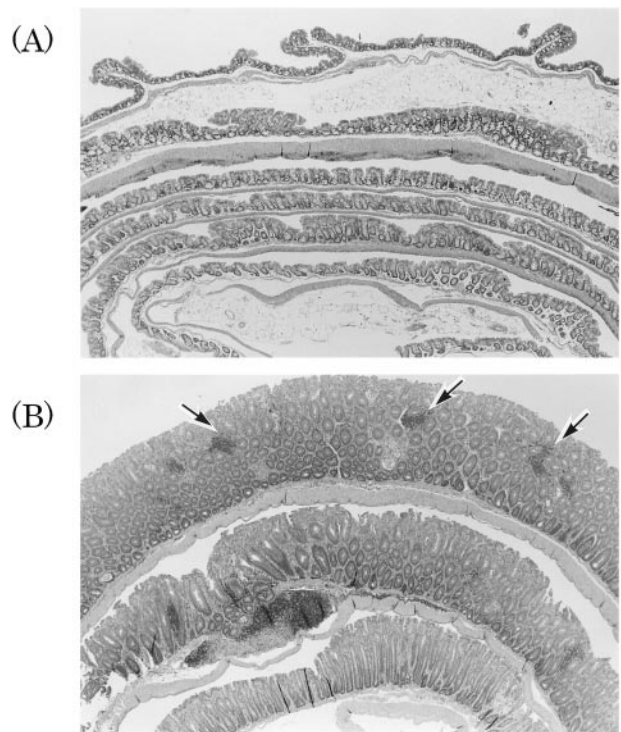


Fig. 3. Histopathology of colitis in germ-free (A) and conventionalized (B) $TCR\beta^{-/-}$ $p53^{-/-}$ mice. H&E staining; magnification, $\times 4$. A, no significant abnormality is observed (colitis score 0). B, several multifocal mononuclear cell infiltration (arrows) in the lamina propria, mild epithelial hyperplasia, and mucin depletion (colitis score 2).

Table 2 Effect of microflora on colitis in $TCR\beta^{-/-}$ $p53^{-/-}$ mice

Group	No. of mice examined	Colitis score				
		0	1	2	3	4
Cvd mice ^a	10	1	5	4	0	0
GF mice ^b	10	10	0	0	0	0

^a Conventionalized mice.

^b Germ-free mice.

the colon relatively early in life with a high frequency, are considered not only a useful colitis-dysplasia-carcinoma sequence model, but also to have potential usefulness as an animal model for clarifying the involvement of intestinal microflora in the development of adenocarcinoma of the colon. Further research is planned to prepare gnotobiotics of this mouse strain, to elucidate the relationship of intestinal microflora to carcinogenesis, and to follow tissue levels of cytokines and other inflammatory parameters in various segments of the intestinal tract over time in parallel with histological assessments to clarify the relationship between the occurrence of colitis and carcinogenesis.

Acknowledgments

We thank Dr. Susumu Tonegawa, at the Center for Cancer Research, Massachusetts Institute of Technology (Cambridge, MA) for invaluable discussions.

References

- Goldman, H. Significance and detection of dysplasia in chronic colitis. *Cancer (Phila.)*, 78: 2261–2263, 1996.
- Izkowitz, S. H., Greenwald, B., and Meltzer, S. J. Colon cancer in inflammatory bowel disease. *Inflamm Bowel Dis*, 1: 142–158, 1995.
- Mombaerts, P., Clarke, A. R., Rudnicki, M. A., Iacomini, J., Itoharu, S., Lafaille, J. J., Wang, L., Ichikawa, Y., Jaenisch, R., Hooper, M. L., and Tonegawa, S. Mutations in T-cell antigen receptor gene α and β block thymocyte development at different stages. *Nature (Lond.)*, 360: 225–231, 1992.

4. Mombaerts, P., Arnoldi, J., Russ, F., Tonegawa, S., and Kaufmann, S. H. E. Different roles of $\alpha\beta$ and $\gamma\delta$ T cells in immunity against an intracellular bacterial pathogen. *Nature (Lond.)*, *365*: 53–56, 1993.
5. Mombaerts, P., Mizoguchi, E., Ljunggren, H.-G., Iacomini, J., Ishikawa, H., Wang, L., Grusby, M. J., Glimcher, L. H., Winn, H. J., Bhan, A. K., and Tonegawa, S. Peripheral lymphoid development and function in TCR mutant mice. *Int. Immunol.*, *6*: 1061–1070, 1994.
6. Roberts, S., Smith, A. L., West, A. B., Wen, L., Findly, R. C., Owen, M. J., and Hayday, C. T-Cell $\alpha\beta^{+}$ and $\gamma\delta^{+}$ deficient mice display abnormal but distinct phenotypes toward a natural, widespread infection of the intestinal epithelium. *Proc. Natl. Acad. Sci. USA*, *93*: 11774–11779, 1996.
7. Mombaerts, P., Mizoguchi, E., Grusby, M. J., Glimcher, L. H., Bhan, A. K., and Tonegawa, S. Spontaneous development of inflammatory bowel disease in T cell receptor mutant mice. *Cell*, *75*: 275–282, 1993.
8. Malkin, D., Li, F. P., Strong, L. C., Fraumeni, J. F., Jr., Nelson, C. E., Kim, D. H., Kassel, J., Gryka, M. A., Bischoff, F. Z., Tainsky, M. A., and Friend, S. H. Germ line p53 mutations in a familial syndrome of breast cancer, sarcomas, and other neoplasms. *Science (Washington DC)*, *250*: 1233–1238, 1990.
9. Greenblatt, M. S., Bennett, W. P., Hollstein, M., and Harris, C. C. Mutations in the p53 tumor suppressor gene: clues to cancer etiology and molecular pathogenesis. *Cancer Res.*, *54*: 4855–4878, 1994.
10. Levine, A. J. p53, the cellular gatekeeper for growth and division. *Cell*, *88*: 323–331, 1997.
11. Vogelstein, B., and Kinzler, K. W. p53 function and dysfunction. *Cell*, *70*: 523–526, 1992.
12. Donehower, L. A., Harvey, M., Slagle, B. L., McArthur, M. J., Montgomery, C. A., Jr., Butel, J. S., and Bradley, A. Mice deficient for p53 are developmentally normal but susceptible to spontaneous tumours. *Nature (Lond.)*, *356*: 215–221, 1992.
13. Michele, H., Mark, J. M., Charles, A. M., Jr., Janet, S. B., Allan, B., and Lawrence, A. D. Spontaneous and carcinogen-induced tumorigenesis in p53-deficient mice. *Nat. Genet.*, *5*: 225–229, 1993.
14. Chaubert, P., Benhattar, J., Saraga, E., and Costa, J. K *ras* mutations and p53 alterations in neoplastic and non-neoplastic lesions associated with longstanding ulcerative colitis. *Am. J. Pathol.*, *144*: 767–775, 1994.
15. Kern, S. E., Redstone, M., Seymour, A. B., Caldas, C., Powell, S. M., Kornacki, S., and Kinzler, K. M. Molecular genetic profiles of colitis associated neoplasms. *Gastroenterology*, *107*: 420–428, 1994.
16. Harpaz, N., Peck, A. L., Yin, J., Fiel, I., Hontanosas, M., Tong, T. R., Laurin, J. N., Abraham, J. M., Greenwald, B. D., and Meltzer, S. J. p53 protein expression in ulcerative colitis-associated colorectal dysplasia and carcinoma. *Hum. Pathol.*, *25*: 1069–1074, 1994.
17. Brentnall, T. A., Crispin, D. A., Rabinovitch, P. S., Haggitt, R. C., Rubin, C. E., Stevens, A. C., and Burner, G. A. Mutations in the p53 gene: an early marker of neoplastic progression in ulcerative colitis. *Gastroenterology*, *107*: 369–378, 1994.
18. Burner, G. C., Crispin, D. A., Kolli, D. R., Haggitt, R. C., Kulander, B. G., Rugin, C. E., and Rabinovitch, P. S. Frequent loss of a p53 allele in carcinomas and their precursors in ulcerative colitis. *Cancer Commun.*, *3*: 167–172, 1991.
19. Yin, J., Harpaz, N., Tong, Y., Huang, Y., Laurin, J., Greenwald, B. D., Hontanosas, M., Newkirk, C., and Meltzer, S. J. p53 point mutations in dysplastic and cancerous ulcerative colitis lesions. *Gastroenterology*, *104*: 1633–1639, 1993.
20. Taylor, H. W., Boyle, M., Smith, S. C., Bustin, S., and Williams, N. S. Expression of p53 in colorectal cancer and dysplasia complicating ulcerative colitis. *Br. J. Surg.*, *80*: 442–444, 1993.
21. Funabashi, H., Uchida, K., Kado, S., Matsuoka, Y., and Ohwaki, M. Establishment of a *Terb* and *Trp53* genes deficient mouse strain as an animal model for spontaneous colorectal cancer. *Exp. Anim.*, *50*: 41–47, 2001.
22. Podolsky, D. K. Inflammatory bowel disease. *N. Engl. J. Med.*, *325*: 928–937, 1991.
23. Targan, S. R. The search for pathogenic antigens in ulcerative colitis. *Gastroenterology*, *114*: 1099–1100, 1998.
24. Sadlack, B., Merz, H., Schorle, H., Schimpl, A., Feller, A. C., and Horak, I. Ulcerative colitis-like disease in mice with a disrupted interleukin-2 gene. *Cell*, *75*: 253–261, 1993.
25. Sellon, R. K., Tonkonogy, S., Schultz, M., Dieleman, L. A., Grenther, W., Balish, E., Rennick, D. M., and Sartor, R. B. Resident enteric bacteria are necessary for development of spontaneous colitis and immune system activation in interleukin-10-deficient mice. *Infect. Immun.*, *66*: 5224–5231, 1998.
26. Dianda, Lee, Hanby, M., Wright, N. A., Sebesteny, A., Hayday, A. C., and Owen, M. J. T cell receptor- α -deficient mice fail to develop colitis in the absence of a microbial environment. *Am. J. Pathol.*, *150*: 91–97, 1997.
27. Berg, D. J., Davidson, N., Kuhn, R., Muller, W., Menon, S., Holland, G., Thompson-Snipes, L., Leach, M. W., and Rennick, D. Enterocolitis and colon cancer in interleukin-10-deficient mice are associated with aberrant cytokine production and CD4⁺ TH1-like response. *J. Clin. Invest.*, *98*: 1010–1020, 1996.
28. Dove, W. F., Clipson, L., Gould, K. A., Luongo, C., Marshall, D. J., Moser, A. R., Newton, M. A., and Jacoby, R. F. Intestinal neoplasia in the *Apc^{Min}* mouse: independence from the microbial and natural killer (*beige* Locus) status. *Cancer Res.*, *57*: 812–814, 1997.
29. Rudolph, U., Finegold, M. J., Rich, S. S., Harriman, G. R., Srinivasan, Y., Brabet, P., Boulary, G., Bradly, A., and Birnbaumer, L. Ulcerative colitis and adenocarcinoma of the colon in $G\alpha_{12}$ -deficient mice. *Nat. Genet.*, *10*: 143–150, 1995.
30. Shah, S. A., Simpson, J. S., Brown, L. D., Comiskey, M., de Jong, Y. P., Allen, D., and Terhorst, C. Development of colonic adenocarcinoma in a mouse model of ulcerative colitis. *Inflamm. Bowel Dis.*, *4*: 196–202, 1998.