

Prognosis of Primary Testicular Seminoma: A Report on 57 New Cases¹

Keita Fujikawa,² Yoshiyuki Matsui, Hiroya Oka, Shigeki Fukuzawa, Miharu Sasaki, and Hideo Takeuchi

Department of Urology, Kobe City General Hospital, Kobe City [K. F., Y. M., H. O., S. F., H. T.], and Department of Urology, Shizuoka City Hospital, Shizuoka City 420 [M. S.], Japan

ABSTRACT

Most urologists perform adjuvant radiation therapy for stage 1 ($T_xN_0M_0$) testicular seminoma after orchiectomy, although the majority of patients with clinical stage 1 seminoma do not have occult metastases and therefore do not require elective nodal irradiation. However, there are currently no clinical or histological parameters that can be used to distinguish patients who need radiation therapy from those who do not. We reported previously that estimates of volume-weighted mean nuclear volume (MNV) were a better predictor of the prognosis of prostate cancer and renal cell carcinoma than subjective histological grading. Here, we examined the usefulness of estimation of MNV for predicting the prognosis of primary testicular seminoma. A retrospective study of 57 patients with testicular seminoma diagnosed between April 1981 and March 1997 at Kobe City General Hospital was performed. Unbiased estimates of MNV data were compared for prognostic value with the level of β -human chorionic gonadotropin (β -HCG), α -fetoprotein (AFP), alkaline phosphatase (ALP), and lactate dehydrogenase (LDH). Fifty patients were stage 1 ($T_xN_0M_0$), and 7 patients were stage 2 ($T_xN_{1-2}M_0$). All patients received orchiectomy, followed by radiation therapy. Estimates of MNV of stage 2 patients were significantly larger than that of stage 1 patients ($P = 0.0142$). Although the LDH level was also significantly higher in stage 2 ($P = 0.001$), there were no significant differences between stages 1 and 2 with respect to β -HCG ($P = 0.997$), ALP ($P = 0.226$), and AFP ($P = 0.467$). Multivariate logistic regression analysis revealed that the estimate of MNV was the only variable predicting lymph node metastasis ($P = 0.0315$). In stage 1 patients, only the estimate of MNV was significantly correlated with progression-free survival ($P = 0.0118$). These findings indicate that the estimate of MNV may be an important prognostic indicator for testicular seminoma. Estimates of MNV may also be useful for excluding patients from surveillance protocols.

INTRODUCTION

Remarkable improvement in the prognosis of testicular tumors has recently been achieved. Metastatic disease can be cured in the majority of patients by multiagent systemic chemotherapy after orchiectomy (1, 2). Patients with clinical stage 1 seminoma are treated by orchiectomy plus external radiation to the retroperitoneal lymph nodes at risk of harboring subclinical micrometastases (the ipsilateral pelvic and para-aortic nodes), and this approach has achieved long-term cure rates of greater than 90–95% (3, 4). It is generally accepted that approximately 10–20% of clinical stage 1 seminoma patients have occult disease in the abdomen (5). Therefore, this policy of elective adjuvant regional nodal irradiation means that ~85% of patients are being treated unnecessarily (6). If it were possible to more accurately stage seminoma, many patients could avoid the side effects of radiation therapy, and medical costs would also be decreased. However, conventional histopathological findings cannot be used to identify patients with occult retroperitoneal metastases (7).

Received 9/23/99; accepted 2/16/00.

The costs of publication of this article were defrayed in part by the payment of page charges. This article must therefore be hereby marked *advertisement* in accordance with 18 U.S.C. Section 1734 solely to indicate this fact.

¹ This study was partly supported by the Kobe City Foundation for Medical Research.

² To whom requests for reprints should be addressed, at Department of Urology, Kobe City General Hospital, Minatogima-nakamachi 4-6, Chuo-ku, Kobe City 650, Japan. Phone: 81-78-302-4321; Fax: 81-78-302-2487; E-mail: PS5K-FJKW@asahi-net.or.jp.

Calculation of the volume-weighted MNV³ is the only method by which an unbiased estimate of a three-dimensional parameter can be obtained from single two-dimensional sections (8). The MNV was developed by Gunderson and Jensen (9, 10), based on a stereological method. We have reported previously that this parameter is prognostically important for prostate cancer (11–14), renal cell carcinoma (15), and bladder cancer (16). However, the relationship between MNV and the prognosis of seminoma has not been investigated thus far. In an effort to identify the subset of patients with clinical stage 1 seminoma who may be monitored after orchiectomy rather than requiring elective regional nodal irradiation, we examined the clinical and pathological features of 57 patients, including calculation of their MNV values.

PATIENTS AND METHODS

Patients. Ninety-seven patients with primary testicular tumors were diagnosed at Kobe City General Hospital between 1981 and 1997. All patients underwent orchiectomy, and 57 patients had a final diagnosis of primary pure seminoma after examination of orchiectomy specimens (classic in 53, spermatocytic in 1, and anaplastic in 3). Pretreatment staging was done with physical examination, excretory urography, chest X-ray, bone scan, and computerized tomography of the retroperitoneum. Fifty patients were classified as clinical stage 1 ($T_xN_0M_0$), and 7 patients were classified as stage 2 ($T_xN_{1-2}M_0$). All patients received radiation therapy to the ipsilateral pelvic and para-aortic nodes. Four patients who had residual retroperitoneal masses after irradiation were treated with platinum-based chemotherapy and retroperitoneal lymph node dissection. Patients were followed up every 1–3 months. Routine tests included physical examination, chest X-rays, skeletal survey, ultrasonography, or computerized tomography of the abdomen and serum tumor markers. In this study, unbiased estimates of MNV were compared with the levels of β -HCG, AFP, ALP, and LDH to assess their relative prognostic value. At the time of study completion, 52 patients were still alive, and 5 had died. The mean follow-up period for the surviving patients was 61.1 months (range, 24–192 months).

MNV. The slides used for histological tumor grading were used for the stereological calculation of MNV. An Olympus BHS microscope (Olympus, Tokyo, Japan), with a projection attachment and a $\times 100$ oil immersion lens (numerical aperture, 1.4), was used to obtain the quantitative histopathological variables. The final calibrated magnification was $\times 1600$. A section from each seminoma was projected onto the used test system. In each specimen, the three-dimensional nuclei were first sampled in proportion to height by the histological slide. The nuclei were then resampled in proportion to the sectional area with a point-grid, and only nuclear profiles hit by points were sampled for the estimation of MNV, *i.e.*, nuclei are sampled proportional to height \times sectional area = volume (8). On the point-sampled nuclear profiles, nuclear intercepts were measured from nuclear boundary to nuclear boundary through the sampling point in one direction, as indicated by the test system. A minimum of four visual fields and a minimum of 50 nuclei are needed to calculate MNV (9, 10); thus, 4–10 fields of vision (average, 6.3) obtained at random and 60–120 intercepts (average, 85.1) were examined in each patient. An unbiased estimate of MNV was obtained by multiplying the mean of the cubed intercept length by $\pi/3$. A detailed description of the techniques used, including the formulae and calculations, has been published previously (8–10).

Statistics. Progression-free survival was estimated from Kaplan-Meier plots, and differences between groups were assessed with the log-rank test.

³ The abbreviations used are: MNV, mean nuclear volume; β -HCG, β -human chorionic gonadotropin; AFP, α -fetoprotein; ALP, alkaline phosphatase; LDH, lactate dehydrogenase.

Table 1 Significance of each prognostic factor with regard to the presence of lymph node metastasis in 57 patients with testicular seminoma

	Stage 1 (50 cases)	Stage 2 (7 cases)	P
Age at diagnosis	41.6 (23–71)	48.4 (32–62)	0.2461
Histology			
Classic	46	7	NA ^a
Spermatocytic	1	0	
Anaplastic	3	0	
LDH	473.5 (276–959)	622.7 (479–804)	0.0010
β-HCG	2.315 (0–43.5)	2.327 (0.26–5.60)	0.9972
AFP	2.515 (0–6.6)	1.914 (0–4.1)	0.4668
ALP	141.3 (107–791)	219.0 (86–596)	0.2258
Estimates of MNV	626.2 (259.4–1066.7)	891.4 (609.5–1238.2)	0.0142

^a NA, not analyzed.

Table 2 Multivariate logistic regression analysis of the possible predictors of lymph node metastasis in 57 patients with testicular seminoma

	Coefficient	P	Risk ratio
LDH	0.0041	0.0538	1.0041
Estimates of MNV	2.7404	0.0315	1.5010
AFP	−0.2402	0.4175	0.7865
β-HCG	−0.0075	0.9242	0.9924
ALP	−0.0016	0.7271	0.9984

Multivariate logistic regression analysis was performed using SPSS software (Statistical Package for the Social Sciences; SPSS, Inc., Chicago, IL) to determine the variables that were correlated independently with the prognosis. Comparisons between group means were done using the Mann-Whitney U test. More than two groups were analyzed by the nonparametric Kruskal-Wallis test. The limit of significance for all tests was $P < 0.05$.

RESULTS

Lymph Node Metastasis. The mean estimate of MNV calculated for stage 2 patients was $891.4 \mu\text{m}^3$, whereas that of stage 1 patients was $626.2 \mu\text{m}^3$. Therefore, the MNV was significantly larger in stage 2 ($P = 0.0142$, Table 1). Although the LDH level was significantly higher in stage 2 than in stage 1 ($P = 0.001$), there were no significant differences between the two stages with regard to the levels of β-HCG ($P = 0.997$), ALP ($P = 0.226$), and AFP ($P = 0.467$, Table 1). Multivariate logistic regression analysis revealed that estimates of MNV were the only prognostic factor predicting lymph node metastasis ($P = 0.0315$, Table 2).

Progression-free Survival. Factors predicting disease progression were analyzed for the stage 1 patients. Five stage 1 patients showed progression during the follow-up period, with four developing mediastinal lymph node metastasis and one developing inguinal lymph node metastasis. Fifty stage 1 patients were classified by their MNV values, which ranged from 259.4 to $1066.7 \mu\text{m}^3$, with a median of $620 \mu\text{m}^3$. Progression-free survival curves are shown in Fig. 1. The prognosis of the $\text{MNV} \geq 620 \mu\text{m}^3$ group was significantly worse than that of the $\text{MNV} < 620 \mu\text{m}^3$ group ($P = 0.0118$). LDH ($P = 0.3274$), β-HCG ($P = 0.3424$), ALP ($P = 0.1210$), and AFP ($P = 0.9870$) were of no prognostic value.

DISCUSSION

The prognosis of testicular tumors has improved remarkably with the development of techniques for imaging the retroperitoneum, as well as introduction of new chemotherapy agents and identification of sensitive tumor markers (7). Many seminoma patients can be cured by radiation therapy and platinum-based chemotherapy, even when they have distant metastases (1–4). On the other hand, most urologists irradiate the retroperitoneal lymph nodes after orchiectomy for clinically localized (stage 1) seminoma. In fact, the majority of stage 1

seminomas can be cured by orchiectomy alone; therefore it would be desirable to spare patients the unpleasant side effects of irradiation, such as gastrointestinal disturbance, reduced fertility, a risk of secondary retroperitoneal tumors, and anxiety. In a recent study performed in England, 7 of 52 patients (13%) with clinical stage 1 seminoma managed by surveillance after orchiectomy developed recurrence during a follow-up period of 12–41 months (5). Unfortunately, computed tomographic scans cannot identify micrometastases, and conventional histopathological findings cannot identify the patients who have occult retroperitoneal metastases (6, 7). Pathological assessment remains difficult and is subject to interobserver variation. Nativ *et al.* (7) reported on the importance of the nuclear DNA ploidy pattern in seminoma, whereas Hittmair *et al.* (17) stated that a diploid seminoma on flow cytometry is most likely associated with extensive lymphatic infiltration. The present study focused on whether accurate prediction of the malignant potential of seminoma was possible by using ordinary histological slides.

An estimate of MNV is the only method by which an unbiased estimate of three-dimensional parameters can be obtained from a single two-dimensional histological section (8). This parameter was developed by Gunderson and Jensen (9, 10) and is based on a stereological method. It has been proven by Sørensen *et al.* (18), Baak *et al.* (19), Nielsen *et al.* (20), and ourselves (21) to be highly reproducible. Since Weibel (22) discussed the application of stereology to cancer research, the value of MNV as a prognostic factor has been demonstrated for several tumors (11–16, 23–25). We reported previously that MNV was a better predictor of the prognosis of prostate cancer (11–14) and renal cell carcinoma (15) than subjective histological grading. Sørensen and Muller (26) reported that the MNV of testicular carcinoma *in situ* was significantly larger than that of morphologically normal spermatogonia, but no previous study has assessed the relationship between estimates of MNV and the prognosis of seminoma.

When we analyzed the relationship between lymph node metastasis and several prognostic factors, multivariate analysis showed that the estimate of MNV was the only factor predicting lymph node metastasis. It would have been better to study a group of pathologically staged cancer patients, but unfortunately, this is not possible in clinical practice. Despite this limitation, our findings revealed a clear trend. Furthermore, no stage 1 patient with a small estimate of MNV showed disease progression during the follow-up period. These findings suggest that patients with a small MNV and no apparent lymph

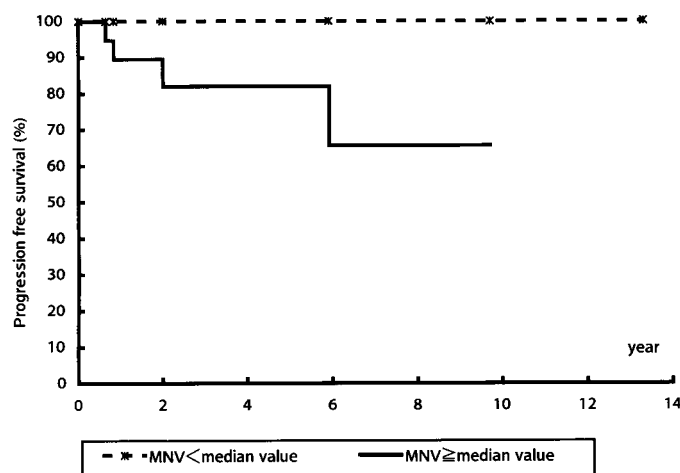


Fig. 1. Kaplan-Meier progression-free survival curves for 50 patients with stage 1 ($T_xN_0M_0$) testicular seminoma stratified according to the MNV. —, $\text{MNV} \geq 620 \mu\text{m}^3$; - - -, $\text{MNV} < 620 \mu\text{m}^3$.

node metastasis on computed tomographic scans may be candidates for surveillance rather than radiotherapy.

Several problems remain to be solved before clinical use of estimates of MNV will become possible. The cut-off value that best reflects the biological characteristics of seminoma needs to be determined. Although we used the median as the cut-off value in the present study, further investigation of a larger number of patients at multiple institutions will be required to provide a more definitive answer. There have been no objective criteria for predicting the outcome of patients with seminoma. However, the present study suggested the possibility that MNV might be one such criterion; therefore, additional studies must be performed to assess the reproducibility of this finding.

In conclusion, estimates of MNV may be prognostically important for seminoma. No special training is needed to measure MNV; only a projector and microscope are required, and evaluation can be performed in 10–15 min with excellent reproducibility. Taking this into account, we recommend MNV estimation for predicting the outcome of patients with seminoma. MNV may also be a useful criterion for excluding patients from surveillance.

ACKNOWLEDGMENTS

We thank Dr. Sørensen, Stereological Research Laboratory, and University Institute of Pathology, Aarhus Kommunehospital, University of Aarhus, Denmark, for technical assistance.

REFERENCES

- Fossa, S. D., Borge, L., Aass, N., Johannessen, N. B., Stenwig, A. E., and Kaalhus, O. The treatment of advanced metastatic seminoma: experience in 55 cases. *J. Clin. Oncol.*, 5: 1071–1078, 1987.
- Loehrer, P. J., Sr., Birch, R., Williams, S. D., Greco, F. A., and Einhorn, L. H. Chemotherapy of metastatic seminoma: the Southeastern Cancer Study Group experience. *J. Clin. Oncol.*, 5: 1212–1220, 1987.
- Epstein, B. E. W., Order, S. E., and Zinreich, E. S. Staging, treatment and results in testicular seminoma: a 12 year report. *Cancer (Phila.)*, 65: 405–411, 1990.
- Bayems, Y. C., Helle, P. A., Van Patten, W. I. J., and Mali, S. P. M. Orchiectomy followed by radiotherapy in 176 stage 1 and 2 testicular seminoma patients: benefits of a 10 year follow-up study. *Radiat. Oncol.*, 25: 97–102, 1992.
- Peckman, M. J., Hamilton, C. R., Horwich, A., and Hendry, W. F. Surveillance after orchiectomy for stage 1 seminoma of the testis. *Br. J. Urol.*, 59: 343–351, 1987.
- Marks, L. B., Rutgers, J. L., Shipley, W. U., Walker, T. G., Stracher, M. S., Waltman, A. C., and Geller, S. C. Testicular seminoma: clinical and pathological features that may predict para-aortic lymph node metastasis. *J. Urol.*, 143: 524–527, 1990.
- Nativ, O., Winkler, H. Z., Reiman, H. R. J., Earle, J. D., and Lieber, M. M. Primary testicular seminoma: prognostic significance of nuclear DNA ploidy pattern. *Eur. Urol.*, 31: 401–404, 1997.
- Sørensen, F. B. Biology of disease. Quantitative analysis of nuclear size for objective malignancy grading: a review with emphasis on new, unbiased stereologic methods. *Lab. Invest.*, 66: 4–23, 1992.
- Gundersen, H. J. G., and Jensen, E. B. Particle sizes and their distributions estimated from line- and point-sampled intercepts. Including graphical unfolding. *J. Microsc.*, 131: 291–310, 1983.
- Gundersen, H. J. G., and Jensen, E. B. Stereological estimation of the volume-weighted mean volume of arbitrary particles observed on random sections. *J. Microsc.*, 138: 127–142, 1985.
- Fujikawa, K., Sasaki, M., Aoyama, T., Itoh, T., and Yoshida, O. Prognostic criteria in patients with prostate cancer: correlation with volume weighted mean nuclear volume. *J. Urol.*, 154: 2123–2127, 1995.
- Fujikawa, K., Sasaki, M., Arai, Y., Yamabe, H., Ogawa, O., and Yoshida, O. Prognostic criteria in patients with prostate cancer: Gleason score versus volume-weighted mean nuclear volume. *Clin. Cancer Res.*, 3: 613–618, 1997.
- Fujikawa, K., Sasaki, M., Itoh, T., Arai, Y., Ogawa, O., and Yoshida, O. Combining volume-weighted mean nuclear volume with Gleason score and clinical stage to predict more reliably disease outcome of the patients with prostate cancer. *Prostate*, 37: 63–69, 1998.
- Fujikawa, K., Aoyama, T., Itoh, T., Nishio, Y., Miyakawa, M., and Sasaki, M. The role of volume-weighted mean nuclear volume for predicting disease outcome in patients with stage M1 prostate cancer. *Acta Pathol. Microbiol. Immunol. Scand.*, 107: 395–400, 1999.
- Fujikawa, K., Sasaki, M., Aoyama, T., and Itoh, T. The role of volume-weighted mean nuclear volume for predicting disease outcome in patients with renal cell carcinoma. *J. Urol.*, 157: 1237–1241, 1997.
- Sasaki, M., Sørensen, F. B., Fukuzawa, S., Yamabe, H., Olsen, S., and Yoshida, O. Quantitative histopathology in the prognostic evaluation of patients with transitional cell carcinoma of the urinary bladder. *Cancer (Phila.)*, 72: 2470–2483, 1993.
- Hittmair, A., Rogatsch, H., Feichtinger, H., Hobisch, A., and Mikuz, G. Testicular seminomas are aneuploid tumors. *Lab. Invest.*, 72: 70–74, 1995.
- Sørensen, F. B., Sasaki, M., Fukuzawa, S., Yamabe, H., Olsen, S., and Yoshida, O. Qualitative and quantitative histopathology in transitional cell carcinoma of the urinary bladder. *Lab. Invest.*, 70: 242–254, 1994.
- Baak, J. P. A., Ladekarl, M., and Sørensen, F. B. Reproducibility of mean nuclear volume and correlation with mean nuclear area in breast cancer: an investigation of various sampling schemes. *Hum. Pathol.*, 25: 80–85, 1994.
- Nielsen, K., Berlid, G. H., Bruun, E., Jørgensen, P. E., and Weis, N. Stereological estimates of mean nuclear volume in prostatic cancer, the reproducibility and the possible value of estimations on repeated biopsies in the course of disease. *J. Microsc.*, 154: 63–69, 1989.
- Fujikawa, K., Aoyama, T., Itoh, T., Nishio, Y., Miyakawa, M., and Sasaki, M. Is new prognosticator “volume-weighted mean nuclear volume” comparable in multiple institutions? *Anal. Quant. Cytol. Histol.*, 22: 55–61, 2000.
- Weibel, E. R. The value of stereology in analyzing structure and function of cells and organs. *J. Microsc.*, 95: 3–10, 1972.
- Sørensen, F. B., Kristensen, I. B., Grymer, F., and Jakobsen, A. DNA level, tumor thickness and stereological estimates of nuclear volume in stage 1 cutaneous malignant melanoma. *Am. J. Dermatol.*, 13: 11–18, 1991.
- Nielsen, K., Orntoft, T., and Wolf, H. Stereological estimates of nuclear volume in noninvasive bladder tumors (Ta) correlated with the recurrence pattern. *Cancer (Phila.)*, 64: 2269–2275, 1989.
- Madsen, C., and Schroder, H. D. Stereological estimation of nuclear mean volume in invasive meningioma. *Acta Pathol. Microbiol. Immunol. Scand.*, 104: 103–107, 1996.
- Sørensen, F. B., and Muller, J. Stereological estimates of nuclear volume in normal germ cells and carcinoma *in situ* of the human testis. *Histopathology*, 17: 327–334, 1990.