

Clinical Implications of Expression of Interleukin 8 Related to Angiogenesis in Uterine Cervical Cancers

Jiro Fujimoto,¹ Hideki Sakaguchi, Ikumi Aoki, and Teruhiko Tamaya

Department of Obstetrics and Gynecology, Gifu University School of Medicine, Gifu City 500-8705, Japan

ABSTRACT

There was a significant correlation between microvessel counts and interleukin (IL)-8 levels and between infiltrated macrophage counts and IL-8 levels in uterine cervical cancers. Immunohistochemical staining revealed that the localization of IL-8 was similar to that of CD68 for macrophages. The prognosis of the 20 patients with high IL-8 (>1000 pg/mg protein) in uterine cervical cancers was extremely poor, whereas the 24-month survival rate of the other 60 patients with low IL-8 (<1000 pg/mg protein) was 67%. Therefore, this indicates that IL-8 might be a prognostic indicator as an angiogenic factor supplied from macrophages within and around the tumor.

INTRODUCTION

Angiogenesis is essential for development, growth, and advancement of solid tumors (1). Although angiogenic factors for tumor angiogenesis have been considered to be produced by tumor cells, it has been demonstrated that they are also produced by interstitial cells within and around the tumor. In uterine cervical cancers, especially adenocarcinomas of the cervix, VEGF² (particularly the VEGF₁₆₅ and VEGF₁₂₁ isoforms) was dominantly expressed in cancer cells (2). Furthermore, VEGF levels correlated with microvessel density (2). However, bFGF and PD-ECGF were expressed in both cancer and interstitial cells of uterine cervical cancers, and PD-ECGF was dominantly expressed in interstitial cells of squamous cell carcinomas of the cervix (3, 4). Furthermore, PD-ECGF levels correlated with microvessel density and patient prognosis in metastatic and primary lesions of uterine cervical cancers (4, 5).

It is well known that infiltration of inflammatory cells is activated in malignant tumors, which contributes to angiogenesis. The tumor-associated macrophage has been recognized as a candidate among inflammatory cells for tumor angiogenesis (6). The macrophages that infiltrate tumors of the liver and the gastrointestinal tract supply bFGF (7), and those that infiltrate breast and ovarian cancers supply VEGF (8) and TNF- α (9). Although TNF- α possesses weak angiogenic activity in itself, the angiogenic potential of TNF- α appears to be modulated through induction of the strong angiogenic factors IL-8, VEGF, and bFGF, and this pathway is regulated through paracrine and/or autocrine mechanisms (10). IL-8 is expressed in macrophages and fibroblasts derived from the interstitium (7) and was recognized as a macrophage-derived mediator of angiogenesis (11). This prompted us to study the clinical implications of macrophage-derived angiogenesis in uterine cervical cancers.

MATERIALS AND METHODS

Patients. Consent for the following studies was obtained from all patients and from the Research Committee for Human Subjects, Gifu University School of Medicine. Eighty patients ranging from 37–74 years of age underwent curative resection for cervical cancer. Patient prognosis was analyzed with a 24-month survival rate after curative resection at the Department of Obstetrics and Gynecology, Gifu University School of Medicine between June 1994 and April 1997. None of the patients had received any preoperative therapy. A part of each uterine cervical cancer tissue was obtained immediately after hysterectomy and snap-frozen in liquid nitrogen to determine the levels of IL-1 α , IL-1 β , TNF- α , IL-8, bFGF, VEGF, and PD-ECGF, and a neighboring part of the tissue was submitted for histopathological study. The clinical stage of uterine cervical cancers was determined by the FIGO classification (12).

Immunohistochemistry. Four- μ m sections of formalin-fixed paraffin-embedded tissue of uterine cervical cancers were cut with a microtome and dried overnight at 37°C on a silanized slide (DAKO, Carpinteria, CA). Samples were deparaffinized in xylene at room temperature for 80 min, washed with a graded ethanol/water mixture, and then with distilled water. The samples for IL-8 and CD68 antigens were soaked in a citrate buffer and then microwaved at 100°C for 10 min, and those for factor VIII-related antigen were treated with 0.3 μ g/ml trypsin in PBS at room temperature for 20 min. The protocol for DAKO LSAB2 Kit Peroxidase (DAKO) was followed for each sample. In the described procedures, rabbit antihuman IL-8 (Biosource, CA), mouse antihuman macrophage CD68 (DAKO), and rabbit anti-factor VIII-related antigen (Zymed, San Francisco, CA) were used at dilutions of 1:50, 1:50, and 1:2, respectively, as the first antibodies. The addition of the first antibody, rabbit antihuman IL-8, mouse antihuman macrophage CD68, or rabbit anti-factor VIII-related antigen, was omitted in the protocols for negative controls of IL-8, CD68, or factor VIII-related antigen, respectively.

Vessels and macrophages were counted in the five highest density areas at $\times 200$ magnification (using a combination of a $\times 20$ objective and a $\times 10$ ocular; 0.785 mm²/field). MVC and IMC were expressed as the mean numbers of vessels and macrophages in these areas, respectively (13, 14). Microvessel density and macrophage infiltration were evaluated by counting microvessels and macrophages, respectively.

Enzyme Immunoassay for Determination of IL-1 α , IL-1 β , TNF- α , IL-8, bFGF, VEGF, and PD-ECGF Antigens. All steps were carried out at 4°C. Tissues of uterine cervical cancers (wet weight, 10–20 mg) were homogenized in HG buffer [5 mM Tris-HCl (pH 7.4), 5 mM NaCl, 1 mM CaCl₂, 2 mM ethyleneglycol-bis- β -aminoethyl ether]-N,N,N',N'-tetraacetic acid, 1 mM MgCl₂, 2 mM DTT, 25 μ g/ml aprotinin, and 25 μ g/ml leupeptin] with a Polytron homogenizer (Kinematics, Luzern, Switzerland). This suspension was centrifuged in a microfuge at 12,000 rpm for 3 min to obtain the supernatant. The protein concentration of samples was measured by the method of Bradford (15) to standardize IL-1 α , IL-1 β , TNF- α , IL-8, bFGF, VEGF, and PD-ECGF antigen levels.

IL-1 α , IL-1 β , TNF- α , IL-8, bFGF, and VEGF antigen levels in the samples were determined by a sandwich enzyme immunoassay using human IL-1 α quantikine (R&D Systems, Minneapolis, MN), human IL-1 β quantikine (R&D Systems), human TNF- α quantikine (R&D Systems), human IL-8 quantikine (R&D Systems), human bFGF quantikine (R&D Systems), and human VEGF assay kit-IBL (Immuno Biological Laboratories, Gunma, Japan), respectively, and PD-ECGF antigen levels were determined by the method described by Nishida *et al.* (16). The levels of IL-1 α , IL-1 β , TNF- α , IL-8, bFGF, VEGF, and PD-ECGF were standardized with the corresponding cellular protein concentrations.

Statistics. Survival curves were calculated using the Kaplan-Meier method and analyzed by the log-rank test. IL-1 α , IL-1 β , TNF- α , IL-8, bFGF, VEGF, and PD-ECGF levels were measured from three parts of the same tissue in

Received 9/23/99; accepted 3/21/00.

The costs of publication of this article were defrayed in part by the payment of page charges. This article must therefore be hereby marked *advertisement* in accordance with 18 U.S.C. Section 1734 solely to indicate this fact.

¹ To whom requests for reprints should be addressed, at Department of Obstetrics and Gynecology, Gifu University School of Medicine, 40 Tsukasa-machi, Gifu City 500-8705, Japan. Phone: 81-58-267-2631; Fax: 81-58-265-9006.

² The abbreviations used are: VEGF, vascular endothelial growth factor; bFGF, basic fibroblast growth factor; PD-ECGF, platelet-derived endothelial cell growth factor; TNF, tumor necrosis factor; IL, interleukin; MVC, microvessel count; IMC, infiltrated macrophage count; FIGO, International Federation of Gynecology and Obstetrics.

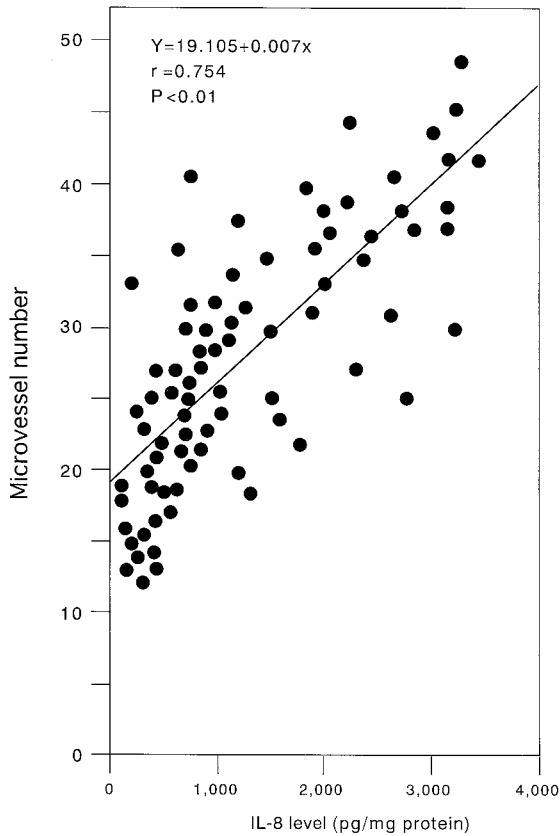


Fig. 1. Correlation between microvessel number and IL-8 level in uterine cervical cancers.

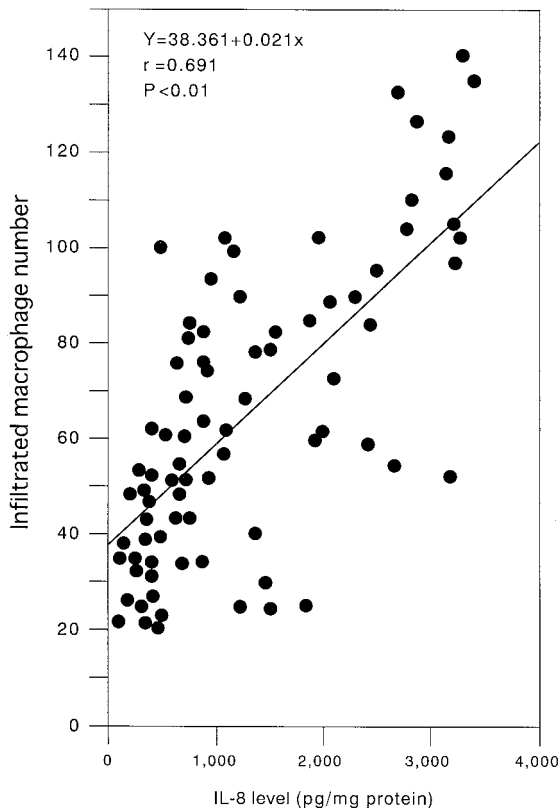


Fig. 2. Correlation between infiltrated macrophage number and IL-8 level in uterine cervical cancers.

triplicate. Statistical analysis was performed with Student's *t* test. Differences were considered significant when *P* was less than 0.05.

RESULTS

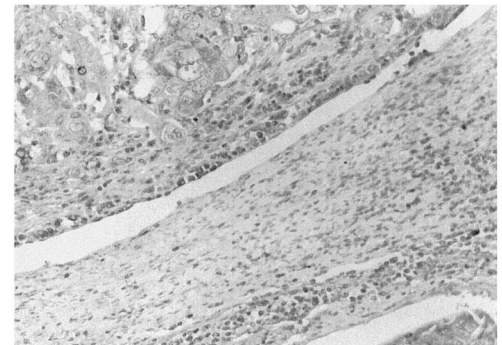
There was a significant correlation between MVCs and IL-8 (*P* < 0.01, as shown in Fig. 1), bFGF (*P* < 0.01), VEGF (*P* < 0.01), and PD-ECGF levels (*P* < 0.01) in uterine cervical cancers, but not between MVCs and IL-1 α , IL-1 β , or TNF- α .

There was a significant correlation between IMCs and IL-8 levels in uterine cervical cancers, as shown in Fig. 2 (*P* < 0.01), but not between IMCs and IL-1 α , IL-1 β , TNF- α , bFGF, VEGF, or PD-ECGF (data not shown).

Immunohistochemical staining for IL-8 and CD68 in a representative case of adenocarcinoma is shown in Fig. 3. IL-8 was distributed in the interstitium within and around the tumor. CD68 was found in a localization and manner similar to IL-8 in all cases.

There was no significant correlation between histopathological type

IL-8



CD68



negative control

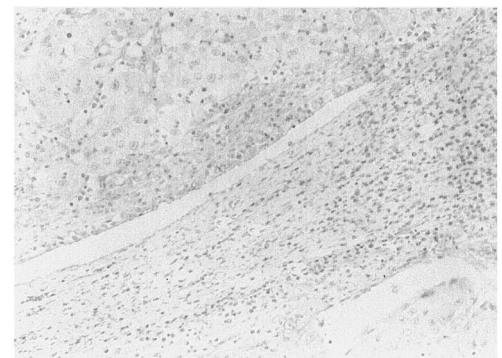

Fig. 3. Immunohistochemical staining for IL-8 and CD68 in uterine cervical cancers (original magnification, $\times 200$). A case of adenocarcinoma of the uterine cervix is shown. Rabbit antihuman IL-8 (Biosource) and mouse antihuman macrophage CD68 (DAKO) were each used at a dilution of 1:50 as the first antibodies. The addition of the first antibody was omitted in the protocols for negative controls of IL-8 and CD68 antigens. Dark gray staining, positive for IL-8 and CD68 antigens.

and IL-8 levels, as shown in Fig. 4. There was a significant difference ($P < 0.05$) in IL-8 levels between early-stage (stage I) and late-stage (stages II–IV) uterine cervical cancers, as shown in Fig. 5.

The prognosis of the 20 patients with high IL-8 (>1000 pg/mg protein) in uterine cervical cancers was extremely poor, whereas the 24-month survival rate of the other 60 patients with low IL-8 (<1000 pg/mg protein) was 67% (Fig. 6).

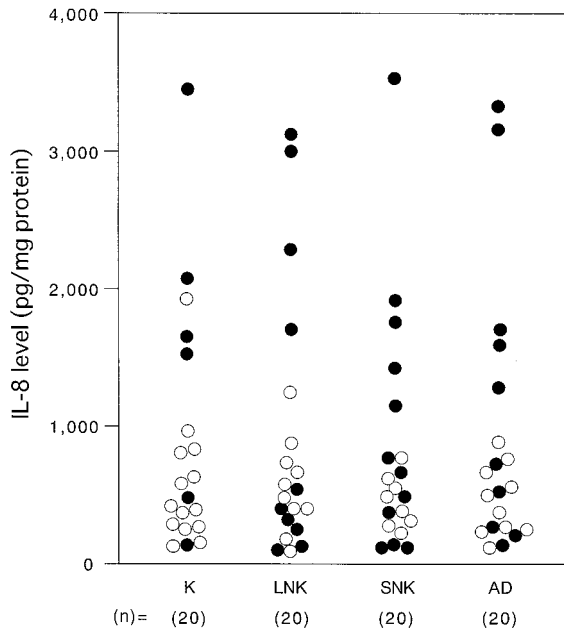


Fig. 4. Levels of IL-8 in uterine cervical cancers classified according to histopathological type. Histological types of uterine cervical cancers were assessed according to FIGO classification. Each level is the mean \pm SD of nine determinations. Living and deceased cases are shown as \circ and \bullet , respectively. *K*, keratinizing squamous cell carcinoma; *LNK*, large cell nonkeratinizing squamous cell carcinoma; *SNK*, small cell nonkeratinizing squamous cell carcinoma; *AD*, adenocarcinoma.

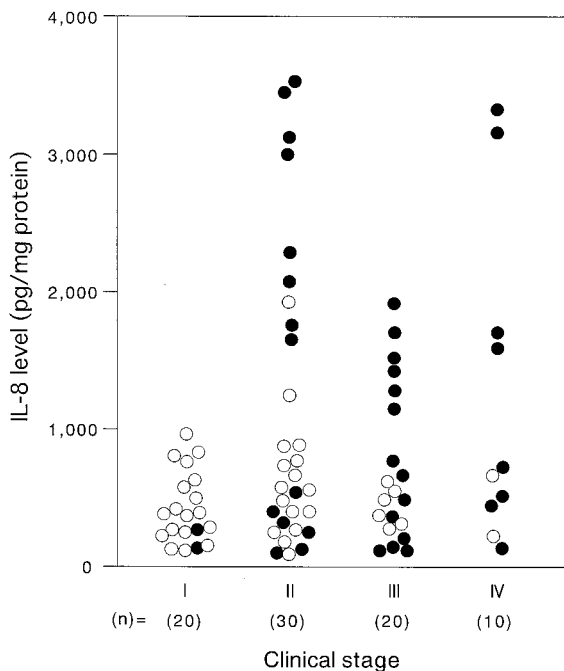


Fig. 5. Levels of IL-8 in uterine cervical cancers classified according to clinical stages. Clinical stages of uterine cervical cancer were assessed according to FIGO classification. Each level is the mean \pm SD of nine determinations. Living and deceased cases are shown as \circ and \bullet , respectively.

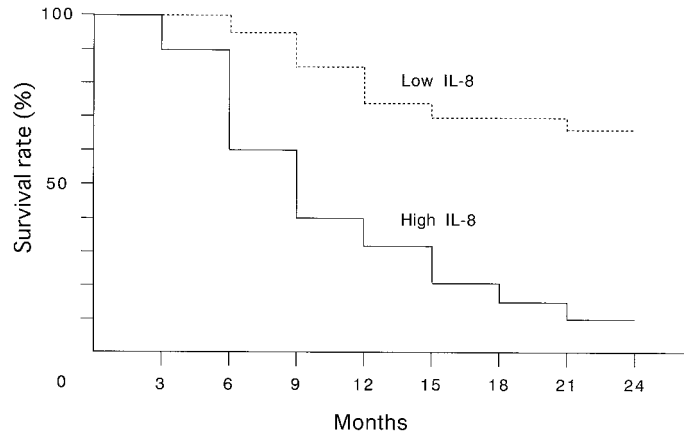


Fig. 6. Survival rate after curative resection for uterine cervical cancers. Patient prognosis was analyzed using a 24-month survival rate. High IL-8, >1000 pg/mg protein ($n = 20$); low IL-8, <1000 pg/mg protein ($n = 60$).

DISCUSSION

Infiltrated macrophages in tumors are activated, which leads to the induction of angiogenic potential; in fact, macrophage infiltration correlates with microvessel density in breast cancers (6). In the present study, there was a significant correlation between IMC and MVC ($P < 0.05$) in uterine cervical cancers (data not shown). Therefore, we studied which angiogenic factors derived from tumor-associated macrophages promote tumor angiogenesis in uterine cervical cancers. Generally, bFGF, VEGF, PD-ECGF, TNF- α , and IL-8 have been recognized as tumor-associated macrophage-derived angiogenic factors (7–11).

In the present study, the positive correlation between MVCs and IL-8, bFGF, VEGF, and PD-ECGF demonstrates that these factors work as angiogenic factors. In uterine cervical cancers, VEGF from cancer cells is related to patient prognosis, but only in early invasion (2, 17, 18). PD-ECGF from the interstitial cells correlates with patient prognosis, especially with lymph node metastasis (4, 5). bFGF from both the cancer and interstitial cells relates to clinical stage and advancement (3). Although PD-ECGF and bFGF were provided in part from tumor-associated macrophages, macrophage infiltration was positively correlated with only IL-8 among IL-1 α , IL-1 β , TNF- α , bFGF, VEGF, PD-ECGF, and IL-8, which demonstrates that IL-8 might be dominantly supplied from tumor-associated macrophages. Furthermore, localization of IL-8 in the tumors was similar to that of macrophage CD68. Although there is no distinct cytokine network among IL-1 α , IL-1 β , TNF- α , and IL-8 in tumor angiogenesis derived from infiltrated macrophages, it is strongly speculated that IL-8 works as an angiogenic factor in uterine cervical cancers. In other angiogenesis-dependent diseases, IL-8 contributes to growth related to angiogenesis in bronchogenic carcinoma (19), glioblastoma (20), melanoma (21), ovarian carcinoma (22, 23), and other cancers. Furthermore, IL-8 activates metastatic potential (21).

In the present study, IL-8 levels were significantly increased during the advancement from stage I to stages II, III, and IV. Therefore, IL-8 might be the angiogenic switch in advancement to later stages of uterine cervical cancers. Furthermore, IL-8, as an angiogenic factor supplied from infiltrated macrophages within and around the tumor, might be a prognostic indicator.

REFERENCES

1. Folkman, J. Tumor angiogenesis. *Adv. Cancer Res.*, 43: 175–203, 1985.
2. Fujimoto, J., Sakaguchi, H., Hirose, R., Ichigo, S., and Tamaya, T. Expression of vascular endothelial growth factor (VEGF) and its mRNA in uterine cervical cancers. *Br. J. Cancer*, 80: 827–833, 1999.

3. Fujimoto, J., Ichigo, S., Hori, M., Hirose, R., Sakaguchi, H., and Tamaya, T. Expression of basic fibroblast growth factor and its mRNA in advanced uterine cervical cancers. *Cancer Lett.*, *111*: 21–26, 1997.
4. Fujimoto, J., Ichigo, S., Sakaguchi, H., Hirose, R., and Tamaya, T. The expression of platelet-derived endothelial cell growth factor in uterine cervical cancers. *Br. J. Cancer*, *79*: 1249–1254, 1999.
5. Fujimoto, J., Sakaguchi, H., Hirose, R., Hongwu, W., and Tamaya, T. Clinical implication of expression of platelet-derived endothelial cell growth factor (PD-ECGF) in metastatic lesions of uterine cervical cancers. *Cancer Res.*, *59*: 3041–3044, 1999.
6. Leek, R. D., Lewis, C. E., Whitehouse, R., Greenall, M., Clarke, J., and Harris, A. L. Association of macrophage infiltration with angiogenesis and prognosis in invasive breast carcinoma. *Cancer Res.*, *56*: 4625–4629, 1996.
7. Barid, A., Mormede, P., and Bohlen, P. Immunoreactive fibroblast growth factor in cells of peritoneal exudate suggests its identity with macrophage-derived growth factor. *Biochem. Biophys. Res. Commun.*, *126*: 358–364, 1985.
8. Leek, R. D., Harris, A. L., and Lewis, C. E. Cytokine networks in solid human tumors: regulation of angiogenesis. *J. Leukocyte Biol.*, *56*: 423–435, 1994.
9. Pusztai, L., Clover, L. M., Cooper, K., Starkey, P. M., Lewis, C. E., and McGee, J. O. Expression of tumour necrosis factor α and its receptors in carcinoma of the breast. *Br. J. Cancer*, *70*: 289–292, 1994.
10. Yoshida, S., Ono, M., Shono, T., Izumi, H., Ishibashi, T., Suzuki, H., and Kuwano, M. Involvement of interleukin-8, vascular endothelial growth factor, and basic fibroblast growth factor in tumor necrosis factor α -dependent angiogenesis. *Mol. Cell. Biol.*, *17*: 4015–4023, 1997.
11. Koch, A. E., Polverini, P. J., Kunkel, S. L., Harlow, L. A., DiPietro, L. A., Elner, V. M., Elner, S. G., and Strieter, R. M. Interleukin-8 as a macrophage-derived mediator of angiogenesis. *Science (Washington DC)*, *258*: 1798–1801, 1992.
12. FIGO news. *Int. J. Gynecol. Obstet.*, *28*: 189–193, 1989.
13. Maeda, K., Chung, Y. S., Ogawa, Y., Takatsuka, S., Kang, S. M., Ogawa, M., Sawada, T., Onoda, N., Kato, Y., and Sowa, M. Thymidine phosphorylase/platelet-derived endothelial cell growth factor expression associated with hepatic metastasis in gastric carcinoma. *Br. J. Cancer*, *73*: 884–888, 1996.
14. Matsumura, M., Chiba, Y., Lu, C., Amaya, H., Shimomatsuya, T., Horiuchi, T., Muraoka, R., and Tanigawa, N. Platelet-derived endothelial cell growth factor/thymidine phosphorylase expression correlated with tumor angiogenesis and macrophage infiltration in colorectal cancer. *Cancer Lett.*, *128*: 55–63, 1988.
15. Bradford, M. A. Rapid and sensitive method for the quantification of microgram quantities of protein utilizing the principle of protein-dye binding. *Anal. Biochem.*, *72*: 315–323, 1976.
16. Nishida, M., Hino, A., Mori, K., Matsumoto, T., Yoshikubo, T., and Ishitsuka, H. Preparation of anti-human thymidine phosphorylase monoclonal antibodies useful for detecting the enzyme levels in tumor tissues. *Biol. Pharm. Bull.*, *19*: 1407–1411, 1996.
17. Guidi, A. J., Abu-Jawdeh, G., Berse, B., Jackman, R. W., Tognazzi, K., Dvorak, H. F., and Brown, L. F. Vascular permeability factor (vascular endothelial growth factor) expression and angiogenesis in cervical neoplasia. *J. Natl. Cancer Inst.*, *87*: 1237–1245, 1995.
18. Kodama, J., Seki, N., Tokumo, K., Hongo, A., Miyagi, Y., Yoshinouchi, M., Okuda, H., and Kudo, T. Vascular endothelial growth factor is implicated in early invasion in cervical cancer. *Eur. J. Cancer*, *35*: 485–489, 1999.
19. Smith, D. R., Polverini, P. J., Kunkel, S. L., Orringer, M. B., Whyte, R. I., Burdick, M. D., Wilke, C. A., and Strieter, R. M. Inhibition of interleukin-8 attenuates angiogenesis in bronchogenic carcinoma. *J. Exp. Med.*, *179*: 1409–1415, 1994.
20. Desbaillets, I., Diserens, A. C., Tribolet, N., Hamou, M. F., and Van Meir, E. G. Upregulation of interleukin 8 by oxygen-deprived cells in glioblastoma suggests a role in leukocyte activation, chemotaxis, and angiogenesis. *J. Exp. Med.*, *186*: 1201–1212, 1997.
21. Luca, M., Hung, S., Gershenwald, J. E., Singh, R. K., Reich, R., and Bar-Eli, M. Expression of interleukin-8 by human melanoma cells up-regulates MMP-2 activity and increases tumor growth and metastasis. *Am. J. Pathol.*, *151*: 1105–1113, 1997.
22. Yoneda, J., Kuniyasu, H., Crispens, M. A., Price, J. E., Bucana, C. D., and Fidler, I. J. Expression of angiogenesis-related genes and progression of human ovarian carcinomas in nude mice. *J. Natl. Cancer Inst.*, *90*: 447–454, 1998.
23. Xu, L., Xie, K., Mukaida, N., Matsushima, K., and Fidler, I. J. Hypoxia induced elevation in interleukin-8 expression by human ovarian carcinoma cells. *Cancer Res.*, *59*: 5822–5829, 1999.