

Correlating Genetic Aberrations with World Health Organization-defined Histology and Stage across the Spectrum of Thymomas¹

Masayoshi Inoue, Petr Starostik, Andreas Zettl, Philipp Ströbel, Stephan Schwarz, Francesco Scaravilli, Kristin Henry, Nick Willcox, Hans-Konrad Müller-Hermelink, and Alexander Marx²

Institute of Pathology, University of Würzburg, D-97080 Würzburg, Germany [M. I., P. Sta., A. Z., P. Str., S. S., H-K. M-H., A. M.]; Department of Neuropathology, Institute for Neurology, University College London, London WC1N 3BG, United Kingdom [F. S.]; Charing Cross Hospital, London W6 8RF, United Kingdom [K. H.]; and Neuroscience Group, Institute of Molecular Medicine, John Radcliffe Hospital, Oxford OX3 9DS, United Kingdom [N. W.]

ABSTRACT

Thymomas are thymic epithelial tumors. Because most of them are rich in nonneoplastic T-cells, recurrent genetic aberrations have been reported only in the rare, lymphocyte-poor WHO types A, B3, and C. We have now investigated virtually the whole spectrum of thymomas, including the commoner types AB and B2, microdissecting or culturing neoplastic cells from these lymphocyte-rich thymomas and applying 41 microsatellite markers covering 17 loci on 10 chromosomes. In 28 cases, comparative genomic hybridization data were available. Apart from type A, there was striking heterogeneity between thymomas. Allelic imbalances were seen in 87.3% of the 55 cases, and MSI in 9.9%. Losses of heterozygosity (LOHs) were much the commonest aberration. Overall, they were most prevalent at four regions on chromosome 6. Aberrations elsewhere, affecting mainly 8p11.21 and 7p15.3, suggested a cortical footprint because they recurred only in the thymopoietically active type AB and B thymomas. LOHs were also seen at the *adenomatous polyposis coli* (*APC*) locus (5q21-22) in subsets of these thymomas, whereas combined LOHs at the *APC*, *retinoblastoma* (13q14.3), and *p53* (17p13.1) loci were confined to a subset of B3 thymomas that had possibly evolved from *APC*-hemizygous B2 thymomas by tumor progression; indeed, thymomas combining B2 plus B3 features are common. Notably, some AB and B thymomas shared LOHs despite their nonoverlapping morphology and different clinical behavior. Finally, allelic imbalances at 8p11.21 and 16q22.1 (*CDH1*) were significantly more frequent in stage IV metastatic thymomas. We conclude that the WHO-defined histological thymoma types generally segregate with characteristic genetic features, type A thymomas being the most homogeneous. Many findings support the view that B2 and B3 thymomas form a continuum, with evidence of tumor progression. However, other findings imply that types A and AB are biologically distinct from the others, any potential invasiveness being severely restricted by a medullary commitment in the precursor cell undergoing neoplastic transformation.

INTRODUCTION

Thymomas are the commonest human mediastinal tumors and frequently associated with MG³ (1–3). According to the recently published WHO classification (4), they are divided into types A (also called medullary), AB (mixed), B, and C thymomas. Type B thymomas are additionally subdivided into type B1 (predominantly cortical), B2 (cortical), or B3 (well-differentiated thymic carcinoma; Refs.

3–6). Type C thymomas comprise a heterogeneous group of thymic carcinomas (4).

Although the immunological features of thymomas have been intensively studied (7–15), their genetic characterization has been hampered by the abundant nonneoplastic lymphocytes in ~70% of cases. Therefore, genetic characterization has concentrated on the rare WHO types A, B3, and C that harbor few lymphocytes (16, 17). For the majority of lymphocyte-rich type AB, B1, and B2 thymomas, there are only a few case reports of karyotypes revealed by classical cytogenetics (18–20). Using CGH and more sensitive/more finely localized microsatellite analyses, we previously defined some recurrent genetic abnormalities in WHO types A, B3, and C thymoma (16, 17). LOHs frequently occurred on chromosomes 3p, 6, 13q, and 16q (16), especially on the long arm of chromosome 6 (17). Other consistent LOHs were detected at 5q21-22, including the *APC* locus, and at 17p13.1, including the *p53* locus (17). Comparing the allelotypes of types A, B3, and C thymoma, we inferred two mutually exclusive pathogenetic pathways characterized by either the 6q23.3-25.3 or 5q21-22 LOHs.

However, we could not address certain controversial issues because of the exclusion of the common types AB and B2: (a) whether the new WHO-defined thymoma types are just convenient descriptive labels or reflect true biologically distinct entities with specific genetic alterations, clinical features, and prognoses, analogous to most WHO-defined lymphoma types (21); (b) whether the various histological thymoma types represent a continuum ranging from the usually benign type A to the frankly malignant types B3 and C (22) or whether types A and AB show qualitatively distinct differentiation pathways (3, 6, 23); and (c) the supposedly close relationships between type A and AB thymomas and between types B2 and B3 remain hypotheses (3, 6, 24) based on clinical or morphological observations and require substantiation by genetic data.

To address these questions, we have now extended allelotyping studies to all WHO-defined thymoma types, except for the very rare WHO type B1 thymoma, of which we have not received a single fresh sample during the last 2.5 years. By contrast, the lymphocyte-rich and clinically most relevant types AB and B2 were studied here for the first time with a broad panel of microsatellite markers using laser-assisted microdissection or short-term primary thymoma epithelial cell cultures to isolate tumor DNA. To detect allelic imbalance or MSI at putative tumor suppressor gene loci, we applied microsatellite markers that proved useful in the previous study (17). Although we recently found several LOH hot spots on chromosome 6 using microsatellite analysis (25), the other chromosomes have not been studied across the spectrum of thymomas. Moreover, we added additional markers for *CDH1* (at 16q22.1) because it contributes to invasion in gastric and breast cancers (26, 27), and also the *AIRE* (at 21q22.3) locus because of its role in tolerance induction in the thymus (28) and the frequent occurrence of autoimmunity in thymoma patients. The results suggest a spectrum of genetic alterations with diversity increasing from the relatively homogeneous type A through AB to B2 and possibly B2 to B3 progression.

Received 12/12/02; accepted 4/24/03.

The costs of publication of this article were defrayed in part by the payment of page charges. This article must therefore be hereby marked *advertisement* in accordance with 18 U.S.C. Section 1734 solely to indicate this fact.

¹ This work was supported by a Humboldt Research Fellowship from the Alexander von Humboldt Foundation (to M. I.), Deutsche Krebshilfe Grant 10-1740St (to P. Sta., H-K. M-H.), Deutsche Forschungsgemeinschaft Grant FOR303/2 and European Union Grant QRLT-2000-1918 (to P. Str. and A. M.).

² To whom requests for reprints should be addressed, at the Institute of Pathology, University of Würzburg, Luitpoldkrankenhaus, Josef-Schneider-Str. 2, D-97080 Würzburg, Germany. Phone: 49-931-201-47421; Fax: 49-931-201-47505; E-mail: alex.marx@mail.uni-wuerzburg.de.

³ The abbreviations used are: MG, myasthenia gravis; LOH, loss of heterozygosity; MSI, microsatellite instability; CGH, comparative genomic hybridization; FHIT, fragile histidine triad; APC, adenomatous polyposis coli; RB, retinoblastoma; CDH1, E-cadherin; DCC, deleted in colon cancer; AIRE, autoimmune regulator.

MATERIALS AND METHODS

Patients. Fifty-seven patients (ages 29–84 years; mean, 59 years; 29 females, 28 males) with thymoma were selected for this study from our files. Among these, 55 thymomas were evaluated using microsatellite analysis and 28 were analyzed by CGH. Thymomas were classified according to the WHO system (4): type A ($n = 11$); AB ($n = 18$); B2 ($n = 6$); B3 ($n = 18$); and C ($n = 4$). Our type C thymomas included only epidermoid thymic carcinomas. Tumor stage was defined according to Masaoka's staging system as modified by Shimosato and Mukai (2, 29): 12 cases were stage I; 25 cases were stage II (infiltration through the tumor capsule into the mediastinal fat); 11 cases were stage III; and 9 cases were stage IV. Among the 57 cases, type AB ($n = 18$) and B2 ($n = 6$) lymphocyte-rich thymomas were tested here for the first time with a broad panel of microsatellite markers. MG diagnosis was confirmed by detection of anti-AChR antibodies in 32 cases. Among these MG patients, two had been pretreated with corticosteroids (both type A tumors).

Microdissection. Frozen sections (7- μ m thick) were stained with anti-CD3 antibody (Immunotech, Marseille, France) using the Dako ChemMate DAB kit K5001 (Dako, Glostrup, Denmark), followed by hematoxylin. By laser-assisted microdissection, we collected cells from neoplastic epithelium-rich areas that were clearly separate from lymphocyte-rich areas in 15 type AB thymomas. Tumor cells were laser-microdissected on the IX 70 microscope (Olympus, Tokyo, Japan) using the Robot-MicroBeam program (Palm, Bernried, Germany) and then catapulted into the microcentrifuge caps coated with DNA digestion buffer. Manual microdissection under a microscope was performed on type B3 thymomas to harvest the most epithelium-rich areas. Twenty serial 10- μ m thick tissue sections were cut; the first and last were stained with H&E to assure high tumor content. Tumor-rich areas were scraped from fresh frozen tissue sections visualized under the microscope. Paraffin-embedded tissue sections were additionally stained by Nuclear-Fast Red to delineate tumor areas precisely.

Short-Term Primary Culture of Neoplastic Thymic Epithelial Cells. Epithelial cells from short-term primary cell cultures were used as a source of tumor DNA in six type B2 thymomas, which, by definition, contain abundant nonneoplastic lymphocytes throughout the tumor, as also in two of the 17 type AB thymomas. Fresh surgical specimens of thymoma were minced and cultured for 5 days in the presence of 1.35 mM 2-deoxyguanosine (Sigma, Steinheim, Germany) in MEM-D-Val (Life Technologies, Inc. Ltd., Paisley, United Kingdom) supplemented with 10% FCS. 2-Deoxyguanosine-treated tissue fragments were incubated in 0.25% trypsin-0.02% EDTA for 30 min at 37°C and vortexed vigorously. Dispersed cells were cultured for 2 days and only adherent tumor cells were then collected; their purity was >95% as confirmed by labeling with a mixture of anticytokeratin 8 and 18 antibodies (CAM 5.2; Becton-Dickinson, San Jose, CA). Only tumor cells harvested from the first passage of primary cultures within 1 week after surgical resection were used. These cultured cells were clearly an appropriate source of tumor DNA: (a) primary cultures from lymphocyte-poor type A ($n = 1$) and B3 ($n = 3$) thymomas showed genotypes identical to those of cells from the same patient's tumor block (data not shown); and (b) genotypes of thymic epithelial cells from a primary culture of a hyperplastic thymus showed no sign of *in vitro* acquisition of genetic aberrations (data not shown).

DNA Extraction and Microsatellite Analysis. DNA extraction was performed according to conventional protocols (30). Microdissected or whole tumor tissue (types A, AB, B3, and C thymomas) or pellets of cultured tumor cells (types AB and B2) were digested using proteinase K. DNA was extracted using phenol-chloroform, followed by ethanol precipitation. Control DNA was obtained from peripheral blood lymphocytes or adjacent remnant thymus tissue not involved by the tumor.

For microsatellite analyses, we used the 41 highly selected repeats that revealed frequent allelic imbalances in our previous study and in exactly the same way (17). D3S1293 and D3S1283 at 3p24, D3S4103 and D3S1300 at 3p14.2 (*FHIT*), D5S82 and D5S346 at 5q21-22 (*APC*), D6S105, D6S1666, and D6S1560 at 6p21.3 (*MHC*), D6S1596, D6S284, and D6S460 at 6q14-15, D6S1592 and D6S447 at 6q21, D6S441, D6S290, D6S473, D6S442, D6S1708, and D6S1612 at 6q25.2-25.3, D7S493 and D7S673 at 7p15.3, D8S1734 and D8S1820 at 8p21.2-21.1, D8S532 and D8S255 at 8p11.21, D13S153 and D13S319 at 13q14.3 (*RB*), D16S663 and D16S405 at 16p13, D16S3031 and D16S3095 at 16q22.1 (*CDHI*), D16S516 and D16S402 at 16q23-24, TP53CA and p53p at 17p13.1 (*P53*), D18S35, D18S1127, and

D18S1129 at 18q21 (*BCL-2* and *DCC*), and D21S49 and D21S171 at 21q22.3 (*AIRE*). The primer sequences for the amplification of microsatellite repeats were retrieved from the Genome Data Base.⁴ Chromosomal locations of markers were derived from the gene map on the National Center for Biotechnology Information web site and Ensembl Human Genome server.^{5,6} PCR primers were synthesized at MWG Biotech (Munich, Germany) or Applied Biosystems (Weiterstadt, Germany), and one oligonucleotide of each primer pair was labeled with fluorescent dye phosphoramidites FAM, HEX, NED, or with TAMRA. Paired normal and tumor DNA samples from each thymoma patient were amplified with the AmpliTaq Gold enzyme (Applied Biosystems, Foster City, CA) using 50 ng of genomic DNA as template under conditions specified by Genome Data Base. Thirty PCR cycles were carried out in an MWG Primus Gold thermal cycler (MWG Biotech) in a total volume of 20 μ l. The annealing temperatures ranged from 55°C to 61°C. Aliquots of the PCR products were mixed with Genescan 350-ROX (Applied Biosystems, Warrington, United Kingdom) as a size standard and formamide-denatured and electrophoresed on a 4.5% polyacrylamide gel using a 377 DNA Sequencer (Applied Biosystems). The automatically collected data were analyzed using Genescan and Genotyper software. Because homozygosity and MSI render any locus uninformative for allelic imbalances, we studied only heterozygous cases, determining ratios of the alleles in both the normal and the tumor samples. Any ratios differing by >20% were additionally evaluated for possible allelic imbalances. For determination of LOH or amplification in the cases without CGH data, the unchanged allele was first identified by comparison with other microsatellites showing no change in the same multiplex PCR and then the ratios between the alleles at each locus were calculated. An increase of at least 40% in the tumor:control ratio is designated amplification; a decrease by at least 40% is an LOH (25). MSI was detected as the appearance of new bands not seen in the genomic DNA (25). Any genetic aberrations were checked at least twice more.

CGH. When sufficient DNA was available, CGH analysis was performed as described previously (16). Briefly, tumor DNA was labeled with biotin-16-dUTP, whereas normal DNA extracted from placenta was labeled with digoxigenin-11-dUTP by nick translation (Roche Diagnostics, Mannheim, Germany). Equal amounts of test and reference DNA (1 μ g each) were cohybridized on commercially available metaphase slides (Vysis, Downers Grove, IL). Detection of biotin- and digoxigenin-labeled probes was accomplished with FITC avidin (Vector Laboratories, Burlingame, CA) or Cy3-conjugated antidigoxigenin (Dianova, Hamburg, Germany), respectively. 4,6-Diamidino-2-phenylindole counterstain was used for chromosome identification after antibody detection. Signals were visualized under a Zeiss Axiophot fluorescence microscope and analyzed with the ISIS digital image analysis system (MetaSystems, Altlußheim, Germany). At least 15 metaphases/case were analyzed. For identification of chromosomal imbalances, ratios of 1.25 and 0.8 were used as upper and lower thresholds, respectively.

Immunohistochemistry for hMLH1 and hMSH2. In cases showing increased levels of MSI, we performed immunohistochemical staining for the mismatch repair gene products hMLH1 and hMSH2 (anti-hMLH1 antibody was from hybridoma clone G168-15 from PharMingen, San Diego, CA; anti-hMSH2 antibody was from hybridoma clone FE11 from Calbiochem, San Diego, CA) on formalin-fixed, paraffin-embedded tissue sections using standard immunoperoxidase techniques. Normal lymphoid cells on the same slide served as a control.

Statistical Analysis. Statistical differences were analyzed by χ^2 test or Fisher's exact test using the commercially available Stat View statistical program (Abacus Concepts, Inc., Berkeley, CA).

RESULTS

Overall Frequencies of Genetic Aberrations in Thymoma. We found genetic aberrations at one or more of the 17 chromosomal regions studied in 87.3% of cases. There were allelic imbalances in 48 of 55 cases (87.3%). Most of these were LOHs, whereas only 7 cases (12.7%) showed amplifications at certain loci (Fig. 1). MSIs were found in 5 of 55 cases (9.9%; Figs. 2 and 3).

⁴ Internet address: <http://gdbwww.gdb.org/>.

⁵ Internet address: <http://www.ncbi.nlm.nih.gov>.

⁶ Internet address: <http://www.ensembl.org/>.

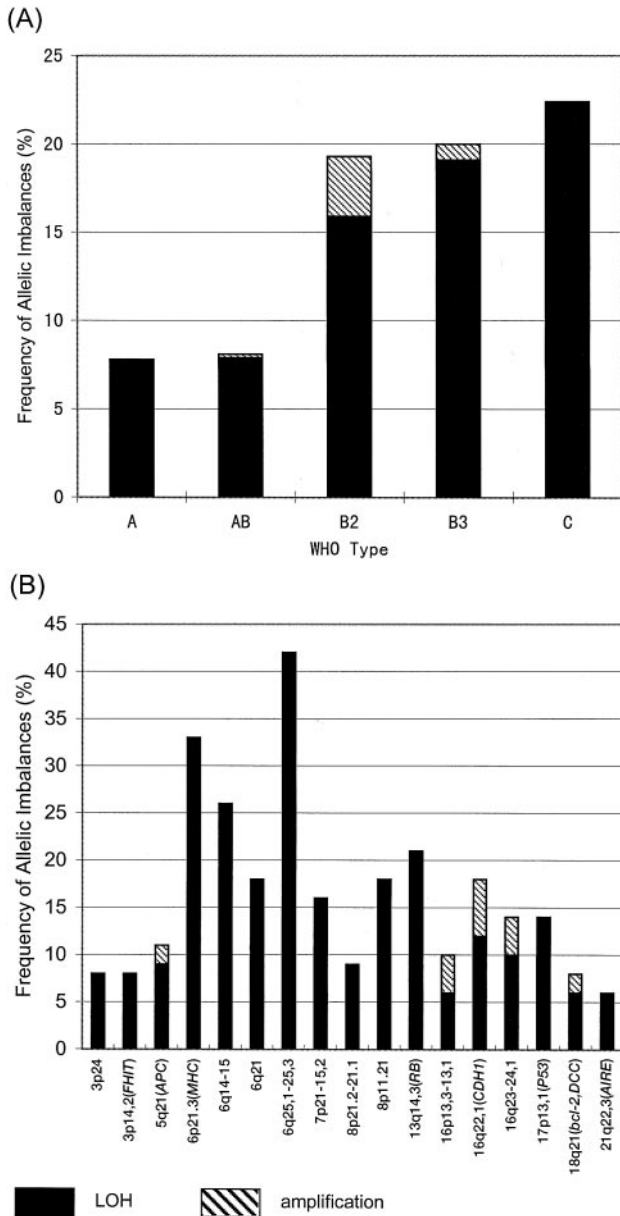


Fig. 1. Overall frequencies of allelic imbalances for each thymoma type (A) and microsatellite region (B). ■ indicates LOHs and descending stripes amplifications. A, significant differences by χ^2 test were found in type A versus B2 ($P < 0.0001$), A versus B3 ($P < 0.0001$), A versus C ($P < 0.0001$), AB versus B2 ($P < 0.0001$), AB versus B3 ($P < 0.0001$), and AB versus C ($P < 0.0001$). B, the most frequent LOHs occurred at 6q25.2-25.3 and 6p21.3 (MHC).

Overall, the aberrations at four regions on chromosome 6 and 13 regions on nine other chromosomes give a strong impression of heterogeneity. Types B2, B3, and C thymomas usually showed genetic aberrations on multiple chromosomes, although such multiple aberrations were rare in type A and intermediate in type AB thymoma (Fig. 4). Types B and C showed more allelic imbalances than types A or AB (Fig. 1A). In all types, they were most frequent on chromosome 6, especially at 6q25.2-25.3 and 6p21.3, as shown in Fig. 1B. In addition, we saw amplifications at three regions on chromosome 16 (including *CDH1*), one region on chromosome 5 (including *APC*), and one region on chromosome 18 (including *BCL-2* and *DCC*) in a total of seven thymomas (Fig. 1B).

Although we found MSIs in only five thymomas (1 AB, 1 B2, and 3 B3), they frequently involved multiple sites; in case no. 36, they occurred at 44% of informative loci (MSI-high) and at 10 and 20%

(MSI-low) in case nos. 39 and 40 (all type B3). Nevertheless, we found no sign of defective expression of the mismatch repair proteins hMLH1 and hMSH2; nuclear staining was strongly positive in these thymomas (data not shown).

Frequent and Multiple LOHs on Chromosome 6 in all Thymoma Types. The two regions most frequently affected were on chromosome 6-6p21.3 (*MHC*) and 6q25.2-25.3 (Fig. 2); interestingly, these showed LOHs in all thymoma types, whereas those at 6q14-15 and 6q21 were less common in types A and AB (Fig. 2) such as those at the other chromosomal regions (Fig. 3). We found deletions of one entire chromosome 6 (monosomy 6) in one type B2, three B3, and one C thymomas using both microsatellite analysis and CGH. One type B3 (case no. 36) with numerous MSIs and one type C (case no. 53), exhibited an apparently complete loss of chromosome 6 by CGH, whereas microsatellite analysis detected small regions of chromosome 6 with retention of heterozygosity in both samples. Monosomy 6 detected by CGH occurred significantly more frequently in types B-C than types A-AB ($P = 0.0045$). No amplifications were seen at any of the four regions on chromosome 6.




Fig. 2. Genetic aberrations on chromosome 6 in thymoma. Status of each locus is indicated: (■), LOH; (▨), MSI; (▩), retention of heterozygosity; and (□), homozygosity. In CGH data: (-), no gain or loss; NA, not available for CGH.




Fig. 3. Genetic aberrations on other chromosomes than 6 in thymoma. Status of each locus is indicated: (■), LOH; (▨), amplification; (▧), MSI; (▩), retention of heterozygosity; and (□), homozygosity. In the CGH column: (-), no gain or loss; NA, not analyzed by CGH.

Frequent Allelic Imbalances at 13q14.3 (*RB*), 16q22.1 (*CDH1*), 8p11.21, and 7p15.3 in Non-A Type Thymomas. Results for chromosomes other than 6 are shown in Fig. 3; recurring aberrations are summarized in Table 1. Only 3 of 11 type A thymomas showed LOHs there, affecting multiple loci only in one (case no. 11). By contrast, genetic aberrations were more frequent in some AB thymomas, especially at 13q14.3 (*RB*) and 7p15.3, strikingly, also in 22 of 28 with types B2, B3, or C and involving 8p11.21, 16q22.1 (*CDH1*), and 17p13.1 (*p53*) in addition. Thus, in these cases, LOHs at multiple regions were also commoner (Fig. 4). We noted amplifications (▨) more often on chromosome 16 in the B2 and B3 samples and MSIs (▧) at multiple sites in the B3s especially (Fig. 3).

Whereas type A thymomas showed recurrent alterations only on chromosome 6, the aberrations at other loci become increasingly diverse as one scans from types AB through B2 to B3 in Table 1 and Fig. 3. Their prevalence approached 100% only in type C, where we

also saw unusual LOHs at 16q23-24.1. Interestingly, in two type B2 thymomas, there were amplifications at 16q22.1 (*CDH1*; Fig. 3), whereas recurrent LOHs in the B2s were seen at 5q21-22, 7p15.3, and 8p11.21 (Fig. 3); in addition, three advanced stage III or IV type B3s shared a unique combination of LOHs at 5q21-22 (*APC*), 13q14.3 (*RB*), and 17p13.1 (*p53*; case nos. 44, 45, and 46 marked * in Table 1 and Fig. 3). Surprisingly, this co-occurred with LOH at 6q25.2-25.3 in one B3 (case no. 46), although we had previously concluded that these were mutually exclusive (16, 17). Finally, recurring LOHs at 5q21-22, 7p15, and 8p11 in both type B2 and B3 thymomas, plus the generally higher frequencies of genetic aberrations in the B3s (including shared MSIs at 7p15.3), are consistent with B2 to B3 progression in some cases.

Gross Genetic Aberrations Detected by CGH Analysis. CGH was performed in the 28 cases in which sufficient DNA was available. The results of 18 cases are already published (16); we now add one

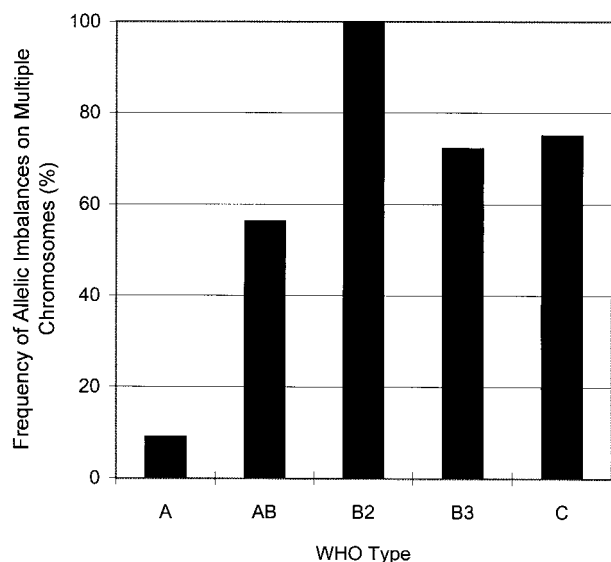


Fig. 4. Frequency of cases showing genetic aberrations on multiple chromosomes for each thymoma type: A ($n = 11$); AB ($n = 18$); B2 ($n = 6$); B3 ($n = 18$); and C ($n = 4$). This frequency was significantly lower in type A than in the other thymoma types ($P = 0.0003$).

type A, four conventional AB (including case no. 56), one AB with unusual histological heterogeneity (case no. 57; Fig. 5), and four B2 thymomas. Monosomy 6 was detected in one B2, four B3, and two C thymomas (Fig. 2). Seven cases showed losses at 13q (including the *RB* locus): one AB; five B3; and one C. Thus, when both types of analysis were performed in a given case, the CGH findings confirmed the results of the microsatellite analysis (Figs. 2 and 3).

In two cases (nos. 56 and 57), only CGH was performed because nonneoplastic tissue was not available. Loss at 5q21-q31 (including the *APC* locus) was the only aberration detected in case no. 56 (conventional type AB by morphology). By contrast, the carcinoma-like area in an unusual AB thymoma with heterogeneous histology showed a complex pattern of genetic imbalances (case no. 57 Fig. 5, *a-c*). Chromosomal gains were found at 1q, 5q15-qter, 17q, and Xq22-qter. Chromosomal losses occurred at 3p14-pter, 10p, 11q21-q23, 13q, 16q, 17p13-pter, and Xp14-pter (Fig. 5, *d* and *e*).

Correlation with Tumor Stage. We found an association between tumor progression and genetic characteristics (Table 2). Allelic imbalances at 8p11.21 (all LOHs) and 16q22.1 (*CDHI*, including two amplifications) were significantly more frequent in stage IV metastatic cases than in stages I–III (Table 2).

Some Thymomas Share Identical Allelic Imbalances despite very Different Clinicopathological Features. We looked for simple correlations between genetic and clinicopathological findings but found several intriguingly discordant pairs of thymomas that differed strikingly in invasiveness despite very similar LOHs (Table 3). For example, although one type of AB thymoma (case no. 19) had three LOHs, it was fully encapsulated (stage I), whereas one B3 (case no. 48) that shared two of them (at 7p15.3 and 8p11.21) exhibited pleural dissemination (stage IVA). Other similar, if less extreme, contrasts are highlighted in Table 3. Taken together, these pairs suggest that the correlation between genetic and clinicopathological thymoma features is not simple. That is supported by the apparent intratumorous progression revealed by CGH in case no. 57. The focal high-grade change in this otherwise conventional AB thymoma was accompanied by complex aberrations, including gains at 1q and LOHs at 16q and 17p. Although these changes are characteristic of advanced stage B3 thymomas and thymic epidermoid carcinomas (Table 2; Refs. 16, 17), no such morphological patterns were seen in the high-grade focus of this

Masaoka stage II thymoma (Fig. 5*a*). This suggests that the biology of the (medullary/spindle) tumor cell acquiring the stereotypic high-grade genetic imbalances at 1q, 16q, and 17p could restrict the subsequent phenotypic potential.

DISCUSSION

This study reports five major new findings about the genetics of thymomas in addition to their obvious heterogeneity: (*a*) the various WHO-defined histological thymoma types, including the lymphocyte-rich AB and B2 systematically studied here for the first time, exhibit different profiles of genetic aberrations; (*b*) some of the lymphocyte-poor type B3 thymomas are genetically closely related to the lymphocyte-rich B2 thymomas and may arise from them by gain of genetic aberrations; (*c*) only WHO type A thymomas exhibit a generally homogeneous profile of genetic abnormalities mainly involving chromosome 6, in contrast with the heterogeneity in the other thymoma types; (*d*) metastatic behavior shows a significant correlation with allelic imbalances at 8p11.21 and 16q22.1; and (*e*) some type A and AB thymomas share apparently similar profiles of genetic aberrations with type B or C thymomas but maintain their distinctive morphology and benign clinical behavior.

Frequent LOHs on Chromosome 6. The frequent LOHs on chromosome 6 might play several important roles in thymoma evolution. Interestingly, the hitherto elusive lymphocyte-rich AB and B2 types closely resembled the previously studied lymphocyte-poor types A, B3, and C thymomas in their frequent LOHs at 6q25 (Figs. 1*B* and 2; Refs. 16, 17). This suggests nearby tumor suppressor genes in this region that is lost early in thymomagenesis. Its rarity in other epithelial neoplasms (31, 32) and non-Hodgkin's lymphoma (33) implies a specific role in normal thymic epithelial homeostasis. In addition, because localized chromosome 6 LOHs were common in all thymoma subtypes, whereas complete deletions (*i.e.*, monosomy 6) were found only in clinically malignant types B2, B3, and C of at least stage III (Fig. 2), loci elsewhere on this chromosome may influence histological phenotype and prognosis.

The 6p21.3 LOH, spanning the *MHC* locus, was common in types A, AB, B3, and C but was seen in only one of six B2 thymomas, a possible difference that requires confirmation. In theory, loss of a *MHC* haplotype might affect intratumorous T-cell selection (7); however, the LOH at 6p21.3 did not associate significantly with MG in this study ($P > 0.05$) and nor did the LOH of the putative autoimmunity-related *AIRE* locus on chromosome 21 (28). Alternatively,

Table 1 Loci showing recurrent allelic imbalances according to WHO classification of thymic tumors

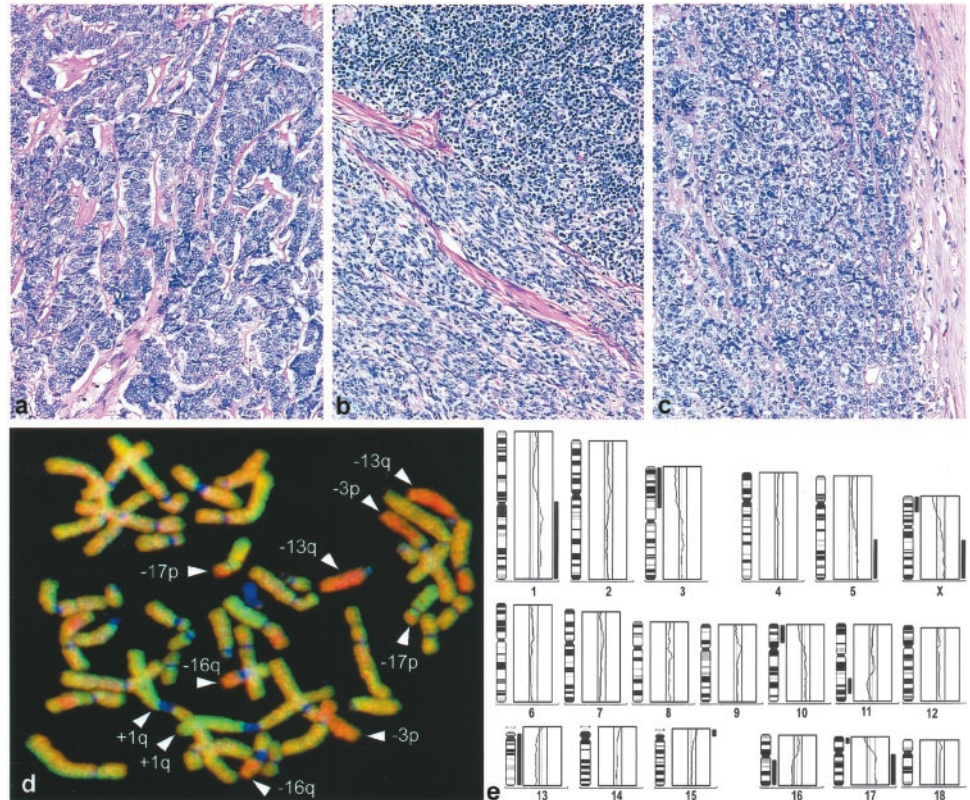
Locus	Gene	WHO thymoma type ^a				
		A	AB	B2	B3	C
3p14.2	<i>FHIT</i>				(16%)	
5q21-22	<i>APC</i>			33% ^b	(16%)*	
6p21.3	<i>MHC</i>	27%	25%		41%	75%
6q14-15		27%			37%	75%
6q21					33%	
6q25.2-25.3		36%	37%	33%	39%	100%
7p15.3				50%		
8p11.21				33%	30%	
13q14.3	<i>RB</i>		27%		28%*	
16q22.1	<i>CDHI</i>			50%		50%
16q23-24.1						50%
17p13.1	<i>p53</i>				(16%)*	

^a Type: histological type according to the WHO classification of thymic tumors (4).

^b Percentage (%): loci showing recurrent LOHs or amplification in at least 25% of informative cases in each thymoma type.

* Combined LOHs in three advanced B3 thymomas (stage III-IVA): case nos. 44, 45, 46. In addition, case nos. 44 and 46 shared the LOH at 3p14.2 (*FHIT*; Fig. 3). Percentages of LOHs in this subset of B3 thymomas are given in brackets when <25%.

Fig. 5. High-grade progression within a type AB thymoma (case no. 57) as revealed by morphology and CGH. *a*, high-grade tumor region composed of elongated tumor cells in a trabecular arrangement and hyalinized stroma. *b*, region inside the same tumor composed of spindle cells arranged in the conventional composite AB pattern with sharply delineated lymphocyte-rich (*top right*) and lymphocyte-poor (*bottom left*) areas. *c*, a lymphocyte-poor region in the same tumor made up of benign looking polygonal cells. This is a well known but less frequent feature of AB thymomas. *d*, representative metaphase of CGH with DNA from the microdissected high-grade region shown in *a*, showing gains on chromosomes 1q, 5q, 17q, and Xq and losses on 3p, 10p, 11q, 13q, 16q, 17p, and Xp (*e*). By contrast, CGH of microdissected lymphocyte-poor regions as shown in *b* or *c* revealed no allelic imbalances (data not shown).



MHC loss might reflect escape from immune surveillance, as with other tumors: colorectal, head and neck, and cervical carcinomas; chronic lymphocytic leukemia; and astrocytoma (34).

Signs of Tumor Progression. Whereas type A thymomas were the most homogeneous, with recurrent LOHs restricted to chromosome 6, the other types typically showed multiple recurrent allelic imbalances at other chromosomal loci, sometimes without aberrations on chromosome 6 (Figs. 2 and 3). Surprisingly, AB thymoma was more akin to type B in this respect, despite sharing a singularly benign clinical behavior with type A. Some type B2 and B3 thymomas shared recurrent genetic features as well, notably LOHs at 5q21-22 (*APC*), 7p15, and 8q11, suggesting B2 to B3 progression. However, the combined loss of regions 5q21-22 (*APC*), 13q14.3 (*RB*), and 17p13.1 (*p53*) was unique to a subset of more invasive type B3 thymomas (* in Table 1). The *APC* gene is involved both in intercellular adhesion through β -catenin and E-cadherin and in the control of proliferation via the *WNT* pathway (35, 36). Inherited or acquired *APC* mutations initiate a variety of tumors (35–40) indicating the *APC*-dependent adenoma-colon carcinoma sequence (also involving the *APC*, *RB*, and *p53* loci) that predisposes to both sporadic and familial colorectal cancer (37, 38), a sequence strikingly echoed by the combined LOHs in this subset of B3 thymomas (* in Table 1).

The shared aberrations at 5q21-22, 7p15 and 8p11 and the com-

bined LOHs at 3p14.2, 5q21-22, 13q14.3, and 17p13.1 only in some type B3 thymomas suggests that a subset of B3s may arise from B2s; that is also supported by the frequent occurrence of both B2- and B3-like areas in combined thymomas (3, 4, 6, 24). In line with this progression, B2 and especially B3 thymomas have proved aggressive in most clinicopathological studies (6, 41, 42). On the other hand, we saw LOHs at 5q21-22 (*APC*) not only in type B but also (by CGH) in one AB thymoma (case no. 56), which therefore seems closer to type B than to A. Furthermore, these recurrent LOHs in type AB, B2, and B3, but not A, thymomas correlate with the generation of abundant thymocytes, as in normal thymic cortex, and may imply a cortical footprint.

Correlates of Invasiveness/Metastasis. The LOH at 8p11.21 was seen in approximately one-third of both type B2 and B3 thymomas and appears to be independent of the LOHs at 5q21-22 or 6p25.2-25.3. LOHs at 8p have been observed in many cancers, including gastrointestinal (43, 44), hepatic (45), oral and laryngeal (46), pulmonary (47), prostate (48), breast (49), and ovarian carcinomas (50). Although there is a candidate *LZTSL1* tumor suppressor near 8p22 (51), imbalances at 8p21.2-21.1 proved to be ~2-fold less frequent than at 8p11.21, perhaps implying additional more centromeric candidates.

A third recurrent feature in occasional type B thymomas (16.7%) was the MSI that affected multiple loci both on chromosome 6 and elsewhere. The isolated MSIs at 7p15.3 in one of six B2 samples (case no. 31) and at 16q23-24.1 in 1 of 17 ABs (case no. 22) may be unusual events, for example, in this rare monophasic variant of the AB type that is lymphocyte-rich throughout the tumor (case no. 22). It would be interesting to compare the genetic profiles of thymoma epithelial cells cultured from such cortex-like areas and lymphocyte-poor (medulla-like) areas that occur side-by-side in the commoner composite variant of AB thymomas. In any event, the findings suggest that, in some cases, MSI may represent a third route to thymoma

Table 2. Loci showing frequent allelic imbalances in advanced thymoma

Locus	Gene	Stage ^a				<i>p</i> ^b
		I	II	III	IV	
8p11.21	(Unknown)	1/10	2/21	2/10	4/8	0.0284
16q22.1	<i>CDH1</i>	0/11	3/20	2/11	4/9	0.0402

^a Stage: Masaoka's staging system (29) as modified by Shimosato and Mukai (2).

^b *P*: stage I–III versus IV, calculated using Fisher's exact test. Allelic imbalances at 8p11.21, and 16q22.1 were significantly more frequent in stage IV metastatic cases than those in stage I–III thymomas.

Table 3 *Thymoma cases with shared genetic imbalances at few loci despite divergent morphology*

Shared LOHs ^a	Different WHO types, modified Masaoka's stage (no. case numbers)
5q15-31 (<i>APC</i>)	AB stage II (no. 56*) ^{b,c} ; B2 stage II (no. 30), IVB (no. 32), B3 stage III (no. 44), IVA (no. 45), III (no. 46)
6p21.3 (<i>MHC</i>)	A stage II (no. 1); B3 stage II (no. 42)
6p21.3 and 6q25.2-25.3	AB stage II (no. 16), I (no. 26); C stage IVB (no. 55)
6p21.3, 6q14-15 and 6q25.2-25.3	A stage I (no. 5); B3 stage II (no. 37)
6q21	A stage I^d (no. 3), AB stage I (no. 13); B3 stage II (no. 43), IVB (no. 50)
7p15.3 and 8p11.21	AB stage I (no. 19); B3 stage III (no. 41), B3 stage IVA (no. 48)
16q22.1 (<i>CDH1</i>)	A stage I (no. 11); B3 stage IVA (no. 51), C stage IVB (no. 54)
17p13.1 (<i>p53</i>)	A stage I (no. 11); B2 stage IVA (no. 29)

^a LOHs were detected by microsatellite analysis.

^b Capital letters A, AB, B2, B3, C represent WHO thymoma types.

^c In AB case no. 56*, only CGH was applied, because only tumor material but no nonneoplastic tissue was available. Numbers in parenthesis represent the individual case numbers as applied in Figs. 2 and 3.

^d The pairs with the most discrepant clinicopathological features are highlighted by bold letters.

development in addition to the previously suggested pathways via 6q25.2-25.3 or 5q21-22.

Advanced tumor spread (stage IV) correlated primarily with allelic imbalances, particularly LOHs at 8p11.21 and 16q22.1 (*CDH1*), but not with any others (Table 2). That echoes findings in other malignancies, including LOHs at 8p in advanced colorectal and breast cancers (44, 49), that seem not to involve *LZTS1* at 8p22. In addition, reduced expression of E-cadherin, encoded by the *CDH1* gene at 16q22.1, may impair adhesion among tumor cells, therefore, favoring invasion or metastasis; *CDH1* deletions or mutations have been observed in invasive gastric (26), breast (27), and prostate carcinomas (52). Taken together, our results implicate a variety of pathways in metastatic thymomas. However, tumor stage is subject to other influences such as early discovery by chance on routine screening. More systematically, associated autoimmune disorders (especially MG) may lead to earlier diagnosis of thymomas; because MG is most common in type B2 (2–6, 53), advanced stages may be underrepresented in this type.

Notably, several pairs of A/B, A/C, AB/B, or AB/C thymomas with very similar LOHs differed strikingly in their invasiveness (Table 3). Therefore, we suspect that additional loci must also be involved, although we have screened most of the candidates best known to confer aggressiveness to a wide histogenetic spectrum of other tumors (26, 27, 43, 52), particularly the LOHs at 7p, 8p11, 16q22.1 (*CDH1*), and 17p13.1 (*p53*). The apparent resistance of some type A and AB thymomas to tumor progression despite their numerous aggression-prone allelic imbalances (Table 3) is very striking (see below).

Does Epithelial Progenitor Commitment Restrict the Malignant Potential of Thymomas. Although the view that thymomas form a biological continuum (7, 22) or represent distinct biological entities (3, 23) may appear conflicting, our present findings suggest that there is truth in both hypotheses. Already favoring the latter are the rarity of tumor-related deaths in types A and AB but not other types (2, 41, 42), and the virtual absence of thymomas combining histological features of types A or AB with those of type B3 (3, 6, 23). We can now add that, genetically, type A thymomas clearly form a distinct, relatively homogeneous group, with abnormalities apparently restricted to chromosome 6 (Table 3). However, with other types, many other findings support the continuum hypothesis (22): rare thymomas combine morphological features of types A or AB with type C (54); malignancy varies considerably within each of the B1–3 types, tumor stage being a better prognosticator for survival (24, 41, 42, 53); and some thymomas combine morphological features of B1, B2, B3, and C thymomas (3). To these arguments, we can now add: the frequent recurrence of LOHs on chromosome 6 regardless of thymoma type; the overlapping LOH at 5q (*APC*) and/or 16q between rare AB thymomas (case nos. 56 and 57) and a subgroup of B and C thymomas (Table 3, Fig. 5); the evidence of tumor progression discussed above; and the co-occurrence in case no. 46 (type B3, stage III) of LOHs at

both 5q21-22 and 6q25.2-25.3, arguing that these pathways are not mutually exclusive as previously inferred (17).

In conclusion, type A thymomas appear distinct and relatively homogeneous, with genetic aberrations mainly on chromosome 6. By contrast, the diverse changes in other subtypes suggest that, genetically, type AB thymomas are true intermediates between type A and B thymomas and that some B3 thymomas may arise from B2s by tumor progression. However, the distinctively benign behavior of types A and AB strongly suggests some additional genetic silencer(s); these could explain the imperfect correlation between genotype and phenotype in Table 3. Considering also the accumulating evidence that the diverse cortical and medullary epithelial subtypes (55, 56) derive from a common precursor (56, 57), we therefore propose that the stage at which neoplastic transformation occurs (*e.g.*, in an uncommitted precursor or one with a medullary or cortical commitment) influences the biology and phenotype of the resulting thymoma.

ACKNOWLEDGMENTS

We thank Evi Werder and Christl Kohaut for expert technical assistance and Elke Oswald for advice on cell culture methods.

REFERENCES

- Willcox, N. Myasthenia gravis. *Curr. Opin. Immunol.*, 5: 910–917, 1993.
- Shimosato, Y., and Mukai, K. Tumors of the mediastinum. In: Rosai, J. and Sobin, L. H. (eds.), *Atlas of Tumor Pathology*, Ed. 3, pp. 93–115. Washington, DC: Armed Forces Institute of Pathology, 1997.
- Müller-Hermelink, H. K., and Marx, A. Thymoma. *Curr. Opin. Oncol.*, 12: 426–433, 2000.
- Rosai, J. Histological typing of tumours of the thymus. Ed. 2, p. 65. Berlin and Heidelberg: Springer-Verlag, 1999.
- Marino, M., and Müller-Hermelink, H. K. Thymoma and thymic carcinoma. Relation of thymoma epithelial cells to the cortical and medullary differentiation of thymus. *Virchows Arch. A Pathol. Anat. Histopathol.*, 407: 119–149, 1985.
- Kirchner, T., Schälke, B., Buchwald, J., Ritter, M., Marx, A., and Müller-Hermelink, H. K. Well-differentiated thymic carcinoma. An organotypical low-grade carcinoma with relationship to cortical thymoma. *Am. J. Surg. Pathol.*, 16: 1153–1169, 1992.
- Willcox, N., Schlup, M., Ritter, M. A., Schuurman, H. J., Newsom-Davis, J., and Christensson, B. Myasthenic and nonmyasthenic thymoma. An expansion of a minor cortical epithelial cell subset? *Am. J. Pathol.*, 127: 447–460, 1987.
- Takeuchi, Y., Fujii, Y., Okumura, M., Inada, K., Nakahara, K., and Matsuda, H. Accumulation of immature CD3-CD4+CD8- single-positive cells that lack CD69 in epithelial cell tumors of the human thymus. *Cell. Immunol.*, 161: 181–187, 1995.
- Nagvekar, N., Moody, A. M., Moss, P., Roxanis, I., Curnow, J., Beeson, D., Pantic, N., Newsom-Davis, J., Vincent, A., and Willcox, N. A pathogenetic role for the thymoma in myasthenia gravis. Autosensitization of IL-4-producing T cell clones recognizing extracellular acetylcholine receptor epitopes presented by minority class II isotypes. *J. Clin. Invest.*, 101: 2268–2277, 1998.
- Inoue, M., Fujii, Y., Okumura, M., Takeuchi, Y., Shiono, H., Miyoshi, S., and Matsuda, H. Neoplastic thymic epithelial cells of human thymoma support T cell development from CD4-CD8- cells to CD4+CD8+ cells *in vitro*. *Clin. Exp. Immunol.*, 112: 419–426, 1998.
- Inoue, M., Okumura, M., Miyoshi, S., Shiono, H., Fukuhara, K., Kadota, Y., Shirakura, R., and Matsuda, H. Impaired expression of MHC class II molecules in response to interferon- γ (IFN- γ) on human thymoma neoplastic epithelial cells. *Clin. Exp. Immunol.*, 117: 1–7, 1999.
- Kadota, Y., Okumura, M., Miyoshi, S., Kitagawa-Sakakida, S., Inoue, M., Shiono, H., Maeda, Y., Kinoshita, T., Shirakura, R., and Matsuda, H. Altered T cell development

- in human thymoma is related to impairment of MHC class II transactivator expression induced by interferon- γ (IFN- γ). *Clin. Exp. Immunol.*, 121: 59–68, 2000.
13. Hoffacker, V., Schultz, A., Tiesinga, J. J., Gold, R., Schalke, B., Nix, W., Kiefer, R., Müller-Hermelink, H. K., and Marx, A. Thymomas alter the T-cell subset composition in the blood: a potential mechanism for thymoma-associated autoimmune disease. *Blood*, 96: 3872–3879, 2000.
 14. Buckley, C., Douek, D., Newsom-Davis, J., Vincent, A., and Willcox, N. Mature, long-lived CD4+ and CD8+ T cells are generated by the thymoma in myasthenia gravis. *Ann. Neurol.*, 50: 64–72, 2001.
 15. Ströbel, P., Helmreich, M., Menioudakis, G., Lewin, S. R., Rüdiger, T., Bauer, A., Hoffacker, V., Gold, R., Schalke, B., Elert, O., Semik, M., Müller-Hermelink, H. K., and Marx, A. Paraneoplastic myasthenia gravis correlates with generation of mature naive T cells in thymomas. *Blood*, 100: 159–166, 2002.
 16. Zettl, A., Ströbel, P., Wagner, K., Katzenberger, T., Ott, G., Rosenwald, A., Peters, K., Krein, A., Semik, M., Müller-Hermelink, H. K., and Marx, A. Recurrent genetic aberrations in thymoma and thymic carcinoma. *Am. J. Pathol.*, 157: 257–266, 2000.
 17. Zhou, R., Zettl, A., Ströbel, P., Wagner, K., Müller-Hermelink, H. K., Zhang Sj, S. J., Marx, A., and Starostik, P. Thymic epithelial tumors can develop along two different pathogenetic pathways. *Am. J. Pathol.*, 159: 1853–1860, 2001.
 18. Kristofferson, U., Heim, S., Mandahl, N., Akerman, M., and Mitelman, F. Multiple clonal chromosome aberrations in two thymomas. *Cancer Genet. Cytogenet.*, 41: 93–98, 1989.
 19. Sonobe, H., Takeuchi, T., Ohtsuki, Y., Taguchi, T., and Shimizu, K. A thymoma with clonal complex chromosome abnormalities. *Cancer Genet. Cytogenet.*, 110: 72–74, 1999.
 20. Mirza, I., Kazimi, S. N., Ligi, R., Burns, J., and Braza, F. Cytogenetic profile of a thymoma. A case report and review of the literature. *Arch. Pathol. Lab. Med.*, 124: 1714–1716, 2000.
 21. Jaffe, E. S., Harris, N. L., Stein, H., and Vardiman, J. W. Tumours of haematopoietic and lymphoid tissues. In: *World Health Organization Classification of Tumours. Pathology and Genetics*. 1–351 Lyon, France: IARC Press, 2002.
 22. Suster, S., and Moran, C. A. Thymoma, atypical thymoma, and thymic carcinoma. A novel conceptual approach to the classification of thymic epithelial neoplasms. *Am. J. Clin. Pathol.*, 111: 826–833, 1999.
 23. Müller-Hermelink, H. K., and Marx, A. Towards a histogenetic classification of thymic epithelial tumours? *Histopathology*, 36: 466–469, 2000.
 24. Quintanilla-Martinez, L., Wilkins, E. W., Jr., Ferry, J. A., and Harris, N. L. Thymoma-morphologic subclassification correlates with invasiveness and immunohistologic features: a study of 122 cases. *Hum. Pathol.*, 24: 958–969, 1993.
 25. Inoue, M., Marx, A., Zettl, A., Ströbel, P., Müller-Hermelink, H. K., and Starostik, P. Chromosome 6 suffers frequent and multiple aberrations in thymoma. *Am. J. Pathol.*, 161: 1507–1513, 2002.
 26. Becker, K. F., Atkinson, M. J., Reich, U., Becker, I., Nekarda, H., Siewert, J. R., and Hofler, H. E-Cadherin gene mutations provide clues to diffuse type gastric carcinomas. *Cancer Res.*, 54: 3845–3852, 1994.
 27. Bex, G., Cloton-Jansen, A. M., Nollet, F., de Leeuw, W. J., van de Vijver, M., Cornelisse, C., and van Roy, F. E-Cadherin is a tumour/invasion suppressor gene mutated in human lobular breast cancers. *EMBO J.*, 14: 6107–6115, 1995.
 28. Anderson, M. S., Venanzi, E. S., Klein, G., Chen, Z., Berzins, S., Turley, S. J., von Boehmer, H., Bronson, R., Dierich, A., Benoist, C., and Mathis, D. Projection of an immunological self-shadow within the thymus by the Aire protein. *Science (Wash. DC)*, 29: 1395–1401, 2002.
 29. Masaoka, A., Monden, Y., Nakahara, K., and Tanioka, T. Follow-up study of thymomas with special reference to their clinical stages. *Cancer (Phila.)*, 48: 2485–2492, 1981.
 30. Sambrook, J., Fritsch, E. F., and Maniatis, T. *Molecular cloning: a laboratory manual*. Cold Spring Harbor, New York: Cold Spring Harbor Laboratory Press, 1989.
 31. Utada, Y., Haga, S., Kajiwara, T., Kasumi, F., Sakamoto, G., Nakamura, Y., and Emi, M. Mapping of target regions of allelic loss in primary breast cancers to 1-cm intervals on genomic contigs at 6q21 and 6q25.3. *Jpn. J. Cancer Res.*, 91: 293–300, 2000.
 32. Wang, V. W., Bell, D. A., Berkowitz, R. S., and Mok, S. C. Whole genome amplification and high-throughput allelotyping identified five distinct deletion regions on chromosomes 5 and 6 in microdissected early-stage ovarian tumors. *Cancer Res.*, 61: 4169–4174, 2001.
 33. Starostik, P., Greiner, A., Schultz, A., Zettl, A., Peters, K., Rosenwald, A., Kolve, M., and Müller-Hermelink, H. K. Genetic aberrations common in gastric high-grade large B-cell lymphoma. *Blood*, 95: 1180–1187, 2000.
 34. Garrido, F., and Algarra, I. MHC antigens and tumor escape from immune surveillance. *Adv. Cancer Res.*, 83: 117–158, 2001.
 35. Brantjes, H., Barker, N., van Es, J., and Clevers, H. TCF: Lady Justice casting the final verdict on the outcome of Wnt signalling. *Biol. Chem.*, 383: 255–261, 2002.
 36. Fodde, R., Smits, R., and Clevers, H. APC, signal transduction and genetic instability in colorectal cancer. *Nat. Rev. Cancer*, 1: 55–67, 2001.
 37. Kinzler, K. W., and Vogelstein, B. Lessons from hereditary colorectal cancer. *Cell*, 87: 159–170, 1996.
 38. Rubinfeld, B., Albert, I., Porfiri, E., Fiol, C., Munemitsu, S., and Polakis, P. Binding of GSK3 β to the APC- β -catenin complex and regulation of complex assembly. *Science (Wash. DC)*, 272: 1023–1026, 1996.
 39. Oda, H., Imai, Y., Nakatsuru, Y., Hata, J., and Ishikawa, T. Somatic mutations of the APC gene in sporadic hepatoblastomas. *Cancer Res.*, 56: 3320–3323, 1996.
 40. Cho, J. H., Noguchi, M., Ochiai, A., and Hirohashi, S. Loss of heterozygosity of multiple tumor suppressor genes in human gastric cancers by polymerase chain reaction. *Lab. Invest.*, 74: 835–841, 1996.
 41. Quintanilla-Martinez, L., Wilkins, E. W., Jr., Choi, N., Efrid, J., Hug, E., and Harris, N. L. Thymoma. Histologic subclassification is an independent prognostic factor. *Cancer (Phila.)*, 74: 606–617, 1994.
 42. Okumura, M., Ohta, M., Tateyama, H., Nakagawa, K., Matsumura, A., Maeda, H., Tada, H., Eimoto, T., Matsuda, H., and Masaoka, A. The World Health Organization histologic classification system reflects the oncologic behavior of thymoma: a clinical study of 273 patients. *Cancer (Phila.)*, 94: 624–632, 2002.
 43. Baffa, R., Santoro, R., Bullrich, F., Mandes, B., Ishii, H., and Croce, C. M. Definition and refinement of chromosome 8p regions of loss of heterozygosity in gastric cancer. *Clin. Cancer Res.*, 6: 1372–1377, 2000.
 44. Fujiwara, Y., Emi, M., Ohata, H., Kato, Y., Nakajima, T., Mori, T., and Nakamura, Y. Evidence for the presence of two tumor suppressor genes on chromosome 8p for colorectal carcinoma. *Cancer Res.*, 53: 1172–1174, 1993.
 45. Pineau, P., Nagai, H., Prigent, S., Wei, Y., Gyapay, G., Weissbach, J., Tiollais, P., Buendia, M. A., and Dejean, A. Identification of three distinct regions of allelic deletions on the short arm of chromosome 8 in hepatocellular carcinoma. *Oncogene*, 18: 3127–3134, 1999.
 46. El-Naggar, A. K., Coombes, M. M., Batsakis, J. G., Hong, W. K., Goepfert, H., and Kagam, J. Localization of chromosome 8p regions involved in early tumorigenesis of oral and laryngeal squamous carcinoma. *Oncogene*, 16: 2983–2987, 1998.
 47. Wistuba, I. I., Behrens, C., Virmani, A. K., Milchgrub, S., Syed, S., Lam, S., Mackay, B., Minna, J. D., and Gazdar, A. F. Allelic losses at chromosome 8p21–23 are early and frequent events in the pathogenesis of lung cancer. *Cancer Res.*, 59: 1973–1979, 1999.
 48. Kagan, J., Stein, J., Babaian, R. J., Joe, Y. S., Pisters, L. L., Glassman, A. B., von Eschenbach, A. C., and Troncoso, P. Homozygous deletions at 8p22 and 8p21 in prostate cancer implicate these regions as the sites for candidate tumor suppressor genes. *Oncogene*, 11: 2121–2126, 1995.
 49. Yaremkov, M. L., Kutza, C., Lyzak, J., Mick, R., Recant, W. M., and Westbrook, C. A. Loss of heterozygosity from the short arm of chromosome 8 is associated with invasive behavior in breast cancer. *Genes Chromosomes Cancer*, 16: 189–195, 1996.
 50. Lassus, H., Laitinen, M. P., Anttonen, M., Heikinheimo, M., Aaltonen, L. A., Ritvos, O., and Butzow, R. Comparison of serous and mucinous ovarian carcinomas: distinct pattern of allelic loss at distal 8p and expression of transcription factor GATA-4. *Lab. Invest.*, 81: 517–526, 2001.
 51. Cabeza-Arvelaiz, Y., Sepulveda, J. L., Lebovitz, R. M., Thompson, T. C., and Chinnault, A. C. Functional identification of LZTS1 as a candidate prostate tumor suppressor gene on human chromosome 8p22. *Oncogene*, 20: 4169–4179, 2001.
 52. Latil, A., Cussenot, O., Fournier, G., and Lidereau, R. Infrequent allelic imbalance at the major susceptibility HPC1 locus in sporadic prostate tumours. *Int. J. Cancer*, 71: 1118, 1997.
 53. Okumura, M., Miyoshi, S., Fujii, Y., Takeuchi, Y., Shiono, H., Inoue, M., Fukuhara, K., Kadota, Y., Tateyama, H., Eimoto, T., and Matsuda, H. Clinical and functional significance of WHO classification on human thymic epithelial neoplasms: a study of 146 consecutive tumors. *Am. J. Surg. Pathol.*, 25: 103–110, 2001.
 54. Suster, S., and Moran, C. A. Primary thymic epithelial neoplasms showing combined features of thymoma and thymic carcinoma. A clinicopathologic study of 22 cases. *Am. J. Surg. Pathol.*, 20: 1469–1480, 1996.
 55. Rodewald, H. S., Paul, S., Haller, C., Bluethmann, H., and Blum, C. Thymus medulla consisting of epithelial islets each derived from a single progenitor. *Nature (Lond.)*, 414: 763–768, 2001.
 56. Blackburn, C. C., Manley, N. R., Palmer, D. B., Boyd, R. L., Anderson, G., and Ritter, M. A. One for all and all for one: thymic epithelial stem cells and regeneration. *Trends Immunol.*, 23: 391–395, 2002.
 57. Gill, J., Malin, M., Hollander, G. A., and Boyd, R. Generation of a complete thymic microenvironment by MTS24 (+) thymic epithelial cells. *Nat. Immunol.*, 3: 635–642, 2002.