

Amifostine Protects against Early but not Late Toxic Effects of Doxorubicin in Infant Rats¹

Kirsi Jahnukainen,² Timo Jahnukainen, Toivo T. Salmi, Konstantin Svechnikov, Staffan Eksborg, and Olle Söder

Pediatric Endocrinology Unit, Karolinska Institute [K. J., K. S., O. S.], and Karolinska Pharmacy [S. E.], Karolinska Hospital, 171 76 Stockholm, Sweden; Department of Pediatrics, University of Turku, 20520 Turku, Finland [K. J., T. T. S.]; and Children's Hospital, University of Helsinki, 00290 Helsinki, Finland [K. J., T. J.]

ABSTRACT

The improved prognosis and increased expected lifetime among long-term survivors of childhood malignancies have made these patients especially sensitive to the late toxicity of cancer therapy and prone to secondary malignancies. Recently, new strategies aiming to protect against cancer treatment toxicity have been developed, including the drug amifostine (Ethyol), which is suggested to protect normal tissues from the toxic effects of radiation and cytotoxic agents. In the present study, the possible protective effect of amifostine against toxicity induced by a single injection of doxorubicin (3 mg/kg) in immature rats was evaluated. Specifically, we evaluated the protection against long-term toxicity and the effects of amifostine on growing immature tissues. Amifostine (50–200 mg/kg) given 15 min before doxorubicin had a significant protective effect against doxorubicin-induced early alopecia in young rats. Significant protection against cataract formation was obtained by the use of low-dose amifostine (50 mg/kg). However, amifostine did not protect young rats against the late toxic effect of doxorubicin on linear growth, body weight, plasma leptin levels, and heart or testicular tissue. Worrisome, and in contrast to earlier studies in adult rats, an increased doxorubicin toxicity actually was observed and mortality was increased when the higher doses of amifostine (100–200 mg/kg) were used. The present results suggest that more data from growing immature animal models are needed to analyze the safety of amifostine treatment and its mechanisms of action before wider clinical use of this drug in pediatric cancer patients is recommended.

INTRODUCTION

The prognosis of childhood cancer has improved markedly in the last 20 years, which has led to a greater awareness of the late consequences of successful curing therapy. The long life expectancy of the young survivors makes them especially prone to the late sequelae of cancer therapy, *e.g.*, therapy-induced secondary malignancies, cardiac toxicity, and infertility. Childhood cancer survivors would be the group that might gain the most from the new strategies aiming to protect against cancer treatment toxicity (1).

Amifostine (Ethyol), a recently introduced cytoprotective drug, has been demonstrated to protect normal tissue from the toxic effects of radiation therapy and cytotoxic drugs both in animal models and clinical studies (2–5). *In vitro*, amifostine may even diminish the potential genotoxic and carcinogenic effects of the cancer therapy (2, 5). Amifostine is believed to scavenge free radicals, disarm radicals on essential molecules, and form mixed disulfides to protect normal cells (2). In contrast, malignant cells are not protected, and the enhancement of chemo- and radiotherapy has been observed in clinical studies (6, 7). The selectivity, in terms of cytoprotection of normal

tissues, is assumed to be related to the perfusion-related distribution and absorption of amifostine and a greater alkaline phosphatase activity in normal than in malignant tissues (2, 3).

Knowledge of the usefulness of amifostine in children is poor. It is not known whether amifostine protects against the long-term toxicity of cytostatic drugs and radiation, or whether amifostine itself may have some late effects in children. Only a few clinical trials with amifostine in children have been published, mainly including short-term follow-ups among relapsed poor-risk patients (8–10). In these studies, significant protection of amifostine against the early hematological toxicity of chemotherapy has been reported. Doxorubicin is a cytotoxic drug known to bind and intercalate DNA, to inhibit topoisomerase II activity, to generate free radicals, and to covalently bind to DNA after reductive metabolism (11). Observed side effects in clinical trials and rat model studies included myelosuppression, alopecia, cataract formation, chronic cardiotoxicity, and testicular toxicity (12–17). As there are no reports of the effects of amifostine on growing immature individuals, we performed the present study to evaluate the possibility that amifostine would protect against doxorubicin induced toxicity in immature rats. Specifically, we evaluated protection against long-term toxicity and the effects of amifostine on growing immature tissues.

MATERIALS AND METHODS

Animals. Lactating Sprague Dawley rats with 10 male newborns/mother were purchased from BK-Universal (Stockholm, Sweden) and kept under standard conditions at the animal house of the Karolinska Institute, Stockholm, Sweden. Animals were separated from the mother at the age of 25 days and were thereafter given rodent chow and water *ad libitum*. The study was approved by the local animal ethics committee (P. N. 169/97).

Treatment Protocol. The animals were randomized, and 10 in each group were treated at a postnatal age of 6 days with a single i.p. injection of either 3 mg/kg doxorubicin, 200 mg/ml amifostine, or saline. Another three groups of 10 animals received an i.p. injection of 50, 100, or 200 mg/kg amifostine, respectively, as a pretreatment 15 min before 3 mg/kg of doxorubicin i.p. Amifostine (Schering Plough, Stockholm, Sweden) and lyophilized doxorubicin (Pharmacia Upjohn, Stockholm, Sweden) were dissolved in saline immediately before use and injected in dose volumes of 0.06–0.25 ml/100 g of body weight (50 mg/ml) and 0.15 ml/100 g of body weight (2 mg/ml), respectively. The body temperature was measured in control, amifostine only, doxorubicin only, and doxorubicin and amifostine 50 mg/kg pretreated animals at 0, 30, 60, and 90 min and at 20 h after the first injection. A small but statistically insignificant decrease in body temperature was observed 60 min after the first injection of amifostine in each treatment group (temperature, 0 min and 60 min: control, 33.3 ± 0.2 and 32.7 ± 0.2°C; amifostine 200 mg/kg, 33.4 ± 0.1 and 31.7 ± 0.2°C; doxorubicin 3 mg/kg, 32.7 ± 0.2 and 32.6 ± 0.2°C; and amifostine 50 mg/kg + doxorubicin 3 mg/kg, 33.7 ± 0.1 and 33.0 ± 0.2°C, respectively). Body temperature normalized to the pretreatment level in all groups within 90 min after treatment and was stable for the next 20 h of follow-up. No statistically significant differences in body temperature were seen between the different treatment groups.

In a second experiment, 20 young rats at the age of 6 days were treated by injection of 3 mg/kg doxorubicin i.v. in the tail vein. Ten of these animals were treated with 50 mg/kg amifostine i.p. 15 min before doxorubicin administration.

Study Variables. Animals were observed and weighed weekly, and the appearance of alopecia and cataract as well as the deaths were noted. The study

Received 1/15/01; accepted 7/3/01.

The costs of publication of this article were defrayed in part by the payment of page charges. This article must therefore be hereby marked *advertisement* in accordance with 18 U.S.C. Section 1734 solely to indicate this fact.

¹Supported by grants from the Swedish Children's Cancer Fund, the Finnish Cancer Society, the Finnish Cultural Foundation, and the Finnish Pediatric Research Foundation; from the Nona and Kullervo Väre Foundation (to K. J.); from the Åke Wiberg Foundation, the Cancer and Traffic Injury Victims Foundation, the Cancer and Allergy Fund; and by Grants 8282 and 11412 from the Swedish Medical Research Council (to O. S.).

²To whom requests for reprints should be addressed, at Children's Hospital, University of Helsinki, Stenbäckinkatu 11, FIN-00290 Helsinki, Finland. Phone: 358-9-4711; Fax: 358-9-47174707; E-mail: Kirsi.Jahnukainen@hus.fi.

was terminated when animals were 80 days of age, *i.e.*, 74 days after the start of the treatment. Animals were euthanized with an overdose of carbon dioxide, and blood samples were collected for testosterone and leptin analyses. Body weight and nose-tail length were measured. The heart, spleen, liver, right kidney, right testis, right epididymis, and right seminal vesicle were excised from each animal and weighed. Hearts were immersion-fixed in 10% neutral buffered formalin and testes were immersion-fixed in Bouin's fixative. The samples were embedded in paraffin and prepared for light microscopic examination.

Testosterone and Leptin Analyses. Testosterone and leptin were assayed in plasma samples. Testosterone was measured by a Coat-a-Count radioimmunoassay kit (Diagnostic Products Corporation, Los Angeles, CA), and leptin was measured by a rat-specific radioimmunoassay kit (Diagnostika, Stockholm, Sweden) according to the manufacturers' instructions.

Statistical Analysis. Data are presented as the mean values \pm SE. The Mann-Whitney nonparametric *U* test was used for comparison of two independent sample populations. Kruskal-Wallis analyses with a Dunn's posttest were performed for multiple comparison of independent sample populations. The mortality data were analyzed using the Kaplan-Meier method with a log-rank test for the comparison of curves. A $P < 0.05$ was considered significant.

RESULTS

Weight Changes and Early Toxicity of Doxorubicin after Amifostine Pretreatment. There was a slower gain of the body weight, starting 25 days after treatment with doxorubicin, when compared with saline- or amifostine-only-treated controls. This difference in body weight increased up to the end of the experiment. There was no protection against the poor weight gain with any amifostine pretreatment dose. The weight gain in amifostine-only-treated rats was comparable with controls.

The eyes of the animals were opened during the 2nd week after treatment and were judged to be normal in all treatment groups. The incidence of cataract increased slowly during the 3rd week after doxorubicin treatment, reaching its maximum (70% of all living animals) 25 days after doxorubicin injection (Fig. 1A). Pretreatment with 50 mg/kg of amifostine before doxorubicin significantly decreased cataract formation. Only 10% of all living animals in this treatment group had developed cataract 25 days after treatment (Fig.

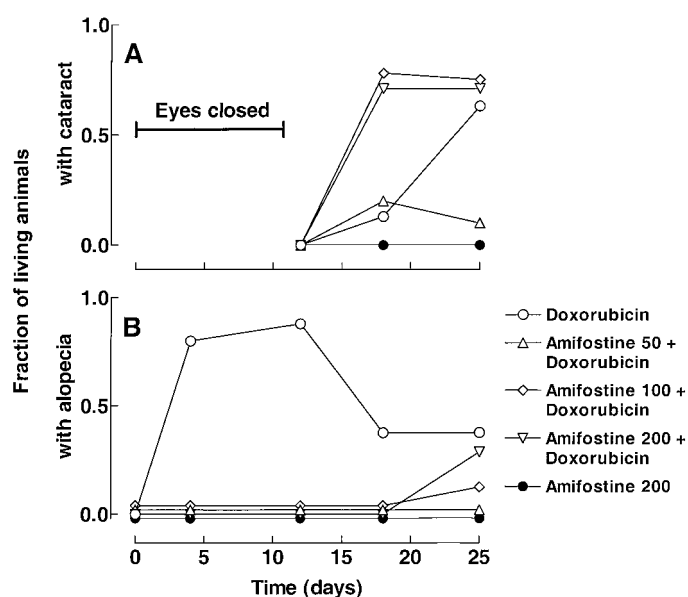


Fig. 1. Cumulative incidence of doxorubicin-induced cataract (A) and alopecia (B) and effect of pretreatment with 50, 100, and 200 mg/kg of amifostine 15 min before injection of 3 mg/kg doxorubicin *i.p.* Amifostine 200 mg/kg without doxorubicin was used as a treatment control.

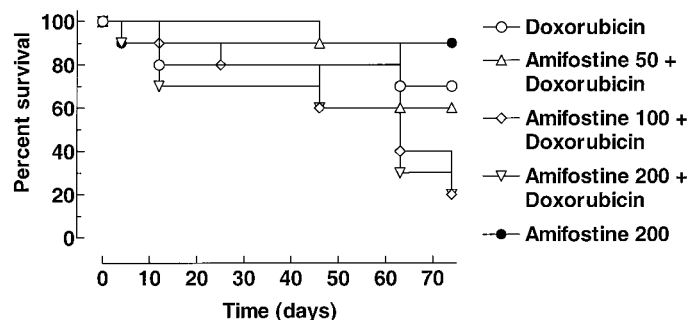


Fig. 2. Survival after *i.p.* injection of amifostine 200 mg/kg, *i.p.* doxorubicin 3 mg/kg alone or combined with amifostine 50, 100, or 200 mg/kg 15 min before doxorubicin during a total follow-up time of 74 days. ($P = 0.015$; Kaplan-Meier method with the log-rank test).

1A). Animals receiving the higher amifostine doses (100 mg/kg and 200 mg/kg) showed a rapid appearance of cataract during the 2nd week after treatment. The incidence of cataract in these treatment groups was already 70% of all living animals 18 days after the treatment (Fig. 1A). No cataract was observed in control or amifostine-only groups.

Head and proximal neck alopecia was observed 4 days after the single dose of doxorubicin (Fig. 1B). Altogether, 90% of living animals had lost their neck hair during the 2nd week after treatment. Thereafter, regrowth of the fur was observed, and alopecia disappeared. In contrast, amifostine-pretreated animals did not lose their neck hair during the 1st and 2nd weeks after doxorubicin treatment. All amifostine doses were effective to protect against alopecia (Fig. 1B). A small injection-site alopecia not affected by amifostine pretreatment was found in all doxorubicin-treated rats. No alopecia was observed in control or amifostine-only-treated animals.

Mortality after Doxorubicin and Amifostine Pretreatment. Data on mortality during the course of study are shown in Fig. 2. A statistically significant ($P = 0.015$) difference in survival between the different treatment groups was observed. Of the doxorubicin-only-treated animals, 3 of 10 died before termination of the experiment, giving a survival rate of 70%. Two of the deaths occurred during the 2nd week after treatment, and the third death occurred 65 days after treatment. There was no early mortality in the animal group pretreated with 50 mg/kg amifostine. However, 4 of 10 animals died after 45 days of follow-up, giving a survival rate of 60%. Pretreatment with 100 mg/kg and 200 mg/kg of amifostine was toxic to young rats. The mortality in these groups started to increase after 45 days of follow-up and reached 80% at the time of cessation of experiment when the animals were 80 days of age. At the necropsy, the most consistent gross pathological changes found in animals with early deaths were excessive amounts of peritoneal fluid and a pale discoloration of the kidneys and the intestine. Organ weights of three rapidly necropsied 200 mg/kg amifostine-pretreated rats were obtained at the ages of 52, 65, and 66 days. Body weights of these animals were 100 g, 196 g, and 224 g; heart weights were 642 mg, 761 mg, and 1196 mg; and testis weights were 210 mg, 280 mg, and 151 mg, respectively. There were no deaths in the group of 10 control animals. In the amifostine-only treated group, one animal was lost during the 1st day of the experiment because of bleeding after injection.

Late Toxicity of Doxorubicin after Amifostine Pretreatment. At the end of the experiment, the body weights in the doxorubicin-treated group were significantly lower compared with control and amifostine-only-treated groups. No protection against low final body weight was obtained with pretreatment with 50 mg/kg of amifostine (Table 1). Because animals receiving doxorubicin were so much smaller, additional comparison of organ weights was made with

Table 1 Body and organ weights and nose-tail length of treated and control rats after follow-up of 74 days

Treatment	Saline control		Amifostine 200 mg/kg		Doxorubicin 3 mg/kg		Amifostine (50 mg/kg) + Doxorubicin (3 mg/kg)	
	Weight	Weight index (mg/g) ^a	Weight	Weight index (mg/g) ^a	Weight	Weight index (mg/g) ^a	Weight	Weight index (mg/g) ^a
Body weight (g) ^a	455 ± 9		400 ± 16		283 ± 36		295 ± 19	
Kidney weight (mg) ^a	1,618 ± 28	3.6 ± 0.1	1,456 ± 55	3.6 ± 0.1	1,115 ± 122 ^b	4.0 ± 0.2	1,120 ± 80 ^b	3.8 ± 0.2
Spleen weight (mg) ^a	913 ± 27	2.0 ± 0.1	890 ± 26	2.2 ± 0.1	539 ± 118 ^b	1.8 ± 0.2	798 ± 147	2.9 ± 0.7
Liver weight (mg) ^a	17,312 ± 823	38.0 ± 1.4	15,100 ± 677	37.7 ± 0.8	11,697 ± 1552 ^b	41.8 ± 2.6	10,591 ± 987 ^b	35.7 ± 1.8
Heart weight (mg) ^a	1,653 ± 38	3.6 ± 0.1	1,477 ± 55	3.7 ± 0.1	1,254 ± 151 ^b	4.5 ± 0.2 ^b	1,441 ± 120	4.9 ± 0.4 ^{b,c}
Testis weight (mg) ^a	1,560 ± 54	3.5 ± 0.1	1,535 ± 28	3.9 ± 0.1	352 ± 95 ^b	1.2 ± 0.2 ^{b,c}	488 ± 119 ^{b,c}	1.7 ± 0.4 ^c
Epididymis weight (mg) ^a	533 ± 24	1.1 ± 0.1	518 ± 17	1.3 ± 0.0	106 ± 32 ^b	0.3 ± 0.0 ^{b,c}	157 ± 29 ^{b,c}	0.6 ± 0.1 ^c
Seminal vesicle weight (mg) ^a	536 ± 21	1.2 ± 0.1	487 ± 16	1.2 ± 0.0	88 ± 31 ^{b,c}	0.3 ± 0.1 ^{b,c}	70 ± 17 ^{b,c}	0.2 ± 0.0 ^{b,c}
Nose-tail length (mm) ^a	Length	Length index (mm/g)	Length	Length index (mm/g)	Length	Length index (mm/g)	Length	Length index (mm/g)
	474 ± 2	1.1 ± 0.0	468 ± 4	1.2 ± 0.1	423 ± 11 ^{b,c}	1.6 ± 0.2 ^b	430 ± 8 ^b	1.5 ± 0.1 ^b

^a Values are given as mean ± SE.

^b $P < 0.05$ compared with value in control group.

^c $P < 0.05$ compared with value in amifostine 200 mg/kg-treated group.

relative index values (organ weight/body weight). In the doxorubicin-treated group, heart weight indices were significantly increased and testicular, epididymis, and seminal vesicle weight indices significantly decreased as compared with control and amifostine-only-treated groups (Table 1). The organ weight indices in the amifostine-pretreated group did not differ from those in the doxorubicin-only treated group (Table 1). There were no changes in weight indices of other investigated organs after doxorubicin treatment compared with control, amifostine-only, or amifostine-pretreatment groups (Table 1). Body and organ weights in amifostine-only-treated groups were comparable with controls (Table 1). At necropsy, the gross pathological changes in doxorubicin-treated and amifostine-pretreated animals were comparable with those seen in the animals with early deaths. No gross abnormalities were observed in animals given amifostine-only or in saline-treated controls. The high mortality in the 100 mg/kg and 200 mg/kg amifostine-pretreated groups did not allow additional analysis of any protective effect at the end of experiment. The mean index values for heart (mg/g index, 4.8 ± 1.5) and testis (mg/g index, 1.5 ± 0.9) weights were measured for three necropsied (dead 14, 15, and 28 days before cessation of experiment) and two surviving rats in the 200 mg/kg amifostine-pretreatment group. No statistical difference ($P > 0.05$) was observed when these values were compared with the mean index values for heart (mg/g index, 4.5 ± 0.2) and testis (mg/g index, 1.2 ± 0.2) in the doxorubicin-treated group at the end of experiment.

Late Toxicity of Doxorubicin after i.v. Injection and Effect of Amifostine Pretreatment. In all animals, i.v. injection of doxorubicin into the tail vein caused mild to severe tissue necrosis in surrounding s.c. tissues of the injection site. Deformed tails were observed in six of eight surviving rats at the end of experiment, i.e., at the age of 80 days, and no difference was observed after amifostine pretreatment (5 of 7 rats). Cataract appeared in 5 of 10 animals during the 3rd week after treatment with i.v. doxorubicin, reaching its maximum (6 of 10 animals) 25 days after the treatment. Altogether, 2 of 10 animals got cataract after 50 mg/kg amifostine-pretreatment during the 2nd week after treatment, and the prevalence of cataract reached 100% (10 of 10) 25 days after treatment. A low incidence of alopecia (2 of 10 rats) was observed 12 days after i.v. doxorubicin with and without 50 mg/kg amifostine-pretreatment. Survival at the end of experiment did not differ statistically ($P = 0.94$) between the doxorubicin-only-treated group (survival 80%) and the amifostine-pretreated group (survival 70%). All of the early deaths occurred later than 45 days of follow-up. The final body weights at the end of the experiment were 298 ± 32 g and 271 ± 17 g in the two groups of animals, respectively. Heart weight in the doxorubicin i.v. group was 1125 ± 111 mg (mg/g

index, 3.9 ± 0.2); in the amifostine-pretreated group, it was 1154 ± 62 mg (mg/g index, 4.3 ± 0.1); testis weight was 1013 ± 64 mg (mg/g index, 3.8 ± 0.6) and 998 ± 99 mg (mg/g index, 3.8 ± 0.5), respectively. There was no statistically significant difference ($P > 0.05$) in body weight or in any measured organ weights between amifostine-pretreated or doxorubicin i.v. treated group. At the necropsy, the gross pathological changes were comparable with the doxorubicin i.p. treated group.

Histological Morphology of Cardiac and Testicular Tissue.

Testicular tissue of animals treated with a single dose of doxorubicin i.p. at the age of 6 days showed major damage of the spermatogenic epithelium at the age of 80 days. Sertoli-cell-only tubules with some degenerating spermatogenic cells were seen in histological sections. Leydig cell hyperplasia was observed in the interstitium. The damage in testicular morphology after amifostine 50 mg/kg pretreatment was similar to that after doxorubicin-only treatment, and no signs of protection were seen at the microscopic level. Control animals and amifostine-only-treated animals showed normal testicular morphology. In light microscopic sections from myocardium of doxorubicin i.p.-treated animals, the alterations consistent with doxorubicin-induced toxicity were seen. Cardiomyocytes were vacuolated, and edema of the cells was observed. Similar changes were observed also after amifostine 50 mg/kg pretreatment. Control animals and amifostine-only-treated animals showed normal myocardial morphology.

Testosterone and Leptin Levels after Amifostine and Doxorubicin Treatment. Testosterone levels in control, amifostine-only, doxorubicin i.p.-only, and amifostine 50 mg/kg-pretreated doxorubicin i.p. groups were 4.1 ± 0.9 ng/l, 1.6 ± 0.6 ng/l, 3.1 ± 1.1 ng/l, and 5.8 ± 2.1 ng/l, respectively, at the end of the experiment. There was no statistically significant difference between the treatment groups. Leptin levels in the same treatment groups were 5.7 ± 0.7 ng/l, 7.7 ± 1.1 ng/l, 3.7 ± 1.1 ng/l, and 3.7 ± 1.0 ng/l, respectively. There was a statistically significant difference ($P < 0.05$) in leptin levels between amifostine-only- and doxorubicin-only-treated groups and amifostine-only and amifostine-pretreated groups.

DISCUSSION

The present study shows that amifostine in young growing rats has significant protective effect against alopecia, an early toxic effect of doxorubicin. Hair is lost because of the necrotizing effect of peak plasma doxorubicin levels on hair follicle cells, which are actively dividing (15). The present observation is in line with the previous clinical results that amifostine has a protective effect in actively dividing hematopoietic cells in bone marrow (8, 9).

A high rate of cataract formation is reported after pediatric bone marrow transplantation (18, 19). The growing lens during infancy is known to be sensitive to irradiation, high-dose chemotherapy, and systemic steroids (14, 18). Busulfan, a cytotoxic drug, has been shown to induce a reduction of mitotic activity in the lens epithelium and nuclear disintegration with chromatin aggregation leading to cataract formation in rats and humans (20, 21). In the present study, a low dose 50 mg/kg of amifostine showed significant protection against the doxorubicin-induced changes in the lens and decreased cataract formation.

Earlier clinical studies have suggested that young children may tolerate higher amifostine doses than adult patients, and that higher doses of amifostine in children give increased protection against myelosuppression (8). According to these results, an amifostine dose of 1650 mg/m² has been recommended for future Phase II pediatric trials. The recommended dose in adults for myeloprotection is 740–910 mg/m² (4, 5). In light of these recommendations, the present observations that high doses of amifostine (100–200 mg/kg equal to 300–600 mg/m²; Ref. 22) in young growing rats actually increased late toxicity of doxorubicin and caused late mortality, are worrisome. An amifostine dose of 200 mg/kg has been reported to protect various tissues against doxorubicin toxicity in adult rats (3). In the present study, the young rats initially tolerated high amifostine doses, and there was protection against early toxicity of doxorubicin with these doses. Cataract appeared as the first sign of the adverse effects of high amifostine doses, and mortality of the animals increased markedly after 45 days of follow-up. At necropsy, the gross pathological changes compatible with doxorubicin toxicity were seen in animals with early deaths. A similarly increased late mortality 9–11 weeks after the use of amifostine and repeated doses of doxorubicin has been reported recently in spontaneous hypertensive rats (23). Our results show the importance of long-term follow-up when optimal doses of amifostine are selected for the treatment of children.

In the present immature rat model, the best protection against alopecia and cataract formation was reached with a dose of 50 mg/kg of amifostine. With this dose, long-term survival was comparable with the doxorubicin-treated group. However, when the effects of doxorubicin in heart and testicular spermatogenic epithelia were evaluated, no significant protection was seen. The animals grew poorly in both amifostine-pretreated and doxorubicin-only-treated groups. The present study shows clearly that amifostine does not have protective effect against the late toxicity of doxorubicin when the lower doses with acceptable mortality were used. Our results from rats with early deaths, receiving the highest dose of amifostine, do not suggest that an increased dose of amifostine has protective effect in the sensitive organs. Among some laboratory animal strains, extreme reduction in body temperature after treatment with amifostine has been reported as leading to peripheral vasoconstriction, decreased renal clearance, and potentiation of chemotherapy toxicity (24). We could not detect any significant changes in body temperature after amifostine injection, suggesting that changes in body temperature have not interfered with the results in the presently used animal model.

In the present study, marked toxicity of a single i.p. injection of doxorubicin in young growing animals was detected. The degree of weight loss was more pronounced than the decrease in linear growth. The decrease in plasma levels of leptin in doxorubicin-treated groups also suggests a decrease in fat mass, as leptin concentration in blood is known to be proportional to body fat mass, both in humans and rodents (25). Gastrointestinal lesions caused by the local effects of i.p. injections might have been an important factor in the decline in body weight. However, the i.p. route of doxorubicin was not shown to create increased lesions in intraabdominal organs or to affect the amifostine protection. When the study was repeated with doses given

i.v., a similar decline in body weight was seen, and the gross intestinal pathology in necropsy was comparable with i.p.-treated animals. No protection with amifostine was seen, irrespective of the doxorubicin administration route chosen.

The observed tissue necrosis at the injection site of the tail neck in the treated group is obviously attributable to some tissue leakage of doxorubicin. This may affect the pharmacokinetics of doxorubicin and decrease the peak plasma levels of the drug. The observed slightly lower mortality, lower incidence of alopecia, and decreased testicular toxicity in the i.v.- compared with the i.p.-treated group may be a reflection of this phenomena. Interestingly, the i.v. route of administration of doxorubicin abolished the protective effect of 50 mg/kg amifostine on cataract formation. This suggests that the timing of amifostine dosing to reach protective concentrations in correlation to peak plasma levels of doxorubicin may be critical for ocular protection. Another possibility behind the higher testicular toxicity observed in the i.p.-treated group is that doxorubicin may have a direct toxic effect in the testicular tissue by diffusion through the testicular capsule. This aspect is important when planning additional studies on testicular toxicity in very immature animals. In contrast, the heart was damaged both with i.p. and i.v. injections of doxorubicin. This suggests that the heart in young rats is very sensitive to doxorubicin, which is in agreement with clinical observations that the risk of long-term cardiotoxicity is increased when treatment is given to very young children (26).

In conclusion, our results demonstrate that amifostine has a significant protective effect against early toxicity of doxorubicin in young growing animals. However, amifostine did not protect young rats against late toxic effects of doxorubicin on linear growth, heart, or testicular tissue. More worrisome, the mortality was actually found to be increased after pretreatment with high doses of amifostine. Additional studies analyzing the safety of amifostine treatment and the mechanisms of exacerbation of doxorubicin toxicity by amifostine in young growing animals are highly warranted before a wider use of this drug in pediatric cancer patients can be recommended.

ACKNOWLEDGMENTS

We thank Dr. Ann-Christine Eklöf and Annika Lindberg for skilful technical assistance.

REFERENCES

- Bukowski, R. Cytoprotection in the treatment of pediatric cancer: review of current strategies in adults and their application to children. *Med. Pediatr. Oncol.*, 32: 124–134, 1999.
- Peters, G. J., and van der Vijgh, W. J. F. Protection of normal tissues from the cytotoxic effects of chemotherapy and radiation by amifostine (WR-2721): preclinical aspects. *Eur. J. Cancer*, 31A: S1–S7, 1995.
- Capizzi, R. L. The preclinical basis for broad-spectrum selective cytoprotection of normal tissues from cytotoxic therapies by amifostine (Ethyol). *Eur. J. Cancer*, 32A: S5–S16, 1996.
- Budd, G. T., Ganapathi, R., Adelstein, D. J., Pelley, R., Olencki, T., Petrus, J., McLain, D., Zhang, J., Capizzi, R., and Bukowski, R. M. Randomized trial of carboplatin plus amifostine versus carboplatin alone in patients with advanced solid tumors. *Cancer (Phila.)*, 80: 1134–1140, 1997.
- Santini, V., and Giles, F. J. The potential of amifostine: from cytoprotectant to therapeutic agent. *Haematologica*, 84: 1035–1042, 1999.
- Schiller, J. H., Storer, B., Berlin, J., Wittenkeller, J., Larson, M., Pharo, L., Larson, M., and Berry, W. Amifostine, cisplatin and vinblastine in metastatic non-small-cell lung cancer: report of high response rates and prolonged survival. *J. Clin. Oncol.*, 14: 1913–1921, 1996.
- Glover, D., Glick, J. H., Weiler, C., Fox, K., and Guerry, D. WR-2721 and high-dose cisplatin: an active combination in the treatment of metastatic melanoma. *J. Clin. Oncol.*, 5: 574–578, 1987.
- Adamson, P. C., Balis, F. M., Belasco, J. E., Lange, B., Berg, S. C., Blaney, S. M., Craig, C., and Poplack, D. G. A phase I trial of amifostine (WR-2721) and melphalan in children with refractory cancer. *Cancer Res*, 55: 4069–4072, 1995.

9. Borsi, J. D., Csáski, C., Ferencz, T., and Oster, W. Administration of Etyhol (amifostine) to a child with medulloblastoma to ameliorate hematological toxicity of high dose carboplatin. *Anticancer Drugs*, 7: 121–126, 1996.
10. De Kraker, J., Bierings, M. B., and Offringa, M. Lack of protection of proximal tubular cells by amifostine (Etyhol) in ifosfamide-containing regimens. *Med. Pediatr. Oncol.*, 34: 78–79, 2000.
11. Myers, C. E., Jr., and Chabner, B. A. Anthracyclines. In: B. A. Chabner and J. M. Collins (eds.), *Cancer Chemotherapy; Principles and Practice*, p. 356–360. Philadelphia: J. B. Lippincott Co., 1990.
12. Lefrak, E. A., Pitha, J., Rosenheim, S., and Gottlieb, J. A. A clinicopathologic analysis of Adriamycin cardiotoxicity. *Cancer (Phila.)*, 32: 302–314, 1973.
13. Blum, R. H., and Carter, S. K. Adriamycin: a new anticancer drug with significant clinical activity. *Ann. Int. Med.*, 80: 249–259, 1974.
14. Casazza, A. M., Bellini, O., Formelli, F., Giuliani, F., Lenaz, L., and Magrini, U. Tumors and dental and ocular abnormalities after treatment of infant rats with Adriamycin. *Tumori*, 63: 331–338, 1977.
15. Balsari, A. L., Morelli, D., Ménard, S., Veronesi, U., and Colnaghi, M. I. Protection against doxorubicin-induced alopecia in rats by liposome-entrapped monoclonal antibodies. *FASEB J.*, 8: 226–230, 1994.
16. Jahnukainen, K., Hou, M., Parvinen, M., Eksborg, S., and Söder, O. Stage-specific inhibition of deoxyribonucleic acid synthesis and induction of apoptosis by anthracyclines in cultured rat spermatogenic cells. *Biol. Reprod.*, 63: 482–487, 2000.
17. Arola, O., Saraste, A., Pulkki, K., Kallajoki, M., Parvinen, M., and Voipio-Pulkki, L.-M. Acute doxorubicin cardiotoxicity involves cardiomyocyte apoptosis. *Cancer Res.*, 60: 1789–1792, 2000.
18. Ng, J. S. K., Lam, D. S. C., Li, C. K., Chik, K. W., Cheng, G. P. M., Yuen, P. M. P., and Tso, M. O. M. Ocular complications of pediatric bone marrow transplantation. *Ophthalmology*, 106: 160–164, 1999.
19. Frisk, P., Hagberg, H., Mandahl, A., Söderberg, P., and Lönnerholm, G. Cataracts after autologous bone marrow transplantation in children. *Acta Paediatr.*, 89: 814–819, 2000.
20. Grimes, P., von Sallmann, L., and Frichette, A. Influence of Myleran on cell proliferation in the lens epithelium. *Investig. Ophthalmol.*, 3: 566–576, 1964.
21. Kaida, T., Ogawa, T., and Amemiya, T. Cataract induced by short-term administration of large doses of busulfan: a case report. *Ophthalmologica*, 231: 397–399, 1999.
22. Holford, N. H. G. A size standard for pharmacokinetics. *Clin. Pharmacokinet.*, 30: 329–332, 1996.
23. Herman, E. H., Zhang, J., Chadwic, D. P., and Ferrans, V. J. Comparison of the protective effects of amifostine and dexrazoxane against the toxicity of doxorubicin in spontaneously hypertensive rats. *Cancer Chemother. Pharmacol.*, 45: 329–334, 2000.
24. Korst, A. E. C., Boven, E., van der Sterre, M. L. T., Fichtinger-Schepman, A. M. J., and van der Vijgh, W. J. F. Influence of single and multiple doses of amifostine on the efficacy and the pharmacokinetics of carboplatin in mice. *Br. J. Cancer*, 75: 1439–1446, 1997.
25. Himms-Hagen, J. Physiological roles of the leptin endocrine system: differences between mice and humans. *Crit. Rev. Clin. Lab. Sci.*, 36: 575–655, 1999.
26. Lipshultz, S. E., Colan, S. D., Gelber, R. D., Perez-Atayde, A. R., Sallan, S. E., and Sanders, S. P. Late cardiac effects of doxorubicin therapy for acute lymphoblastic leukemia in childhood. *N. Engl. J. Med.*, 324: 808–815, 1991.