

Normalization of Elevated Hepatic 8-Hydroxy-2'-Deoxyguanosine Levels in Chronic Hepatitis C Patients by Phlebotomy and Low Iron Diet¹

Junji Kato, Masayoshi Kobune, Tokiko Nakamura, Ganji Kuroiwa, Kohichi Takada, Rishu Takimoto, Yasuhiro Sato, Koshi Fujikawa, Minoru Takahashi, Tetsuji Takayama, Tatsuru Ikeda, and Yoshiro Niitsu²

Fourth Department of Internal Medicine [J. K., T. N., G. K., K. T., R. T., Y. S., K. F., M. T., T. T., Y. N.] and Department of Molecular Medicine [M. K.], Sapporo Medical University School of Medicine, and Department of Clinical Pathology, Sapporo Medical University Hospital [T. I.], Sapporo 060-8543, Japan

ABSTRACT

Accumulation of 8-hydroxy-2'-deoxyguanosine (8-OHdG) in DNA, which may result from the continuous reactive oxygen species (ROS) generation associated with chronic inflammation, has been reported in various human preneoplastic lesions and in cancerous tissues. However, no direct causative relationship between the 8-OHdG formation and carcinogenesis has been thus far demonstrated in humans. Directly proving the causality requires showing that depletion of 8-OHdG levels in tissue by interfering with ROS generation results in a reduction in cancer. Chronic hepatitis C virus (HCV) infection is associated with a high risk of hepatocellular carcinoma (HCC). Several studies on patients with chronic HCV have shown that hepatic iron overload is attributable to liver injury and that iron depletion improved serum aminotransferase levels. Excess iron is known to generate ROS within cells, which causes mutagenic lesions, such as 8-OHdG. In this study, therefore, we have evaluated whether therapeutic iron reduction (phlebotomy and low iron diet) with a long-term follow-up (6 years) would decrease the hepatic 8-OHdG levels and the risk of HCC development in patients with chronic HCV. Patients (34) enrolled were those who had undergone standard IFN therapy but had no sustained response. Quantitative immunohistochemistry using the KS-400 image analyzing system and electrochemical detection was used for 8-OHdG detection. With this treatment, elevated hepatic 8-OHdG levels in patients with chronic hepatitis C ($8.3 \pm 4.6/10^5$ dG) significantly decreased to almost normal levels ($2.2 \pm 0.9/10^5$ dG; $P < 0.001$) with concomitant improvement of hepatitis severity, including fibrosis, whereas HCV titers were unaffected. None of these patients developed HCC. Thus, long-term iron reduction therapy in patients with chronic hepatitis C may potentially lower the risk of progression to HCC.

INTRODUCTION

Chronic inflammation is tightly associated with the continuous generation of ROS,³ which causes various types of tissue damage (1, 2). Damaging events at the molecular level underlying these various types include lipid peroxidation, degradation of proteins or sugars, strand breakage of DNA, and formation of 8-OHdG (3–5). Through these molecular derangements, highly concentrated ROS may give rise to parenchymal cell death, replaced by tissue fibrosis (6). Even when ROS levels are too low to cause such lethal damage, chronic exposure to cells can lead to accumulation of 8-OHdG in DNA. 8-OHdG is generated by oxidation of C8 of guanine and forms pairs with undesirable adenine residue in addition to authentic cytosine residue in DNA, thereby leading to a greatly increased frequency of G:C to T:A transversion mutation (7–9). Accumulation of 8-OHdG in

DNA eventually brings about cellular mutagenesis and subsequent carcinogenesis. However, this sequential progression has been observed only in animal models (10–12). In humans, the increment of 8-OHdG in DNA has been found in various inflammation-related putative preneoplastic lesions, such as gastric mucosa infected with *Helicobacter pylori* (13), mucosa of inflammatory bowel diseases (14), uterine cervical cells with dysplasia (15), and several cancerous tissues, including lung, colon, breast and stomach (16–18). However, there has been no report demonstrating a direct causative relationship between the 8-OHdG formation and carcinogenesis in human tumors.

HCV infection is a major cause of HCC worldwide (19). However, the mechanism behind the genesis of HCC associated with HCV infection has not been clarified yet. Clinically persistent elevation of serum ALT levels and hepatic fibrosis has been found to be linked with the development of HCC (20, 21). Both of these HCC-related clinical manifestations may be reflections of the hepatocyte damage and induction of collagen synthesis in hepatic stellate cells caused by ROS (22), which, on the other hand, is a mutagenesis factor. Generation of ROS, particularly the hydroxyl radical ($\cdot\text{OH}$), which is the key radical for 8-OHdG formation, is facilitated by the presence of iron.

Because the liver is an iron-rich organ which contains ~30% of total body storage iron (23), it is considered to be one of the most susceptible organs to cellular damage or DNA mutagenesis caused by ROS; in this regard, we have shown previously that in Long-Evans cinnamon rats, an abrupt accumulation of iron in the liver caused spontaneous hepatitis and subsequent development of HCC (24). It is therefore highly plausible that ROS and iron are involved in the hepatocarcinogenesis of HCV infection. There have, in fact, been reports demonstrating that there is an accumulation of 8-OHdG in the livers of patients with chronic hepatitis C and HCV-related HCC (25, 26). However, it has not been known whether manipulating of ROS can reduce hepatic 8-OHdG levels and the risk of HCC development.

Recently, in an attempt to reduce hepatic iron, phlebotomy therapy has been introduced for the treatment of chronic hepatitis C, and serum ALT levels in most cases were indeed successfully lowered, whereas HCV titers were unchanged (27, 28). However, in these studies, phlebotomy treatment lasted for a maximum of 6 months, and therefore, the possible long-term effects of this approach on reduction of 8-OHdG, prevention of progression to cirrhosis, and lowering the risk of HCC, which is one of the ultimate aims of chronic hepatitis C treatment, have not been elucidated.

In the present study, therefore, chronic hepatitis C patients who were refractory for prior IFN therapy were treated with phlebotomy and a concomitant low iron diet for 6 years, and the following issues were addressed: (a) if there is indeed a correlation between HIC and hepatic 8-OHdG levels; (b) if hepatic 8-OHdG levels decrease as iron reduction therapy continues; (c) if there is any improvement of histological features of hepatitis after the therapy; and (d) if the therapy was preventive for HCC development. As it is well known that in an iron-deficient state, dietary iron absorption is highly augmented (29), the iron reduction modality of the present study was intentionally

Received 7/11/01; accepted 10/18/01.

The costs of publication of this article were defrayed in part by the payment of page charges. This article must therefore be hereby marked *advertisement* in accordance with 18 U.S.C. Section 1734 solely to indicate this fact.

¹ Supported by Grant-in-Aid 11670520 for Cancer Research from the Ministry of Education, Culture, Sports, Science and Technology, Japan.

² To whom requests for reprints should be addressed, at Fourth Department of Internal Medicine, Sapporo Medical University School of Medicine, South-1, West-16, Chuo-ku, Sapporo 060-8543, Japan. Phone: 81-11-611-2111; Fax: 81-11-612-7987; E-mail: niitsu@sapmed.ac.jp.

³ The abbreviations used are: ROS, reactive oxygen species; 8-OHdG, 8-hydroxy-2'-deoxyguanosine; HCV, hepatitis C virus; HCC, hepatocellular carcinoma; ALT, alanine transaminase; HIC, hepatic iron concentration; HAI, hepatitis activity index; dG, deoxyguanosine; TNF, tumor necrosis factor.

designed to consist of phlebotomy and a strict low-iron diet under the direction of a dietitian.

MATERIALS AND METHODS

HCV Patients and Therapy Protocol. This study was approved by the Human Ethics Committee of the Sapporo Medical University School of Medicine. Patients (45) with chronic hepatitis C, who were routinely visiting the Liver Unit of our department between January 1993 and December 1994, provided written informed consent for iron reduction therapy after having met the following criteria: (a) adult (≥ 20 years of age) with detectable anti-HCV antibodies and HCV-RNA; (b) those who had been treated previously with a standard 6-month IFN therapy (six MU IFN- α given daily for 2 weeks followed by three times weekly for 24 weeks) but had no sustained response; (c) those who showed persistent elevated serum ALT levels (≥ 80 IU/liter for >6 months) at least 1 year after IFN treatment; (d) those with histopathological evidence of chronic hepatitis without cirrhosis on liver biopsy; (e) those testing negative for antinuclear antibody, smooth muscle antibody, antimitochondrial antibody, or hepatitis B surface antigen; and (f) those with no habitual drug or alcohol use, anemia (hemoglobin < 11 grams/dl), or iron deficiency (baseline serum ferritin < 12 $\mu\text{g/liter}$ or transferrin saturation $< 15\%$).

However, 8 of these 44 HCV patients [5 men and 3 women; mean (\pm SD) age, 51.4 ± 9.1 years] subsequently declined to receive the treatments. The remaining 37 patients [20 men and 17 women; mean (\pm SD) age, 53.4 ± 12.1 years] were enrolled in the iron reduction study, but 3 of them prematurely withdrew because of a change of residence to a distant location (2 patients) or noncompliance (1 patient).

Therapeutic iron reduction for patients with chronic hepatitis C was carried out based on phlebotomy combined with regulation of dietary iron intake, as it is known that iron absorption increases reciprocally in an iron-deficient state (29). At the initial phase of iron depletion, all patients underwent weekly phlebotomy of 200 ml until a state of mild iron deficiency was achieved (defined by either < 10 $\mu\text{g/liter}$ serum ferritin and/or 11 grams/dl blood hemoglobin concentration). The mild iron deficiency state was maintained by additional phlebotomies during the study period; patients were followed up at regular intervals of ≥ 4 weeks for the duration, and a phlebotomy (200 ml) was performed if the hemoglobin level exceeded 11 grams/dl. In addition, all subjects were advised to reduce their intake of iron-rich foods during the intervention and instructed both p.o. and in writing by a registered dietitian (S. K.). To aid with compliance, each subject was given a comprehensive list of iron-rich foods, which they were to avoid, and instructions on how to complete dietary records, which required a listing of all food and drink consumed over a 3-day period once every 3 months throughout the intervention. The subjects were not required to alter their total caloric intake but were expected to replace their iron-rich foods with appropriate substitutes. All patients allocated to the low iron diets were instructed to reduce their consumption of beans, shellfish, green vegetables, meat, and seaweed and replace them with refined carbohydrates. Dietary energy (1900–2000 kcal/day), nutritional balance, and iron intake (5–7 mg/day) during study periods were assessed from the dietary records by using the nutrition analyzing software Win Kenkoukun-III (Hokenjyouhou Co, Chiba, Japan). We performed liver biopsies at the end of the initial iron reduction phase (5–16 weeks after commencing treatment) and at the end of treatment (after 6 years). For the surveillance of HCC, all subjects underwent ultrasound examination and/or computed tomography every 3–4 months during the study period.

Laboratory Tests. Complete blood cell counts, iron studies (serum iron, ferritin, and transferrin saturation), and biochemical examinations, including serum ALT, were determined using automated procedures in the clinical laboratories of Sapporo Medical University Hospital at every visit. Serum HCV-RNA level was determined by reverse transcriptase-PCR using a commercial kit (Amplicor HCV; Roche Diagnostics, Branchburg, NJ), and genotyping was performed on PCR products using a second-generation reverse hybridization, line-probe assay (Inno-LiPA HCV-II; Innogenetics, Zwijndrecht, Belgium).

Tissue Samples. Ultrasound-guided percutaneous needle liver biopsy was performed using Monopty needles (16-gauge, 22-mm length; C. R. Bard, Inc., Covington, GA). Each fresh biopsy specimen was divided into three portions: two small and one large (5, 5, and 12 mm, respectively). The large portion

(12-mm length) was formalin fixed, paraffin embedded, and subjected to histological evaluation and immunohistochemical analysis. The two small portions (5-mm length) of each specimen were used for determination of HIC and electrochemical detection of 8-OHdG. Similarly, from patients with HCC ($n = 21$) and metastatic liver cancer ($n = 8$) who had undergone surgical resection, HCC and histological normal liver specimens, which had been formalin fixed and paraffin embedded, were also subjected for immunohistochemical analysis of 8-OHdG.

Histopathological Grading. Formalin-fixed and paraffin-embedded liver tissue sections were subjected to histological evaluation by light microscopy, including staining by H&E. Each section was reviewed by two independent pathologists (T. I. and H. I.), who were unaware of the clinical outcome or sequence of the liver tissues, under blind fashion. Hepatic inflammation and fibrosis were scored based on Knodell's HAI (30).

HIC. HIC was determined by using atom-absorption spectrophotometry as described previously (24). The results are expressed as $\mu\text{g/gram}$ dry weight of liver tissue (normal range, 250–1100 $\mu\text{g/gram}$).

Immunohistochemical Determination of Hepatic 8-OHdG. Immunohistochemical analysis for formalin-fixed, paraffin-embedded tissue samples was performed using an avidin-biotin-peroxidase complex technique after microwave antigen retrieval as described previously (31). Sections (4 μm) were successively treated with blocking solution, 1 $\mu\text{g/ml}$ anti-8-OHdG monoclonal antibody (Nikken Foods Co., Fukuroi, Japan) or normal mouse IgG (DAKO, Glostrup, Denmark), biotinylated secondary antibody, and a peroxidase-avidin complex (ABC-kit; Vector Laboratories, Burlingame, CA). The intensity of 8-OHdG immunostaining in the sections was assessed by using an AxioCam photomicroscope and the KS-400 image analyzing system (Carl Zeiss Vision GmbH, Hallbermoos, Germany). A microscopic image of each liver section was imported into the KS-400, and brown-stained areas, which represented positively stained nuclei of hepatocytes corresponding to 8-OHdG immunoreactivity, were converted into a 255-graded gray scale. The average gray scale intensity of each sample was calculated by using the KS-400 image analyzing program and represented by the ratio to that of each sequential section immunostained by normal mouse IgG.

Electrochemical Measurements of Hepatic 8-OHdG Levels. The 8-OHdG levels in the liver DNA were determined by the method of Shimoda *et al.* (25). To prevent oxidation by air exposure, all solutions and instruments that came in contact with the tissue specimen were filled with argon gas. High molecular DNA was purified from each 5 mm of fresh liver biopsy specimen using a DNeasy Tissue Kit (Qiagen GmbH, Hilden, Germany). Each extracted DNA sample was treated with nuclease P1, alkaline phosphatase and filtrated through an Ultra Free Centrifugal Filter (Millipore Co., Bedford, MA), and ~ 10 μg of DNA were injected into the high performance liquid chromatograph (Shimadzu, Kyoto, Japan). The 8-OHdG in the digested DNA was detected by using an electrochemical detector (ECD-300; Eicom Co., Kyoto, Japan). The amount of dG was calculated from the absorbance at 290 nm, and the 8-OHdG levels were represented as the number of 8-OHdG per 10^5 dG in DNA (normal range, $0.8\text{--}3.1/10^5$ dG).

Statistical Analysis. Quantitative values are expressed as means \pm SD or median (range). Each data set was first evaluated for normality of distribution by the Kolmogorov-Smirnov test to decide whether a nonparametric rank-based analysis or a parametric analysis should be used. Two groups were compared by either the Wilcoxon signed-rank test or the Student *t* test. Multiple groups were compared by the rank-based, Kruskal-Wallis ANOVA test followed by Dunn's test for differences among groups or standard ANOVA followed by Dunn's test for multiple comparisons against a control group. The correlations between variables were examined by simple or multiple linear regression analysis or Spearman's coefficient of rank correlation test. *Ps* of < 0.05 were considered to indicate statistical significance.

RESULTS

Frequency of Phlebotomy and Amount of Daily Iron Intake in Therapy-completed Patients. All 34 patients who completed this therapy showed no serious complications except for slight thinning of the fingernails. The median number of phlebotomies required and the volume of blood removed to achieve the initial iron-deficient state were 11 times (range, 5–16 times) and 2.2 liters (range, 1–3.2 liters),

Table 1 Changes of iron-related parameters in patients with chronic hepatitis C before and after iron reduction therapy^a

Variable	Baseline (n = 34)	End point (n = 31)	Normal range in adults	P ^b
Hemoglobin (grams/dl)	13.9 ± 1.1	10.7 ± 0.1	11.1–16.9 ^c	<0.001
Serum iron (μg/dl)	160.3 ± 25.7	28.0 ± 9.4	60–140 ^c	<0.001
Serum ferritin (μg/liter)	258.9 ± 266.4	7.1 ± 4.7	18–250 ^c	<0.001
HIC (μg/gram liver)	1,159 ± 576 ^d	527 ± 279 ^d	250–1,100 ^e	0.02

^a Values represent mean ±SD or median (range).

^b Comparisons are between variables at baseline and variables at end point.

^c Reference normal range was listed.

^d HIC was determined in 22 liver samples in which paired tissues were available.

^e HIC in the normal liver was determined in eight liver samples.

respectively. During the maintenance phase, all patients required additional phlebotomies (median 0.6 times/month; range, 0.08–1) to maintain the low hepatic iron state as determined by serum ferritin and HIC; the mean ±SD HIC level significantly reduced from 1159 ± 576 to 527 ± 279 μg/gram liver ($P < 0.001$) during the 6-year treatment (Table 1). The median daily iron intake of 34 patients before treatment estimated from the dietary records was 11.9 mg/day (range, 9–16.3 mg/day), which was comparable with that of the typical Japanese diet (median 11.4 mg/day; range, 8.8–14.2 mg/day; Ref. 32). The median level kept by the 34 patients during the maintenance phase was 5.6 mg/day (range, 5–6.8 mg/day).

Depletion of Hepatic 8-OHdG Levels in Chronic Hepatitis C Patients by Iron Reduction Therapy. Applying two independent methods, immunohistochemical analysis and electrochemical detection, we assessed the change of hepatic 8-OHdG levels during iron reduction therapy. As shown in Fig. 1A, which represents the typical staining pattern of each specimen, positive nuclear staining was observed in most of the hepatocytes in pretherapy specimens and HCC specimens, whereas little staining was detected in specimens of either normal liver or of post-therapy, chronic hepatitis C. The specificity and intensity of the reaction were then assessed by computer-assisted quantitative analysis in all tested samples by comparing the average gray scale intensity of a positive sample to that obtained for the sequential section reacted with normal IgG. As shown in Fig. 1B, the median (range) of the relative staining levels in groups for chronic hepatitis 6.4 (2.6–10.8) before iron reduction treatment and HCC 6.4 (3.9–11) was significantly higher than the levels of normal liver (0.9; range, 0.3–1.9). After commencement of the iron reduction therapy, hepatic 8-OHdG levels started to decrease significantly in a rather short period of time (initial iron reduction phase) and almost completely normalized by the end of the therapy term (6 years later). On the contrary, hepatic 8-OHdG levels of those who declined the therapy remained elevated for 6 years; *i.e.*, they remained as high as the initial levels of those who underwent iron reduction therapy. Electrochemical detection carried out on liver specimens from patients having undergone the therapy disclosed a decrease of 8-OHdG levels; those of immunohistochemical analysis were clearly observed. There was a significant correlation ($R^2 = 0.687$, $P < 0.001$) between 8-OHdG levels measured by immunohistochemical staining and those by electrochemical detection.

Biochemical Parameters during Iron Reduction Therapy. Before treatment, serum ferritin, serum iron, and HIC were high in patients with chronic hepatitis C (Table 1). As expected, mean hemoglobin levels were significantly reduced, keeping between 11 and 10 grams/dl during the maintenance phase (Table 1 and Fig. 2). The mean ±SD values of serum iron and serum ferritin were also significantly decreased after the 6-year treatment ($P < 0.001$). At baseline, all patients had elevated serum ALT concentrations (150.8 ± 72.9 IU/liter; range, 62–353 IU/liter). The mean ±SD serum ALT levels significantly decreased ($P < 0.001$) after the initial iron reduction

phase. The levels further decreased, and by the end of the 6-year treatment, they were able to be maintained ($P < 0.001$; Table 2 and Fig. 2), being normalized (5–40 IU/liter) in 22 of the 34 patients (65%). In all patients, serum ALT levels had decreased to <60 IU/liter by the end of the treatment. However, serum HCV-RNA levels remained unchanged during the course of this study (Table 2). When the relationship between HIC and hepatic 8-OHdG levels was analyzed in these patients, a significant correlation ($R^2 = 0.567$, $P < 0.001$) was observed. A positive correlation was also evident in between serum ALT levels and hepatic 8-OHdG levels ($R^2 = 0.518$,

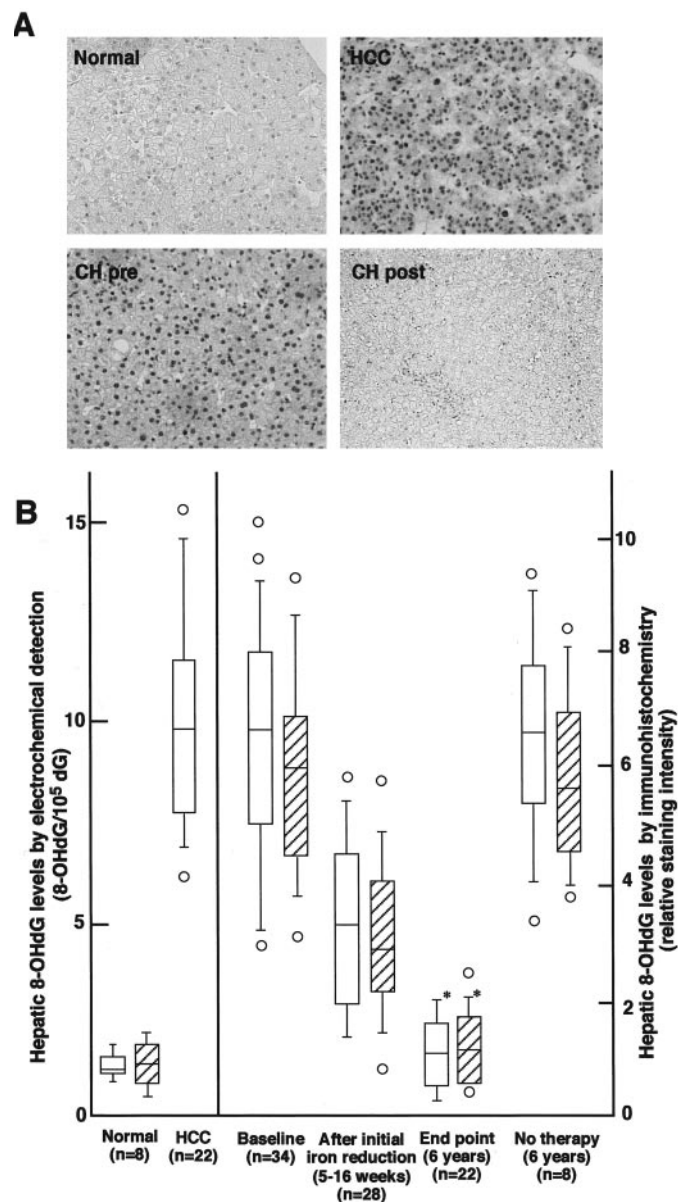


Fig. 1. Evaluation of hepatic 8-OHdG levels in chronic, hepatitis C patients who underwent iron reduction therapy. A, immunohistochemical staining of hepatic 8-OHdG in normal liver, HCC, and chronic hepatitis C before (CH pre) and after (CH post) iron reduction therapy. Paraffin-embedded liver sections were reacted with anti-8-OHdG monoclonal antibody, biotinylated secondary antibody, and a peroxidase-avidin complex as described in "Materials and Methods." B, changes of hepatic 8-OHdG levels associated with iron reduction therapy. Relative staining intensity of the hepatic 8-OHdG was quantified by computer-assisted image analysis (□). Hepatic 8-OHdG levels were also determined by an electric chemical detection method (hatched boxes) in normal livers and in chronic hepatitis C. The results are shown as Box plot profiles. The bottom and top edges of the boxes are the 25th and 75th percentiles, respectively. Median values are shown by the line within the box. Values outside top or bottom 95th percentiles are shown individually (○). * $P < 0.001$ versus the values at baseline.

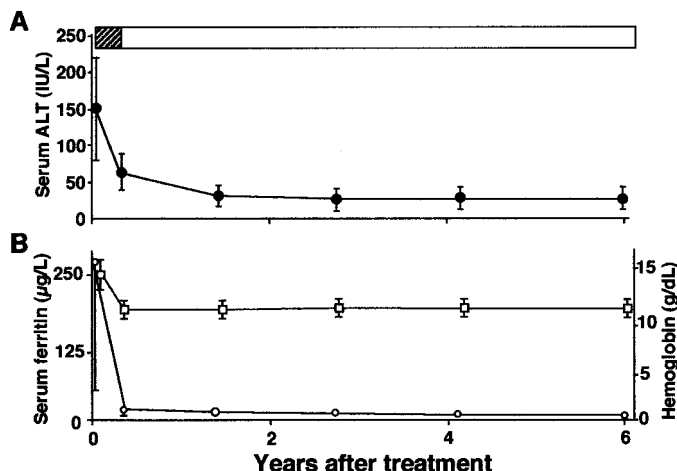


Fig. 2. Changes of the mean \pm SD of values for serum ALT (A, ●), serum ferritin (B, ○), and hemoglobin (B, □) concentrations associated with iron reduction therapy in patients with chronic hepatitis C. Hatched box and open box represent initial iron reduction phase and maintenance phase, respectively.

$P = 0.005$). In those who declined the therapy, serum ALT, serum iron, serum ferritin, and HIC were all elevated with the mean \pm SD values of 134.2 ± 93.1 IU/liter, 154.2 ± 48.3 μ g/dl, 241.8 ± 155.3 μ g/liter, and 1230 ± 622 μ g/gram liver, respectively, after a 6-year observation period.

Histopathological Change. In 28 patients in whom paired pre and posttreatment biopsies were available, total HAI score ($P = 0.01$), including necrosis, inflammation ($P = 0.03$), and fibrosis subscale scores ($P = 0.04$), showed appreciably significant improvements at the end of the treatment (Table 2). In 8 patients who declined the therapy, the HAI score (median 11.5; range, 6–15) after the 6-year observation period was clearly higher than that of postiron reduction therapy (Table 2). None of the 34 patients who received iron reduction therapy developed cirrhosis or HCC during the 6-year study, whereas of the 8 patients who declined the therapy, 2 patients developed cirrhosis, and 1 patient developed HCC.

DISCUSSION

In the present study, two independent methods, electrochemical detection and semiquantitative immunohistochemical analysis, were used for measuring 8-OHdG levels in liver specimens. With the electrochemical method, quantitative results could be obtained, but because the specimens were homogenized before applying to the high-performance liquid chromatography column, the values may not necessarily have represented those of hepatocytes. Therefore, we additionally performed immunohistochemical analysis to stain 8-OHdG specifically in the nuclei of hepatocytes and quantify the staining intensity by applying the KS-400 computer program to assure

the objectivity of determination. As a result, values obtained by both methods showed a reasonable correlation (Fig. 1), indicating the equal validity of both methods. In terms of practicality, however, the availability of formalin-fixed samples made immunostaining less laborious than the former method, which requires the use of fresh-frozen biopsy samples; therefore, mainly immunostaining was used.

Another practical concern in the present study was in developing an effective protocol to maintain low hepatic iron levels over an extended period of time. The protocol we adopted for iron depletion therapy was phlebotomy combined with a low iron diet. This protocol was well tolerated during the study course, with only 1 patient (3%) showing noncompliance, resulting in early withdrawal from this study. In addition to therapeutic phlebotomies, we advised the patients to reduce their daily iron intake to a maximum of 7 mg each, because it is known that iron absorption is significantly increased in an iron-deficient state (29). The daily iron intake levels were kept at 5.6 mg/day (range, 5–6.8 mg/day) during the intervention period. As a result, mean serum ferritin levels were kept low, and we were able to greatly reduce the mean number of phlebotomies in the maintenance phase.

Selection of patients was also an important issue to be addressed. As the priority treatment strategy for chronic hepatitis C at present is the administration of IFN or IFN/ribavirin (33, 34), we enrolled patients who had no appreciable response to 6 months of IFN therapy completed at least 6 months before being admitted to our therapy program. When we assessed the hepatic nonheme iron levels in these patients before beginning the therapy, we noticed that the mean value was significantly higher than that found in normal liver. The mechanism(s) underlying the elevation of hepatic iron in chronic hepatitis C patients is presently unclear. There is a possibility that the increment of hepatic iron in chronic hepatitis C is attributable to increased hepatocytolysis, release of ferritin, and subsequent uptake by reticuloendothelial cells or by hepatocytes (35). An alternative possibility is that inflammatory-related cytokines, including TNF- α induced by hepatic inflammation, which has been demonstrated to increase in the sera of patients with chronic hepatitis C (36), would stimulate iron uptake via up-regulation of transferrin receptor expression in hepatocytes as described previously (37). However, the possibility that there is a high incidence of genotype associated with genetic hemochromatosis, specifically *HFE* gene mutation (C282Y and H63D; Ref. 38), among patients with chronic hepatitis C (39) is not likely, at least in our study group, because none of the 28 subjects tested had these mutations (data not shown). Further investigation is needed for elucidation of the mechanism.

We then confirmed that the levels of 8-OHdG both in hepatitis specimens and HCC specimens were higher than those in normal liver, showing close correlation with the levels of nonheme iron in each corresponding specimen. Nevertheless, the close correlation between levels of 8-OHdG and hepatic nonheme iron does not necessarily assure the effectiveness of iron reduction therapy on depletion

Table 2 Changes of serum ALT, HCV-RNA levels, and HAI scores in patients with chronic hepatitis C patients before and after the iron repletion therapy^a

	Iron reduction therapy group (n = 34)			Control group (n = 8)		
	Baseline	End point	<i>P</i> ^b	Baseline	End point	<i>P</i> ^b
Serum ALT (IU/liter)	150.8 \pm 72.9	34.8 \pm 11.3	<0.001	142.2 \pm 98.7	134.2 \pm 93.1	0.56
HCV-RNA (kcopies/ml)	575.3 \pm 421.8	583.4 \pm 410.7	0.87	515.3 \pm 379.4	605.3 \pm 572.8	0.37
HAI scores						
Periportal/bridging fibrosis	2 (1–4)	1 (0–3)	0.005	2 (1–4)	3 (1–5)	0.04
Intralobular degeneration/necrosis	2 (1–3)	1 (0–3)	0.03	2 (1–4)	3 (1–4)	0.34
Portal inflammation	3 (1–4)	2.5 (0–4)	0.03	2 (1–3)	3 (2–3)	0.28
Fibrosis	3 (1–3)	2.5 (0–3)	0.04	3 (1–3)	3 (1–4)	0.048
Total	10 (3–14)	7 (0–12)	0.01	9 (4–13)	11.5 (6–15)	0.03

^a Values represent mean \pm SD or median (range).

^b Comparisons are between variables at baseline and variables of end point at 6 years.

of 8-OHdG; *i.e.*, 8-OHdG, once incorporated into DNA, may not be readily removed and substituted with guanine residue. However, our study clearly demonstrated that iron reduction therapy was indeed effective in bringing about substantial decrease of 8-OHdG in the initial phlebotomy phase (5–16 weeks), reducing it to almost a normal range by the end of 6 years of therapy with concomitant suppression of hepatic iron. Furthermore, it was also shown that not only the mean value, but also that for each and every individual patient examined, showed a significant decrease. The improvement of hepatic 8-OHdG levels over a relatively short period during the initial phlebotomy phase indicates that DNA is being repaired; *i.e.*, this particular base is being removed, in the absence of iron, namely ROS. In this regard, the recent discovery of enzymes which specifically repair 8-OHdG, such as 8-oxoguanine DNA glycosylase (40), supports our observation. As current medical ethics regulations in Japan do not generally allow long-term, therapy-free observation of chronic hepatitis C patients, control patients who did not undergo iron reduction therapy were not randomly examined in our study. However, from the 8 patients who had declined therapy, liver biopsy specimens obtained after 6 years of observation period were available, and the analysis of these specimens were considered to provide information equivalent to that of control patients. The 8-OHdG levels in these particular specimens were almost the same as those found in liver just before the iron depletion therapy, indicating that in liver not having undergone iron depletion therapy, hepatic 8-OHdG levels had essentially remained unchanged. In other words, depletion of 8-OHdG during the iron reduction therapy is a therapy-related phenomena and not an incidental phenomena occurring as part of the natural course of chronic hepatitis.

As has been reported previously, a decrease of serum ALT by iron reduction, which suggests both the cessation of ROS-induced damage of hepatocytes and their recovery from the damage, was also observed in our study. In chronic hepatitis C, hepatocellular damage may be initiated by various immunological reactions occurring on the cell surface, including the interaction of Fas on hepatocytes with the Fas ligand on cytotoxic T cells (41, 42) and TNF receptors on hepatocytes with TNF- α released from macrophages, etc., and subsequently substantiated by apoptotic signaling, which generates the most toxic type of ROS (\cdot OH) in the presence of ferrous iron (the Fenton reaction; Ref. 43). Iron depletion of hepatocytes may prevent the generation of toxic ROS, and it may interfere with apoptosis signaling.

In the present study, not only ALT but also histological improvements by iron depletion were observed, though the latter occurrence retarded the former. Periportal/bridging necrosis, and intralobular degradation/necrosis may be primarily ascribed to hepatocellular death caused by ROS. Furthermore, the induction of fibrosis by ROS through the stimulation of fibroblasts is a well-known phenomena (6, 44). Thus, the effect of iron depletion on histological features may be rationalized by the concomitant inhibition of ROS generation. Neither decrease of serum ALT levels nor histological improvement was observed in patients who declined the therapy, suggesting the notion that ALT elevation and histological derangement in chronic hepatitis C are ascribed to the effects of iron. The fact that HCV titers are unaffected by the iron reduction treatment suggests that in chronic HCV infection, this treatment interferes pathogenic process rather than with viral infection. Because ROS is commonly involved in ALT elevation, fibrosis, and 8-OHdG formation, which is a highly mutagenic factor, these empirical risk factors for HCC may be now theoretically rationalized. In other words, 8-OHdG is deemed to be a genuine risk factor. Therefore, reduction of 8-OHdG levels by iron depletion therapy was shown in this study to be one of the reasonable approaches for prevention of HCC. In fact, none of 34 patients who received the therapy developed HCC over the course of the 6 years, but 1 of the 8 patients who declined the therapy did. Although this

term may not be sufficiently long to draw definitive conclusions about the lowering risk of HCC, as there have been several reports showing 2.7–3.8% occurrence of HCC a year (16–23% in 6 years) among patients with chronic hepatitis C (20), 0% among our treated patients is noteworthy.

In conclusion, our results demonstrate that a close link exists between oxidative DNA damage, hepatocarcinogenesis, and hepatic iron overload in patients with chronic HCV infection. Iron reduction therapy is a safe and potentially promising means of treating patients with chronic hepatitis C and is associated with great improvements in histological responses and repair of oxidative DNA damage. Alternatively, other methods, such as administration of iron-chelating agents, might be applicable to reducing iron stores in individuals. Although the ultimate therapeutic goal is the eradication of all detectable HCV from the blood, even when more effective, less toxic approaches are developed, long-term iron reduction may be worthwhile as an adjunctive therapy.

ACKNOWLEDGMENTS

We thank Kevin S. Litton for editorial assistance of this manuscript, Dr. H. Iwaki for pathological review, E. Takagawa and T. Sasaki for technical assistance in processing the image analysis, and S. Kataoka for assessment of dietary records.

REFERENCES

- Hensley, K., Robinson, K. A., Gabbita, S. P., Salsman, S., and Floyd, R. A. Reactive oxygen species, cell signaling, and cell injury. *Free Radic. Biol. Med.*, 28: 1456–1462, 2000.
- Chapple, I. L. Reactive oxygen species and antioxidants in inflammatory diseases. *J. Clin. Periodontol.*, 24: 287–296, 1997.
- Halliwell, B., and Aruoma, O. I. DNA damage by oxygen-derived species. Its mechanism and measurement in mammalian systems. *FEBS Lett.*, 281: 9–19, 1991.
- Kappus, H. Oxidative stress in chemical toxicity. *Arch. Toxicol.*, 60: 144–149, 1987.
- Farber, J. L., Kyle, M. E., and Coleman, J. B. Mechanisms of cell injury by activated oxygen species. *Lab. Investig.*, 62: 670–679, 1990.
- Poli, G., and Parola, M. Oxidative damage and fibrogenesis. *Free Radic. Biol. Med.*, 22: 287–305, 1997.
- Kasai, H., and Nishimura, S. Hydroxylation of guanine in nucleosides and DNA at the C-8 position by heated glucose and oxygen radical-forming agents. *Environ. Health. Perspect.*, 67: 111–116, 1986.
- Shibutani, S., Takeshita, M., and Grollman, A. P. Insertion of specific bases during DNA synthesis past the oxidation-damaged base 8-oxodG. *Nature (Lond.)*, 349: 431–434, 1991.
- Cheng, K. C., Cahill, D. S., Kasai, H., Nishimura, S., and Loeb, L. A. 8-Hydroxyguanine, an abundant form of oxidative DNA damage, causes G-T and A-C substitutions. *J. Biol. Chem.*, 267: 166–172, 1992.
- Yamamoto, F., Kasai, H., Togashi, Y., Takeichi, N., Hori, T., and Nishimura, S. Elevated level of 8-hydroxydeoxyguanosine in DNA of liver, kidneys, and brain of Long-Evans Cinnamon rats. *Jpn. J. Cancer Res.*, 84: 508–511, 1993.
- Chen, X., Ding, Y. W., Yang, G., Bondoc, F., Lee, M. J., and Yang, C. S. Oxidative damage in an esophageal adenocarcinoma model with rats. *Carcinogenesis (Lond.)*, 21: 257–263, 2000.
- Kasai, H., Nishimura, S., Kurokawa, Y., and Hayashi, Y. Oral administration of the renal carcinogen, potassium bromate, specifically produces 8-hydroxydeoxyguanosine in rat target organ DNA. *Carcinogenesis (Lond.)*, 8: 1959–1961, 1987.
- Baik, S. C., Youn, H. S., Chung, M. H., Lee, W. K., Cho, M. J., Ko, G. H., Park, C. K., Kasai, H., and Rhee, K. H. Increased oxidative DNA damage in *Helicobacter pylori*-infected human gastric mucosa. *Cancer Res.*, 56: 1279–1282, 1996.
- Lih-Brody, L., Powell, S. R., Collier, K. P., Reddy, G. M., Cerchia, R., Kahn, E., Weissman, G. S., Katz, S., Floyd, R. A., McKinley, M. J., Fisher, S. E., and Mullin, G. E. Increased oxidative stress and decreased antioxidant defenses in mucosa of inflammatory bowel disease. *Dig. Dis. Sci.*, 41: 2078–2086, 1996.
- Romano, G., Sgambato, A., Mancini, R., Capelli, G., Giovagnoli, M. R., Flamini, G., Boninsegna, A., Vecchione, A., and Cittadini, A. 8-Hydroxy-2'-deoxyguanosine in cervical cells: correlation with grade of dysplasia and human papillomavirus infection. *Carcinogenesis (Lond.)*, 21: 1143–1147, 2000.
- Farinati, F., Cardin, R., Degan, P., Rugge, M., Mario, F. D., Bonvicini, P., and Naccarato, R. Oxidative DNA damage accumulation in gastric carcinogenesis. *Gut*, 42: 351–356, 1998.
- Floyd, R. The role of 8-hydroxyguanine in carcinogenesis. *Carcinogenesis (Lond.)*, 11: 1147–1150, 1990.
- Inoue, M., Osaki, T., Noguchi, M., Hirohashi, S., Yasumoto, K., and Kasai, H. Lung cancer patients have increased 8-hydroxydeoxyguanosine levels in peripheral lung tissue DNA. *Jpn. J. Cancer Res.*, 89: 691–695, 1998.

19. Di Bisceglie, A. M. Hepatitis C and hepatocellular carcinoma. *Hepatology*, 26(Suppl. 1): 34S–38S, 1997.
20. Seeff, L. B. Natural history of hepatitis C. *Hepatology*, 26 (Suppl. 1): 21S–25S, 1997.
21. Benvegnu, L., and Alberti, A. Risk factors and prevention of hepatocellular carcinoma in HCV infection. *Dig. Dis. Sci.*, 41 (Suppl.): 49S–55S, 1996.
22. Svegliati-Baroni, G., Saccomanno, S., van Goor, H., Jansen, P., Benedetti, A., and Moshage, H. Involvement of reactive oxygen species and nitric oxide radicals in activation, and proliferation of rat hepatic stellate cells. *Liver*, 21: 1–12, 2001.
23. Bonkovsky, H. L. Iron and the liver. *Am. J. Med. Sci.*, 301: 32–43, 1991.
24. Kato, J., Kobune, M., Kohgo, Y., Sugawara, N., Hisai, H., Nakamura, T., Sakamaki, S., Sawada, N., and Niitsu, Y. Hepatic iron deprivation prevents spontaneous development of fulminant hepatitis and liver cancer in Long-Evans Cinnamon rats. *J. Clin. Investig.*, 98: 923–929, 1996.
25. Shimoda, R., Nagashima, M., Sakamoto, M., Yamaguchi, N., Hirohashi, S., Yokota, J., and Kasai, H. Increased formation of oxidative DNA damage, 8-hydroxydeoxyguanosine, in human livers with chronic hepatitis. *Cancer Res.*, 54: 3171–3172, 1994.
26. Farinati, F., Cardin, R., Degan, P., De Maria, N., Floyd, R. A., Van Thiel, D. H., and Naccarato, R. Oxidative DNA damage in circulating leukocytes occurs as an early event in chronic HCV infection. *Free Radic. Biol. Med.*, 27: 1284–1291, 1999.
27. Hayashi, H., Takikawa, T., Nishimura, N., Yano, M., Isomura, T., and Sakamoto, N. Improvement of serum aminotransferase levels after phlebotomy in patients with chronic active hepatitis C and excess hepatic iron. *Am. J. Gastroenterol.*, 89: 986–988, 1994.
28. Piperno, A., Sampietro, M., D'Alba, R., Roffi, L., Fargion, S., Parma, S., Nicoli, C., Corbetta, N., Pozzi, M., Arosio, V., Boari, G., and Fiorelli, G. Iron stores, response to α -interferon therapy, and effects of iron depletion in chronic hepatitis C. *Liver*, 16: 248–254, 1996.
29. Nathanson, M. H., Muir, A., and McLaren, G. D. Iron absorption in normal and iron-deficient beagle dogs: mucosal iron kinetics. *Am. J. Physiol.*, 249: G439–G448, 1985.
30. Knodell, R. G., Ishak, K. G., Black, W. C., Chen, T. S., Craig, R., Kaplowitz, N., Kiernan, T. W., and Wollman, J. Formulation and application of a numerical scoring system for assessing histological activity in asymptomatic chronic active hepatitis. *Hepatology*, 1: 431–435, 1981.
31. Kato, J., Sakamaki, S., and Niitsu, Y. More on p53 antigen loss in stored paraffin slides. *N. Engl. J. Med.*, 333: 1501–1502, 1995.
32. Committee on Resources, Science Bureau of Japan, Standard tables of food composition in Japan, Ed. 5. Printing Office, Ministry of Finance, Tokyo, 1997.
33. McHutchison, J. G., Gordon, S. C., Schiff, E. R., Shiffman, M. L., Lee, W. M., Rustgi, V. K., Goodman, Z. D., Ling, M. H., Cort, S., and Albrecht, J. K. Interferon α -2b alone or in combination with ribavirin as initial treatment for chronic hepatitis C. Hepatitis Interventional Therapy Group. *N. Engl. J. Med.*, 339: 1485–1492, 1998.
34. Lindsay, K. L. Therapy of hepatitis C: Overview. *Hepatology*, 26 (Suppl. 1): 71S–77S, 1997.
35. Bonkovsky, H. L., Banner, B. F., and Rothman, A. L. Iron and chronic viral hepatitis. *Hepatology*, 25: 759–768, 1997.
36. Kaplanski, G., Farnarier, C., Payan, M. J., Bongrand, P., and Durand, J. M. Increased levels of soluble adhesion molecules in the serum of patients with hepatitis C. Correlation with cytokine concentrations and liver inflammation and fibrosis. *Dig. Dis. Sci.*, 42: 2277–2284, 1997.
37. Hirayama, M., Kohgo, Y., Kondo, H., Shintani, N., Fujikawa, K., Sasaki, K., Kato, J., and Niitsu, Y. Regulation of iron metabolism in HepG2 cells: a possible role for cytokines in the hepatic deposition of iron. *Hepatology*, 18: 874–880, 1993.
38. Feder, J. N., Gnirke, A., Thomas, W., Tsuchihashi, Z., Ruddy, D. A., Basava, A., Dormishian, F., Domingo, R., Jr., Ellis, M. C., Fullan, A., *et al.* A novel MHC class I-like gene is mutated in patients with hereditary haemochromatosis. *Nat. Genet.*, 13: 399–408, 1996.
39. Smith, B. C., Gorge, J., Guzail, M. A., Day, C. P., Daly, A. K., Burt, A. D., and Bassendine, M. F. Heterozygosity for hereditary hemochromatosis is associated with more fibrosis in chronic hepatitis C. *Hepatology*, 27: 1695–1699, 1998.
40. Rosenquist, T. A., Zharkov, D. O., and Grollman, A. P. Cloning and characterization of a mammalian 8-oxoguanine DNA glycosylase. *Proc. Natl. Acad. Sci. USA*, 94: 7429–7434, 1997.
41. Hiramatsu, N., Hayashi, N., Katayama, K., Mochizuki, K., Kawanishi, Y., Kasahara, A., Fusamoto, H., and Kamada, T. Immunohistochemical detection of Fas antigen in liver tissue of patients with chronic hepatitis C. *Hepatology*, 19: 1354–1359, 1994.
42. Ando, K., Hiroishi, K., Kaneko, T., Moriyama, T., Muto, Y., Kayagaki, N., Yagita, H., Okumura, K., and Imawari, M. Perforin, Fas/Fas ligand, and TNF- α pathways as specific and bystander killing mechanisms of hepatitis C virus-specific human CTL. *J. Immunol.*, 158: 5283–5291, 1997.
43. Liu, D., Liu, J., and Wen, J. Elevation of hydrogen peroxide after spinal cord injury detected by using the Fenton reaction. *Free Radic. Biol. Med.*, 27: 478–482, 1999.
44. Saccani, A., Saccani, S., Orlando, S., Sironi, M., Bernasconi, S., Ghezzi, P., Mantovani, A., and Sica, A. Redox regulation of chemokine receptor expression. *Proc. Natl. Acad. Sci. USA*, 97: 2761–2766, 2000.