

# Pancreatic Islet-Cell and Other Tumors in Rats Given Heliotrine, a Monoester Pyrrolizidine Alkaloid, and Nicotinamide

R. Schoental

Department of Pathology, Royal Veterinary College, Royal College Street, London, NW1 England

## SUMMARY

Three rats of six males, surviving 22 to 27.5 months after one or two intragastric doses of the monoester pyrrolizidine alkaloid, heliotrine (230 mg/kg body weight), and pretreatment with nicotinamide (350 mg/kg body weight) by i.p. injections, developed pancreatic islet-cell tumors, accompanied in one of the rats by transitory cell papillomas of the urinary bladder and interstitial testicular tumors and in another by a hepatoma. The lesions in the livers showed progression from megalocytosis, to microscopic hepatocellular hyperplasia, to increasingly larger nodules and hepatoma.

One rat, given heliotrine but no nicotinamide, also developed adenoma of the pancreatic islet cells.

Adenomas of the pituitary were present among the experimental and also among the control rats killed between 19 and 27.5 months after the beginning of the experiment, and they are not likely to have been caused by the alkaloid.

Heliotrine, in which the crucial double bond in the pyrrolizidine moiety is sterically hindered, appears to be less readily sequestered by the liver and also to affect other organs. Alkylation of nicotinamide at the N-1 position prevents its being reused for coenzyme biosynthesis. Hence, pretreatment of rats with large doses of nicotinamide prevents the depletion of nicotinamide adenine dinucleotide coenzymes and liver necrosis in rats given heliotrine (230 mg/kg body weight).

## INTRODUCTION

Many plant species, growing as weeds, contain alkaloids that are esters of 1,2-dehydropyrrolizidines and are hepatotoxic and carcinogenic (7, 10, 15-20, 23). These alkaloids include the cyclic diesters of retronecine and its *N*-oxide (e.g., retrorsine, isatidine, monocrotaline, etc.) and the open diesters of heliotridine (lasiocarpine, etc.) and its monoesters (heliotrine, etc.) (18).

Pyrrolizidine alkaloids can also induce tumors in other organs besides the liver. Pancreatic islet cell tumors have been reported in rats given alkaloidal extracts of *Amsinckia intermedia* Fisch and Mey or of *Heliotropium supinum* L., plant species that contain open ester pyrrolizidine alkaloids (19). These uncommon pancreatic islet-cell tumors ap-

peared to deserve further studies, especially in the light of the reported striking increase of the incidence of pancreatic islet-cell tumors in rats given streptozotocin (a carcinogenic, secondary metabolite of *Streptomyces achromogens*) when the animals were pretreated with nicotinamide (11). This paper deals with the long-term effects of heliotrine in rats pretreated with nicotinamide, some of which developed pancreatic islet-cell tumors.

## MATERIALS AND METHODS

White male weanling rats, 45 to 50 g body weight, were used. These were derived from the Porton-Wistar strain by random breeding at the Medical Research Council Laboratory Animal Centre, Carshalton, Surrey, England. Crystalline heliotrine (Chart 1), m.p. 128° (from acetone) [isolated from *Heliotropium ramosissimum* (Lehm)] (*Heliotropium persicum*), was used. The alkaloid was dissolved in water with the aid of equimolecular amounts of dilute hydrochloric acid and administered by stomach tube; the concentration of the solution was adjusted so that the volume given did not exceed 0.5 ml/rat. Nicotinamide, (a commercial crystalline preparation) was dissolved in distilled water, 70 or 100 mg/ml, and given by i.p. injection. The rats were kept in plastic or metal cages not exceeding 6/cage and were given pelleted food (Dixon's diet for laboratory research animals) and water *ad libitum*. Animals killed when appearing moribund and those that died were autopsied; their main organs and any grossly abnormal tissues were fixed in alcoholic formaldehyde and processed in the usual way. Sections cut 5 to 6  $\mu$ m were routinely stained with hematoxylin and eosin. Other stains were used when required.

Thirty-four rats were used in these experiments. Four rats were given heliotrine, 300 mg/kg body weight. A 2nd similar dose was given, after 3 weeks, to 2 surviving rats. Six rats were given heliotrine, 300 mg/kg body weight, preceded 10 to 15 min earlier by i.p. injection of nicotinamide, 500 mg/kg body weight. A 2nd dose of nicotinamide, 500 mg/kg, was given 2.5 hr after heliotrine. This treatment with heliotrine and nicotinamide was repeated after 3 weeks. Four rats were given heliotrine, 230 mg/kg body weight, by stomach tube; 2 died within 3 days. The surviving 2 rats were given a 2nd dose of heliotrine 5 days after the 1st dose. Twelve rats were given heliotrine, 230 mg/kg body weight, by stomach tube 10 to 15 min after administration of

Received January 6, 1975; accepted April 1, 1975.

nicotinamide, 350 mg/kg body weight by i.p. injection. A 2nd dose of nicotinamide, 350 mg/kg body weight, was given i.p. 2.5 hr after heliotrine. Six of these rats were given a similar 2nd treatment with heliotrine and nicotinamide 5 days after the 1st dosage. Two rats were given only the nicotinamide treatment comprising 4 i.p. doses, 350 mg/kg body weight, each at the time of treatment of the rats in the last group. Six rats were kept as untreated controls.

**RESULTS AND DISCUSSION**

All the rats in Groups A and B that were given the higher dose of heliotrine, 300 mg/kg body weight, died within 5 months after the alkaloid. Regardless of whether or not they were pretreated with nicotinamide, the lesions found in the livers and other organs of these rats resembled the lesions seen in rats dying at comparable times after various other hepatotoxic pyrrolizidine alkaloids (20). These rats did not survive long enough to develop tumors.

In the 2nd set of experiments, in which the dose of heliotrine was reduced to 230 mg/kg body weight, some of the animals survived longer. Their treatments, survival times, and the main lesions found at death are summarized in Table I.

Of the 4 rats given only heliotrine (Group C), only 1 survived 27 months after the alkaloid and it developed in

the pancreas an islet-cell tumor about 5 mm in diameter (Figs. 1 and 2), which contained in parts many thin-walled blood vessels and hemorrhagic cysts (Fig. 3). The rat also had an adenoma of the pituitary.

Of the 12 rats pretreated with nicotinamide and given 1 or 2 doses of heliotrine, 230 mg/kg body weight, 4 died or were killed when moribund within 5.5 months after the 1st dose, due to liver and other lesions characteristic for rats that die at comparable times after the pyrrolizidine alkaloids. Two rats were killed when 1 developed a very large (51-g) s.c. fibrosarcoma and the other developed inflammation of the upper jaw caused by greatly deformed incisor teeth.

Only six rats survived 22 months or longer after the treatment; among these, 3 had pancreatic islet-cell tumors, accompanied in a rat that had multiple islet-cell adenomas

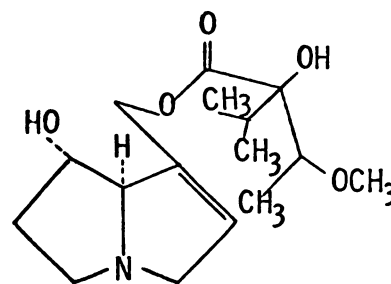


Chart 1. Heliotrine.

Table I  
Survival and main lesions found in male rats given heliotrine (230 mg/kg body weight, intragastrically) with or without nicotinamide or only nicotinamide (350 mg/kg body weight, i.p.)

Rat	Treatment		Survival (mo.)	Death	Pancreatic islet-cell tumors	Main gross lesions
	No. of heliotrine doses	No. of nicotinamide doses				
1	1		0.1	D <sup>a</sup>		Liver hard, necrotic; pleural effusions.
2	1		0.1	K		Liver hard, necrotic; pleural effusions.
3	2		1.7	D		Liver small, rubbery; lung congested.
4	2 <sup>b</sup>		27	K	+	Pituitary enlarged.
1	2	+	1.3	D		Liver small, rubbery.
2	2	+	1.3	D		Liver small, decomposed.
3	1	+	3.5	K		Liver nodular; ascites.
4	1	+	5.5	K		Liver nodular; ascites.
5	2	+	10	K		s.c. sarcoma; liver nodular.
6	2	+	13	K		Incisor teeth deformed; swelling of upper jaw, infection, and inflammation of brain.
7	1	+	22	K	+	Coma, liver nodular.
8	1	+	24	K	+	Bladder papillomas; interstitial testicular tumor.
9	2	+	25	K		Liver nodular; prostate hyperplasia and inflammation.
10	1	+	26	D		Liver large, nodular; decomposed.
11	2	+	26	K		Liver nodular; pituitary hemorrhagic
12	1	+	27.5	K	+	Liver large, nodular, hepatoma; ascites
1		+	21.5	K		Pituitary enlarged.
2		+	27	K		No abnormalities.

<sup>a</sup> D, dead; K, killed.

<sup>b</sup> Part of the 1st dose spilled.

(Fig. 4) by liver hepatoma, and in another by transitional cell papillomas in the bladder (Figs. 5 and 6) and interstitial testicular tumors. The livers of the rats in Group D showed progression with time of the liver lesions from microscopic megalocytosis and nodular hyperplasia to increasingly larger hyperplastic nodules and hepatoma.

Among the control rats killed between 19 and 27.5 months, 3 had adenomas of the pituitary (2 among the 6 untreated rats and 1 of 2 given nicotinamide only), but no other abnormalities.

The finding of pancreatic islet-cell tumors in 3 of 6 rats that survived 22 to 27.5 months after treatment with heliotrine and nicotinamide appears to be significant. Such tumors are exceedingly rare among Wistar-derived rats. Only 23 have been found among 1032 rats at the Unilever Research Laboratories (approximately a 2% incidence). I am indebted to Dr. M. Gellatly of these laboratories, Colworthy House, Sharnbrook, Bedford, England, for having allowed me to quote his findings. Pancreatic islet-cell tumors are also rare in other strains of rodents, but their incidence increases after irradiation or after treatment with certain chemical carcinogens (for references see Ref. 12). Holtzman male rats given a single dose of streptozotocin had a 4% incidence of pancreatic islet cell tumors; the incidence of these tumors increased to 64% when the rats were pretreated with nicotinamide (11), which prevented the depletion of NAD coenzymes, necrosis of the pancreatic islet cells (6, 13, 14), and the diabetogenic but not the antitumor action of streptozotocin (14).

Nicotinamide is known to prevent the depression of liver NAD coenzymes in rats treated with heliotrine (1, 2), carbon tetrachloride (4, 5, 21), and certain other hepatotoxins (13, 21) and also of their necrotizing action.

Although the survival of rats given heliotrine in doses exceeding 300 mg/kg was not affected by nicotinamide (2), the latter prevented liver necrosis after 230 mg/kg body weight in these experiments (Table I). As pointed out by Slater (21), decrease of NAD coenzymes in liver homogenates can imply their total deprivation in the areas that become necrotic. Deprived of NAD coenzymes, essential for more than 50 vital biochemical reactions, cells must die (17). The depletion of NAD coenzymes may be due to alkylation of nicotinamide at the ring nitrogen by alkylating moieties formed in the liver from the parent hepatotoxins (17). Increased excretion of *N*-1-methylnicotinamide and of *N*-1-methyl-2-pyridonecarboxamide followed the treatment of rats with methylmethane sulfonate (3). These metabolites of nicotinamide were radioactive when [*methyl*-<sup>14</sup>C]methane sulfonate was used (3). *N*-1 Alkylated nicotinamide can no longer be used for NAD biosynthesis. The requirements of nicotinamide as vitamin would obviously increase due to its loss by additional abnormal alkylation; the amounts formed from degradation of tryptophan represent a small fraction of the requirements even under normal conditions.

Alkylation of ring nitrogen in nicotinamide has been suggested to be responsible for the antitumor action of certain ethyleneimine compounds (8).

In the case of heliotrine, the alkylating moiety might be

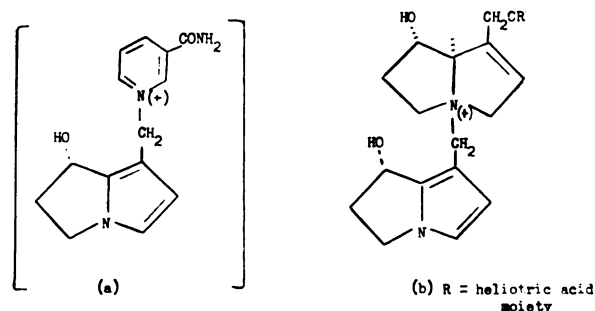


Chart 2. Structures of a putative product of nicotinamide (a) and of an *in vitro* metabolite of heliotrine (b).

dehydroheliotridine, if one could judge by analogy (Chart 2). The tertiary compound *N*-[6,7-dihydro-7 $\alpha$ -hydroxy-1-(5*H*-pyrrolizino)]methylheliotrine chloride (Chart 2B) is formed from heliotrine *in vitro* by rat liver microsomal preparations (9). Other possible metabolites of heliotrine cannot be excluded; attention has been drawn to forms epoxidized at the 1,2-double bond of the pyrrolizidine moiety (16, 18). Heliotrine, in which the 1,2-double bond is less accessible than in the cyclic diester pyrrolizidine alkaloids (22), is approximately 6 to 8 times less hepatotoxic than fulvine or retrorsine. Being less readily sequestered by the liver heliotrine can affect other organs, such as the pancreas and even the bladder. Which of the metabolites are responsible for the carcinogenic action of pyrrolizidine alkaloids (1) has not yet been verified experimentally.

## ACKNOWLEDGMENTS

I am indebted to Professor E. Cotchin for hospitality in his Department and for the evaluation of some of the lesions, and to the Medical Research Council Laboratory Animals Centre for gift of the rats. I thank F. A. Shephard and R. F. Legg for the photomicrographs, J. Rodney and R. Edgar for excellent care of the animals, and N. P. Brewster for valuable secretarial help. I am indebted to Dr. S. N. Salem, Kuwait, for supplies of *H. persicum*.

## REFERENCES

- Christie, G. S., and Le Page, R. N. Liver Damage in Acute Heliotrine Poisoning. 1. The Intracellular Distribution of Pyridine Nucleotides. *Biochem. J.*, **84**: 25-38, 1962.
- Christie, G. S., and Le Page, R. N. Liver Damage in Acute Heliotrine Poisoning. 2. The Effect of Nicotinamide on Pyridine Nucleotide Concentrations. *Biochem. J.*, **84**: 202-212, 1962.
- Chu, B. C. F., and Lawley, P. D. Increased Urinary Excretion of Pyrimidine and Nicotinamide Derivatives in Rats Treated with Methyl Methane Sulphonate. *Chem.-Biol. Interactions*, **8**: 65-73, 1974.
- Gallagher, C. H., and Simmonds, R. A. Prophylaxis of Poisoning by Carbon Tetrachloride. *Nature*, **184**: 1407, 1959.
- Gibb, J. W., and Brody, T. M. The Protective Effect of Nicotinamide on Carbon Tetrachloride Induced Hepatotoxicity. *Biochem. Pharmacol.*, **16**: 2047-2049, 1967.
- Gunnarsson, R., Berne, C., and Hellerström, C. Cytotoxic Effects of Streptozotocin and *N*-Nitrosomethylurea on the Pancreatic  $\beta$  Cells with Special Regard to the Role of Nicotinamide-adenine Dinucleotide. *Biochem. J.*, **140**: 487-494, 1974.
- Harris, P. N., and Chen, K. K. Development of Hepatic Tumors in Rats following Ingestion of *Senecio longilobus*. *Cancer Res.*, **30**:

- 2881-2886, 1970.
8. Holzer, H., Duntze, W., and Frank, S. Zum Carcinostatischen Wirkungsmechanismus von Äthylenimin-Verbindungen: Alkylierung von Nicotinsäureamid am Pyridin-Stockstoff. *Angew. Chem.*, *70*: 746, 1958.
  9. Jago, M. V., Edgar, J. A., Smith, L. W., and Culvenor, C. C. J. Metabolic Conversion of Heliotridine Based Pyrrolizidine Alkaloids to Dehydroheliotridine. *Mol. Pharmacol.*, *6*: 402-406, 1970.
  10. Newberne, P. M., and Rogers, A. E. Nutrition, Monocrotaline and Aflatoxin B<sub>1</sub> in Liver Carcinogenesis. *Plant Foods Man*, *1*: 23-31, 1973.
  11. Rakieten, N., Gordon, B. S., Beatty, A., Cooney, D. A., Davis, R. D., and Schein, P. S. Pancreatic Islet Cell Tumors Produced by the Combined Action of Streptozotocin and Nicotinamide. *Proc. Soc. Exptl. Biol. Med.*, *137*: 280-283, 1971.
  12. Rowlatt, U. F. Pancreatic Neoplasms of Rats and Mice. *In*: E. Cotchin and F. J. C. Roe (eds.), *Pathology of Laboratory Rats and Mice*, pp. 85-101. Oxford: Blackwell Scientific Publications, 1967.
  13. Schein, P. S. 1-Methyl-1-Nitrosourea and Dialkylnitrosamine Depression of Nicotinamide Adenine Dinucleotide. *Cancer Res.*, *29*: 1226-1232, 1969.
  14. Schein, P. S., Cooney, D. A., and Vernon, M. L. The Use of Nicotinamide to Modify the Toxicity of Streptozotocin Diabetes without Loss of Antitumor Activity. *Cancer Res.*, *27*: 2324-2332, 1967.
  15. Schoental, R. Toxicology and Carcinogenic Action of Pyrrolizidine Alkaloids. *Cancer Res.*, *28*: 2237-2246, 1968.
  16. Schoental, R. Hepatotoxic Activity of Retrorsine, Senkirine and Hydroxysenkirine in Newborn Rats, and the Role of Epoxides in Carcinogenesis by Pyrrolizidine Alkaloids and Aflatoxins. *Nature*, *227*: 401-402, 1970.
  17. Schoental, R. Biochemical Basis of Liver Necrosis Caused by Pyrrolizidine Alkaloids and certain Other Hepatotoxins. *Biochem. Soc. Trans.*, *3*: 292-294, 1975.
  18. Schoental, R. Natural Carcinogens. *In*: C. E. Searle (ed.), *Chemical Carcinogens. Monograph of the American Chemical Society*, in press.
  19. Schoental, R., Fowler, M. E., and Coady, A. Islet Cell Tumors of the Pancreas Found in Rats Given Pyrrolizidine Alkaloids from *Amsinckia intermedia* Fisch and Mey and from *Heliotropium supinum* L. *Cancer Res.*, *30*: 2127-2131, 1970.
  20. Schoental, R., and Magee, P. N. Further Observations on the Subacute and Chronic Liver Changes in Rats after a Single Dose of Various Pyrrolizidine (*Senecio*) Alkaloids. *J. Pathol. Bacteriol.*, *78*: 471-482, 1959.
  21. Slater, T. F. Mechanism of Protection against Acute Liver Injury. *Biochem. Soc. Trans.*, *1*(4): 922-926, 1973.
  22. Sussman, J. L., and Wodak, S. J. The Crystal Structure of Fulvine: A Pyrrolizidine Alkaloid. *Acta Cryst.*, *29*: 2918-2926, 1973.
  23. Svoboda, D. J., and Reddy, J. K. Malignant Tumors in Rats Given Lasiocarpine. *Cancer Res.*, *32*: 908-912, 1972.

- 
- Fig. 1. Pancreatic islet-cell adenoma; white male rat killed 27 months after the 1st of 2 intragastric doses of heliotrine, 230 mg/kg body weight. H & E, × 12.5.
- Fig. 2. Higher magnification of the adenoma shown in Fig. 1. H & E, × 40.
- Fig. 3. Higher magnification of the top right area of the tumor in Fig. 1 showing hemorrhagic cysts and many thin-walled blood vessels. H & E, × 100.
- Fig. 4. Pancreatic islet-cell adenomas; white male rat killed 27.5 months after a single intragastric dose of heliotrine, 230 mg/kg body weight, and 2 i.p. doses of nicotinamide, 350 mg/kg body weight. This rat also had a hepatoma. H & E, × 12.5.
- Fig. 5. Urinary bladder with papillomas; white male rat killed 24 months after a single intragastric dose of heliotrine, 230 mg/kg body weight, and 2 i.p. doses of nicotinamide, 350 mg/kg body weight. This rat also had an islet-cell adenoma, similar to the one shown in Fig. 1, and interstitial cell testicular tumors. H & E, × 12.5.
- Fig. 6. Higher magnification of the transitional cell papillomas of the bladder shown in Fig. 5. H & E, × 100.

