

Electron Microscopy and Immunofluorescence of Glomerular Immune Complex Deposits in Cancer Patients¹

Robert R. Pascal,² Philip M. Iannaccone, Florence M. Rollwagen,³ Tatia A. Harding, and Sidney J. Bennett

Departments of Pathology [R. R. P., P. M. I.] and Surgery [S. J. B.], and Cancer Research Center [R. R. P., F. M. R., T. A. H., S. J. B.], Columbia University, College of Physicians and Surgeons, New York, New York 10032

SUMMARY

Kidneys of 29 patients without clinical renal disease were studied by electron microscopy for the presence of glomerular basement membrane deposits: those from 11 of 20 patients with cancers of various sites, but only 1 of 9 patients without cancer contained electron-dense subendothelial deposits. The majority of these kidneys gave positive immunofluorescent reactions for immunoglobulin and complement. However, among a number of the cases studied, a lack of correlation between electron microscopic and immunofluorescence findings has yet to be investigated. Although the number of patients in this study is small because of the difficulty in obtaining tissue for electron microscopy, it is postulated that the deposition of immune complexes in the kidney occurs with a high frequency among cancer patients. The kidneys may thus be a valuable source for isolating tumor-associated antigens and corresponding antibodies.

INTRODUCTION

Nephrotic syndrome among patients with cancer putatively related to the glomerular deposition of tumor-associated antigen-antibody complexes has been the subject of many case reports (2-7, 9-12, 14, 21, 22, 23). Most of these patients had lymphoreticular and hematopoietic cancers (5-8, 14, 21, 23), but nephrotic syndrome has also been encountered among patients with epithelial tumors (2-4, 10-12, 22).

The occurrence of subclinical glomerular immune complex deposits among animals and humans with neoplasms has been a subject of recent interest (1, 16-19, 24, 25). AKR leukemic mice have been shown to have immune complex deposits as well as C-type viral particles in their glomeruli by immunofluorescence and electron microscopy (1, 16-18). The GMB⁴ deposits in Paris R-III mice with localized mammary tumors contain mammary tumor virus-associated antigens, although no viral particles were found (19). Among humans, subclinical glomerular deposits were demon-

strated by immunofluorescence in 7 of 55 patients with Hodgkin's disease (25). In a similar study, GBM deposits were seen among 15 of 146 patients with leukemia or lymphoma, 2 of 124 patients with solid tumors, and 4 of 33 patients with no demonstrable tumor (24). In a preliminary study utilizing electron microscopy and immunofluorescence, glomerular immune complex deposits were found in about 50% of patients with a variety of malignant tumors (20).

In assessing the prevalence of immune complex deposits in man and animals, 2 difficulties present themselves. First, human renal tissue from patients without renal disease is mostly obtained at autopsy. One recent report of immune complexes in kidneys examined between 2 and 48 hr post-mortem notes that "background fluorescence increases, therefore making those positives considered absolute more difficult to obtain" (24). Second, the use of immunofluorescence as the sole criterion for the recognition of immune complex deposits may produce results that vary with the methods used. Normal laboratory mice were found to have little or no glomerular deposition of immunoglobulin using 1 filter system, whereas up to 95% of the same sections yielded positive fluorescence using another filter combination (13). In an attempt to circumvent both these handicaps, we decided to limit our investigation to those cases in which adequate tissue for electron microscopy could be obtained and to confirm positive findings with immunofluorescence. We felt that, although it resulted in a smaller sample than the aforementioned studies, electron microscopy offered a more precise way of identifying and locating GBM deposits. Most samples of kidney obtained within 6 hr postmortem were suitable for study by electron microscopy, *i.e.*, nuclear and cell membranes of endothelial and epithelial cells were intact, the trilamellar structure of the GBM was distinct, and there was no artifactual separation of endothelial cells from the basement membrane. Surgical specimens, when available, were also examined. In this pilot study of 29 cases the ultrastructural findings were compared with the immunofluorescence findings, and the prevalence of deposits among patients with and without cancer was evaluated.

MATERIALS AND METHODS

There were 29 cases included in the study. Portions of kidneys from 15 patients with cancers were obtained at postmortem examination within 6 hours of death and from 5 surgical specimens when nephrectomy or biopsy was performed for therapeutic or diagnostic reasons. Autopsy specimens were also obtained from 4 patients without cancer.

¹ Supported by Grant 1 RO-1-CA-16179-01A1 and Center Grant CA-13696-02 from the National Cancer Institute.

² Present address: Laboratory Service, Veterans Administration Hospital, University of South Florida, 13000 North 30th Street, Tampa, Fla. 33612. To whom requests for reprints should be addressed.

³ Present address: Sloan-Kettering Division, Graduate School of Medical Sciences, Cornell University School of Medicine, New York, N. Y. 10021.

⁴ The abbreviations used are: GBM, glomerular basement membrane; PBS, phosphate-buffer saline (Sorenson's 0.1 M).

Received April 1, 1975; accepted September 16, 1975.

Samples of each specimen were fixed in 2% glutaraldehyde and postfixed in 1% osmium tetroxide for electron microscopy (18). When available, renal cortex was snap-frozen in dry ice-methylbutane for cryostat sectioning for immunofluorescence. All remaining renal tissue was deep-frozen for future elution procedures. In addition, plastic-embedded renal biopsy specimens from 5 patients who underwent renal vascular surgery for mild hypertension were kindly supplied for electron microscopy by Dr. Conrad L. Pirani, Professor of Pathology, College of Physicians and Surgeons. None of these patients had a history or clinical evidence of cancer.

Patients who had significant renal disease by clinical and light microscopic examination were excluded from the study, as were patients with metastatic tumor in the kidney, a history of radiation to the renal area, or known septicemia. Included were 2 cases of renal cell carcinoma and 1 case with transitional cell carcinoma of the renal pelvis. In each of these, the tumor was under 4 cm in maximum dimension and not necrotic, and the renal tissue was taken as far as possible from the tumor. In these 3 specimens, the absence of compression, hemorrhage, or other direct effects of the tumor on the renal parenchyma was also confirmed by light microscopy.

One- μ m Araldite sections were examined by light microscopy to exclude the sampling of glomeruli involved by pyelonephritis, ischemic sclerosis, or malignant infiltrates. At least 4 glomeruli from each patient were examined by electron microscopy, but no attempt was made to quantitate the changes observed.

Twenty-two of the kidney specimens were also examined by the indirect immunofluorescent staining procedure for IgG, IgM, B-1-C, fibrinogen, and albumin. The goat antisera were obtained from Cappel Laboratories, Downingtown, Pa., and used at 1:10 dilution. Rabbit antiserum to goat IgG (Cappel Laboratories) was fluoresceinated (15) and used at 1:20 dilution. Each antiserum was tested for monospecificity by immunodiffusion. Nonimmune goat serum (Cappel Laboratories) was used as a control at 1:10 dilution in each case. After sectioning, slides were washed for 25 min in 5 changes of PBS at a pH of 7.4, fixed for 10 min in absolute acetone, washed for 20 min in 4 changes of PBS, and incubated for 30 min at room temperature with the antisera. After each incubation slides were washed for 20 min in 4 changes of PBS. The sections were examined with a Leitz Ortholux microscope equipped with an Osram HBO 220-watt mercury lamp and a BG 38 red-absorbing filter. A BG-12 + K530 filter combination was consistently used to examine and photograph each section.

RESULTS

Of the 29 specimens examined by electron microscopy, 12 showed deposits in the glomeruli. Table 1 shows the distribution of electron-dense deposits among cancer patients and the control group. All deposits were located subendothelially in the glomerular tufts (Figs. 1 and 2) and in the mesangial region (Fig. 3). No subepithelial deposits were seen. Fusion of foot processes was seen in affected glomeruli (Figs. 1 to 3).

Table 2 lists the age, diagnosis, and immunofluorescence findings among the patients with GBM deposits visualized by electron microscopy. Table 3 lists similar data for patients without electron-dense deposits. The average age of patients listed in Table 2 is 48 years and of those in Table 3 is 47 years.

When present, granular immunofluorescence was distributed among the capillary loops and mesangium. IgG was found more often than IgM, and the presence of immunoglobulin was associated with the presence of B-1-C in all but 1 case. Sections incubated with antialbumin showed fluorescence only among tubular casts. Sections incubated with nonimmune serum showed no fluorescence.

As shown, 2 specimens contained electron-dense deposits without demonstrable IgG, IgM, and B-1-C. Eight specimens without deposits showed some positive fluorescence for immunoglobulin.

The clinical records of all 29 patients were examined for evidence of functional renal disturbance, and, except for mild (+ to ++ by commercial reagent strips) and intermittent albuminuria, none was found. There was no correlation between proteinuria and presence or absence of deposits.

DISCUSSION

Over the past few years it has been shown that laboratory animals may have a humoral immune response to spontaneously occurring neoplasms as evidenced by the deposition of immune complexes in their kidneys (1, 16-19). In some cases, these complexes have been shown to contain antibodies that react with antigens of the virus associated with the tumor (16, 17). The presence of tumor-associated and virus-associated antigenic material in the renal deposits has also been demonstrated (16, 17, 19, 20).

That a similar immune response may occur in humans was suggested by sporadic reports of nephrotic syndrome associated with malignant neoplasms (2-7, 9-12, 14, 21, 22, 23). More recently, immune complexes have been demonstrated by immunofluorescence in the glomeruli of patients without clinically manifest renal disease (24, 25). By this method the prevalence of subclinical renal deposits in all types of cancer combined was about 8%. This figure was slightly higher (11 to 14%) among patients with leukemia (24). In this study, 11 of 20 patients with cancer and 1 of 9 without cancer had subendothelial electron-dense deposits in their glomeruli in the absence of clinical renal disease. The average age and age range of the patients with and without deposits were not significantly different. There was no correlation between renal deposits and proteinuria as

Table 1
Prevalence of electron-dense deposits in glomeruli of 29 patients with and without cancer

	Deposits	No deposits	Total
Cancer patients	11	9	20
No known cancer	1	8	9
Total	12	17	

Table 2
Diagnoses and immunofluorescence data of 12 patients with GBM deposits by electron microscopy

Code no.	Age	Diagnosis	IgG	IgM	B-1-C	Fibrino- gen	Albumin
100-001 (S) ^a	70	Carcinoma of prostate and bladder	+	+	+	++	0
100-015 (A)	15	Synovial sarcoma	0	++	0	++	0
100-030 (A)	60	Lymphosarcoma	+	++	+	++	0
100-056 (A)	61	Reticulum cell sarcoma	++	0	++	0	0
100-076 (A)	35	Nephrosclerosis	0	0	0	+	0
100-144 (S)	68	Carcinoma of renal pelvis	0	0	0	0	0
100-440 (A)	69	Reticulum cell sarcoma	+	0	+	0	0
100-743 (S)	44	Renal cell carcinoma	+	+	++	+	0
100-748 (A)	52	Carcinoma of colon	0	0	0	0	0
100-760 (A)	49	Hepatoma	+	+	++	0	0
101-030 (S)	17	Hodgkin's disease	+	0	+	0	0
13-E-71 (S)	34	Renal cell carcinoma	ND	ND	ND	ND	ND

^a (S), surgical specimen; (A), autopsy specimen; +, weak to moderate; ++, strong; 0, absent; ND, not done.

Table 3
Diagnoses and immunofluorescence data of 17 patients without GBM deposits by electron microscopy

Code No.	Age	Diagnosis	IgG	IgM	B-1-C	Fibrino- gen	Albumin
100-027 (A) ^a	42	Acute granulocytic leukemia	++	++	++	++	0
100-036 (A)	72	Myelofibrosis	+	0	+	0	0
100-083 (A)	30	Embryonal carcinoma of retroperitoneum	0	0	++	0	0
100-109 (A)	26	Embryonal carcinoma of testis	+	0	+	0	0
100-147 (A)	81	Chronic granulocytic leukemia	+	0	++	+	0
100-180 (A)	50	Carcinoma of lung	0	0	0	0	0
100-331 (A)	74	Carcinoma of breast	+	0	+	0	0
100-438 (A)	42	Acute promyelocytic leukemia	0	0	0	0	0
100-476 (A)	60	Carcinoma of colon	+	0	+	0	0
Autopsy (A) 24832	64	Waldenstrom's macroglobulinemia	ND	ND	ND	ND	ND
100-846 (A)	52	Reticulum cell sarcoma	0	0	+	0	0
101-231 (A)	41	Pancreatitis	++	+	++	+	0
73-K40 (S)	41	Hypertension	ND	ND	ND	ND	ND
73-K68 (S)	42	Hypertension	ND	ND	ND	ND	ND
74-K45 (S)	37	Hypertension	ND	ND	ND	ND	ND
74-K47 (S)	20	Hypertension	ND	ND	ND	ND	ND
74-K42 (S)	31	Hypertension	ND	ND	ND	ND	ND

^a For explanation of symbols, see Table 1.

measured during the patients' hospitalizations, but urinary protein had not been measured accurately or with the same frequency among all patients.

The subendothelial location of glomerular deposits among mice with neoplasms has been commented on previously (18, 19). Among humans with subclinical deposits, one previous report (24) and the present study have noted the high frequency of subendothelial localization. Immune complex deposits associated with nephrotic syndrome and cancer have been located subepithelially (4, 5, 10) or subendothelially (8, 9). Observations in this laboratory have shown the deposits associated with murine leukemia (18), mouse mammary tumor (19), and human cancer (20) to be exclusively subendothelial. We have no explanation for this at the present time. We have speculated that the location might be due to high-molecular-weight complexes (*i.e.*,

Class II complexes). Examination of eluates of some of these kidneys, currently in progress, have shown binding of the immunoglobulin fraction to autologous and certain heterologous tumor cells, but the antigen fraction is as yet uncharacterized.⁵

In this study, 2 of the kidneys with electron-dense GBM deposits contained neither IgG, nor IgM, nor B-1-C. Although we have not yet tested for other classes of immunoglobulins, it is possible that these 2 cases represent deposition of nonimmune macromolecules. Our current studies of eluates of such kidneys should help answer that question.⁵

A greater discrepancy can be seen in Table 3 where 9 of

⁵ S. J. Bennett, S. F. Slovin, J. Pfeiffer, and R. R. Pascal. Glomerular Immune Complex Deposits in Cancer Patients. Studies of Renal Eluates, in preparation.

11 kidneys tested showed some immunofluorescence in the absence of ultrastructurally demonstrable deposits. It was originally thought that nonspecific adherence of plasma proteins to glomerular capillary walls postmortem or during surgical devascularization could account for that phenomenon. The failure to detect albumin, except in tubular casts, is evidence against that hypothesis. The question of why these glomeruli gave positive immunofluorescence reactions remains unanswered thus far. Adhering to our major criterion of the ultrastructural visualization of deposits, we consider these cases "negative" until the studies of their eluates are completed.

We do not here purport to have ascertained the frequency of immune complex deposits among patients with cancer. The discrepancies between the electron microscopic and immunofluorescence data do not negate the following conclusion. A far greater proportion of cancer patients than previously expected have subclinical GBM deposits when studied by electron microscopy. Furthermore, those deposits usually consist of immune complexes containing antibodies directed against components of tumor cells (11, 12).⁵ This has already been shown to be true in experimental animals (Refs. 16 and 17; S. J. Bennett, S. F. Slovin, and R. R. Pascal. Demonstration of a Tumor Cell Reactive Antibody in Kidneys of Mice Bearing Mammary Tumors, in preparation). Further support of these conclusions must come from a larger number of cases with and without cancer studied by a combination of methods.

In summary we have formed the following hypotheses to be tested.

1. Deposition of immune complexes in renal glomeruli occurs in association with cancer among humans and experimental animals. The role of the humoral antibody response in the host reaction to cancer is not explained by these findings.

2. Renal deposits among cancer patients, although they may be present in a large proportion of a given population, infrequently result in clinical renal disease.

3. The frequency of renal deposits in humans with cancer will vary with sampling and with the methods used to detect them.

4. The subendothelial location of the deposits, regardless of the type of cancer, suggests some common feature of the antigen or complex involved, perhaps molecular size.

5. Kidneys of cancer patients are a potential source for the study of human tumor antigens and corresponding antibodies.

REFERENCES

1. Batzing, B. L., and Hanna, M. G., Jr. Localization of Endogenous C-type Virus in the Glomerular Basement Membrane of Aged AKR Mice. *J. Immunol.*, 110: 1189-1193, 1973.

2. Cantrell, E. G. Nephrotic Syndrome Cured by Removal of Gastric Carcinoma. *Brit. Med. J.*, 2: 739, 1969.
3. Costanza, M. E., Pinn, V., Schwartz, R. S., and Nathanson, L. Carcinoembryonic Antigen-Antibody Complexes in a Patient with Colonic Carcinoma and Nephrotic Syndrome. *New Engl. J. Med.*, 289: 520-522, 1973.
4. Couser, W. G., Wagonfeld, J. B., Spargo, B. H., and Lewis, E. J. Glomerular Deposition of Tumor Antigen in Membranous Nephropathy Associated with Colonic Carcinoma. *Am. J. Med.*, 57: 962-970, 1974.
5. Froom, D. W., Franklin, W. A., Hanno, J. E., and Potter, E. V. Immune Deposits in Hodgkin's Disease with Nephrotic Syndrome. *Arch. Pathol.*, 94: 547-553, 1972.
6. Ghosh, L., and Muehrcke, R. C. The Nephrotic Syndrome: A Prodrome to Lymphoma. *Ann. Internal Med.*, 72: 379-382, 1970.
7. Gupta, R. K. Immunohistochemical Study of Glomerular Lesions in Retroperitoneal Lymphomas. *Am. J. Pathol.*, 71: 427-436, 1973.
8. Hyman, L. Nephrotic Glomerular Disease Associated with Malignant Lymphomas. In: P. M. Burkholder (ed.), *Atlas of Human Glomerular Pathology*, pp. 363-365. Hagerstown, Md.: Harper & Row, 1974.
9. Hyman, L. R., Burkholder, P. M., Joo, P. A., and Segar, W. E. Malignant Lymphoma and Nephrotic Syndrome. A Clinicopathologic Analysis with Light, Immunofluorescence and Electron Microscopy of the Renal Lesions. *J. Pediat.*, 82: 207-213, 1973.
10. Lee, J. C., Yamaucki, H., and Hopper, J. The Association of Cancer and the Nephrotic Syndrome. *Ann. Internal Med.*, 64: 41-51, 1966.
11. Lewis, M. G., Loughridge, L. W., and Phillips, T. M. Immunological Studies in Nephrotic Syndrome Associated with Extrarenal Malignant Disease. *Lancet*, 2: 134-135, 1971.
12. Loughridge, L. W., and Lewis, M. G. Nephrotic Syndrome in Malignant Disease of Non-Renal Origin. *Lancet*, 1, 256-258, 1971.
13. Markham, R. V., Jr., Sutherland, J. C., and Mardiney, M. R., Jr. The Ubiquitous Occurrence of Immune Complex Localization in the Renal Glomeruli of Normal Mice. *Lab. Invest.*, 29: 111-120, 1973.
14. Muggia, E. M., and Uittmann, J. E. Glomerulonephritis or Nephrotic Syndrome in Malignant Lymphoma, Reticulum-Cell Type. *Lancet*, 1: 805, 1971.
15. Nairn, R. C. *Fluorescent Protein Tracing*, Ed. 3, pp. 303-307. Baltimore: The Williams & Wilkins Company, 1969.
16. Oldstone, M. B. A., Aoki, T., and Dixon, F. J. The Antibody Response of Mice to Murine Leukemia Virus in Spontaneous Infection: Absence of Classical Immunologic Tolerance. *Proc. Natl. Acad. Sci. U. S. A.*, 69: 134-138, 1972.
17. Oldstone, M. B. A., Tishon, A., Toniatti, G., and Dixon, F. J. Immune Complex Disease Associated with Spontaneous Murine Leukemia: Incidence and Pathogenesis of Glomerulonephritis. *Clin. Immunol. Immunopathol.*, 1: 6-14, 1972.
18. Pascal, R. R., Koss, M. N., and Kassel, R. L. Glomerulonephritis Associated with Immune Complex Deposits and Viral Particles in Spontaneous Murine Leukemia. An Electron Microscopic Study with Immunofluorescence. *Lab. Invest.*, 29: 159-165, 1973.
19. Pascal, R. R., Rollwagen, F. M., Harding, T. A., and Schiavone, W. A. Glomerular Immune Complex Deposits Associated with Mouse Mammary Tumor. *Cancer Res.*, 35: 302-304, 1975.
20. Pascal, R. R., Rollwagen, F. M., Koss, M. N. and Iannaccone, P. M. Glomerular Immune Complexes Associated with Cancer (Abstr.) *Lab. Invest.*, 32: 432, 1975.
21. Plager, J., and Stutzman, L. Acute Nephrotic Syndrome as a Manifestation of Active Hodgkin's Disease. Report of Four Cases and Review of the Literature. *Am. J. Med.*, 50: 56-66, 1971.
22. Richard, C., Dupont, E., Dupuis, F., Potvlieve, P., and Toussaint, C. Syndrome Nephrotique Associé au Cancer Bronchique. *J. Urol. Nephrol.*, 79: 745-748, 1973.
23. Sutherland, J. C., and Mardiney, M. R. Immune Complex Disease in the Kidneys of Lymphoma-Leukemia Patients: The Presence of an Oncornavirus-Related Antigen. *J. Natl. Cancer Inst.*, 50: 633-644, 1973.
24. Sutherland, J. C., Markham, R. V., Jr., and Mardiney, M. R., Jr. Subclinical Immune Complexes in the Glomeruli of Kidneys Postmortem. *Am. J. Med.*, 57: 536-541, 1974.
25. Sutherland, J. C., Markham, R. V., Jr., Ramsey, H. E., and Mardiney, M. R., Jr. Subclinical Immune Complex Nephritis in Patients with Hodgkin's Disease. *Cancer Res.*, 34: 1179-1181, 1974.

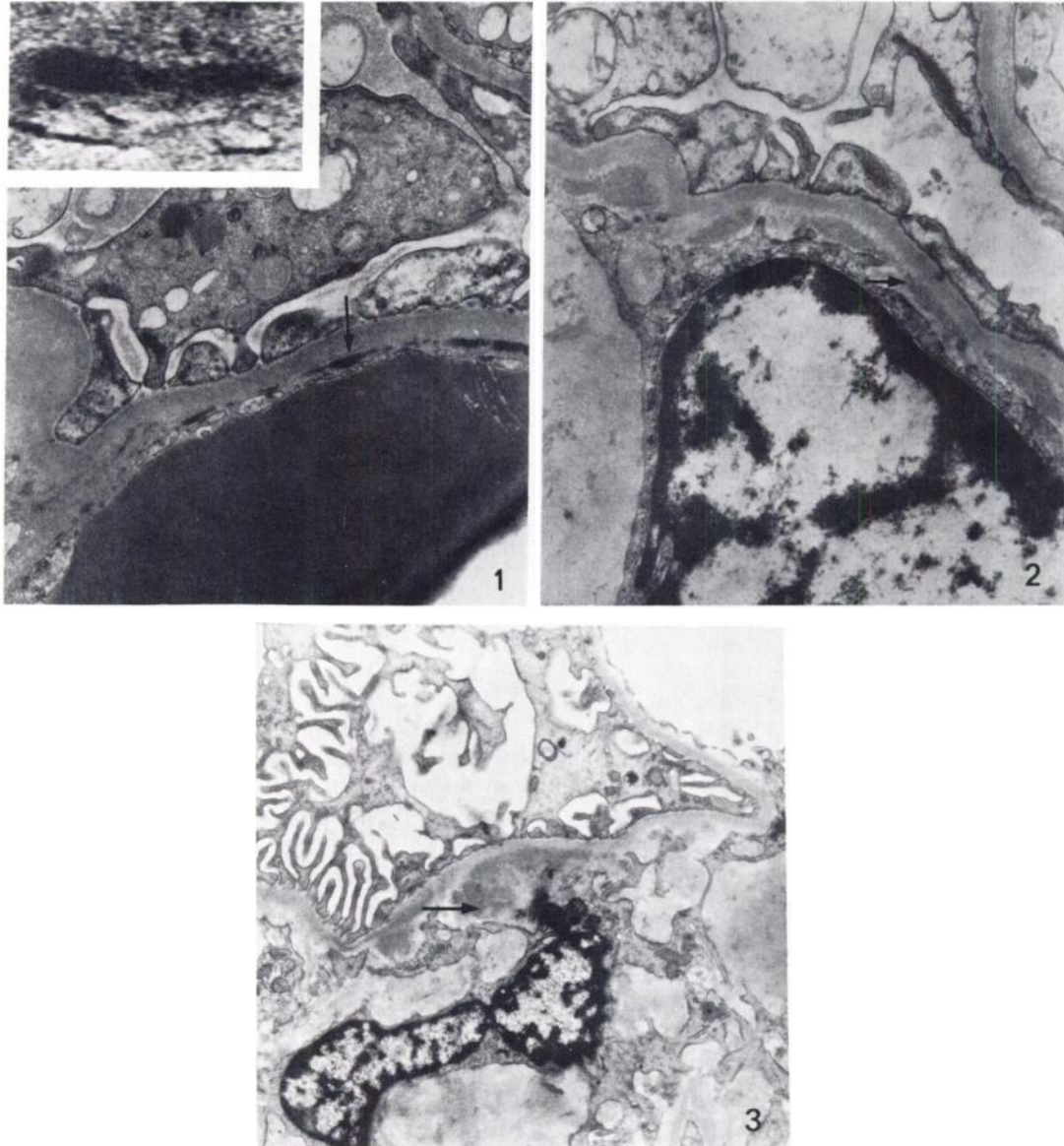


Fig. 1. Kidney from patient with synovial sarcoma (100-015). Several dense deposits (*arrow*) are situated on the endothelial side of the basement membrane. Mild fusion of foot processes is seen in this region. *Inset*, higher magnification of a deposit in this kidney. Fibrillar structures and periodicity associated with fibrin are absent. Lead citrate and uranyl acetate, $\times 13,000$. *Inset*, $\times 114,000$.

Fig. 2. Kidney from patient with lymphosarcoma (100-030). Prominent foot process fusion is seen overlying the subendothelial deposits (*arrow*). Lead citrate and uranyl acetate, $\times 13,000$.

Fig. 3. Kidney from patient with carcinoma of prostate and bladder (100-001). Deposits (*arrow*) are present in the region of a mesangial cell and mild fusion of foot processes is seen on the *right*. In more peripheral locations, subendothelial deposits were also present. Lead citrate and uranyl acetate, $\times 9,600$.