

Tumor Induction by a Single Subcutaneous Injection of Sterigmatocystin in Newborn Mice¹

Keiji Fujii,² Hiroshi Kurata, Shigeyoshi Odashima, and Yuichi Hatsuda

Department of Pathology, School of Medicine, University of Tsukuba, Ibaraki [K. F.], National Institute of Hygienic Sciences [H. K., S. O.], and Tottori University, Tottori [Y. H.], Japan.

SUMMARY

Sterigmatocystin, a mycotoxin produced by *Aspergillus versicolor*, *Aspergillus sydowi*, *Aspergillus nidulans*, and a species of *Bipolaris*, was given to newborn BALB/c × DBA/2 F₁ (hereafter referred to as CD2F₁) mice by a single s.c. administration in 1% gelatin suspension. In an acute toxicity study, the maximum tolerated dose of sterigmatocystin was 5 μg/g body weight. In a chronic study, a single s.c. injection of 5, 1, or 0.5 μg/g body weight gave rise to high incidences of lung and liver adenomas when the animals were killed at the end of 1 year. The incidence of both tumors in mice at the dose of 5 μg/g body weight was statistically significant, and the incidences of lung tumor in female mice and of liver tumor in male mice at the dose of 1 μg/g body weight were also statistically significant, compared with tumors in control mice. Other tumors also were induced in treated mice (two malignant lymphomas and one adenoma of the submaxillary gland), in contrast to a zero incidence in vehicle control mice. These results confirm that a small quantity of sterigmatocystin induces tumors of lung and liver and that the dose of sterigmatocystin is related to the incidence of tumors in mice.

INTRODUCTION

Sterigmatocystin, which consists of a xanthone nucleus attached to a bifuran structure, is a major toxic metabolite of *Aspergillus versicolor*, *Aspergillus sydowi*, *Aspergillus nidulans*, and an unidentified species of *Bipolaris* (3, 7). The structural similarity between sterigmatocystin and aflatoxins may suggest that the biological action of sterigmatocystin mimics that of aflatoxins. Sterigmatocystin was carcinogenic to rats by s.c. and p.o. administration and may also be 1 of the major mycotoxins to induce hepatoma in humans in South Africa (1, 5, 6).

The present studies were undertaken to investigate the tumorigenic effects of sterigmatocystin on CD2F₁ mice observed for 1 year after receiving a single s.c. administration on Day 1 of life.

MATERIALS AND METHODS

Materials. Sterigmatocystin (pale yellow needles, m.p. 244-245°) was isolated from the mycelia of *A. versicolor*

¹ A part of this investigation was supported by a Grant-in-Aid for Cancer Research from the Ministry of Welfare of Japan.

² To whom requests for reprints should be addressed, at Department of Pathology, School of Medicine, University of Tsukuba, Sakura, Niihari-gun, Ibaraki, Japan 300-31.

Received July 9, 1975; accepted December 29, 1975.

(Vuillemin) Tiraboschi and purified according to the method reported by Hatsuda and Kuyama (3). This compound was determined to be 99.9% pure by means of the analytical method (3) together with the X-ray structural analysis that was recently reported (4).

Gelatin was purchased from Difco Laboratories, Detroit, Mich. Gelatin (1%) in distilled water was autoclaved for 30 min, and sterigmatocystin was suspended in the gelatin solution at room temperature by magnetic stirring before use.

Animals. Pregnant BALB/c mice, mated with male DBA/2 mice, were supplied by Dr. K. Suzuki, Institute of Medical Science, University of Tokyo.

Animal Treatment. For determining the maximum tolerated dose of sterigmatocystin, 9 dams of CD2F₁ mice were arbitrarily separated according to the dose tested. A s.c. injection of 0.03 ml of 1% gelatin suspended with 100, 50, 5, 1, and 0.5 μg/g body weight of sterigmatocystin was given within 24 hr after birth. Infant mice were observed for 2 weeks for acute toxic effects. Most of the babies died within 5 days after treatment and all were cannibalized by their mothers.

In a chronic experiment, 224 newborn mice were divided according to litter into 4 groups, including a control group that received only the vehicle. Animals in Groups 1, 2, and 3 received a s.c. injection of 0.03 ml suspension containing 5, 1, or 0.5 μg/g body weight of sterigmatocystin, respectively, in the nape. Group 4, a vehicle control, received 0.03 ml of 1% gelatin solution. All animals were weaned at 1 month, segregated by sex, and housed in a plastic cage with sawdust bedding in groups of 5 or less animals from each litter. CE-2 pellet diet (CLEA Japan Inc., Tokyo, Japan) and water were given *ad libitum*. All animals were allowed to survive, with the exception of those sacrificed when moribund, until the experiment was terminated at 1 year, when the surviving mice were autopsied. The tissues were fixed in neutralized 10% formalin solution, sectioned at 3 μm, and stained routinely with hematoxylin and eosin. Special stains were used in a few instances.

RESULTS

Acute Toxicity Study. Thirty-nine progeny from 9 dams were available for evaluation of acute toxicity as shown in Table 1. Doses of 10 μg/g body weight and higher were acutely toxic, and all animals but 1 died of sterigmatocystin toxicity, while deaths from doses of 5 μg or less per g body weight were negligible. Thus, it was decided that 5 μg/g

body weight was the maximum tolerated dose for newborn CD2F₁ mice.

Chronic Study. Survival times and total tumor incidence are listed in Table 2. Newborn mice (224) from 32 dams were treated with the suspension of sterigmatocystin or the vehicle, and 92% of the treated mice were weaned at 1 month irrespective of the group. Most of the animals (95%) survived the 1-year duration of the experimental period.

Table 1
Acute toxicity in CD2F₁ mice given sterigmatocystin by s.c. injection on Day 1 of life

Dosage of sterigmatocystin (μg/g body wt)	No. of animals dead from toxicity/ no. of animals tested
100	5/5
50	5/5
10	4/4, 4/5
5	0/2, 3/4, 0/5
1	0/5
0.5	0/4

Treated animals showed an increase in total tumor incidence and a slight increase in number of tumors per tumor-bearing animal as compared with the controls. An apparent dose relation was found for the incidence of total tumors. The organ distribution of tumors is listed in Table 3.

Lung Tumors. The incidence of lung tumors in mice of Group 1 was higher (male, 33%; female, 27%) than that of other experimental groups (0 to 20%), and it corresponded with the multiplicity of tumors. Multiple lung tumors were recorded in 4 of 18 mice (22%) in Group 1 and in 1 of 5 mice (20%) in Group 2, whereas, a solitary tumor was found both in 1 mouse in Group 3 and in 1 control mouse. The incidence in Group 1 was statistically significant in comparison with that of control group (male, $\chi^2 = 2.89, p < 0.1$; female, $\chi^2 = 5.96, p < 0.02$), and that in Group 2 was partly significant (male, $\chi^2 = 0.50, p > 0.2$; female, $\chi^2 = 1.72, p < 0.2$). There was no significant incidence in Group 3 (male, $\chi^2 = 0.02, p > 0.90$; female, $\chi^2 = 0.53, p > 0.2$).

Macroscopically, most of the lung tumor nodules measured up to 2 mm in diameter and were located near the

Table 2
Survival time and tumor incidence in CD2F₁ mice given sterigmatocystin by s.c. injection on Day 1 of life
Animals were sacrificed 52 weeks after the start of the experiment.

Group	Dosage of sterigmatocystin (μg/g body wt)	No. of animals given injections	No. of litters	No. of survivors at weaning	Sex	No. of survivors at						Tumor-bearing animals		No. of tumors/animal	No. of tumors/tumor-bearing animal
						4 weeks	10 weeks	20 weeks	30 weeks	40 weeks	50 weeks	No.	% ^a		
1	5	62	8	60	M	27	27	27	27	24	23	14	52	0.89	1.7
					F	33	33	33	32	32	32	12	36		
2	1	38	6	37	M	15	14	14	14	14	14	7	47	0.53	1.1
					F	22	22	22	22	22	22	3	14		
3	0.5	77	11	74	M	40	40	40	40	38	36	10	25	0.40	1.6
					F	34	34	34	34	34	34	1	3		
4	Vehicle control	47	7	36	M	18	18	18	18	17	17	3	17	0.17	1.0
					F	18	18	18	18	18	18	0	0		

^a Percentage was calculated based on the number of tumor-bearing animals over the number of animals at weaning (4 weeks old).

Table 3
Organ distribution of tumors in tumor-bearing animals
Percentages are of number of animals at weaning.

Group	Sex	Lung tumors		Liver tumors		Lymphoma		Other tumors		Animals with lung and liver tumor
		No.	%	No.	%	No.	%	No.	%	
1	M	9	33	10	37	0		0		5
	F	9	27	3	9	1	3	0		1
2	M	3	20	4	27	1	7	0		1
	F	2	9	0		0		1 ^a	5	
3	M	4	10	6	15	0		0		
	F	1	3	0		0		0		
4	M	2	11	1	6	0		0		
	F	0		0		0		0		

^a Adenoma of the submaxillary gland.

surface of the lung. Microscopically, all but 1 had a papillary adenomatous pattern with slight cellular atypism and scarce mitotic figures, and adenomas sometimes protruded beyond the bronchi. One papillary adenocarcinoma occupied the entire median lobe, and tumor cells infiltrated into the pleural wall with fibrous adhesions.

Liver Tumors. The incidence of liver tumors in male mice treated with sterigmatocystin was 37% in Group 1; 15% incidence in Group 3 was higher than that in mice in the control group (6%). The incidence in Group 1 was statistically significant (male, $\chi^2 = 5.80, p < 0.02$; female, $\chi^2 = 1.74, p < 0.2$), and that of male mice in Group 2 was also statistically significant ($\chi^2 = 2.84, p < 0.1$) in comparison with that of control group. However, the incidence was not statistically significant in Group 3 males ($\chi^2 = 1.04, p > 0.2$). A dose relationship was also clearly demonstrated in the incidence of liver tumors in males. Males were more sensitive to the induction of liver tumors than were females.

Macroscopically, the liver tumors were either solitary or multiple; they were elevated, red to brownish-red nodules, and they measured up to 10 mm in diameter (Fig. 1). Dilated veins were seen on the surface of the nodules.

Microscopically, nodules had irregularly arranged cell cords with dilated sinusoids and were sharply demarcated from normal liver tissue. The cytoplasm of tumor cells frequently contained vacuoles and hyaline inclusion bodies. Mitotic figures were frequent. Metastatic foci were not observed. We classified these as hepatocellular adenomas (Fig. 2).

Other Tumors. Two malignant lymphomas and 1 adenoma of the submaxillary gland were found in 47 tumor-bearing animals treated with sterigmatocystin (Fig. 3).

DISCUSSION

This investigation demonstrated that a single s.c. injection of sterigmatocystin at 5, 1, or 0.5 $\mu\text{g/g}$ of body weight induced mainly tumors of the lung and liver in newborn mice. An appreciably higher number of lung and liver tumors was observed in those animals that received 5 $\mu\text{g/g}$ body weight of sterigmatocystin, and a dose relationship was found between the incidences of lung and liver tumor and the dose given to animals. The incidence of both tumors in mice at the dose of 5 $\mu\text{g/g}$ body weight was statistically significant in comparison with the incidence in control mice; at the dose of 1 $\mu\text{g/g}$ body weight, the incidences of lung tumor in females and of liver tumor in males were also statistically significant. There was a sex difference in the incidence of lung and liver tumor; males were more sensitive than were females to induction of these tumors. A

single s.c. injection of sterigmatocystin was tumorigenic in mice when administered on Day 1 of life. A single injection of the maximum tolerated dose (5 $\mu\text{g/g}$) was sufficient to induce tumors. Most of the animals were sacrificed at 52 weeks of age, at the termination of the experiment; only a few mice were autopsied before the termination of the experiment. This does not provide any information on the developmental aspects of these tumors. Time-sequence studies would clarify when the induction of tumor was begun or whether tumors would continue to grow progressively in animals surviving for more than 52 weeks.

A few studies have reported on the carcinogenic response of rats to sterigmatocystin. In 1 study, 0.5 mg of sterigmatocystin administered s.c. to rats induced local sarcomas, as well as liver tumors (1). In another study, 0.15 to 2.25 mg/day by gavage or in the diet for 52 weeks gave rise to high incidence of hepatocellular carcinoma (5). However, no reports were available for mice.

Biochemical studies have indicated that sterigmatocystin caused a nucleolar segregation in cultured monkey kidney epithelial cells and actively prevented the incorporation of [^3H]thymidine and [^3H]uridine indicative of DNA and RNA synthesis (2).

Further information on the cellular action of sterigmatocystin is needed in order to understand the carcinogenic effect to mammalian species.

ACKNOWLEDGMENTS

We thank Dr. Melvin D. Reuber, National Cancer Institute, for reading the manuscript.

REFERENCES

- Dickens, F., Jones, H. E. H., and Waynforth, H. B. Oral, Subcutaneous and Intratracheal Administration of Carcinogenic Lactones and Related Substances: The Intratracheal Administration of Cigarette Tar in the Rat. *Brit. J. Cancer*, **20**: 134-144, 1966.
- Engelbrecht, J. C., and Altenkirk, B. Comparison of Some Biological Effects of Sterigmatocystin and Aflatoxin Analogues on Primary Cell Cultures. *J. Natl. Cancer Inst.*, **48**: 1647-1655, 1972.
- Hatsuda, Y., and Kuyama, S. Studies on the Metabolic Products of *Aspergillus versicolor*. Part 1. Cultivation of *Aspergillus versicolor*, Isolation and Purification of Metabolic Products. *J. Agr. Chem. Soc. Japan*, **28**: 989-992, 1954.
- Fukuyama, K., Tsukihara, T., Katsube, Y., Tanaka, N., Hamasaki, T., and Hatsuda, Y. The Crystal and Molecular Structure of the *p*-Bromobenzoate of Sterigmatocystin. *Bull. Chem. Soc. Japan*, **48**: 1980-1983, 1975.
- Purchase, I. F. H., and Van der Watt, J. J. Carcinogenicity of Sterigmatocystin. *Food Cosmet. Toxicol.*, **8**: 289-295, 1970.
- Terao, K., Yamazaki, M., and Miyaki, T. Carcinoma by Administration of the Divided Dose of LD_{50} of Sterigmatocystin to Rat (in Japanese). *J. Food Hyg. Soc. Japan*, **14**: 272-273, 1973.
- Van der Watt, J. J. Sterigmatocystin. In: I. F. H. Purchase (ed.), *Mycotoxins*, pp. 369-382. Amsterdam: Elsevier Scientific Publishing Co., 1974.

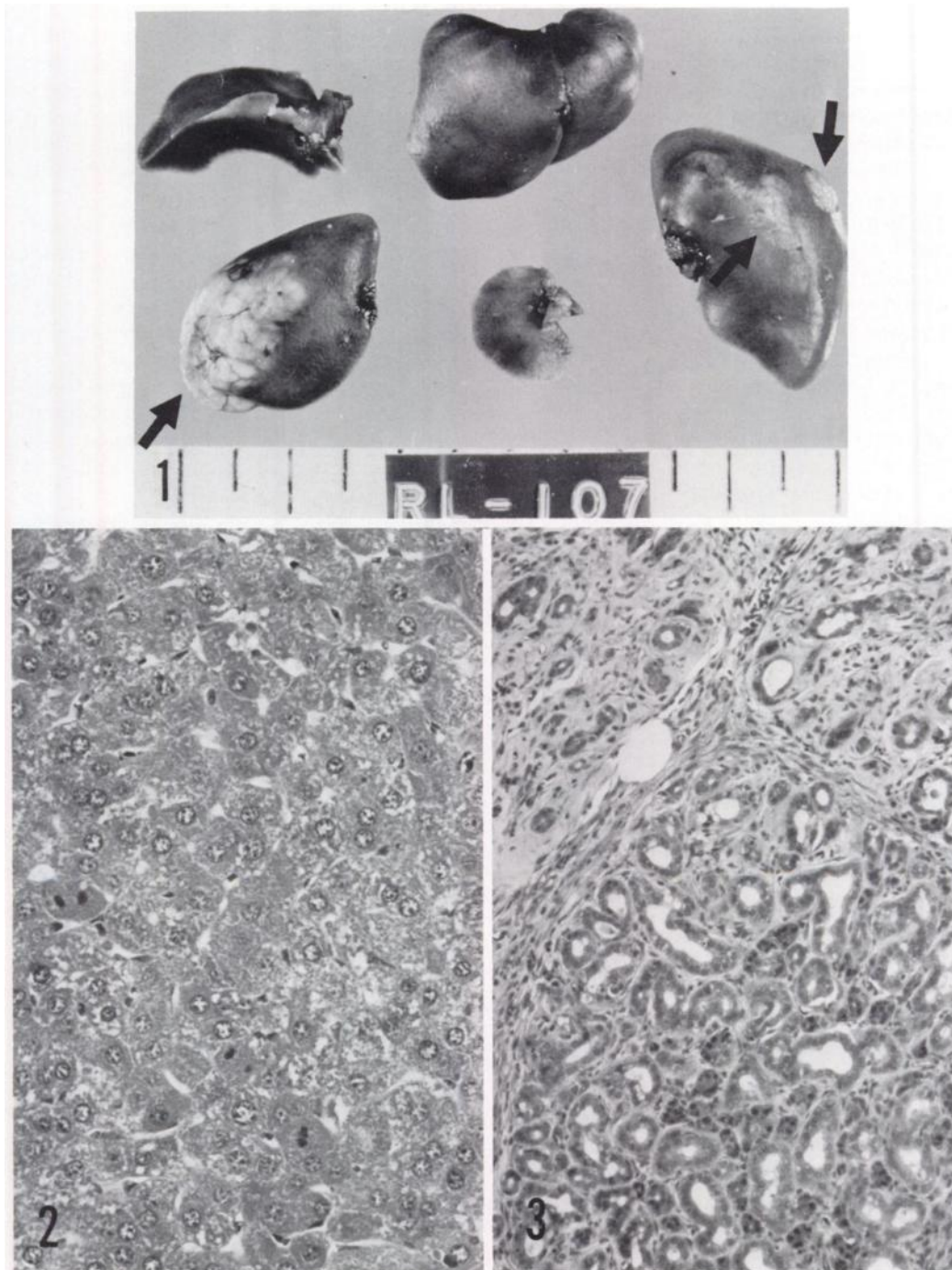


Fig. 1. Arrows, liver tumor in male mouse treated with 0.5 μg of sterigmatocystin suspended in 1% gelatin in animal sacrificed at 1 year.

Fig. 2. Hepatocellular adenoma with frequent mitotic figures 1 year after treatment of the animal with 5 μg of sterigmatocystin suspended in 1% gelatin. H & E, $\times 240$.

Fig. 3. Adenoma, consisting of a tubular configuration, of the submaxillary gland. The animal was treated with 5 μg of sterigmatocystin suspended in 1% gelatin. H & E, $\times 120$.