

Expression of *Ricinus communis* Receptors on Epithelial Cells in Oral Carcinomas and Oral Wounds

Erik Dabelsteen and Ian C. Mackenzie

Department of Oral Pathology, Royal Dental College, Copenhagen, Denmark [E. D.], and College of Dentistry, The University of Iowa, Iowa City, Iowa 52240 [I. C. M.]

ABSTRACT

The histological distribution of receptors for *Ricinus communis* Fraction 1 (RCA₁) in oral carcinomas and in oral epithelial cells during wound healing has been studied by use of fluorescein-tagged RCA₁. Biopsies from 15 human oral carcinomas and adjacent normal mucosa showed RCA₁ receptors at the cell membranes in the basal and spinous layer of the normal epithelium, whereas receptors could not be demonstrated in invading islands of the tumors. In healing oral wounds from eight humans and three monkeys, RCA₁ receptors were demonstrated both in normal epithelium adjacent to the wounds and in the epithelial outgrowth from the wound margin. Titrations, however, showed that the epithelial outgrowth reacted more weakly than did the normal adjacent epithelium. These results support previous *in vitro* studies showing changes in carbohydrate composition of moving normal cells and of malignant cells, a finding that may be of interest in relation to formation of metastases.

INTRODUCTION

Evidence from many studies points towards the cell surface as a major component in the regulation of various cellular activities. In particular variations in the structure and composition of cell surface glycoproteins and glycolipids have been associated with certain cell properties such as contact inhibition of movement, cell proliferation, intercellular linkages, and expression of antigens (1, 8, 10). Permanent defects in growth control and cell-to-cell interactions are characteristic features of neoplasia and may be reflected in changes in cell membrane structure and function (2, 9, 10, 24, 29).

We have previously examined changes in blood group antigens in wounded and malignant oral mucosa (5, 7), but a broader range of information about cell membrane carbohydrates can be obtained through the use of lectins which, when conjugated with fluorescein, act as stains with specific properties for certain saccharide moieties (3, 27). Two lectins have been obtained from *Ricinus communis*, and one of these RCA₁¹ (previously termed RCA₁₂₀) is a lectin that specifically binds to terminal β -D-galactopyranosyl residues (15, 21, 22). A relationship has been shown between RCA₁ binding sites and blood group antigens (17), and *in vitro* studies have demonstrated a cell contact-dependent increase in membrane-bound RCA₁ receptors on

normal but not virus- or spontaneously transformed fibroblasts (23). Because the presence of RCA₁ receptors thus seems, in some systems, to be dependent on states of cell mobility and malignant transformation, the distribution of RCA₁ receptors in histological sections of oral squamous cell carcinomas and the epithelium adjacent to oral wounds was investigated.

MATERIALS AND METHODS

Squamous Cell Carcinomas. The human material comprised 15 biopsies of the oral mucosa (from 8 males and 7 females) that had been diagnosed as squamous cell carcinomas by conventional histopathological criteria. The material was formalin fixed, embedded in paraffin wax, and cut as 5- μ m sections. Areas of histologically normal mucosa were present in all sections.

Human Wound Healing. Specimens were collected from 8 healthy male students. Standardized wounds were made with a 3-mm punch on the mucosa just inside the angle of the mouth. Forty-eight hr after wounding, another biopsy 4 mm in diameter was taken including the 2-day-old wound area and the surrounding wound margins. The tissue was fixed in 10% neutral formalin, embedded in paraffin wax, and cut as 5- μ m sections.

Monkey Wound Healing. Four rhesus monkeys were used as experimental animals. Standardized wounds were made: (a) in the attached gingiva midway between the gingival margin and the mucogingival junction; (b) in the palate 5 mm lateral to the level and the mandibular sulcus. The linear wounds were approximately 3 cm long and were made with 2 blades held in a hemostat and spaced by a distance of 1 mm. Biopsies of the wounds were taken at 6 hr, and 1, 2, 4, and 6 days after wounding. The tissue was fixed in 10% neutral formalin, embedded in paraffin wax, and cut as 5- μ m sections.

Staining for RCA₁ Receptors. RCA₁ receptors were demonstrated in the tissue sections by a 1-step fluorescent staining technique with FITC conjugated to RCA₁. The method of preparation of RCA₁, the conjugation procedure, and the staining methods have been described previously (6). In brief sections were dewaxed and brought to water, and *Ricinus* receptors in each tissue were demonstrated by incubation with lectin in a moist chamber for 40 min prior to 3 washes in PBS, pH 7.2. Sections were mounted in 10% glycerol-PBS, pH 7.2. Malignant and wounded human tissues were semiquantitated by a 2-fold titration (ranging from undiluted to 1:640) of the conjugated lectin.

Various tests of the specificity of the staining reactions were undertaken as described previously.⁶ These included a 0.9% NaCl solution control, staining with FITC dissolved

¹ The abbreviations used are: RCA₁, *Ricinus communis* Fraction 1; FITC, fluorescein isothiocyanate; WGA, wheat germ agglutinin; Con A, concanavalin A; PBS, phosphate-buffered saline (0.015 M sodium phosphate and 0.004 M potassium phosphate buffer, pH 7.2, containing 0.15 M NaCl).

Received March 6, 1978; accepted September 8, 1978.

in PBS (1 mg/ml diluted 1:10,000), inhibition studies with lactose, and α -methyl-D-glucopyranoside added to the dilutions of RCA₁ in a concentration of 0.15 M. As a test of access of conjugated lectin to the cell surfaces, a range of normal and wounded human and monkey tissue and malignant human tissue was stained with FITC-conjugated WGA and Con A (Miles-Yeda, Rehovoth, Israel) using the methods given previously.

RESULTS

Cells in the basal and spinous layers of the epithelium of normal mucosa in all specimens of both human and rhesus material showed a positive staining reaction with RCA₁, consisting of a bright green fluorescence in the region of the cell plasma membranes (Fig. 1).

Titration of human epithelium showed that the majority of cases stained with dilutions up to 1:160, but some higher and lower end-point titers were found (Tables 1 and 2).

The carcinomas showed a characteristic staining pattern, with positive fluorescent staining of epithelial cells in the superficial part of the tumor, and a lack of cell membrane staining, or only a very weak reactivity (Fig. 1), in the deep-invasive islands and strands of tumor cells. The positive-staining cells in the superficial parts of the tumor have the same end-point titer as does the surrounding normal epithelium. In 10 specimens there was a patchy distribution of positively reacting cells within the deeper parts of the carcinoma. Positive cells never appeared to form more than about 1 in 5 of the total malignant cell populations, and titrations showed an end-point titer for these cells that was lower than that found for normal epithelium (Table 1).

Keratin pearls, when they were present, stained positively but, unlike the cell membrane reactivity, this staining remained after inhibition with lactose.

In sections of the healing wounds of human mucosa (Fig. 2A), RCA₁ receptors were demonstrated both in the normal epithelium that was adjacent to the wounds and in the epithelial outgrowth from the wound margin. However, titrations showed that the leading edge of the epithelial outgrowth reacted with end-point titers 3 to 4 titer steps

Table 1
Range of end-point titers of FITC-conjugated RCA₁ staining normal and malignant human oral epithelial cells

Case	Normal epithelium	Carcinoma majority of invasive cells	Single cells
1	1:160	1:20	
2	1:160	0	1:20
3	1:160	0	1:20
4	1:160	0	1:160
5	1:320	0	1:40
6	1:320	0	1:20
7	1:320	0	1:10
8	1:320	0	1:10
9	1:320	0	0
10	1:40	0	0
11	1:80	0	1:10
12	1:320	0	1:5
13	1:80	0	0
14	1:320	0	1:5
15	1:80	0	0

Table 2
Range of end-point titers of FITC-conjugated RCA₁ staining specimens of normal and wounded human oral epithelium

Case	Normal epithelium	Moving epithelial cells
1	1:160	1:40
2	1:80	1:5
3	1:160	1:80
4	1:160	1:80
5	1:160	1:10
6	1:40	1:5
7	1:160	1:20
8	1:320	1:20

lower than did the rest of the epithelium (Table 2, Fig. 2, B and C).

Examination of sections of the healing wounds of rhesus oral mucosa showed an essentially similar pattern of staining for the wounds of each of the 3 types of mucosa examined. As in the human wounds, RCA₁ receptors were demonstrated both in the normal epithelium adjacent to the wounds and in the epithelial outgrowth from the wound margin, but titrations again showed that the epithelial outgrowth reacted much more weakly than did normal epithelium. Reduced RCA₁ binding of the epithelial cells lying within 100 to 200 μ m of the wound margin was observed as early as 6 hr after wounding. When epithelial contact was reestablished at the healing wound margins, as was apparent in some 4- and 6-day specimens, reactivity for RCA₁ receptors of the epithelial cells forming the edge of healing wounds was restored.

The inhibition studies with lactose showed no staining of any tissue at any of the concentrations used, but α -methyl-D-glucopyranoside did not block the reaction and had no effect on staining. FITC-conjugated Con A (6) and WGA stained the surfaces of epithelial cells from all areas and tissues examined, including the malignant cells.

DISCUSSION

The results of this study demonstrate that fluorescein-conjugated RCA₁ will bind to the surface region of basal and spinous cells of normal human and rhesus oral epithelium. Control reactions indicated that this binding was specific, and it therefore appears that oral epithelial cells have exposed surface components with terminal β -D-galactopyranosyl residues.

The amount of RCA₁ receptors in the tissue sections was semiquantitated by titration. Obviously, it is not easy to make valid semiquantitative judgments about RCA₁ receptors, based on the examination of sections in which cell size, shape, and intercellular relation vary. However, titration offers some information on the amount of exposed RCA₁ receptors in the tissue.

In both carcinomas and healing wounds, the normal pattern of RCA₁ binding was altered. Binding of RCA₁ to the cell surface could not be demonstrated for most invading malignant cells. Epithelial cells at the margin of healing wounds showed a decreased binding of RCA₁. These results are interpreted to indicate changes in the surfaces of *in vivo* epithelial cells. Such alterations may be similar to changes that have been examined more extensively *in vitro* by biochemical methods.

In vitro studies have shown that cell surface proteins possessing terminal galactose groups are present in confluent cultures of fibroblasts but are absent or reduced in nonconfluent cultures and in cultures of transformed cells (9, 10, 20, 21). The pattern of a reduced reaction for terminal β -D-galactopyranosyl residues on epithelial cells moving into a wound and on cells of downgrowths from carcinomas appears similar to the general patterns observed in these *in vitro* studies. Such findings would also agree with concepts of modulation of cell surface carbohydrates in association with cell movement and with previous studies of cell surface changes in oral mucosa that have shown a loss of blood group antigen activity in oral carcinomas and during wound healing (5, 7, 8, 18). The loss of RCA₁ reactivity within 6 hr and the observation of return of reactivity for RCA₁ when epithelial contact was reestablished and cell movement presumably ceased are of particular interest and are in keeping with previous studies of blood group antigens in healing wounds. It seems probable that loss of reaction for RCA₁ receptors on oral epithelial cells in both wounds and tumors may be an indication of an increased potential for cell mobility.

It could be postulated alternatively that loss of binding of RCA₁ is associated with reduced maturation of cells rather than with mobility. Both tumors and healing wounds, when compared to normal tissue, consist of a higher proportion of cells failing to show maturation. However, no such correlation between cell maturation and RCA₁ binding was observed in normal tissues where basal cells, which are immature cells, also showed binding of RCA₁.

Kim *et al.* (16, 17) have used biochemical methods to study cancerous tissue from the colon and have demonstrated in such lesions an increase in RCA₁ receptors, which is associated with a parallel decrease in blood group antigen A activity. To explain this change they postulated an enzyme defect that resulted in the production of incomplete oligosaccharide chains with terminal galactose moieties. Such chains were thought to correspond to a precursor stage in the formation of carbohydrates of the blood group antigens that would normally be present. Our previous studies with fluorescence microscopy have also shown that most oral carcinomas developing from an epithelium that normally shows activity for blood group antigen A have a decreased or absent activity for this antigen (7).

Our present findings taken together with the results of our previous studies (5, 7, 18) indicate that the binding for RCA₁ and antibodies to blood group antigen A are both decreased in oral carcinomas and wounded oral mucosa. These findings therefore appear to differ from Kim's findings of an inverse proportion between RCA₁ receptors and blood group antigen. This could represent a difference in behavior between oral and intestinal epithelia. Alternatively, differences between these studies in the methods used to examine changes could account for such a difference in findings. For example lack of binding of RCA₁ to histological sections could result from (a) absence of surface receptors due to their incomplete synthesis (10, 26), (b) from their proteolysis (2, 12-14, 25), or (c) masking of cell membrane receptors by other cell surface components (4, 28, 30). Histological methods might fail to indicate the

presence of RCA₁ binding sites that would be detected by biochemical methods following tissue dissociation. However, the positive WGA and Con A staining of sites failing to stain with RCA₁ indicates that tissue changes are not preventing access of other lectins to the cell surface. There is not therefore a generalized masking or proteolysis of all surface components. A substance such as sialic acid, which is often bound to galactose residues in glycoproteins (11), could block RCA₁ receptors in a semispecific fashion, and studies with neuraminidase that can "unmask" RCA₁ cell surface receptors would help to clarify this problem (4, 19, 28).

The results of this investigation do not permit firm conclusions regarding the mechanism leading to the observed loss of binding of RCA₁, and it is possible that different mechanisms were involved in the decreased expression of Ricinus receptors in wounds and in carcinomas. The decreased reactivity of RCA₁ receptors found in both wounds and carcinomas together with the presence of RCA₁ receptors on some tumor cells does not at present suggest a clear relationship between cancer and the binding of RCA₁. However, the finding of altered binding in these conditions indicates that histological methods can be used to examine cell surface changes and that such studies may assist in relating the findings of more rigorously controlled *in vitro* biochemical studies to the patterns of behavior of tissues *in vivo*. As these histological techniques are fairly simple to perform, it is also possible that further work on examining binding under various conditions, together with extension of such studies to include other conjugated lectins, may be of interest. Such studies could provide information not available from the usual methods of histological examinations and might be of clinical value in the diagnosis of incipient invasion.

REFERENCES

1. Abercrombie, M., and Ambrose, E. J. The Surface Properties of Cancer Cell: A Review. *Cancer Res.*, 22: 525-548, 1962.
2. Ali, I. U., Mautner, V., Lanza, R., and Hynes, R. O. Restoration of Normal Morphology, Adhesion and Cytoskeleton in Transformed Cells by Addition of a Transformation-Sensitive Surface Protein. *Cell*, 11: 115-126, 1973.
3. Cook, G. M. W., and Stoddart, R. W. Surface Carbohydrates of the Eukaryotic Cell, pp. 116-119. New York, Academic Press, Inc., 1973.
4. Currie, G. A., and Bagshawe, K. D. The Role of Sialic Acid in Antigenic Expression: Further Studies of the Landschütz Ascites Tumour. *Brit. J. Cancer*, 22: 843-853, 1968.
5. Dabelsteen, E., and Fejerskov, O. Loss of Epithelial Blood Group Antigen-A During Wound Healing in Oral Mucous Membrane. *Acta Pathol. Microbiol. Scand. A*, 82: 431-434, 1974.
6. Dabelsteen, E., Fejerskov, O., Norén, O., and Mackenzie, I. C. Concanavalin A and Ricinus Communis Receptor Sites in Normal Human Oral Mucosa. *J. Invest. Dermatol.*, 70: 11-15, 1978.
7. Dabelsteen, E., and Pindborg, J. J. Loss of Epithelial Blood Group Substance A in Oral Carcinomas. *Acta Pathol. Microbiol. Scand. A*, 87: 435-444, 1973.
8. Edelman, G. M. Surface Modulation in Cell Recognition and Cell Growth. *Science*, 192: 218-226, 1976.
9. Gahmberg, C. G., and Hakomori, S. Altered Growth Behavior of Malignant Cells Associated with Changes in Externally Labeled Glycoprotein and Glycolipid. *Proc. Natl. Acad. Sci. U. S. A.*, 70: 3329-3333, 1973.
10. Hakomori, S. Glycolipids of Tumor Cell Membrane. *Advan. Cancer Res.*, 18: pp. 265-315, 1973.
11. Hughes, R. C. Membrane Glycoproteins, p. 298. London: Butterworth & Co., 1976.
12. Hynes, R. O. Alteration of Cell-Surface Proteins by Viral Transformation and by Proteolysis. *Proc. Natl. Acad. Sci. U. S. A.*, 70: 3170-3174, 1973.
13. Hynes, R. O. Role of Surface Alterations in Cell Transformation: The Importance of Proteases and Surface Proteins. *Cell*, 1: 147-156, 1974.
14. Hynes, R. O., and Pearlstein, E. S. Investigations of the Possible Role of

- Proteases in Altering Surface Proteins of Virally Transformed Hamster Fibroblasts. *J. Supramol. Struct.*, **4**: 1-14, 1976.
15. Irimura, T., Kawaguchi, T., Terao, T., and Osawa, T. Carbohydrate-Binding Specificity of the So-Called Galactose-Specific Phytohemagglutinins. *Carbohydrate Res.*, **39**: 317-327, 1975.
 16. Kim, Y. S., and Isaacs, R. Glycoprotein Metabolism in Inflammatory and Neoplastic Diseases of the Human Colon. *Cancer Res.*, **35**: 2092-2097, 1975.
 17. Kim, Y. S., Isaacs, R., and Perdermo, I. M. Alterations of Membrane Glycopeptides in Human Colonic Adenocarcinoma. *Proc. Natl. Acad. Sci. U. S. A.*, **71**: 4869-4873, 1974.
 18. Mackenzie, I. C., Dabelsteen, E., and Zimmermann, K. The Relationship between Expression of Epithelial B-Like Blood Group Antigen, Cell Movement and Cell Proliferation. *Acta Pathol. Microbiol. Scand. A*, **85**: 45-56, 1973.
 19. Nicholson, G. L. Neuraminidase "Unmasking" and Failure of Trypsin to "Unmask" D-Galactose-Like Sites on Erythrocyte, Lymphoma, and Normal and Virus-Transformed Fibroblast Cell Membranes. *J. Natl. Cancer Inst.*, **50**: 1443-1451, 1973.
 20. Nicholson, G. L. Factors Influencing the Dynamic Display of Lectin Binding Sites on Normal and Transformed Cell Surfaces. *In*: B. Clarkson and R. Baserga (eds.), *Control of Cell Proliferation*, Vol. 1, Cold Spring Harbor Laboratory Conferences, pp. 251-270, 1974.
 21. Nicolson, G. L., and Blaustein, J. The Interaction of *Ricinus Communis* Agglutinin with Normal and Tumor Cell Surfaces. *Biochim. Biophys. Acta*, **266**: 543-547, 1972.
 22. Nicolson, G. L., Blaustein, J., and Etzler, M. E. Characterization of Two Plant Lectins from *Ricinus Communis* and Their Quantitative Interaction with a Murine Lymphoma. *Biochemistry* **13**: 196-204, 1974.
 23. Nicolson, G. L., and Lacorbiere, M. Cell Contract-Dependent Increase in Membrane β -D-Galactopyranosyl-Like Residues on Normal, but Not Virus- or Spontaneously-Transformed, Murine Fibroblasts. *Proc. Natl. Acad. Sci. U. S. A.*, **70**: 1672-1676, 1973.
 24. Poste, G., and Weiss, L. Some Considerations on Cell Surface Alterations in Malignancy. *In*: L. Weiss (ed.), *Fundamental Aspects of Metastasis*, Amsterdam: North-Holland Publishing Co., 1976.
 25. Rilber, M., and Romano, E. Transformation-Dependent Modifications in Released and Cell-Bound Surface Proteins Detected by Antisera to Shed Antigens. *Cancer Res.*, **36**: 3568-3573, 1976.
 26. Roth, S., and White, D. Intercellular Contact and Cell-Surface Galactosyltransferase Activity. *Proc. Natl. Acad. Sci.*, **69**: 485, 1972.
 27. Sharon, N., and Lis, H. Lectins: Cell-Agglutinating and Sugar-Specific Proteins. *Science*, **177**: 949-959, 1972.
 28. Simmons, R. L., and Rios, A. Cell Surface Modification in the Treatment of Experimental Cancer: Neuraminidase or Concanavalin A. *Cancer*, **34**: 1541-1547, 1974.
 29. Vahari, A., and Ruoslahti, E. Disappearance of a Major Celltype Specific Surface Glycoprotein Antigen (SF) after Transformation of Fibroblasts by Rous Sarcoma Virus. *Intern. J. Cancer*, **13**: 579-586, 1974.
 30. Van Beek, W. P., Smets, L. A., and Emmelot, P. Increase Sialic Acid Density in Surface Glycoprotein of Transformed and Malignant Cells—A General Phenomenon. *Cancer Res.*, **33**: 2913-2922, 1973.

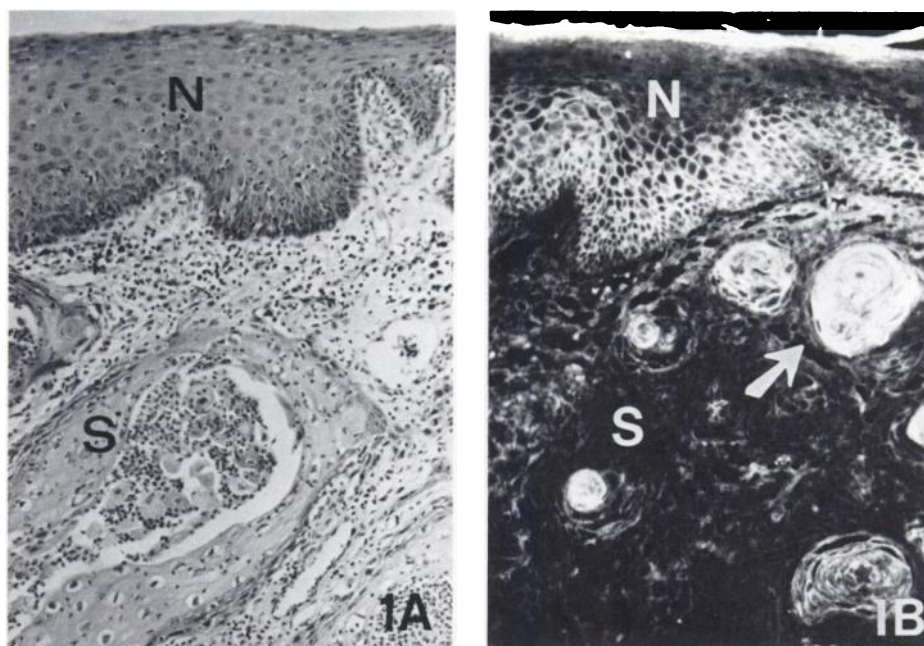


Fig. 1. Normal mucosa (N) and squamous cell carcinoma (S). A, H & E; B, *R. communis* staining at high concentration; arrows, keratin pearls in squamous cell carcinoma. Note in B that normal epithelial cells stain, whereas only keratin pearls stain in carcinoma even when high concentrations of RCA₁ are used. × 120.

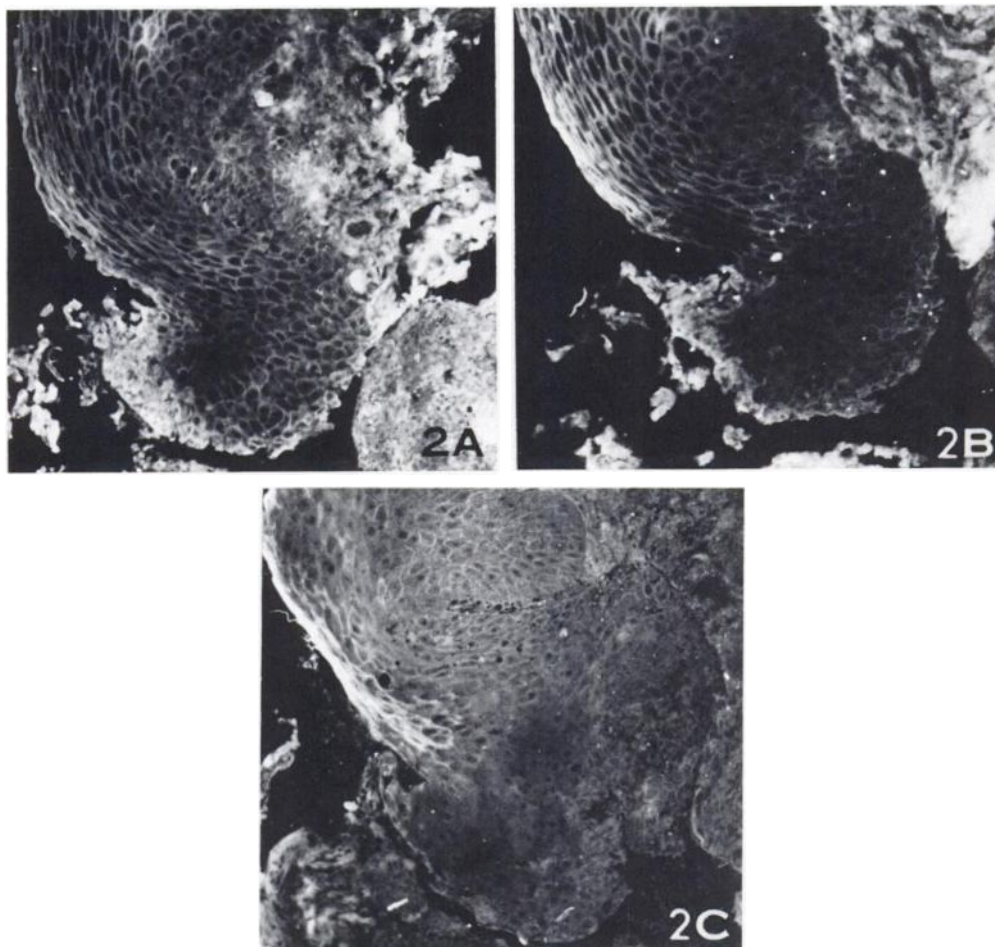


Fig. 2. Human buccal mucosa (Case 7) 2 days after wounding. *R. communis* staining. A, B, and C, staining with different dilutions of FITC-conjugated RCA₁. *R. communis* receptors in the outgrowth are clearly stained in A (dilution, 1:5), are weakly stained in B (dilution, 1:20), and are not stained in C (dilution, 1:80). × 150.