

Methotrexate Levels in the Interstitial Space and Seminiferous Tubule of Rat Testis

Riccardo Riccardi,¹ Robert A. Vigersky, Susan Barnes, W. Archie Bleyer, and David G. Poplack²

Pediatric Oncology Branch, National Cancer Institute, Bethesda, Maryland 20205 [R. R., D. G. P.]; Kyle Metabolic Unit, Walter Reed Army Medical Center, Washington, D. C. 20012 [R. A. V., S. B.]; and Childrens Orthopedic Hospital Medical Center, Seattle, Washington 98105 [W. A. B.]

ABSTRACT

The ability of methotrexate (MTX) to pass from the blood into the interstitial space and seminiferous tubule of the rat was investigated using testicular micropuncture. MTX was administered to anesthetized adult Wistar rats via a femoral vein cannula. Constant plasma levels of MTX were achieved by giving a priming dose followed by a constant infusion of 1, 10, or 100 mg/kg/hr with 6 to 27 rats studied at each dose. Blood (via a jugular vein cannula), testicular interstitial fluid, and seminiferous tubule fluid (via direct micropuncture) were periodically sampled during the 4 hr of drug infusion.

Under steady-state conditions, when compared to corresponding plasma values, MTX levels were 2- to 4-fold lower in the testicular interstitial fluid and 18- to 50-fold lower in the seminiferous tubule. These results indicate that, in the rat, a significant blood-testis barrier to MTX exists at the tubular but probably not at the capillary-interstitial level. If these results can be extrapolated to humans, they do not provide a pharmacological explanation for the frequent occurrence of leukemic relapse in the interstitium of the testes in boys with acute lymphocytic leukemia.

INTRODUCTION

Significant improvement in the therapy for acute lymphoblastic leukemia has increased the number of patients experiencing long-term remissions (12). With increasing survival, an increased incidence of localized testicular relapse has been noted in male patients with this disease. This complication has been reported to occur in up to 30% of patients (2, 4, 7, 9-11, 13-17) and is often followed by systemic relapse (9, 14-16).

It is unknown why the testis represents a privileged site for isolated leukemic infiltration. One proposed mechanism is the existence of a blood-testis barrier which protects leukemic cells from optimal exposure to chemotherapeutic agents such as MTX.³

In the present study using testicular micropuncture, we investigated the ability of i.v. administered MTX to pass from the blood into the testicular interstitial space and seminiferous tubules of the rat.

MATERIALS AND METHODS

Animals

Sexually mature male Wistar rats (Walter Reed strain) weighing

¹ Present address: Catholic University of Rome, Department of Pediatrics, Largo A. Gemelli 8, Rome, Italy.

² To whom requests for reprints should be addressed, at Pediatric Oncology Branch, National Cancer Institute, Building 10, Room 3B03, Bethesda, Md. 20205.

³ The abbreviation used is: MTX, methotrexate.

Received August 10, 1981; accepted January 20, 1982.

between 380 and 540 g were used in these experiments. Sexually mature animals were chosen because tubular fluid cannot be obtained in those that are sexually immature. These animals were anesthetized with sodium pentobarbital (60 mg/kg i.p.) and cannulae were inserted into the contralateral jugular and femoral veins for blood sampling and drug infusion, respectively.

Intravenous Infusions

MTX was diluted with sterile water to a concentration of 1, 10, or 100 mg/0.5 ml. Following a priming dose of 1, 10, or 100 mg/kg, a constant infusion rate of 0.5 ml/hr of the appropriate solution was maintained utilizing a Harvard Model 940 infusion pump (Harvard Apparatus Co., Inc., Dover, Mass.). Six to 27 animals were used at each dose level.

Sampling

Plasma. At 1-, 2-, 3-, and 4-hr intervals from the start of infusion, 0.5 ml of heparinized blood was collected via the jugular vein cannula and promptly centrifuged. Aliquots of plasma were immediately placed in the dark and frozen at -28° until MTX concentrations were determined.

Testis. The testis was exposed by an incision of the scrotal sac and placed on a glass warming basin which maintained the testis at its normal temperature (32°) throughout the experiment. Seminiferous tubules were exposed by incision of the tunica albuginea. Tubular micropuncture was performed at $\times 10$ to $\times 20$ using a technique described previously which uses a glass micropipet sharpened to a diameter of 120 μm (18). A small drop of water-equilibrated mineral oil colored with Sudan black was injected to confirm the intraluminal location of the pipet tip. By aspirating fluid from 5 to 10 tubules, about 1 μl of tubular fluid can be collected over a period of 20 to 30 min. Tubular fluid samples were centrifuged at $12,000 \times g$ for 30 min at 0° in a Beckman RC2B centrifuge to obtain a cell-free sample. The volume of each sample was measured, diluted with 0.9% NaCl solution up to 100 μl and stored in the dark at 20° prior to MTX assay. Interstitial fluid (the fluid between tubules that was devoid of RBC as determined by light microscopy) was obtained by aspirating from multiple extraluminal sites in areas different from those used for intratubular samples. One to 2 μl of interstitial fluid were obtained at each time point.

Peritoneal and Scrotal Fluid. In 4 separate experiments, the peritoneal and scrotal cavities were opened following 3 hr of MTX continuous infusion, and 5 μl of fluid were aspirated immediately.

MTX Assay

MTX concentrations were measured by the dihydrofolate reductase inhibition assay (1) in which the lower limit of sensitivity was 0.4 to 10^{-9}M .

RESULTS

The plasma MTX levels achieved with the 3 different doses are shown in Chart 1. A constant level was achieved in plasma at each dose level for the duration of the experiment.

A typical experiment at the 10-mg/kg/hr dose is shown in

Chart 2. During the infusion, plasma MTX levels remained constant and were about 30 times higher than the simultaneously obtained tubular levels and 2 times higher than the interstitial levels.

The MTX levels achieved in the plasma, interstitial, and tubular fluids with the 3 different dose infusions are shown in Chart 3. Each column represents the mean \pm S.E. of the data obtained at all time points throughout the infusion. Ten rats were studied at the 100-mg/kg/hr infusion rate, 27 rats were studied at the 10-mg/kg/hr infusion rate, and 6 rats were studied at the 1-mg/kg/hr infusion rate. At the 1-mg/kg/hr infusion rate, MTX levels were undetectable in the seminiferous tubule. The interstitial space MTX levels were one-half those of plasma. At the 10-mg/kg/hr infusion rate, the MTX levels were about 4-fold lower than plasma in the interstitial testicular fluid and 18 times lower than plasma in the seminiferous tubule. At the 100-mg/kg/hr infusion rate, a 4-fold decrease of MTX concentration was also found in the interstitial space and about a 50-fold decrease was found in the seminiferous tubule.

The MTX levels in the s.c. fluid of the scrotum and in the peritoneal fluid were evaluated after 3 hr at the 10-mg/kg/hr infusion rate in 4 animals and found to be $2.02 \pm 0.02 \times 10^{-5}$ M and $1.75 \pm 0.6 \times 10^{-5}$ M, respectively (Chart 4). These levels are indistinguishable from those obtained from the testicular interstitial space in animals given the same dose.

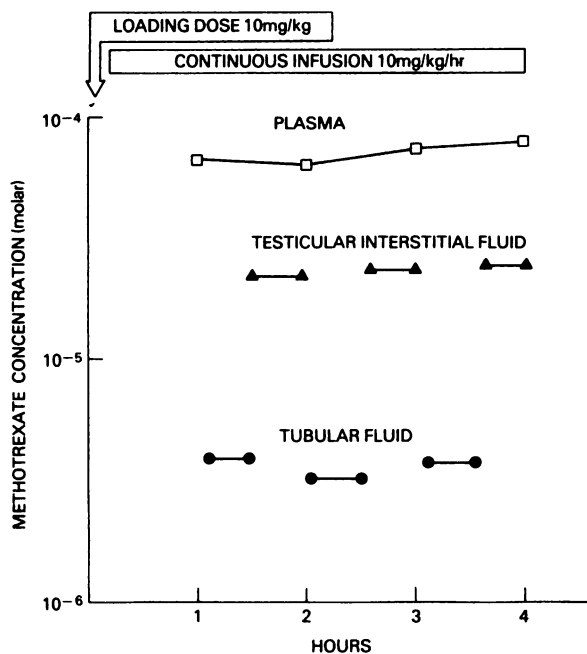


Chart 2. Plasma, interstitial, and tubular fluid MTX levels measured in a representative experiment. The 10-mg/kg/hr dose was used. Length of bars, time elapsed during collection of testicular samples.

DISCUSSION

The existence of a physiological blood-testis barrier which

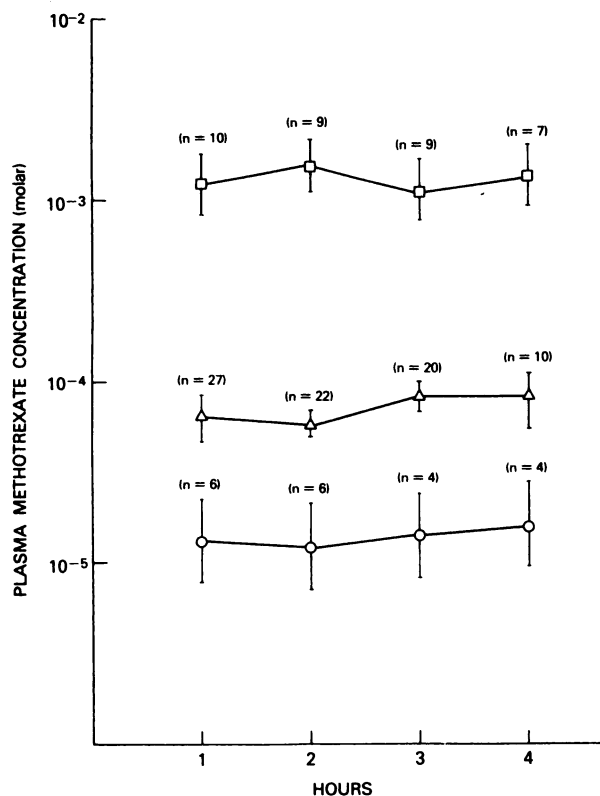


Chart 1. Mean MTX plasma levels achieved at different time intervals after administration of a loading dose followed by a continuous infusion. O, 1 mg/kg/hr; Δ , 10 mg/kg/hr; \square , 100 mg/kg/hr. Numbers in parentheses, number of samples assayed at each time point. Bars, S.E.

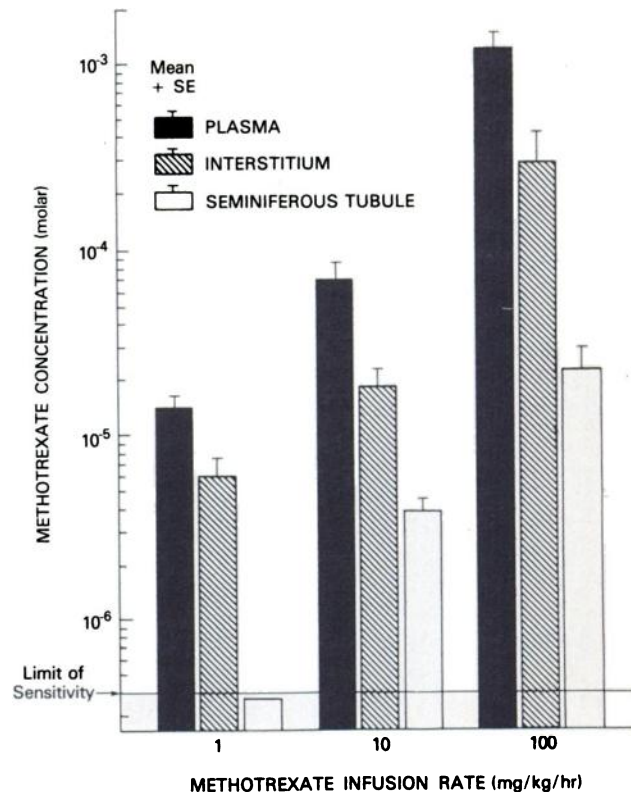


Chart 3. Mean MTX levels achieved in plasma, testes, interstitium, and seminiferous tubules by administration of a loading dose followed by a continuous infusion of 1, 10, and 100 mg/kg/hr. Bars, S.E.

prevents the entry of large-molecular-weight compounds into the seminiferous tubule has been well established both in animals and in humans (3, 6). Anatomically, this barrier is believed to comprise the tight junctions of the Sertoli cells

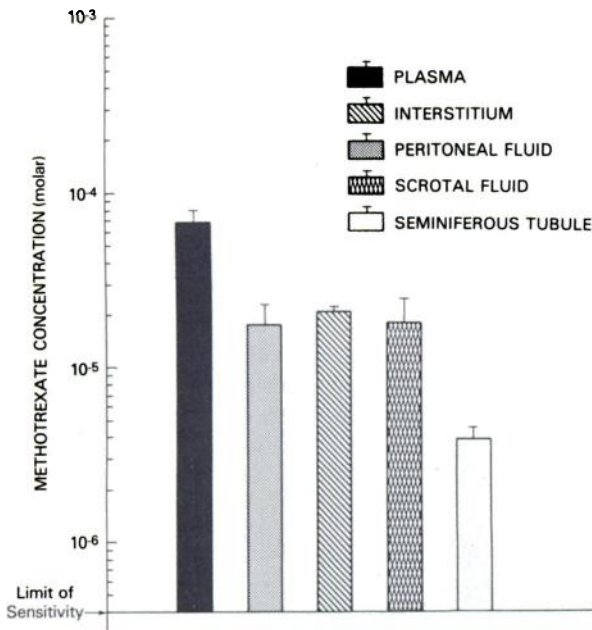


Chart 4. Mean MTX levels achieved in plasma, interstitial, peritoneal, scrotal, and seminiferous tubular fluids by administration of a loading dose followed by a continuous infusion of 10 mg/kg/hr for 3 hr ($n = 4$). Bars, S.E.

which line the seminiferous tubule (3). Whether a second physiological barrier between the blood and interstitial space exists is unclear. One or both of these barriers could potentially modify the therapeutic efficacy and/or toxicity of the commonly used chemotherapeutic agents. Cyclophosphamide is the only antineoplastic agent which has been analyzed for its ability to cross the blood-testis barrier. Using radioactive cyclophosphamide injected directly into the spermatic artery and measuring the radioactivity in the tubular fluid via direct micropuncture, Forrest *et al.* (5) showed that it readily crosses the blood-testis barrier. The significance of this finding is not clear since the drug was injected into the testicular artery, thus probably bypassing the hepatic conversion of cyclophosphamide into its active form. However, the clinical observation that men treated with cyclophosphamide have abolition of spermatogenesis suggests that the active metabolites of cyclophosphamide cross the blood-testis barrier (8).

However, in the present study, we have shown that, in contrast to cyclophosphamide, a tubular barrier to MTX exists. Drug concentrations were 18 to 50 times lower in the seminiferous tubules than in corresponding plasma levels.

Spread of leukemia into the seminiferous tubules is believed to occur only in the late stages of leukemic infiltration into the testis. In most cases, the leukemia is localized in the interstitium. A pharmacological barrier between the blood and interstitium has been proposed to explain this finding. However, although we detected a substantial barrier to MTX at the level of the seminiferous tubule, our data revealed only a 2- to 4-fold

decrease in the interstitial fluid MTX levels compared to plasma. Notably, the peritoneum and scrotum, rare sites of leukemic relapse, had levels of MTX that were similar to those of the interstitial space of the testis.

Therefore, it does not appear that a unique pharmacological barrier for MTX exists between the blood and interstitium in the testes. If these results can be extrapolated to humans, the leukemic infiltration which occurs in the testes does not appear to be due to a pharmacological barrier between the plasma and the interstitial space.

ACKNOWLEDGMENTS

We gratefully acknowledge the technical assistance of Fred Coleman and Jill Savitch and the expert secretarial assistance of Barbara Kuffler and Estelle Coleman.

REFERENCES

- Bertino, J. R., and Fischer, G. A. Techniques for study of resistance to folic acid antagonists. *Methods Med. Res.*, 10: 297-307, 1964.
- Editorial. Testicular infiltration in childhood leukemia: harbour or harbinger? *Lancet*, 2: 136-137, 1978.
- Fawcett, D. W., Leak, L. V., and Heidger, P. M. Electron microscopic observation on the structural components of the blood-testis barrier. *J. Reprod. Fertil.* 10 (Suppl.): 105-122, 1970.
- Finklestein J. Z., Dymont P. G., and Hammond, G. D. Leukemic infiltration of the testes during bone marrow remission. *Pediatrics*, 43: 1042-1045, 1969.
- Forrest, J. B., Turner, T. T., and Howards, S. S. Cyclophosphamide and blood-testis barrier. *Surg. Forum*, 30: 552-553, 1979.
- Guieysse-Pellissier, A. Action de la colchicine sur le testicule du cobaye. *Bull. d'Hist. Appliq. Physiol. Pathol.*, 19: 81-94, 1942.
- Hustu, H. O., and Aur, R.T.A. Extramedullary leukemia. *Clin. Haematol.* 7: 313-337, 1978.
- Kumar, E. R., Biggart, J. D., McEvoy, J., and McGeown, M. G. Cyclophosphamide and reproductive function. *Lancet*, 1: 1212-1214, 1972.
- Kuo, T., Tschang, T., and Chu, J. Testicular relapse in childhood acute lymphocytic leukemia during bone marrow remission. *Cancer (Phila.)* 38: 2606-2612, 1976.
- Medical Research Council's Working Party on Leukemia. Testicular disease in acute lymphoblastic leukemia in childhood. *Br. Med. J.*, 1: 334-338, 1978.
- Nesbit, M. E., Robinson, L. L., Ortega, J. A., Sather, H. N., Donaldson, M., and Hammond, D. Testicular relapse in childhood acute lymphoblastic leukemia: association with pretreatment patient characteristics and treatment. Report for Children Cancer Study Group. *Cancer (Phila.)*, 45: 2009-2016, 1980.
- Pinkel, D. Five-year follow-up of total therapy of childhood lymphocytic leukemia. *J. Am. Med. Assoc.* 216: 648-652, 1971.
- Prieto, C., Hustu, D., Aur, R., and Simone, J. Testicular involvement in childhood acute lymphocytic leukemia. *Proc. Am. Assoc. Cancer Res.*, 16: 178, 1975.
- Schaison, G., Jacquillat, C., Weil, M., Auclerc, M. F., Desperz-Curley, J. P., and Bernard, J. Testicular localizations in association with acute leukemia: 111 cases. *Nouv. Presse Med.*, 12: 1029-1032, 1977.
- Steinfeld, A. D. Radiation therapy in the treatment of leukemic infiltration of the testes. *Radiology*, 120: 681-682, 1976.
- Stoffel, T. J., Nesbit, M. E., and Levitt, S. H. Extramedullary involvement of the testes in childhood leukemia. *Cancer (Phila.)*, 35, 1203-1211, 1975.
- Sullivan, M. P., and Hrgovic, M. Extramedullary leukemia. In: W. W. Sutow, T. J. Vietti, and D. J. Fernbach (eds.), *Clinical Pediatric Oncology*, Ed. 2, pp. 371-397. St. Louis: C. V. Mosby Co. 1977.
- Vigersky, R. A., Loriaux, D. L., Howards, S. S., Hodgen, G. B., Lipsett, M. B., and Chrambach, A. C. Androgen binding proteins of testis, epididymis, and plasma in man and monkey. *J. Clin. Invest.* 58: 1061-1068, 1976.