

Effect of High and Low Dietary Protein on the Dosing and Postdosing Periods of Aflatoxin B₁-induced Hepatic Preneoplastic Lesion Development in the Rat¹

B. Scott Appleton² and T. Colin Campbell³

Division of Nutritional Sciences, Cornell University, Ithaca, New York 14853

ABSTRACT

Aflatoxin B₁-induced liver lesion development is readily modified by dietary protein intake. Earlier work had shown that low-protein diets enhanced the acutely toxic lesion but depressed the carcinogenic lesion. This study examined the emergence of these lesions as a function of dietary protein intake, particularly with respect to whether the protein modification occurred during or after the aflatoxin B₁ dosing period. High (20%) and low (5%) casein diets were fed to growing Fischer 344 rats during the dosing and postdosing periods of aflatoxin B₁-induced hepatic preneoplastic lesion development. Focal areas of hepatocellular alteration were identified and quantitated by staining sections of liver for γ -glutamyl transferase (GGT).

Animals fed low casein diets during the dosing period displayed a characteristic spectrum of lesions including hepatomegaly, severe bile duct proliferation, cholangiofibrosis, and a tendency for developing large remodeling GGT-positive foci. These lesions were regarded as symptomatic of acute hepatotoxicity. Animals fed high-protein diets during the dosing period had small, densely stained, GGT-positive foci, with only mild bile duct proliferation and no cholangiofibrosis, hepatomegaly, or large, remodeling GGT-positive foci.

During the postdosing period, protein modulation markedly influenced the total number of foci. Animals fed high casein diets during this period exhibited an approximate 6-fold increase in the number of foci, regardless of the level of protein fed during the earlier dosing period. The marked increase in foci number (as well as area of liver occupied) in high casein diet animals during the postdosing period is regarded as an increased tendency for tumor development.

INTRODUCTION

Epidemiological studies have shown a high correlation between high dietary protein, particularly animal protein, and cancers of the colon, rectum, breast, and kidney (3, 11). Furthermore, low dietary protein has been shown by numerous investigators to inhibit experimental carcinogenesis (22, 33, 37, 39, 40).

The particular stage of carcinogenesis in which dietary protein has the greatest impact is not known. Low-protein diets have been shown to decrease hepatic AFB₁⁴ macromolecular adduct formation in rats (27), which suggests that dietary protein could

modify the initiation stage. On the other hand, low dietary protein has been found to inhibit the postinitiation developmental stage of AFB₁-initiated preneoplastic liver lesions (1). These studies were therefore designed to compare the effect of dietary protein level on the dosing and postdosing periods of AFB₁-induced preneoplastic liver lesion development. Preneoplastic lesions were identified by staining sections of liver for GGT. GGT activity has been reported to increase sharply in nearly all hepatocarcinogen-induced foci of cellular alteration (20, 25). Evidence supports the probability that these foci of cellular alteration are early preneoplastic lesions which, under the appropriate stimuli, progress to neoplastic lesions (31, 38). We therefore considered use of GGT-positive foci as a reliable means of examining the neoplastic process during its early stages.

MATERIALS AND METHODS

Animals, Diets, and AFL₁. Male Fischer 344 rats (Charles River, Inc., Wilmington, Mass.) were obtained as weanlings and maintained on AIN-76 (28) diet (20% casein) until the onset of the study, at which time they had reached a mean body weight of 80 g. They were individually caged and received diet and tap water *ad libitum*. The temperature, humidity, and lighting conditions were kept constant throughout the entire study. The 5% casein diet was identical to the AIN-76 diet except that sucrose was substituted isocalorically for casein. AFL₁ (Makor Chemicals, Ltd., Jerusalem, Israel) was dissolved in tricapylin at a concentration of 250 μ g/ml.

Experimental Protocol. Chart 1 illustrates the temporal relationships between the dietary treatments and AFB₁ dosing. Four dietary treatments were used. The 5-5 and 20-20 groups were fed 5% and 20% casein diets for the 2-week dosing and 12-week postdosing periods, respectively. The 5-20 group was fed the 5% casein diet during the dosing period and switched to the 20% casein diet for the postdosing period. The 20-5 group was fed the 20% casein diet for the dosing and switched to the 5% casein diet for the postdosing period. In addition to the dosing and postdosing periods, 2 acclimation periods were used. The 1-week predosing period acclimated the animals to their respective diets; the 1-week postdosing period enabled the animals to clear their tissues of AFB₁ and its metabolites. Animals were given a total of 10 doses (one each day, Monday through Friday) of AFB₁ during the 2-week dosing period. The AFB₁ was dissolved in tricapylin and administered by gastric intubation at a level of 250 μ g/kg/dose. The control animals (6/group) were treated according to the same protocol except that they received intubations of tricapylin only.

Histochemical Determination of GGT. At the time of sacrifice, slices of liver were frozen on dry ice and stored at -70° . Frozen cryostat sections (10 μ m) were fixed in ice-cold acetone for 24 hr. Sections were assayed histochemically for GGT according to the method of Rutenburg *et al.* (29). Adjacent sections were stained with hematoxylin and eosin.

Foci of GGT-stained hepatocytes were counted using a light microscope. Foci diameters were determined by projecting the section image at constant magnification with a photographic enlarger. The foci were traced, and diameters were standardized against a 1-cm reference image projected at the same magnification. The percentage of the section

¹ This research was supported by USPHS Grants PO1 CA 26755 and T2 E 50705A.

² Present address: United States Army Institute for Environmental Medicine, Matick, MA 01760.

³ To whom requests for reprints should be addressed, at Division of Nutritional Sciences, N206 MVR, Cornell University, Ithaca, N. Y. 14853.

⁴ The abbreviations used are: AFB₁, aflatoxin B₁; GGT, γ -glutamyl transferase. Received November 9, 1981; accepted February 4, 1983.

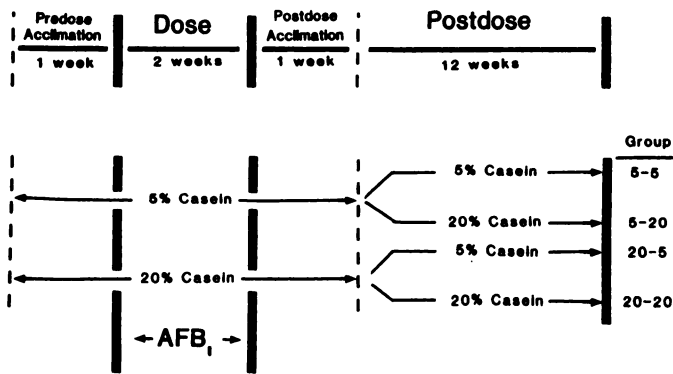


Chart 1. Temporal relationships between AFB₁ dosing and diet treatments.

occupied by GGT-positive foci was determined by projecting an image of the section on a grid of 2000 evenly spaced dots and by dividing the number of dots touching the foci by the total number of dots within the section. Section areas were determined by projecting an image of the section onto standard weight paper. This image was traced and cut out, and its weight was referenced against the weight of a 1-cm-section image. From these data, the number of foci/cu cm and the percentage of liver occupied by the foci were determined as described elsewhere (26).

Statistical Analysis. All statistical analyses were performed using the Minitab computerized program (30). In this program, treatment means of histochemically determined GGT were statistically analyzed by the Mann-Whitney test. All other treatment effects were tested by an analysis of variance.

RESULTS

Table 1 summarizes the body weight and liver weight data. The animals in the 20-20 group were the largest, while those in the 5-5 group were the smallest, with the other groups (Groups 5-20 and 20-5) being intermediate. Liver weights in all groups were the same except for those fed the 5% casein diets during the dosing period. These livers were enlarged and had rough surfaces and rounded edges.

The various dietary regimens produced both qualitative and quantitative differences in lesion development. These differences are summarized in Table 2. Some degree of bile duct proliferation was observed in all animals dosed with AFB₁. However, the groups fed the 5% casein diet during the dosing period (Groups 5-5 and 5-20) had relatively severe bile duct proliferation and cholangiofibrosis (Fig. 1). In these groups, the architecture of the liver was often distorted by fibrous septa. Groups fed the 20% casein diet during the dosing period (Groups 20-5 and 20-20) had mild bile duct proliferation and no cholangiofibrosis.

The numbers of GGT-positive foci observed in the different groups appeared to be dependent upon the level of dietary casein fed during the postdosing period (Table 3). For example, the 5-20 and 20-20 groups had markedly increased numbers of foci when compared with the 5-5 and 20-5 groups. The percentage of liver volume occupied by foci also was greater in the 5-20 and 20-20 groups (Table 3).

There were several qualitative changes in the GGT-positive foci that were dependent upon the level of casein fed during the dosing period. As shown in Table 3, the mean diameters of the foci were larger in animals from the 5-5 and 5-20 groups. Based on their staining patterns, many of these very large foci appeared to be undergoing significant remodeling (Fig. 2). That is, there was an absence of GGT staining in scattered areas within each

focus. Groups fed the 20% casein diet during the dosing period tended to have small, densely stained foci (Fig. 3), which have been regarded as being more persistent (12). The overall effects of the different dietary treatments on the size, number, and apparent disposition of these foci are summarized in Table 2.

DISCUSSION

It is apparent that the emergence of AFB₁-induced liver lesions is dependent upon both the level of dietary casein fed and the time when it is consumed. For example, the feeding of the low-protein diet during the dosing period enhanced the development of lesions thought to be characteristic of AFB₁-induced acute toxicity (bile duct proliferation, cholangiofibrosis, hepatomegaly, large-remodeling foci). However, the feeding of the low-protein diet during the postdosing period resulted in a marked decrease in the number of foci (regardless of their size or nature), and that probably represents a lower tendency for neoplastic development. A comparison of the 5-20 and 20-5 groups is revealing of the dual effect of consumption time and level of dietary protein. The animals in the 5-20 group displayed a large spectrum of lesions including hepatomegaly, severe bile duct proliferation, cholangiofibrosis, and numerous large-remodeling and small-persistent GGT-positive foci. The animals in the 20-5 group, on the other hand, had little bile duct proliferation and very few GGT-positive foci. In fact, the livers from these latter 20-5 animals resembled these of control (no AFB₁) animals. The diversity in the type and amount of lesions that result from the same dose of AFB₁ when the amount and time of dietary protein feeding are modified is impressive.

The role of ductular hyperplasia in the pathogenesis of liver cell cancer is not entirely understood. Although this lesion often precedes the development of chemically induced hepatic neo-

Table 1
Terminal body and liver weights

Statistical significance between values is noted by Footnotes b, d, and e. Means which are different at p < 0.05 have different superscripts.

Treatment	No. of animals	Body wt (g)	Relative liver wt (g/100 g body wt)
Control			
5-5 ^a	6	233 ± 2.3 ^{b, c}	3.9 ± 0.07 ^b
5-20	6	322 ± 9.5 ^d	3.8 ± 0.13 ^b
20-5	6	311 ± 7.7 ^d	3.7 ± 0.05 ^b
20-20	6	349 ± 14.4 ^e	3.8 ± 0.08 ^b
Aflatoxin B ₁			
5-5	12	225 ± 4.5 ^b	4.4 ± 0.07 ^d
5-20	11	291 ± 3.4 ^d	4.4 ± 0.14 ^d
20-5	12	297 ± 4.8 ^d	3.8 ± 0.10 ^b
20-20	12	340 ± 6.0 ^e	3.9 ± 0.06 ^b

^a Percentages of dietary casein during initiation-promotion stages.
^b See Table 1 legend.
^c Mean ± S.E.
^d See Table 1 legend.
^e See Table 1 legend.

Table 2
Lesion characteristics in AFB₁-treated animals fed different diets

% of dietary casein during dosing-post-dosing stages	Bile duct proliferation	GGT-positive foci
5-5	Severe	Few, large-remodeling
5-20	Severe	Many, small-persistent, large-remodeling
20-5	Mild	Very few, small-persistent
20-20	Mild	Many, small-persistent

Table 3

Effect of different dietary treatments on GGT-positive foci development in AFB₁-treated ratsStatistical significance between values is noted by Footnotes b and d. Means which are different at $p < 0.05$ have different superscripts.

Treatment	No. of animals	No. of foci/ml of liver	% of liver vol occupied by foci	Diameter of foci (μm)
5-5 ^a	12	9.4 \pm 4.1 ^{b, c}	1.2 \pm 0.77 ^b	77 \pm 17 ^b
5-20	11	53.9 \pm 17.8 ^d	3.0 \pm 0.91 ^a	67 \pm 13 ^b
20-5	12	15.9 \pm 7.3 ^b	0.19 \pm 0.06 ^b	28 \pm 3 ^d
20-20	12	96.5 \pm 26.3 ^d	1.96 \pm 0.40 ^a	35 \pm 2 ^d

^a Percentages of dietary casein during dosing-postdosing stages.^b See Table 3 legend.^c Mean \pm S.E.^d See Table 3 legend.

plasms, there is considerable evidence that hyperplastic ductular cells are not preneoplastic precursors for hepatocellular carcinomas (14, 15). More recently, Farber (16) has pointed out that liver cell cancer can be induced without accompanying ductular proliferation. Newberne and Wogan (24) studied the sequential morphological changes during AFB₁ hepatocarcinogenesis in the rat and concluded that bile duct proliferation and cholangiofibrosis do not play significant roles in the pathogenesis of AFB₁-induced neoplasms. Although this lesion was prevalent in the groups fed the 5% casein diet during the dosing period, it is probable that it plays only a minor, if any, role in the development of hepatocellular neoplasms. The greater number of foci in the groups fed the 20% casein diet during the postdosing period, on the other hand, probably represents a greater tendency toward tumor development.

The phenomenon of remodeling and persistent foci has been the subject of several studies, and investigators have concluded that chemical carcinogen-induced foci of cellular alteration have 2 major options for further development (12, 18). Most foci (95%?) appear to regress or remodel back to normal-appearing tissue. A few remain persistent and presumably give rise to hepatocellular carcinomas. There is evidence which indicates that remodeling foci can be recalled upon exposure to the appropriate stimuli (4, 17). We also have evidence with the animal model studied here that progenitor cells of GGT-positive foci can be activated after a dormancy period by the feeding of a high-protein diet (2). This suggests that, although the remodeled foci have lost the properties that make them identifiable, they still retain a "memory" of their altered state. Therefore, even though a liver may have no identifiable lesions, it may be at risk of developing cancer if subjected to a sufficient promoting environment.

The fact that a low-protein diet resulted in distinctly different effects, depending upon the time of feeding, suggests the possibility that different mechanisms may be involved. Animals fed low-protein diets have been reported to be more susceptible to the hepatotoxic effects but less susceptible to the carcinogenic effects of AFB₁. Madhavan and Gopalan (21) reported in 1965 that animals fed a low (4%) casein diet developed extensive periportal fibrosis and bile duct proliferation, while animals fed 20% casein diets essentially had none of these changes. However, these workers also reported that the high-protein animals exhibited liver changes that were "considered possible precancerous" and that "were not encountered in the deficient groups." Later work by this group (22) confirmed that the feeding of a low-protein diet depressed the formation of AFB₁-induced hepatocellular carcinoma. We reported subsequently that AFB₁, as the parent compound, inhibited rat liver mitochondrial electron

transport at the antimycin A-sensitive site (10) and postulated subsequently (5) that the enhanced liver cell necrosis and acute toxicity observed in the low-protein animals could be due to the low rate of metabolism and clearance of AFB₁ with a consequent effect on mitochondrial respiration.

During the postdosing period, the inhibition of foci development with the low-protein diet may be related to an inhibition of cell replication. Cells of preneoplastic islands appear to possess a defect of growth control such that they proliferate rapidly and are more susceptible to endogenous and exogenous growth stimuli (32). One study (19) showed that upon continual exposure to AFB₁, inhibition of liver cell replication was followed by a period in which islands of hepatocytes, resistant to the cytotoxicity of the AFB₁, underwent rapid proliferation. These carcinogen-resistant hepatocytes appear to be a similar population of hepatocytes described by other investigators who have shown that these cells eventually progress to form GGT-positive foci (34-36). These reports, along with those of others (6, 7), indicate that cell replication is a crucial event in the process of neoplastic development. Dietary protein deprivation has been shown to inhibit liver cell replication (8, 13). The liver appears to respond to protein deficiency by a prompt and sustained decrease in synthetic processes necessary for cell replication in favor of those required for energy production and protein synthesis (9, 23). This inhibition of liver cell replication may explain why animals fed the 5% casein diets during the postdosing period failed to develop as many GGT-positive foci as animals fed the 20% casein diets, particularly in view of the fact that more rapidly proliferating cells of foci may possess a greater requirement for amino acids for protein synthesis. In addition to an effect on cell replication, dietary protein may modify other important functions, such as immune status and proteolytic enzyme activity.

REFERENCES

1. Appleton, B. S., and Campbell, T. C. Low dietary casein inhibits the development of aflatoxin B₁ initiated preneoplastic liver lesions. *Nutr. Cancer* 3: 200-206, 1982.
2. Appleton, B. S., and Campbell, T. C. Dietary protein intervention during the postdosing phase of aflatoxin B₁-induced hepatic preneoplastic lesion development. *J. Natl. Cancer Inst.*, in press, 1983.
3. Armstrong, B., and Doll, R. Environmental factors and cancer incidence and mortality in different countries, with special reference to dietary practices. *Int. J. Cancer*, 15: 617-631, 1975.
4. Becker, F. F. Sequential phenotypic and biochemical alterations during chemical hepatocarcinogenesis. *Cancer Res.*, 36: 2563-2566, 1976.
5. Campbell, T. C., and Hayes, J. R. The role of metabolism in the toxicity of aflatoxin. *Toxicol. Appl. Pharmacol.*, 35: 199-222, 1976.
6. Cayama, E., Tsuda, H., Sarma, D. S. R., and Farber, E. Initiation of chemical carcinogenesis requires cell proliferation. *Nature (Lond.)*, 275: 60-62, 1978.
7. Columbano, A., Rajalakshmi, S., and Sarma, D. S. R. Requirement of cell proliferation for the initiation of liver carcinogenesis as assayed by three different procedures. *Cancer Res.*, 41: 2079-2083, 1981.
8. Dallman, P. R. Malnutrition: incorporation of thymidine-³H into nuclear and

- mitochondrial RNA. *J. Cell. Biol.*, 51: 549-553, 1971.
9. Dallman, P. R., and Manies, E. C. Protein deficiency: contrasting effects on DNA and RNA metabolism in the rat. *J. Nutr.*, 103: 1311-1318, 1973.
 10. Doherty, W. P., and Campbell, T. C. Aflatoxin inhibition of rat liver mitochondria. *Chem.-Biol. Interact.*, 7: 63-77, 1973.
 11. Drasar, B. S., and Irving, D. Environmental factors and cancer of the colon and breast. *Br. J. Cancer*, 27: 167-172, 1973.
 12. Enomoto, K., and Farber, E. Kinetics of phenotypic maturation of remodeling of hyperplastic nodules during liver carcinogenesis. *Cancer Res.*, 42: 2330-2335, 1982.
 13. Enwonwu, C. O., and Munro, H. N. Rate of RNA turnover in rat liver in relation to intake of protein. *Arch. Biochem. Biophys.*, 138: 532-539, 1970.
 14. Farber, E. Similarities in the sequence of early histological changes induced in the liver of the rat by ethionine, 2-acetylaminofluorene, and 3'-methyl-4-dimethylaminoazobenzene. *Cancer Res.*, 16: 142-155, 1956.
 15. Farber, E. Ethionine carcinogenesis. *Adv. Cancer Res.*, 7: 383-474, 1963.
 16. Farber, E. The pathology of experimental liver cell cancer. In: H. M. Cameron, D. A. Linsell, and G. P. Warwick (eds.), *Liver Cell Cancer*, pp. 243-277. Amsterdam: Elsevier/North-Holland Biomedical Press, 1976.
 17. Farber, E. The sequential analysis of liver cancer induction. *Biochim. Biophys. Acta*, 605: 149-166, 1980.
 18. Farber, E., and Cameron, R. The sequential analysis of cancer development. *Adv. Cancer Res.*, 31: 125-226, 1980.
 19. Godoy, M., Judah, D. J., Arora, H. L., Neal, G. E., and Jones, G. The effects of prolonged feeding with aflatoxin B₁ on adult rat liver. *Cancer Res.*, 36: 2399-2407, 1976.
 20. Kalengayi, M. M. R., Gilli, J., and Desmet, V. J. Tissue dynamics of the oncofetal markers α_1 -fetoprotein and γ -glutamyl transpeptidase in rat liver during aflatoxin B₁ induced carcinogenesis. In: H. E. Nieburgs *et al.* (eds.), *Detection and Prevention of Cancer*, Vol. 31, Part 2, pp. 97-131. New York: Marcel Dekker, 1978.
 21. Madhavan, T. V., and Gopalan, C. Effect of dietary protein on aflatoxin liver injury in weanling rats. *Arch. Pathol.*, 80: 123-126, 1965.
 22. Madhavan, T. V., and Gopalan, C. The effect of dietary protein on carcinogenesis of aflatoxin. *Arch. Pathol.*, 85: 133-137, 1968.
 23. Montecuccoli, G., Novello, F., and Stirpe, F. Effect of protein deprivation and of starvation on DNA synthesis in resting and regenerating rat liver. *J. Nutr.*, 102: 507-514, 1972.
 24. Newberne, P. M., and Wogan, G. N. Sequential morphologic changes in aflatoxin B₁ carcinogenesis in the rat. *Cancer Res.*, 28: 770-781, 1968.
 25. Ogawa, K., Solt, D. B., and Farber, E. Phenotypic diversity as an early property of putative preneoplastic hepatocyte populations in liver carcinogenesis. *Cancer Res.*, 40: 725-733, 1980.
 26. Pitot, H. C., Goldsworthy, T., Campbell, H. C., and Poland, A. Quantitative evaluation of the promotion by 2,3,7,8-tetrachlorodibenzo-p-dioxin of hepatocarcinogenesis from diethylnitrosamine. *Cancer Res.*, 40: 3616-3620, 1980.
 27. Preston, R. S., Hayes, J. R., and Campbell, T. C. The effect of protein deficiency on the *in vivo* binding of aflatoxin B₁ to rat liver macromolecules. *Life Sci.*, 19: 1191-1198, 1976.
 28. Report of the American Institute of Nutrition *ad hoc* committee on standards for nutritional studies. *J. Nutr.*, 107: 1340-1348, 1977.
 29. Rutenburg, A. M., Kim, H., Fischbein, J. W., Harper, J. S., Wasserburg, H. C., and Seligman, A. M. Histochemical and ultrastructural demonstration of gamma-glutamyl transpeptidase activity. *J. Histochem. Cytochem.*, 17: 517-526, 1969.
 30. Ryan, T. A., Joiner, B. L., and Ryan, B. F. *Minitab Student Handbook*. North Scituate, Mass.: Duxbury Press, 1976.
 31. Scherer, E., Hoffman, M., Emmelot, P., and Friedrich-Freksa, M. Quantitative study on foci of altered liver cells induced in the rat by a single dose of diethylnitrosamine and partial hepatectomy. *J. Natl. Cancer Inst.*, 49: 93-106, 1972.
 32. Schulte-Hermann, R., Ohde, G., Schuppler, J., and Timmermann-Trosiener, I. Enhanced proliferation of putative preneoplastic cells in rat liver following treatment with the tumor promoters phenobarbital, hexachlorocyclohexane, steroid compounds, and nafenopin. *Cancer Res.*, 47: 2556-2562, 1981.
 33. Silverstone, H., and Tannenbaum, A. Proportion of dietary protein and the formation of spontaneous hepatomas in the mouse. *Cancer Res.*, 11: 442-446, 1951.
 34. Solt, D. B., Medline, A., and Farber, E. Rapid emergence of carcinogen-induced hyperplastic lesions in a new model for the sequential analysis of liver carcinogenesis. *Am. J. Pathol.*, 88: 595-617, 1977.
 35. Tsuda, H., and Farber, E. Resistant hepatocytes as early changes in liver induced by polycyclic aromatic hydrocarbons. *Int. J. Cancer*, 25: 137-139, 1980.
 36. Tsuda, H., Lee, G., and Farber, E. Induction of resistant hepatocytes as a new principle for a possible short-term *in vivo* test for carcinogens. *Cancer Res.*, 40: 1157-1164, 1980.
 37. Walters, M. A., and Roe, F. J. C. The effect of dietary casein on the induction of lung tumors by the injection of 9,10-dimethyl-1,2-benzanthracene (DMBA) into newborn mice. *Br. J. Cancer*, 18: 312-316, 1964.
 38. Watanabe, K., and Williams, G. M. Enhancement of rat hepatocellular-altered foci by the liver tumor promoter phenobarbital: evidence that foci are precursors of neoplasms and that the promoter acts on carcinogen-induced lesions. *J. Natl. Cancer Inst.*, 67: 1311-1314, 1978.
 39. Wells, P., Aftergood, L., and Alfin-Slater, R. B. Effect of varying levels of dietary protein on tumor development and lipid metabolism in rats exposed to aflatoxin. *J. Am. Oil Chem. Soc.*, 53: 559-562, 1976.
 40. White, J., and Andervont, H. B. Effect of a diet relatively low in cystine on the production of spontaneous mammary-gland tumors in strain C3H female mice. *J. Natl. Cancer Inst.*, 3: 449-451, 1943.

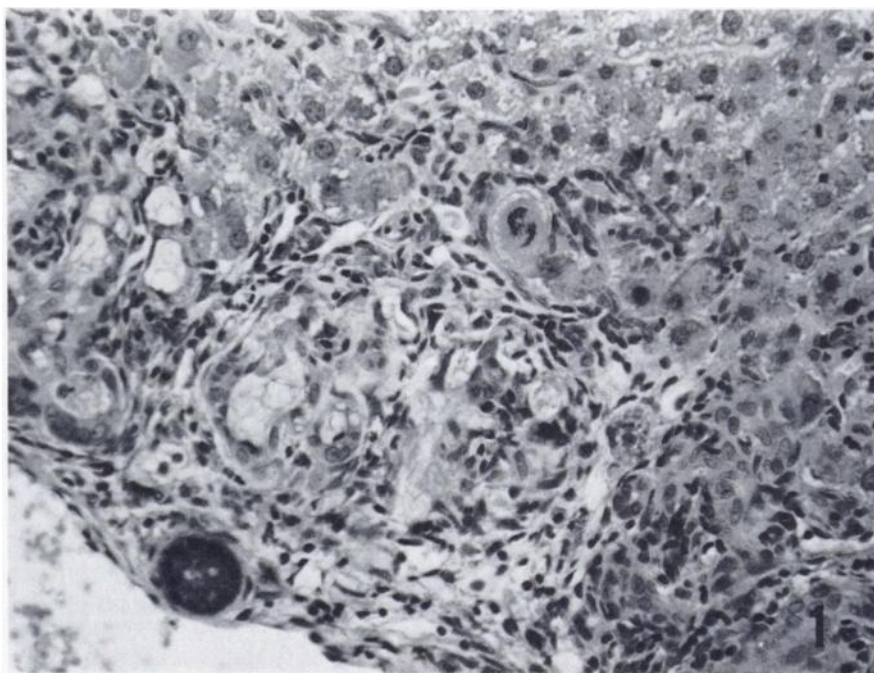


Fig. 1. A section of liver from the 5-5 group showing an area of cholangiofibrosis. H & E, $\times 180$.

Fig. 2. A large GGT-positive focus undergoing significant remodeling. H & E, $\times 65$.

Fig. 3. A section of liver from the 20-20 group showing numerous densely stained GGT-positive foci. GGT, $\times 7$.

