

Cancer Induction in Mice by Feeding of the Uncooked Cultivated Mushroom of Commerce *Agaricus bisporus*¹

Bela Toth² and James Erickson

Eppley Institute for Research in Cancer and Allied Diseases, The University of Nebraska Medical Center, Omaha, Nebraska 68105-1065

ABSTRACT

The cultivated mushroom of commerce in the Western hemisphere, *Agaricus bisporus*, was given p.o. to randomly bred Swiss mice for 3 days and was followed by semisynthetic diet for 4 days each week for life. The mice were 6 weeks old at the beginning of the experiment. As a result of treatment, tumors were induced in the bone, forestomach, liver, and lungs in the following incidences: 16, 38, 8, and 40% in females and 16, 28, 12, and 62% in males, respectively. The corresponding tumor incidences in the untreated controls were 0, 0, 0, and 26% in females and 0, 4, 2, and 34% in males, respectively. Histopathologically, the tumors were classified as osteomas and osteosarcomas, squamous cell papillomas and carcinomas of forestomach, benign hepatomas, and adenomas and adenocarcinomas of lungs. The investigation thus proves the carcinogenicity of uncooked *Agaricus bisporus*.

INTRODUCTION

Agaricus bisporus, the cultivated mushroom of commerce in the Western hemisphere, has several *N-N*-bond-containing chemicals. Among these, the most notable are: β -*N*-[γ -L(+)-glutamyl]-4-(hydroxymethyl)phenylhydrazine (synonym: agaritine); its breakdown product, 4-hydroxymethylphenylhydrazine; 4-(hydroxymethyl)benzenediazonium ion; *p*-hydrazinobenzoic acid; and β -*N*-[γ -L(+)-glutamyl]-4-carboxyphenylhydrazine (1-7).

In a series of earlier experiments we demonstrated the carcinogenicity of the *N'*-acetyl derivative of 4-(hydroxymethyl)phenylhydrazine and the tetrafluoroborate and sulfate forms of 4-(hydroxymethyl)benzenediazonium ion in Swiss mice (8-11). In addition, we have found agaritine and the 4-(hydroxymethyl)benzenediazonium ion to be mutagenic in TA1535 and TA1537 strains of *Salmonella typhimurium* (12). Finally, other investigators have demonstrated the mutagenicity of the water extracts of AB³ in the TA98, TA2637, and TA100 strains of *S. typhimurium* (13).

The present work is the logical extension of our previous investigations and records the carcinogenicity of fresh uncooked AB intermittently administered p.o. for the life of Swiss mice.

MATERIALS AND METHODS

Swiss albino mice from a colony randomly bred in the Chicago Medical School and in this institute since 1951 were used. They were housed in plastic cages on granular cellulose bedding, separated according to sex in groups of 5, and given Wayne Lab Blox diet in regular pellets (Allied Mills, Inc., Chicago, IL) until 6 weeks of age; afterwards, they were given semisynthetic diet (14) prepared by us or the fresh commercial mushroom AB, as described below. Tap water was provided *ad libitum* from the date of birth until natural death.

Received 12/26/85; Revised 4/8/86; accepted 4/22/86.

The costs of publication of this article were defrayed in part by the payment of page charges. This article must therefore be hereby marked *advertisement* in accordance with 18 U.S.C. Section 1734 solely to indicate this fact.

¹ This work was supported by grant CA31611 of the National Cancer Institute, USPHS. Part of the work was presented at the First International Conference of Anticancer Research, October 26 to 30, 1985. Loutraki, Greece (22) and at the 77th Annual Meeting of the American Association for Cancer Research, May 7 to 10, 1986, Los Angeles, CA (27).

² To whom requests for reprints should be addressed.

³ The abbreviation used is: AB, *Agaricus bisporus*.

The mushroom used was the fresh AB, the commercially cultivated variety (Figs. 1 and 2) grown by Camsco Mushroom Company, Inc., Campbell's Farm Fresh Mushrooms, Howe, IN. The fungus was distributed twice weekly to us and to the local food stores by Frank's Fruit House, Omaha, NE.

Toxicity studies were carried out with AB prior to the chronic experiment. AB was fed *ad libitum* for 4.5, 4, 3.5, 3, and 2.5 days each week followed by semisynthetic diet for the rest of the week for a total of 70 days. Each group consisted of 8 animals (4 female and 4 male). Because the body weight of mice treated with AB for 3 days increased steadily, with the exception of an initial short decrease, this dose regimen was selected for the chronic experiment.

The chronic experimental groups and the controls were the following.

Group 1. AB was fed *ad libitum* for 3 days, followed by semisynthetic diet for 4 days of each week for the life span of 50 female and 50 male mice that were 6 weeks (43 days) old at the beginning of the experiment. The estimated average daily mushroom consumption per mouse was 11 g. This figure takes into account the fact that, on the average, 48% of the fresh mushroom is dehydrated in 24 h at room temperature (22°C).

Group 2. As untreated controls, 50 female and 50 male mice received the semisynthetic diet from 6 weeks (44 days) of age until natural death.

The experimental and control animals were carefully checked and weighed weekly, and gross pathological changes were recorded. The animals either were allowed to die or were killed with ether when found in poor condition. Complete necropsies were performed on all animals. All organs were examined macroscopically and were fixed in 10% buffered formalin. The liver, spleen, kidneys, bladder, adrenals, sternum, thyroid, heart, pancreas, testes, ovaries, brain, forestomach, glandular stomach, duodenum, jejunum, ileum, cecum, colon, rectum, nasal turbinal, at least 4 lobes of the lungs from each mouse, and organs showing gross pathological changes were studied histologically. Sections from these tissue were stained routinely with hematoxylin and eosin and studied by light microscopy.

RESULTS

The survival rates after weaning are shown in Table 1. It is clear from the data that the treatment had no substantial effect on survival when compared with the untreated controls; however, the average weekly weight curves of the treated animals were substantially lower throughout the experiment than that of the untreated animals.

The number, percentages of animals with tumors, and their ages at death (latent periods) are summarized in Table 2. The 4 most important neoplasms are described in detail below.

Tumors of Bone. Of the AB-treated females, 8 (16%; $P < 0.005$) developed 21 such neoplasms. Of these, 6 mice had 19 osteomas and 2 mice developed 2 osteosarcomas. In the AB-treated males, 8 (16%; $P < 0.005$) developed 17 bone tumors. Of these, 5 mice had 7 osteomas, 1 mouse had an osteosarcoma and, 2 mice developed 6 osteomas and 3 osteosarcomas.

No bone tumors were found in the untreated controls.

The bone tumors were observed in the following main areas, either connected or adjacent to the bone structures: skull, vertebrae, spine, pelvis, scapula, femur, etc. They were of a hard consistency, well circumscribed, often nodular in shape, and varied in size up to 10 mm diameter. Histologically, some of the lesions showed a disorderly pattern of wide trabeculae,

consisting of calcified osteoid tissue with scattered osteoblasts and capillaries; therefore, based on these characteristics they were classified as osteomas (Figs. 3 and 4). The other types of lesions consisted of abundant osseous and osteoid tissue which intermingled with the malignant spindle- or oval-shaped parenchymatous cells. Often the parenchyma contained varying amounts of vascular tissue with blood vessels and vascular spaces. These lesions were classified as osteosarcomas (Figs. 5 and 6).

Macroscopically and histologically these tumors were similar to those described in humans (15).

Tumors of Forestomach. Of the AB-treated females, 19 (38%; $P < 0.00001$) developed 48 tumors of this organ. Of these, 16 mice had 28 squamous cell papillomas and 3 mice developed

16 squamous cell papillomas and 4 squamous cell carcinomas. In the AB-treated males, 14 (28%; $P < 0.006$) developed 22 neoplasms of the forestomach. Of these, 11 mice had 13 squamous cell papillomas and 3 mice developed 5 squamous cell papillomas and 4 squamous cell carcinomas.

In the untreated controls, 2 (4%) males developed 2 squamous cell papillomas of the forestomach.

Macroscopically and histologically these lesions were similar to those described earlier in other experiments in this laboratory (16).

Tumors of Liver. Of the AB-treated females, 4 (8%; $P < 0.07$) developed benign hepatomas, while in the AB-treated males, 6 (12%; $P < 0.06$) had benign hepatomas.

In the untreated controls one male mouse had a liver tumor, which was classified as a benign hepatoma.

Grossly and histopathologically the liver tumors were similar to those lesions found and described under other experimental conditions in this laboratory (17).

Tumors of Lungs. Of the AB-treated females, 20 (40%) developed 24 tumors of this organ. Of these, 9 mice had 10 adenomas, 8 mice had 8 adenocarcinomas, and 3 mice developed 3 adenomas and 3 adenocarcinomas. In the AB-treated males, 31 (62%; $P < 0.01$) developed 54 lung tumors. Of these, 18 mice had 25 adenomas, 7 mice had 10 adenocarcinomas, and 6 mice developed 12 adenomas and 7 adenocarcinomas.

In the untreated controls, 13 females (26%) developed 13 tumors of this organ. Of these, 6 mice had 6 adenomas and 7 mice developed 7 adenocarcinomas. In the males of the untreated group, 17 (34%) mice developed 34 lung tumors. Of these, 8 mice had 9 adenomas, 5 mice had 9 adenocarcinomas, and 4 mice developed 10 adenomas and 6 adenocarcinomas.

Macroscopically and histologically these tumors were similar to those described previously in this laboratory (18, 19).

Other Tumors. In a number of instances, other types of tumors were also found in the treated groups shown in Table 2. Since these lesions occurred in low incidences, their appearance cannot be attributed to the treatment.

DISCUSSION

The present study shows that p.o. administration to 6-week-old Swiss mice of the fresh, uncooked, cultivated mushroom of commerce, AB, for 3 days, followed by semisynthetic diet for 4 days each week for life induced tumors of bone, the forestomach, liver, and lungs. The treatment gave rise to statistically significant incidences of tumors in these 4 tissues, with the exception of the lungs in the female mice. In addition, AB treatment increased the incidence of blood vessel tumors in both sexes and also lung tumors in females. These increases (blood vessel tumors in both sexes and lung tumors in females), however, were found to be statistically not significant. Statistical analysis was carried out by using Fischer's Exact Test for 2×2 tables (20). Light microscopic examination of the lesions revealed the typical appearance of osteomas and osteosarcomas, squamous cell papillomas and carcinomas of the forestomach,



Fig. 1. *Agaricus bisporus*, the cultivated mushroom of commerce in all countries having a temperate climate. Gross specimen.




Fig. 2. The cultivation and harvesting of mushrooms or champignons *Agaricus bisporus* are performed in an up-to-date-enclosed environment. Gross picture.

Table 1 Treatment and survival rates in AB-treated and control Swiss mice

Group	Treatment	Initial no. and sex of mice	No. of survivors at age (wk)															
			10	20	30	40	50	60	70	80	90	100	110	120	130	140	150	160
1	AB p.o. for 3 days each wk for life	50, F	50	50	49	49	48	46	44	43	41	32	18	9	5			
		50, M	50	50	50	50	50	50	45	41	34	30	20	10	7	3	1	
2	Untreated controls	50, F	50	50	50	50	50	48	47	43	33	27	15	7	2	1		
		50, M	50	48	48	47	46	44	43	40	35	26	17	10	4	3	1	

Table 2. Tumor distribution in AB-treated and control Swiss mice

Group	Treatment	Effective no. and sex of mice	Animals with tumors of												
			Bone			Forestomach			Lungs			Liver			
			No.	%	Av. age at death and range (wk)	No.	%	Av. age at death and range (wk)	No.	%	Av. age at death and range (wk)	No.	%	Av. age at death and range (wk)	
1	AB p.o. for 3 days each wk for life	50, F	8	16	110 (63-125)	19	38	90 (22-138)	20	40	107 (46-138)	4	8	135 (132-138)	8 malignant lymphomas (53, 74, 102, 107, 107, 113, 115, 133) ^a 5 granulosa cell tumors (107, 117, 127, 133, 138) 3 angiosarcomas in livers (96, 96, 110) 3 angiosarcomas in livers (102, 105, 114) 2 angiosarcoma in ovaries (109, 135) 1 angiosarcoma in subcutis (107) 1 carcinoma of breast (102) 1 adenoma of glandular stomach (101) 1 adenoma of Langerhans islands (118) 1 esthesioneuroepithelioma (109)
50, M	8	16	101 (86-113)	14	28	109 (69-142)	31	62	113 (62-153)	6	12	119 (104-142)	5 malignant lymphomas (67, 85, 103, 115, 117) 5 angiosarcomas in livers (105, 108, 110, 112, 133) 1 angiosarcoma in mesenterium (71) 1 angiosarcoma in spleen and epididymis (138) 1 angiosarcoma in liver and epididymis (147) 1 angioma in spleen (123) 1 angioma in liver (110) 1 adenocarcinoma of duodenum (110) 1 adenocarcinoma of gallbladder (104) 1 adrenal cortical adenoma (153) 1 adenoma of Langerhans islands (153)		
2	Untreated controls	50, F													11 malignant lymphomas (67, 78, 80, 83, 89, 90, 93, 105, 106, 112, 120) 3 adenocarcinomas of breasts (105, 106, 114) 2 fibrosarcomas, s.c. (97, 109) 1 fibroma, s.c. (141) 2 granulosa cell tumors (77, 126) 1 adenoma of cecum (78) 1 adrenal cortical adenoma (105) 1 carcinoma of skin (109) 1 adenocarcinoma of skin (103) 1 angioma in liver (77) 1 angioma in subcutis (84) 1 angioma in uterus (59) 1 angioma in ovary (112) 1 angiosarcoma in subcutis (119) 1 angiosarcoma in spleen and subcutis (93) 1 angiosarcoma in uterus and fat (123)
50, M			2	4	108 (92-125)	17	34	95 (63-150)	1	2	106	5 malignant lymphomas (84, 96, 113, 119, 129) 1 malignant histiocytoma (76) 2 angiosarcomas in livers (97, 124) 1 angiosarcoma in liver and spleen (117) 1 angiosarcoma in liver and fat (94) 1 angioma in liver (103) 1 adenoma of glandular stomach (150) 1 fibromyosarcoma in seminal vesicle (149)			

^a Numbers in parentheses, age at death in weeks.

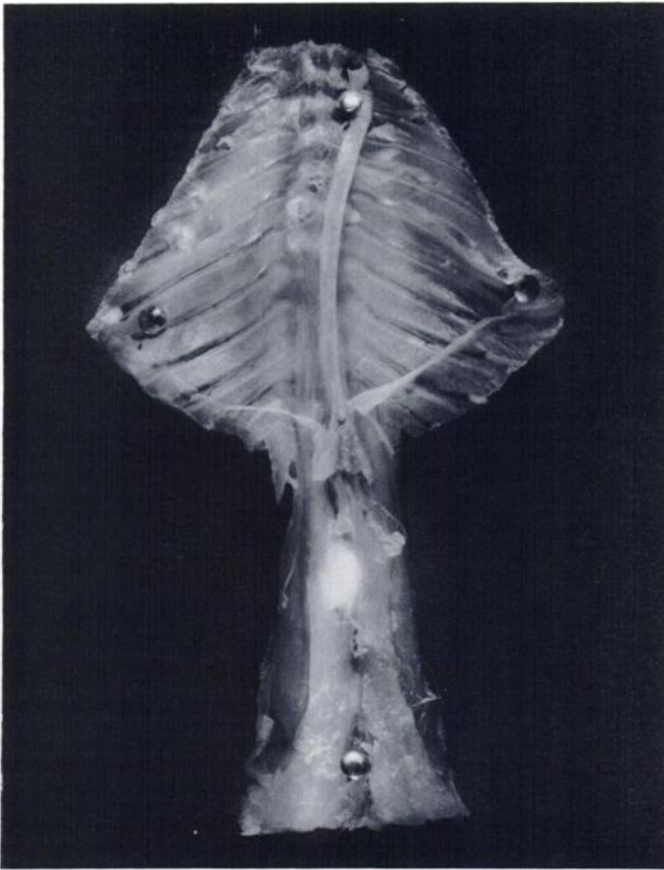


Fig. 3. Osteoma in a mouse treated with AB. The whitish, oval-shaped, smooth-surfaced growth is located in the abdominal spine area. Gross specimen, $\times 2$.

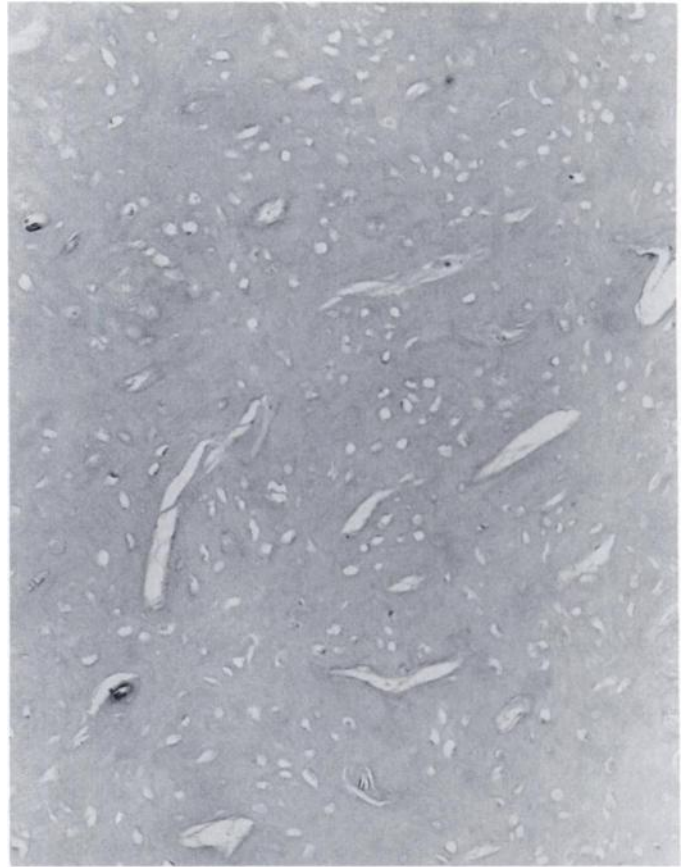


Fig. 4. Same tumor as in Fig. 3. The benign tumor consists of an irregular pattern of ossified trabeculae. Note some of the osteoblasts and vascular elements in the lesion. H & E, $\times 200$.

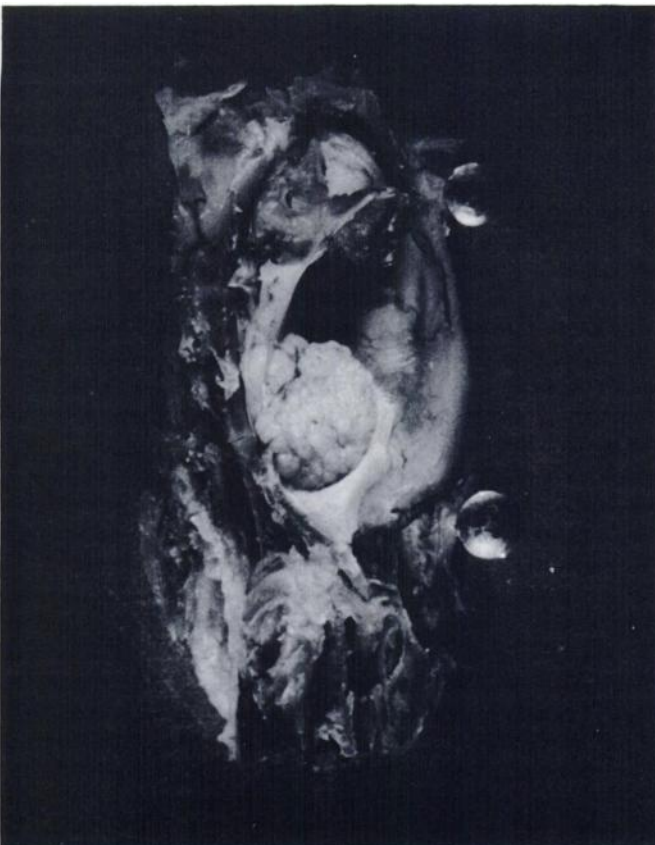

Fig. 5. Osteosarcoma in a mouse treated with AB. The white, round-shaped, granular-surfaced growth is located in the lower caudal part of the skull. Gross specimen, $\times 5$.

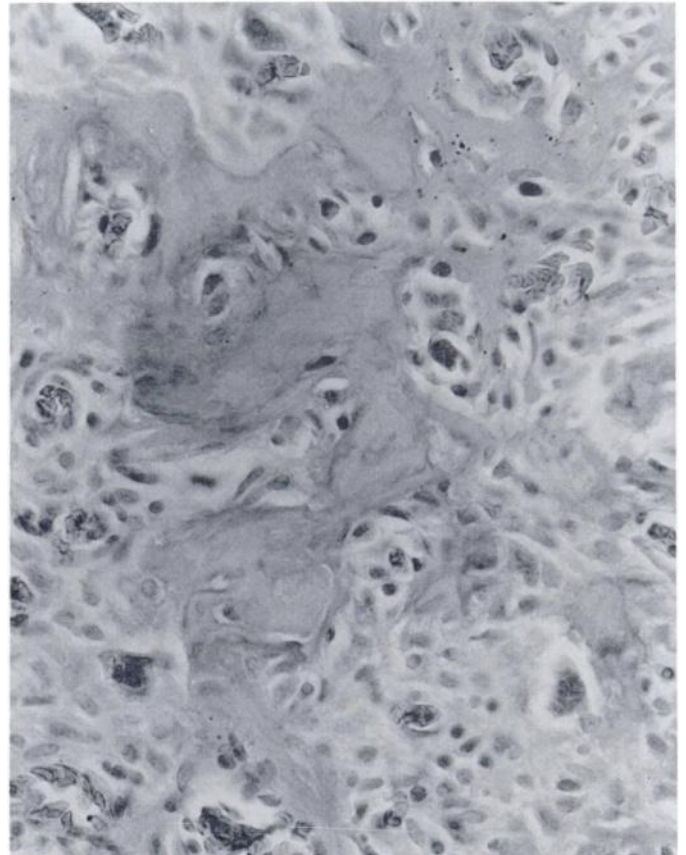


Fig. 6. Same tumor as in Fig. 5. The lesion exhibits extensive osteoid tissue formation together with large masses of spindle- or oval-shaped cells representing the sarcomatous element. H & E, $\times 400$.

benign hepatomas, and adenomas and adenocarcinomas of the lungs.

It is of interest to compare the tumorigenic spectra of the current AB feeding with findings from earlier experiments, which used certain chemical ingredients of AB. P.o. administration of the *N'*-acetyl derivative of 4-(hydroxymethyl)phenylhydrazine induced tumors in the lungs and blood vessels of Swiss mice (8), whereas the tetrafluoroborate and sulfate forms of 4-(hydroxymethyl)benzenediazonium ion, when given s.c. elicited the development of skin and s.c. tissue tumors (9, 11); also, when administered p.o., the tetrafluoroborate form caused glandular stomach tumors in Swiss mice (10). Even though tumorigenesis studies with the other ingredients, *p*-hydrazinobenzoic acid HCl (21) and β -*N*-[γ -L(+)-glutamyl]-4-carboxyphenylhydrazine (22) are still in progress, and another component, agaritine, yielded negative results (23, 24), it is clear that the finding of bone, forestomach, and liver tumors in the AB-fed mice is thus far unique and not encountered in experiments using some of the chemical constituents of AB. This should not come as a surprise, since the mushroom may contain thousands of chemicals and our research is still at a relatively early phase.

Consumption of the AB mushroom in the United States is substantial and shows an increasing trend, because many people have converted to diets containing large amounts of mushrooms to lose weight. The estimated annual consumption of AB, which included domestic production and imports in the United States, was over 340 million kg in 1984–1985 (25, 26). It is also known that in certain parts of Europe, particularly in France, the per capita consumption of AB is higher than in the United States.

In conclusion, the uncooked, fresh, cultivated mushroom AB was found to be carcinogenic in laboratory animals. Since a segment of the human population in North America, Europe, and elsewhere eats this fungus in raw forms (salads, etc.), the present finding could carry practical implications.

ACKNOWLEDGMENTS

The authors wish to thank Dr. Kashinath Patil for his excellent statistical assistance.

REFERENCES

- Levenberg, B. An aromatic diazonium compound in the mushroom *Agaricus bisporus*. *Biochim. Biophys. Acta*, **63**: 212–214, 1962.
- Kelly, R. B., Daniels, E. G., and Hinman, J. W. Agaritine: isolation, degradation, and synthesis. *J. Org. Chem.*, **27**: 3229–3231, 1962.
- Levenberg, B. Isolation and structure of agaritine, a γ -glutamyl-substituted arylhydrazine derivative from Agaricaceae. *J. Biol. Chem.*, **239**: 2267–2273, 1964.
- Ross, A., Nagel, D., and Toth, B. Occurrence, stability and decomposition of β -*N*-[γ -L(+)-glutamyl]-4-hydroxymethylphenylhydrazine (agaritine) from the mushroom *Agaricus bisporus*. *Food Chem. Toxicol.*, **20**: 903–907, 1982.
- Ross, A. E., Nagel, D., and Toth, B. Evidence for the occurrence and formation of diazonium ions in the *Agaricus bisporus* mushroom and its extracts. *J. Agric. Food Chem.*, **30**: 521–525, 1982.
- Chauhan, Y., Nagel, D., Issenberg, P., and Toth, B. Identification of *p*-hydrazinobenzoic acid in the commercial mushroom *Agaricus bisporus*. *J. Agric. Food Chem.*, **32**: 1067–1069, 1984.
- Chauhan, Y., Nagel, D., Gross, M., Cerny, R., and Toth, B. Isolation of *N*²-[γ -L(+)-glutamyl]-4-carboxyphenylhydrazine in the cultivated mushroom *Agaricus bisporus*. *J. Agric. Food Chem.*, **33**: 817–820, 1985.
- Toth, B., Nagel, D., Patil, K., Erickson, J., and Antonson, K. Tumor induction with the *N'*-acetyl derivative of 4-hydroxymethylphenylhydrazine, a metabolite of agaritine of *Agaricus bisporus*. *Cancer Res.*, **38**: 177–180, 1978.
- Toth, B., Patil, K., and Jae, H-S. Carcinogenesis of 4-(hydroxymethyl)benzenediazonium ion (tetrafluoroborate) of *Agaricus bisporus*. *Cancer Res.*, **41**: 2444–2449, 1981.
- Toth, B., Nagel, D., and Ross, A. Gastric tumorigenesis by a single dose of 4-(hydroxymethyl)benzenediazonium ion of *Agaricus bisporus*. *Br. J. Cancer*, **46**: 417–424, 1982.
- Lawson, T., Chauhan, Y. P., and Toth, B. Cultivated mushroom hydrazines: analysis, metabolism and carcinogenesis. *Proc. Am. Assoc. Cancer Res.*, **26**: 104, 1985.
- Rogan, E. G., Walker, B. A., Gingell, R., Nagel, D., and Toth, B. Microbial mutagenicity of selected hydrazines. *Mutat. Res.*, **102**: 413–424, 1982.
- Sterner, O., Bergman, R., Kesler, E., Magnusson, G., Nilson, L., Wickberg, B., Zimerson, E., and Zettenberg, G. Mutagens in larger fungi. I. Forty-eight species screened for mutagenic activity in the *Salmonella*/microsome assay. *Mutat. Res.*, **101**: 269–281, 1982.
- National Research Council, Subcommittee on Laboratory Animal Nutrition. Nutrient requirements of laboratory animals, pp. 43–53. Washington, DC: National Academy of Sciences, 1978.
- Evans, R. W. Histological appearances of tumours, pp. 164–216. Baltimore: The Williams & Wilkins Co., 1968.
- Toth, B., Tomatis, L., and Shubik, P. Multipotential carcinogenesis with urethane in the Syrian golden hamster. *Cancer Res.*, **21**: 1537–1541, 1961.
- Toth, B., Magee, P. N., and Shubik, P. Carcinogenesis study with dimethylnitrosamine administered orally to adult and subcutaneously to newborn BALB/c mice. *Cancer Res.*, **24**: 1712–1721, 1964.
- Toth, B., and Shimizu, H. 1-Carbamyl-2-phenylhydrazine tumorigenesis in Swiss mice. Morphology of lung adenomas. *J. Natl. Cancer Inst.*, **52**: 241–251, 1974.
- Toth, B. Formylhydrazine carcinogenesis in mice. *Br. J. Cancer*, **37**: 960–964, 1978.
- Armitage, P. *Statistical Methods in Medical Research*, pp. 136–138. Oxford, England: Blackwell Scientific Publications, Ltd., 1971.
- Toth, B., and Chauhan, Y. P. Induction of arteriosclerosis in mice by *p*-hydrazinobenzoic acid hydrochloride (HBA) of *Agaricus bisporus*. *Fed. Proc.*, **44**: 523, 1985.
- Toth, B. Hydrazines, edible mushrooms and cancer. I. International Conference on Anticancer Research, Loutraki, Greece (Abstracts) p. 611. 1985.
- Toth, B., Raha, C. R., Wallcave, L., and Nagel, D. Attempted tumor induction with agaritine in mice. *Anticancer Res.*, **1**: 255–258, 1981.
- Toth, B., and Sornson, H. Lack of carcinogenicity of agaritine by subcutaneous administration in mice. *Mycopathology*, **85**: 75–79, 1984.
- United States Department of Agriculture, Crop Reporting Board, Statistical Reporting Service, Mushrooms, Washington, DC, Vg 2-1-2, 1985.
- United States Department of Agriculture, Foreign Agricultural Service, Agricultural Imports, Washington, DC, Report 1, 1, 1985.
- Toth, B. Induction of cancer in mice by feeding the fresh mushroom *Agaricus bisporus* (AB). *Proc. Am. Assoc. Cancer Res.*, **27**: 90, 1986.