

Transplacental Induction of Gonadal Tumors in Rats by a Nitrosamine¹

Parviz M. Pour

The Eppley Institute for Research in Cancer and Department of Pathology and Microbiology, University of Nebraska Medical Center, Omaha, Nebraska 68105

ABSTRACT

Ovarian and testicular tumors were induced in the offspring (F₁ generation) of MRC rats that received single or multiple doses of *N*-nitrosobis(2-oxopropyl)amine on the 14th, 18th, and/or 20th days of pregnancy. The ovarian tumor incidence was significantly higher (46%) in the F₁ generation exposed to the carcinogen a single time at the 18th day of gestation, when compared to those exposed at the 14th ($P < 0.005$) or 20th days ($P < 0.025$), and was highest in those exposed to *N*-nitrosobis(2-oxopropyl)amine repeatedly (at the 14th through 20th days of gestation). Morphologically ovarian tumors were of a mixed stromal cell-coelomic type. Testicular tumors were of mixed Leydig cell-glandular types and occurred in a higher incidence in the F₁ generation exposed to *N*-nitrosobis(2-oxopropyl)amine at the 14th through 20th day of gestation, compared with those exposed to the carcinogen at other times of the gestation period ($P < 0.0005$). This is the first report of transplacental gonadal tumor induction by a nitrosamine.

INTRODUCTION

Ovarian tumors are the fifth most common cause of cancer death and are the sixth most common neoplasm in females in the United States (1). Testicular tumors, while relatively rare (1), rank fourth among causes of death due to cancer in younger men. These diseases are of unknown etiology. However, environmental, genetic, and hormonal factors have been suggested in their development (2).

While the spontaneous development of ovarian tumors is uncommon in mammals other than humans, testicular neoplasms occasionally occur in dogs, horses, mice, and rats (2).

Both ovarian and testicular tumors have been experimentally induced in adult rats or mice by selected polycyclic aromatic hydrocarbons, X-rays, sex hormones, certain metals, and transplantation of gonads into the spleen of gonadectomized animals (2-8). Only sex hormones have been reported to induce gonadal tumors transplacentally (9). Among many carcinogenic nitrosamines tested, only a few have shown to induce transplacentally a very low incidence of granulosa cell tumors (10). All induced neoplasms, however, have been of types uncommon in humans, *i.e.*, ovarian granulosa-theca cell neoplasms and/or testicular interstitial (Leydig) cell tumors. We report, for the first time, the transplacental induction in rats by a nitrosamine of ovarian and testicular tumors of mixed epithelial-stromal types, some components of which resemble human neoplasms.

MATERIALS AND METHODS

Outbred, Wistar-derived, 8-10-week-old female MRC rats from the Eppley Institute colony were used. The rats were caged individually on granular cellulose bedding, maintained under standard laboratory conditions, and given Wayne pelleted diet (Allied Mills, Chicago, IL) and water *ad libitum*.

The females were mated with healthy 8-10-week-old rats from the Eppley Institute colony. The day of mating was considered the first day of gestation and was ascertained by examination of vaginal smears.

Received 1/6/86; revised 3/31/86; accepted 4/30/86.

The costs of publication of this article were defrayed in part by the payment of page charges. This article must therefore be hereby marked *advertisement* in accordance with 18 U.S.C. Section 1734 solely to indicate this fact.

¹ This investigation was supported by Program Project Grant No. 1 P01 CA 25100 from the National Cancer Institute, NIH, Department of Health and Human Services.

BOP² was synthesized as described (11) and dissolved in physiological saline shortly before s.c. injection at either 10 or 20 mg/kg body weight. Pregnant rats (F₀ generation) were divided into 5 groups of 10 rats each and given a single BOP injection (20 mg/kg body weight) at days 14 (group 1), 18 (group 2), or 20 (group 3) of gestation. Group 4 received 3 BOP injections (each at 10 mg/kg body weight) at the 14th, 18th, and 20th days of their pregnancy. Group 5 consisted of controls and received saline injection only 3 times, as did group 4 rats. BOP-treated (group 6-F₀) and saline-treated (group 7-F₀) dams were also kept for life. Data on the dams exposed to BOP at different times during pregnancy were pooled, since no differences were found in their responses to BOP.

Litters (F₁ generation) were checked carefully for external abnormalities and separated from their mothers at 4 weeks of age. Animals were maintained under consistent laboratory conditions in groups of 5 by sex and observed for life. They were inspected twice daily and weighed biweekly.

After their spontaneous deaths, the rats were completely necropsied and their organs were fixed in 10% buffered formalin. The ovaries, uterus, vagina, testes, prostate, coagulating gland, seminal vesicles, and paraurethral glands were processed for histology by conventional methods and stained with hematoxylin and eosin. Findings from other tissues are to be reported elsewhere. Tumors were histologically diagnosed by WHO classification methods (12, 13) and the χ^2 test was used for statistical evaluation. Latency refers to the first histological detection of tumors and the durations stated correspond to the age of the animal.

RESULTS

There were no abnormalities in animal number, sizes, weights, growth rates, and behavior.

The number of rats per group, treatment, average survival, body weights at autopsy, and ovarian tumor incidence are presented in Table 1. Table 2 gives morphological information on ovarian tumors and Table 3 gives the incidence of testicular neoplasms. There were no differences in body weights and survival rates, except among the females in groups 2-F₁ and 4-F₁ and in the males of group 4, all of which had shorter survival times due to ovarian and testicular tumors, respectively.

Ovarian Tumors

Significantly more rats in groups 2-F₁ and 4-F₁ developed neoplasms than did those in the other F₁ groups. In 25% of the BOP-exposed F₁ generation, ovarian tumors (Table 2) were the only induced neoplasms. Among these, 21% were in group 4-F₁. Grossly, the tumors were yellow or brown-yellow lobulated nodules, 3 to 90 mm in diameter. The largest nodules were found in groups 2-F₁ (20 mm in diameter on the average) and 4-F₁ (average size, 29 mm in diameter). Those of the other groups averaged 10-12 mm in diameter. Tumors were bilateral in 0, 28, 14, 32, 0, and 50% of the rats in groups 1-F₁, 2-F₁, 3-F₁, 4-F₁, 5-F₁, and 6-F₀, respectively, and were found earlier in group 4-F₁ (at 46 weeks) than in the other groups (at 56-99 weeks).

The histological types of ovarian lesions, their sites, number, and sizes are summarized in Table 2. In the F₁ generation of BOP-exposed rats 80% of the tumors were of mixed stromal and epithelial types. Only 2 (8%) of the group 6-F₀ rats had

² The abbreviation used is: BOP, *N*-nitrosobis(2-oxopropyl)amine.

Table 1 Experimental results and ovarian tumor incidence in MRC rats from F₀ and F₁ generations

Time of BOP treatment ^a	Group	No. of rats	Final body wt (g ± SD)	Av. survival (wk ± SD)	Incidence of tumors ^b (%)
14th	1-F ₁	42	342 ± 63	92 ± 14	1 (2)
18th	2-F ₁	39	343 ± 75	88 ± 15	18 (46) ^{c, d}
20th	3-F ₁	41	360 ± 60	93 ± 14	7 (17) ^e
14-20th	4-F ₁	39	327 ± 72	87 ± 16	25 (60) ^{c, f}
0 (F ₁)	5-F ₁	42	345 ± 66	94 ± 10	2 (5)
(F ₀) ^g	6-F ₀	68	335 ± 70	91 ± 11	11 (16)
0 (F ₀) ^h	7-F ₀	14	329 ± 62	91 ± 7	0

^a BOP was given at days of pregnancy indicated.

^b Statistical comparison was made among groups 1-F₁ to 5-F₁ and between 6-F₀ and 7-F₀.

^c P < 0.005 compared with 1-F₁ and 5-F₁.

^d P < 0.025 compared with 3-F₁.

^e P < 0.05 compared with 1-F₁.

^f P < 0.001 compared with 3-F₁.

^g Treated dams (initially 10 rats each) from groups 1-F₁ to 4-F₁.

^h Untreated dams.

this mixed type of neoplasm, and there were none in the group 5-F₀ rats. However, 32% of the tumors in group 4-F₁ were primarily of a coelomic type. They also displayed wide variations in cellular and architectural patterns and included papillary neoplasms (Figs. 1 and 2) of serous and less frequently of mucinous types. Tumors of an endometrioid type were not seen. Invasion of surrounding tissue and/or metastases (to liver and lungs) were considered as the only criteria for malignancy. Malignancies included the single tumor in group 1-F₁, 4 of 18 (22%) in group 2-F₁, 9 of 25 (36%) in group 4-F₁, and 4 of 11 (36%) in group 6-F₀.

Bilateral atrophy, oocyte depletion, proliferation and invagination of surface germinal cell layers, with formation of minute tumors and cysts, were found in all BOP-exposed F₁ rats without tumors and in the contralateral ovaries of rats with unilateral neoplasms, but not in the BOP-exposed F₀ generation (group 5-F₀).

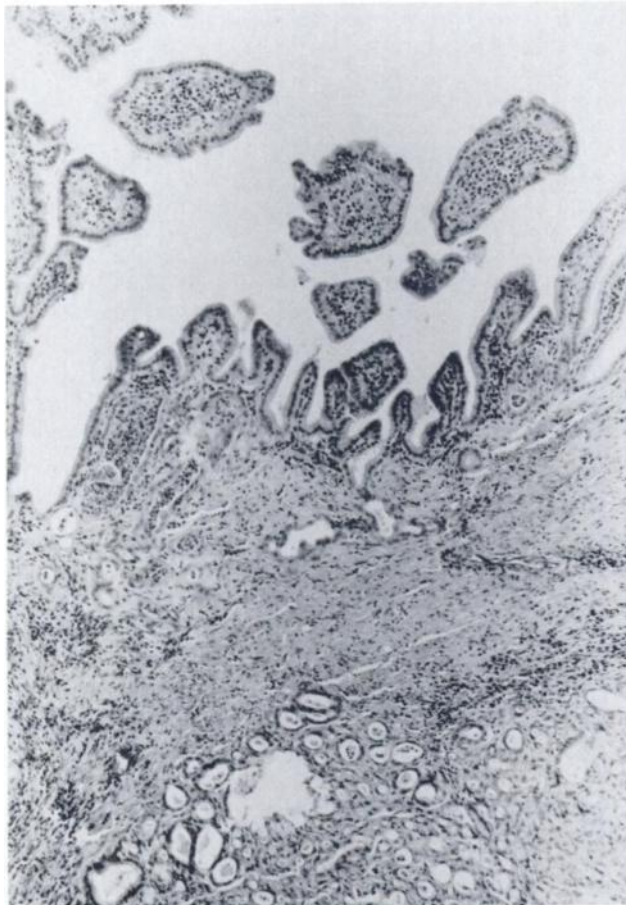


Fig. 1. Mixed papillary serous (top) and microglandular ovarian carcinoma in offspring of rats treated with BOP at the 18th day of pregnancy. H & E, × 40.

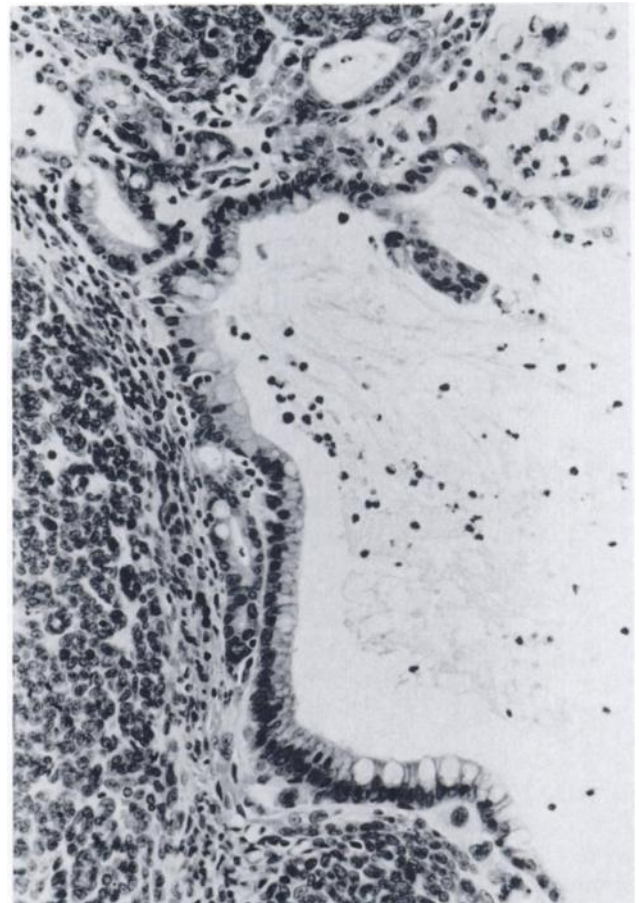


Fig. 2. Mixture of stromal (left and bottom) and glandular types of ovarian tumors in the offspring of BOP-treated female rats. Note the presence of goblet-like cells populating the glandular structure. H & E, × 200.

Table 2 Site, size, and morphology of ovarian tumors induced in the offspring (F₁) of rats treated with BOP at different gestation periods (F₀)

Group	No. of tumors	Location in ovaries			Size (mm) (av.)	Tumor histology (no.)
		Left	Right	Bilateral		
1-F ₁	1	1	0	0	30	Adenomatous ^a (androblastoma?) (1)
2-F ₁	18	10	3	5	3-70 (20 ± 17)	Luteoma (17), adenomatous ^a (1)
3-F ₁	7	3	3	1	8-16 (10 ± 5)	Luteoma (6), granulosa cell tumor (1)
4-F ₁	25	8	9	8	5-90 (29 ± 20)	Luteoma (11), granulosa cell tumor (6), adenomatous ^a (8)
5-F ₁	2	2	0	0	6-15 (10 ± 6)	Thecoma (2)
6-F ₀	11	0	6	5	5-34 (12 ± 11)	Luteoma (2), granulosa-theca cell tumor (2), adenomatous (4), androblastoma (1), angiosarcoma (2)
7-F ₀	0	0	0	0		

^a Includes cystic-papillary, serous, and mucinous tumors.

Table 3 Data relative to the experimental groups, body weight, survival of rats, and incidence of testicular tumors

Group	Day of gestation for BOP treatment	No. of rats	Av. body wt (% \pm SD)	Av. survival (wk \pm SD)	Tumor incidence	
					No.	%
1	14th	41	532 \pm 100	93 \pm 15	13	32 ^a
2	18th	35	522 \pm 100	92 \pm 14	11	31 ^a
3	20th	38	550 \pm 135	97 \pm 6	11	29 ^b
4	14th–20th	36	455 \pm 100	91 \pm 13	19	53 ^c
5	0	40	505 \pm 120	85 \pm 12	3	8

^a $P < 0.025$.

^b $P < 0.05$.

^c $P < 0.0005$.

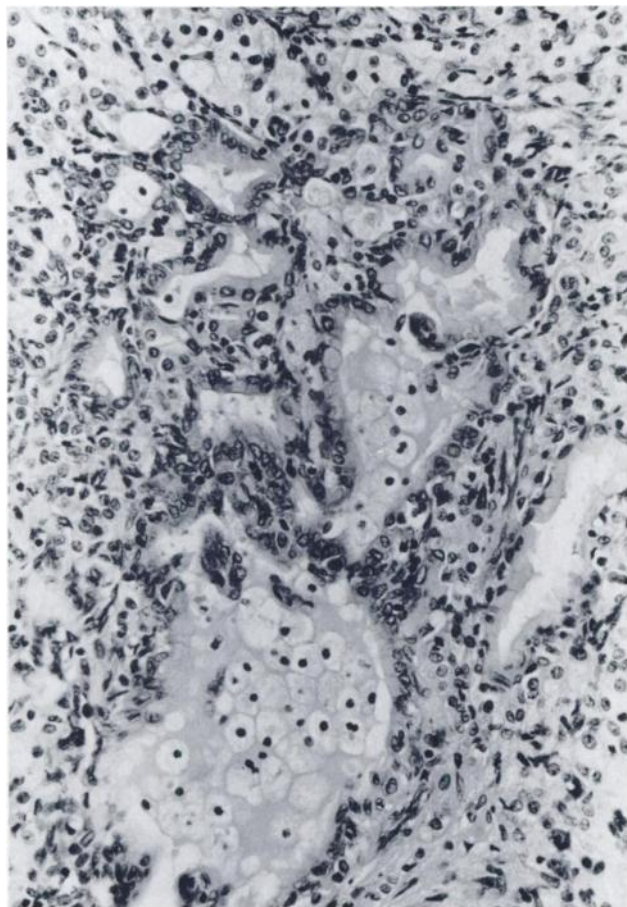


Fig. 3. Mixture of glands and stromal cells in a testicular tumor of offspring from rats exposed to BOP during the 14th–20th days of pregnancy. The glandular cells are of a mucinous type. H & E, \times 200.

The incidence of uterine neoplasms (polyps and adenocarcinomas) was lower in the BOP-exposed F_1 generation (14–20%) than in their control 5- F_1 groups (28%) or in the dams (6- F_0 group, 41–50%).

The vaginas from most of the BOP-exposed F_1 generation exhibited keratinized epithelium. Most of these rats also had distended uterine horns not observed in the dams.

Other genital tract lesions in the rats were within the spectrum of spontaneously occurring alterations in this rat colony.

Testicular Tumors

The testicular tumor incidence (Table 3) in all BOP-exposed F_1 generation rats was significantly higher than that in controls and was highest in group 4 ($P < 0.0005$). The earliest tumor was found at 82 weeks in the experimental groups and at 93 weeks in control rats. In 51% of the experimental rats, testicular tumors were the only induced neoplasms.

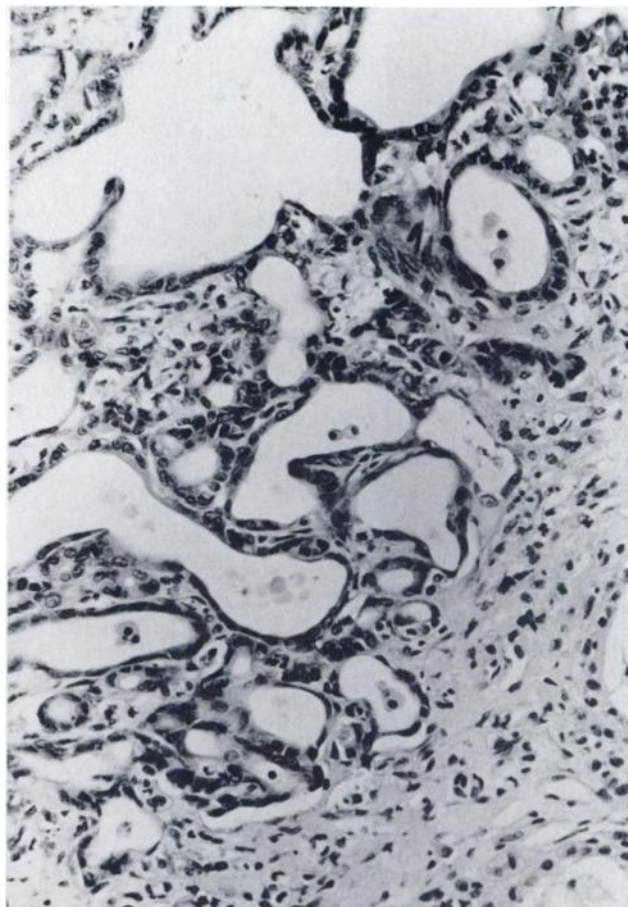


Fig. 4. Area of a testicular tumor, showing glandular structures of various sizes and shapes. Cells lining the glands are flat or low cuboidal. H & E, \times 200.

Grossly, tumors were firm, homogeneous, yellow or mahogany-brown nodules of various sizes (3–20 mm in diameter). These nodules sometimes displayed small, fluid-filled cysts, hemorrhages, white stripes, and/or necrosis. Lesions were often multiple and usually were well demarcated. They occasionally replaced entire areas of tissue. Eight of 54 tumors were bilateral but demonstrated no preference by group.

Many tumors in the BOP-exposed F_1 rats were of a Leydig cell type, as were all neoplasms in controls, and were similar to previously reported spontaneous or induced tumors (7). However, contrary to findings in controls, neoplasms in all BOP-exposed F_1 groups commonly had focal or multifocal epithelial cell components in the form of mixed stromal-glandular elements. The glands were often distorted, showed variations in size and shape, and were covered either by flat, cuboidal cells or by cylindrical cells (Figs. 3 and 4) and, based on their irregular delineation and extension into neighboring tissue, they were judged to be malignant. The glandular elements were most probably ductal differentiation of Sertoli cells, as could be discerned in some areas.

In most BOP-exposed F_1 groups, but not in any control group rats, the ipsilateral or contralateral testes presented either advanced atrophy with cystic distention of seminiferous tubules, focal or multifocal proliferation of interstitial cells, calcification, or diffuse stromal fibrosis. None of these patterns was found in control rats.

Other sex organ lesions that occurred in the experimental rats and not in controls included squamous cell metaplasia of the prostate gland (found in a 21% incidence in group 2 and in a 4–10% incidence in other groups), 1 adenocarcinoma of the

coagulating glands, and 1 rhabdomyosarcoma of the vas deferens. The latter 2 lesions occurred in 1 rat each from group 2.

Tumors of other sites were hepatocellular adenomas, with their highest incidence in females of group 2-F₁ (59%), compared to the other groups (10–45%) and to controls (5%), and hepatocellular carcinomas (21% in females and 14% in males of group 2-F₁, 5% in females and 13% in males of group 3-F₁, 5% in females and 3% in males of group 4-F₁, and none in group 1-F₁ and the control group, 5-F₁). No other tumors attributable to BOP effects were found.

DISCUSSION

The present study demonstrates the transplacental induction, for the first time, of gonadal tumors by a nitrosamine, BOP. Thus far, only sex hormones have been shown to induce gonadal tumors transplacentally (9). The 18th day of gestation (which would correspond to the 3rd to 5th lunar months of human gestation) was found to be the optimal stage for ovarian carcinogenesis by BOP. Also, multiple injections of low doses of BOP from the 14th to 20th days of gestation proved more carcinogenic to both the ovaries and testes than did single doses. The greater effect of the carcinogen on the gonads at the 18th day of gestation and after repeated treatment was also evident because of larger tumor numbers, their malignant nature, and their greater size and because of more selective gonadal tumor induction. Furthermore, these tumors displayed a wide range of histological patterns and were in part or predominantly of either a coelomic type (ovarian tumors) or a glandular cell type (testicular tumors), both of which are the most common human gonadal tumor types.

The induced ovarian neoplasms in the present study histologically resembled in many aspects those induced in the same or other species by other agents (4–6, 13, 14). Also, as in other models, we found ovarian atrophy, depletion of oocytes, a sparsity or absence of follicles, microcystic formation, thecosis or focal accumulation of luteinized cells, and formation of luteomas, as well as focal or multifocal distention, inflammation of uterine horns, and signs of estrogenization, based on findings in vaginal epithelium.

We also observed, as with the other models, a proliferation of germinal epithelium, their invagination, and their apparent gradual neoplastic change. This is consistent with the generally accepted concept that all ovarian tumors derive from the multipotent surface (germinal) epithelial cells (14). Apparently in animals, e.g., canines, the response of ovarian cells to any given tumor-causing agent is unique and is limited primarily to the development of germ cell tumors, which are uncommon in humans. However, in the present study, in contrast to reports with other models, a differentiation toward coelomic epithelium, the origin of most human ovarian cancer, was evident in a significant number of cases, and this finding was particularly common and numerous in rats exposed to BOP at the 18th day of gestation. Hence it appears that not only are cellular differentiation and the stage of development important in the phenotypic expression of ovarian tumors but also the nature of the carcinogen. This possibility is particularly interesting because it conflicts, to some extent, with the concept that ovarian cancer induction by any tumor-inducing agent is due to a direct or an indirect effect on the pituitary gland and is mediated through the stimulation of gonadotropin secretion (6).

Although questions relative to the mode of action of BOP in

ovarian carcinogenicity cannot be answered by the present study, it should be emphasized that BOP or other β -oxidized relative compounds show a remarkable affinity for sex organs or sex organ-dependent tissues, such as the thyroid gland, vagina, prostate, flank organ, ovaries, and testes (15–17). It is also remarkable that BOP did not induce in the offspring thyroid and renal neoplasms, the major target tissue of this carcinogen in adult rats, but instead preferentially affected ovarian tissue. It is difficult to assess whether or not the transplacental route of carcinogen action also applies to human oncology, but this possibility should certainly be considered (18, 19), especially since ovarian cancer frequently occurs in individuals having a family history of colon, lung, ovarian, and prostatic cancer. All of the organs affected in the latter case, incidentally, are target tissues for BOP in rats (17). Moreover cigarette smoke, which is known to contain carcinogenic nitroso compounds, has been linked to ovarian cancer (18). Nevertheless the present experimental results offer a model to elucidate the factors responsible for induction of ovarian cancer by chemical carcinogens.

REFERENCES

1. Cancer Statistics 1985. *Ca—Cancer J. Clin.*, 35: 19–35, 1985.
2. Mostofi, F. K., and Price, E. B. *In: Tumors of the Male Genital System, Atlas of Tumor Pathology, 2nd Series, Fascicle 8.* Washington, DC: Armed Forces Institute, 1973.
3. Carter, R. L., and Ird, E. A. Tumors of the ovary. *In: V. Turusov (ed.), Pathology of Tumors in Laboratory Animals, IARC Scientific Publication No. 6, Vol. 1, pp. 189–200.* Lyon, France: International Agency for Research in Cancer, 1976.
4. Howell, J. S., Marchand, J., and Orr, J. W. The induction of ovarian tumors in mice with 9,10-dimethyl-1,2-benzanthracene. *Br. J. Cancer*, 8: 635–646, 1954.
5. Jabara, A. Canine ovarian tumors following stilbestrol administration. *Aust. J. Exp. Biol.*, 37: 549–566, 1959.
6. Jull, J. W., Streeter, D. J., and Sutherland, L. The mechanism of induction of ovarian tumors in the mouse by 7,12-dimethylbenz[*a*]anthracene. I. Effect of steroid hormones and carcinogen concentration *in vivo*. *J. Natl. Cancer Inst.*, 37: 409–418, 1966.
7. Mostofi, F. K., and Bresler, U. M. Tumors of the testes. *In: V. Turusov (ed.), Pathology of Tumors in Laboratory Animals, IARC Publication No. 6, Vol. 1, pp. 135–150.* Lyon, France: International Agency for Research on Cancer, 1976.
8. Sekiya, S., Endoh, N., Kiuuchi, Y., Katoh, T., Matsuura, A., Iwasawa, B., Takeda, B., and Takamizawa, H. *In vivo* and *in vitro* studies of experimental ovarian adenocarcinoma in rats. *Cancer Res.*, 39: 1108–1112, 1979.
9. Nomura, T., and Kanzaki, T. Induction of urogenital anomalies and some tumors in the progeny of mice receiving diethylstilbestrol during pregnancy. *Cancer Res.*, 37: 1099–1104, 1977.
10. Althoff, J., and Grandjean, C. *In vivo* studies in Syrian golden hamsters: a transplacental bioassay of ten nitrosamines. *Natl. Cancer Inst. Monogr.*, 51: 251–255, 1979.
11. Nagel, D., and Kupper, R. Synthesis of *N*-nitroso(2-oxo-propyl)amine and C¹⁴ analogue. *J. Labeled Compds.*, 18: 1081–1085, 1981.
12. Histologic Typing of Ovarian Tumors, Publication No. 9. Geneva: World Health Organization, 1973.
13. Histologic Typing of Testis Tumors, Publication No. 16. Geneva: World Health Organization, 1977.
14. Marchant, J. The effect of hypophysectomy on the development of ovarian tumors in mice treated with dimethylbenzanthracene. *Br. J. Cancer*, 15: 821–827, 1961.
15. Pour, P. M. Prostatic cancer induced in MRC rats by *N*-nitrosobis(2-oxopropyl)amine and *N*-nitrosobis(2-hydroxypropyl)amine. *Carcinogenesis (Lond.)*, 4: 49–55, 1983.
16. Pour, P. M., Althoff, J., Krüger, F. W., and Mohr, U. A potent pancreatic carcinogen in Syrian hamsters: *N*-nitrosobis(2-oxopropyl)amine. *J. Natl. Cancer Inst.*, 58: 1449–1453, 1977.
17. Pour, P. M., Salmasi, S., Runge, R., Gingell, R., Wallcave, L., Nagel, D., and Stepan, K. Carcinogenicity of *N*-nitrosobis(2-hydroxypropyl)amine and *N*-nitrosobis(2-oxopropyl)amine in MRC rats. *J. Natl. Cancer Inst.*, 63: 181–190, 1979.
18. Mattison, D. R. Smoking and industrial pollution, and their effects on menopause and ovarian cancer. *Lancet*, 2: 187–188, 1978.
19. West, R. O. Epidemiologic study of malignancies. *Cancer (Phila.)*, 19: 1001–1007, 1966.