

Imaging and Therapy of Small Cell Carcinoma Xenografts Using ¹³¹I-labeled Monoclonal Antibody SWA11¹

Alan Smith, Peter Groscurth, Robert Waibel, Gerrit Westera, and Rolf A. Stahel²

Division of Oncology, Department of Medicine, [A. S., R. W., R. A. S.], Division of Nuclear Medicine, Department of Medical Radiology [G. W.], University Hospital of Zurich, CH-8091 Zurich, and Department of Anatomy, University of Zurich [P. G.], Zurich, Switzerland

Abstract

The IgG2a monoclonal antibody SWA11 has been evaluated as a radioimmunotherapeutic agent for use in the treatment of small cell cancer of the lung. This antibody was initially selected for *in vivo* localization studies in a nude mouse model system because of its high affinity for the SW2 small cell cancer cell line *in vitro*. Following i.v. injection of ¹²⁵I labeled antibody into nude mice bearing SW2 xenografts good selective accumulation was observed with 10.5% of injected material/g of tumor. The level remained constant from day 2 to day 4 following injection. At day 4 the tumor:blood ratio was 7:1 and tumor:liver, tumor:kidney, and tumor:lung ratios were 17:1, 24:1, and 12:1, respectively. Initial radioimmunotherapeutic studies performed on established small cell cancer of the lung xenografts have shown reduction in tumor burden following a single injection of 300 μ Ci of ¹³¹I labeled SWA11 with no evidence of regrowth up to day 34 postinjection. Histological evaluation of treated tumors revealed large areas of necrosis and extensive fibrosis. A few residual cells of tumor origin could be observed and these displayed atypical morphology. The clonogenic potential of such cells remains to be determined by long term observation.

Introduction

The use of MAbs³ for diagnosis, imaging, and now RIT of malignant disease is an increasingly realistic objective (1-3). Clearly, in terms of RIT the nature of the disease chosen for attack must significantly affect the likelihood of success. SCC may be a particularly appropriate clinical objective for this therapeutic approach. SCC is a highly chemo- and radiosensitive condition and yet the prognosis for patients is very poor. Because of the metastatic nature of the disease a strong reliance is found on the use of chemotherapy as the first treatment modality. Although initially highly sensitive to this approach SCC is characterized by posttreatment emergence of chemoresistance. The residual form of the disease following first treatment, which is ultimately responsible for relapse, is widely dispersed, is radiosensitive, and exists as small cellular foci. Such characteristics encourage the application of RIT and when taking into consideration the short remission time for most patients the overall picture is one in which RIT may be advantageous and in which data relating to the efficacy of treatment can be quickly obtained.

We describe here studies on the MAb IgG2a SWA11, which appears (by cross-competition experiments) to belong to Cluster w4 as defined at the International Workshop on SCC, London, 1987 (4). This antibody has been chosen for *in vivo* evaluation as a potential agent for RIT because of its strong reactivity with SCC lines *in vitro* (5). SWA11 is characterized by a very high capacity for *in vivo* localization, long biological half-life at the

tumor, and relatively low background levels in nontarget organs. These characteristics suggest SWA11 to be a suitable candidate for use in the establishment of an *in vivo* model for the radioimmunotherapy of SCC tumors and possibly as a clinical reagent for both imaging and therapy. The requirement for new agents such as MAbs to be used as therapeutic tools for use against SCC is indicated by the high mortality of the disease (6, 7).

Materials and Methods

Cell Lines. The SCC cell line SW2 was established in the laboratory of Dr. S. D. Bernal, Dana Farber Institute. It was routinely grown in RPMI supplemented with 1 mM glutamine and 10% fetal calf serum.

Monoclonal Antibodies. Our procedure for antibody generation has been described previously (8). Antibody SWA11 was purified as follows. A 30-55% ammonium sulfate fraction was taken from culture supernatant and adsorbed onto a protein A column in PBS. The adsorbed IgG was eluted with 100 mM citrate buffer (pH 4.5) and then dialyzed against 10 mM phosphate buffer (pH 6.8) containing 0.01 mM CaCl₂. The antibody was then applied to a hydroxylapatite column (Bio-Gel HPHT; Bio-Rad, Richmond, CA) and then eluted with a linear gradient to 350 mM phosphate.

Antibody Labeling Techniques. Iodo-Gen (0.1 mg; Pierce) was dissolved in 0.2 ml chloroform and added to a 1-ml vial. The solvent was evaporated with a gentle stream of nitrogen and then 0.5 mg of antibody in 0.25 ml of water was added. ¹³¹I or ¹²⁵I (0.3 mCi in 0.03 ml) was added and the reaction continued for 15 min at 10°C with stirring. The reaction mixture was applied to a prepacked Sephadex G-50 column which had been equilibrated with PBS. The solution was sterilized by passage through a 0.22 μ m filter (Millex GV). 0.04 ml human serum albumin (25%) was added as a protein carrier, and then radiochemical purity was assessed by thin layer chromatography using a CEL300 polygram (Machery Nagel) and methanol (85%). Radiochemical purity was generally in excess of 95%.

In Vitro Immunoreactivity. To determine the biological activity of radiolabeled SWA11 SW2 cells were washed 3 times in PBS (with 5% nonfat milk-0.05% azide) and varying cell numbers were then incubated for 2 h at 4°C with a fixed amount of radiolabeled antibody (690,000 cpm). After a washing, the activity in the cell pellet was counted. The number of counts remaining unbound were plotted against the reciprocal of the cell number (9).

Resistance to Radiolabeling. To assess the maximal specific activity which could be achieved without impairment of biological activity of SWA11 the antibody was labeled over the range of 2.5 to 25 mCi/mg. Labeled SWA11 at a concentration determined to give half-maximal binding was then evaluated in a fixed cell radioimmunoassay and the number of counts bound was plotted against specific activity.

SW2 Xenograft Model. Female NMRI-*nu/nu* mice were bred within the Biologisches Zentrallabor, Universitaetsspital, Zurich. Pathogen free food and acidified drinking water were given *ad libitum*. Xenograft passage was performed by s.c. transplantation of 2-3-mm³ pieces of SW2 tumor into 4-6-week-old animals. Within approximately 3 weeks tumors were ready for use in antibody localization studies having reached a size of approximately 1 cm³.

In Vivo Localization Studies. The *in vivo* distribution of SWA11 was determined by simultaneous i.v. injection of 20 μ g (10 μ Ci) of ¹³¹I labeled SWA11 and the same amount and activity of a ¹²⁵I labeled anti-CEA. Both antibodies were of the IgG2a subclass. Thyroid blocking was achieved by the administration of 2-3 drops of Lugol's solution

¹ Presented at the "Second Conference on Radioimmunodetection and Radioimmunotherapy of Cancer," September 8-10, 1988, Princeton, NJ. Supported in part by the Swiss Cancer League (FOR.302.85) and the Stiftung für wissenschaftliche Forschung an der Universität Zürich.

² To whom requests for reprints should be addressed, at Division of Oncology, University Hospital, CH-8091 Zurich, Switzerland.

³ The abbreviations used are: MAB, monoclonal antibody; RIT, radioimmunotherapy; SCC, small cell carcinoma of the lung; CEA, carcinoembryonic antigen; PBS, 0.05 M phosphate buffer-0.1 M sodium chloride; %ID/g, percentage of injected dose per g of tissue.

per 100 ml of drinking water. Mice were dissected at days 2, 3, 4, and 7 and the various organs were rinsed in PBS, weighed, and counted in a two channel gamma counter. Localization of antibody was expressed in absolute terms as %ID/g and in relative terms as a tissue:blood ratio.

Gamma Scintigraphy. Tumor bearing mice were given i.v. injections of 100 μ Ci of 131 I labeled SWA11 (100 μ Ci/100 μ g) and then imaged on days 2 and 4 using a pinhole collimator positioned 9 cm from the target animal and linked to a Picker Dyna Camera 4. Images were generated from 50,000 counts acquired using an energy window of 25% centered on 364 keV. No background subtraction technique was required. Animals were anesthetized during imaging by i.p. injection of 0.5 ml Nembutal (1:10 dilution in PBS). No thyroid blocking was used in external scintigraphy studies.

Radioimmunotherapy. Nude mice bearing established xenografts in the range of 0.5–0.9 cm³ were given i.v. injections of 100 μ g SWA11 labeled with 300 μ Ci 131 I, control immunoglobulin similarly labeled, SWA11 unlabeled, or diluent alone. Tumor growth rates were then assessed using the formula of Kopper and Steel (10). Animal weight was also monitored during the experiment.

Tumor Histology. At day 16 postinjection control animals were killed due to tumor burden and tumors were excised and fixed in 4% formalin solution. Tumors from two 131 I SWA11 treated animals were also taken. Sections were stained with hematoxylin and eosin.

Results

In Vitro Immunoreactivity. The Iodo-Gen radiolabeling reagent was used routinely to produce iodinated SWA11 with a specific activity in the range of 0.5–1.0 mCi/mg. The biological activity of the labeled antibody was generally 65–70% as shown in Fig. 1.

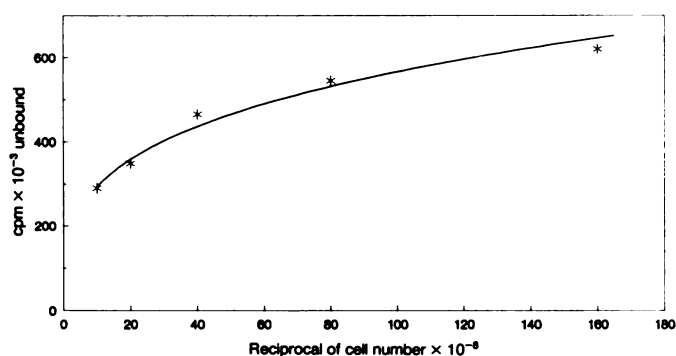


Fig. 1. Assessment of the biological activity of radiolabeled SWA11. Antibody was incubated with increasing concentrations of SW2 cells as described in the text. The number of cpm remaining unbound were then plotted against the reciprocal of the cell number. Knowing the input in cpm the biologically active fraction is determined by extrapolation to the ordinate.

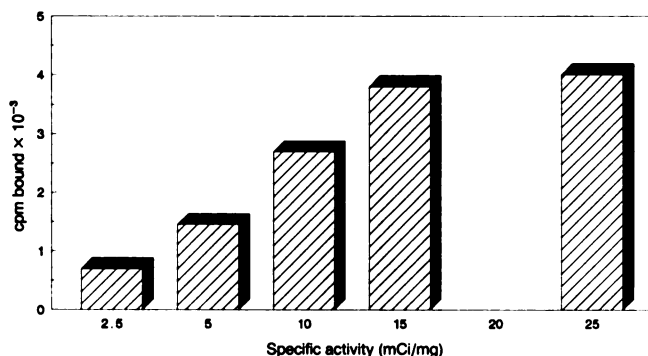


Fig. 2. Resistance of SWA11 to radiolabeling procedures. SWA11 was labeled with 131 I over a range of specific activities from 2.5–25 mCi/mg and was then used in a radioimmunoassay against fixed SW2 cells at a concentration determined to give half-maximal binding. Resultant cpm bound to target SW2 cells are plotted against specific activity.

Resistance to Radiolabeling. Fig. 2 shows the binding of 131 I SWA11 labeled over a range of specific activities to SW2 cells in a fixed cell radioimmunoassay. Whereas increased specific activity results in accompanying increase in counts bound up to an activity of 15 mCi/mg little increase is found between 15 and 25 mCi/mg indicating impairment of biological activity.

In Vivo Localization. SWA11 antibody showed strong selective tumor localization following i.v. injection into nude mice bearing SCC xenografts. Tissue:blood ratios of SWA11 and control anti-CEA at days 2, 3, 4, and 7 are presented in Fig. 3. Whereas no selective localization of anti-CEA was observed, the tumor:blood ratios for SWA11 were 2.4:1, 5.3:1, 7.5:1, and 8.0:1 at days 2, 3, 4, and 7, respectively. At day 4 the level of tumor accumulated SWA11 was 19, 22, and 12 times higher than levels in liver, kidney, and spleen, respectively.

The absolute levels of SWA11 in tumor and various organs (as %ID/g) are presented in Table 1. SWA11 displays a high localization at day 2 with 10.5 %ID/g of tumor. The antibody remains bound to the tumor maintaining 8 %ID/g at days 3 and 4 and then falling to 4.8 %ID/g by day 7.

Gamma Scintigraphy. The selective accumulation of SWA11 in SW2 xenografts at 2 and 4 days following injection was confirmed by external gamma scintigraphy as displayed in Fig. 4. At day 2 the tumor was already clearly visible against the background of activity still present in the blood pool in the visceral organs of the thorax. By day 4 the background level was markedly reduced whereas the tumor remained relatively constant in terms of image intensity. The unblocked thyroid was visible at this time due to accumulation and relative retention of free 131 I.

Radioimmunotherapy. Control animals given injections of diluent or 300 μ Ci of nonspecific immunoglobulin produced similar xenograft growth curves as shown in Fig. 5. By day 16 postinjection the animals were killed because of tumor burden having undergone a 7-fold increase in tumor volume. Xenografts treated with 300 μ Ci of SWA11 showed decrease in volume from day 4 to day 16 to a point where mean tumor volume was only 60% of initial volume. No tumor regrowth was observed up to day 34. Weight loss in mice receiving 300 μ Ci 131 I labeled immunoglobulin was transient, lasting for up to 7 days, and was less than 10% of total body weight.

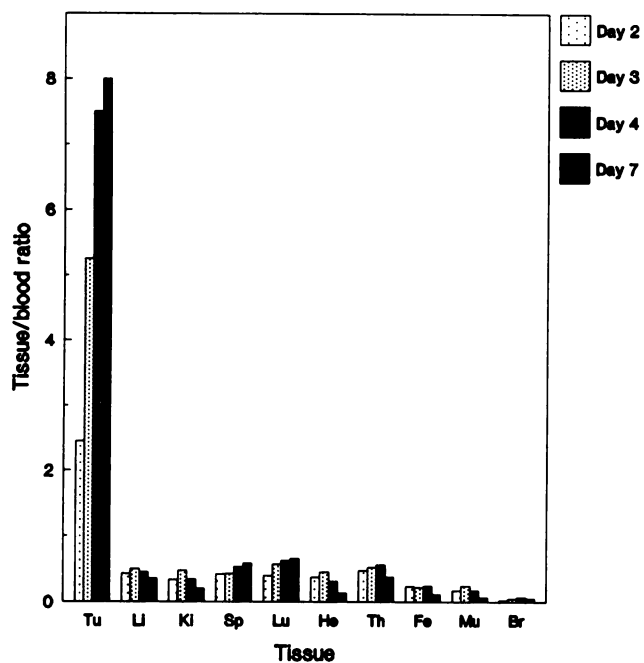
Tumor Histology. Histological sections of diluent and 131 I SWA11 treated xenografts are shown in Fig. 6. Control tumors revealed typical SCC morphology with densely packed small cells showing intense nuclear staining. Xenografts which had been treated with 300 μ Ci 131 I SWA11 possessed markedly different morphology. Extensive areas of necrosis were observed together with much fibrosis. Only a few cells of tumor origin were evident and these were enlarged, possibly by arrest during cell division.

Table 1 Tissue distribution of antibody SWA11

	Day			
	2	3	4	7
Tumor	10.5 ^a	8.0	8.0	4.8
Blood	4.2	1.5	1.1	0.60
Liver	1.9	0.75	0.5	0.22
Kidney	1.4	0.7	0.37	0.12
Spleen	1.8	0.63	0.58	0.35
Lung	1.8	0.82	0.66	0.39
Heart	1.8	0.68	0.33	0.08
Thyroid	2.0	0.84	0.58	0.23
Femur	1.0	0.36	0.25	0.07
Muscle	0.8	0.35	0.18	0.04
Brain	0.25	0.10	0.05	0.013

^a Expressed as percentage of total injected dose per g tissue. Each value is the mean obtained from a group of three animals.

a)



b)

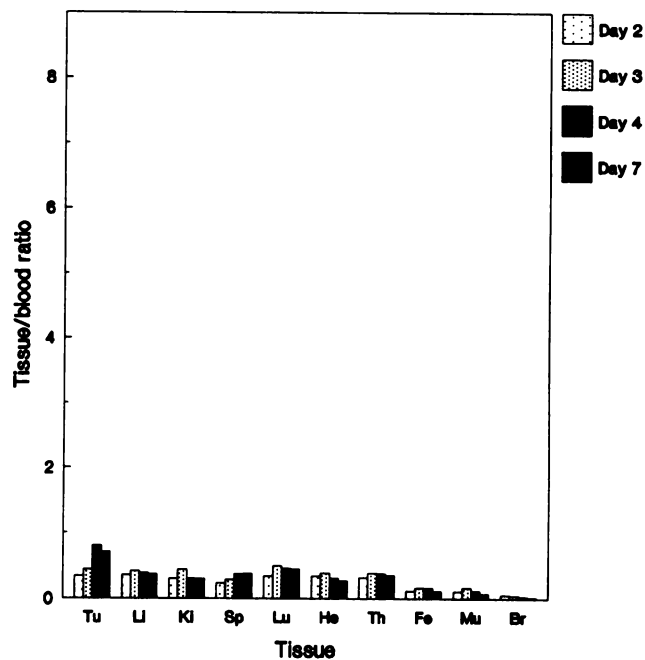


Fig. 3. Tissue to blood ratios for antibody SWA11 (a) and control anti-CEA antibody (b) at 2, 3, 4, and 7 days after i.v. injection of 10 μ Ci (20 μ g) radiolabeled material. *Tu*, tumor; *Li*, liver; *Ki*, kidney; *Sp*, spleen; *Lu*, lung; *He*, heart; *Th*, thyroid; *Fe*, femur; *Mu*, muscle; *Br*, brain.

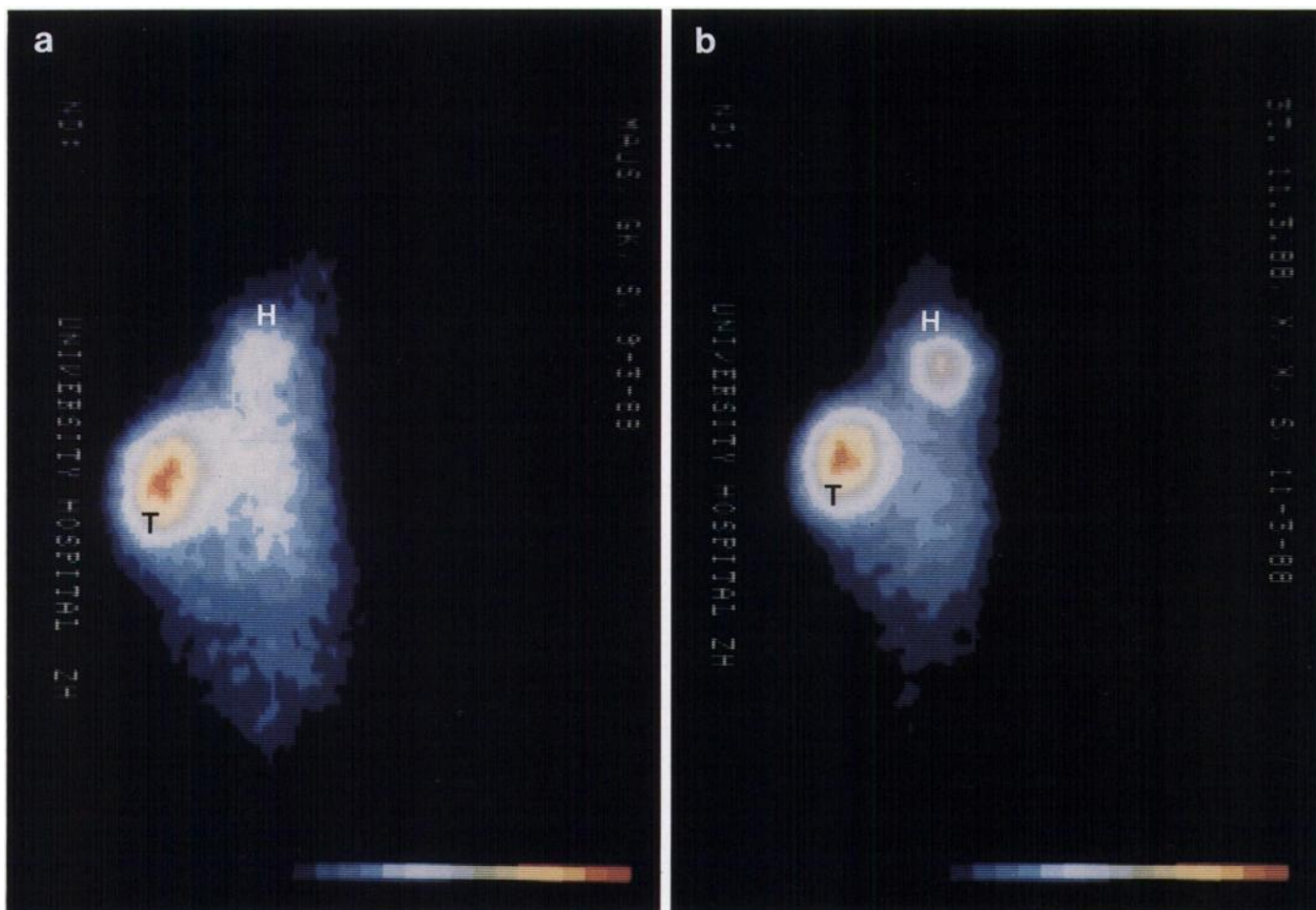


Fig. 4. External gamma scintigraphy following i.v. injection of 100 μ Ci 131 I labeled SWA11. a, 2 days postinjection; b, 4 days postinjection. The head (*H*) and tumor (*T*) are indicated. No background subtraction or thyroid blocking was used.

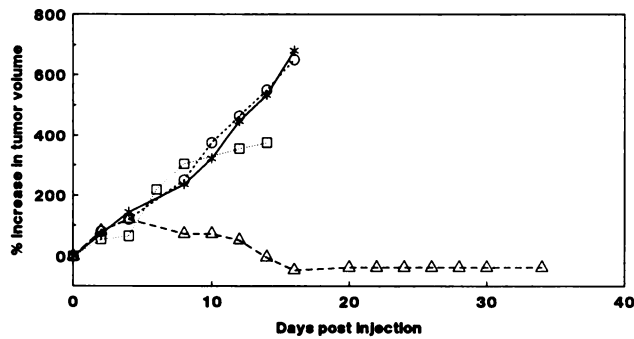


Fig. 5. Radioimmunotherapy of SW2 xenografts. Animals were given i.v. injections of diluent (*), unlabeled SWA11 (□), 300 μ Ci control antibody (O), or 300 μ Ci SWA11 (Δ). Tumor volume was determined by the method of Kopper and Steele.

Discussion

We present here preliminary studies on the use of the anti-SCC monoclonal antibody SWA11 as an agent for radioimmunodetection and radioimmunotherapy in a mouse model

system. This antibody was originally selected because of its high *in vitro* reactivity with SCC cell lines, possessing a K_s of $1.2 \times 10^9 \text{ M}^{-1}$ and about 6×10^5 antigenic sites per SW2 cell (5).

Initial distribution studies in nude mice bearing SW2 xenografts indicated better tumor localization than had been reported previously in the literature for anti-SCC MABs. Stya *et al.* (11) performed external scintigraphy on SCC xenografts using the antibodies UM-MS1, -2, and -3. Highest tumor:tissue ratio was 18.5:1 against muscle and the absolute amount of antibody localizing to tumor had a mean value of 1.2 %ID/g at day 10. The IgM anti-SCC antibody MAb (600D11) achieved tumor localization of 3%ID/g at day 7 after injection but poor tumor:normal tissue ratios were observed (12). MAB 8 anti-SCC antibody displayed unusual biokinetics in that a maximal tumor level of 7.4%ID/g was achieved on day 7 following gradual accumulation throughout the study. The tumor to blood ratio at this point was only 2.7:1 and ratios for tumor to lung, kidney, and liver were 5:1, 11:1, and 9:1 respectively (13). Our studies on SWA11 have shown localization to tumor of 10.5 %ID/g at day 2, around 8% at days 3 and 4, and 4.8% at day 7. Tumor to blood levels at the corresponding times were

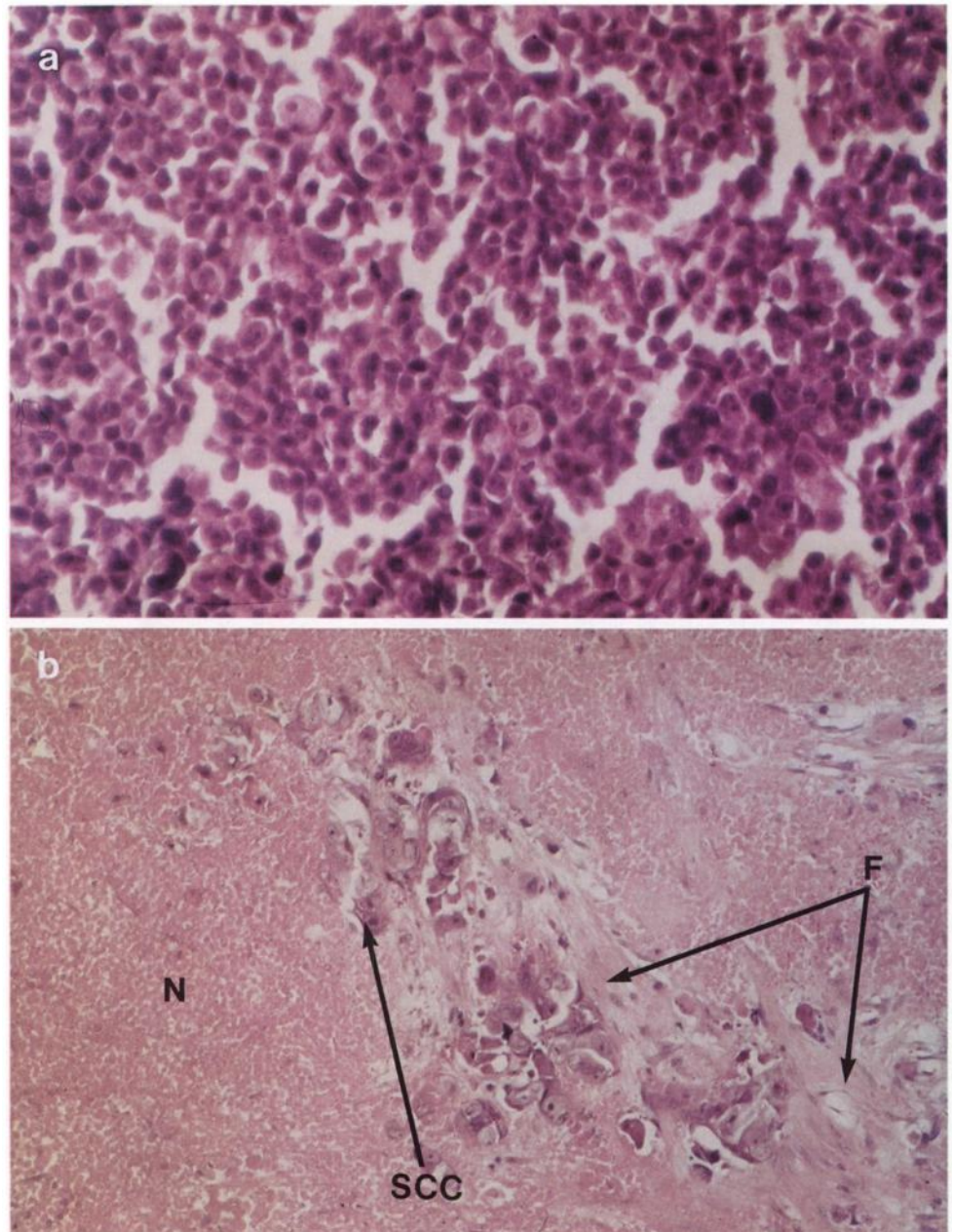


Fig. 6. Histological sections of SCC xenografts. Tumor bearing mice were given i.v. injections of diluent (a) or 300 μ Ci ^{125}I labeled SWA11 (b). Animals were killed at day 16 postinjection and tumors were fixed in 4% formalin. N, necrosis; F, fibrosis; SCC, residual cells of tumor origin.

markedly better than those reported for other antibodies at 2.4:1, 5.3:1, 7.5:1, and 8:1. A representative sample of tumor:organ antibody levels at day 4 show similarly high ratios at 19:1, 22:1, 12:1, and 44:1 for liver, kidney, spleen, and muscle, respectively (5).

Encouraged by these results and by the resistance of SWA11 to radiolabeling procedures we then used the antibody in a radioimmunotherapeutic study in which animals with established tumors (0.5–0.9 cm³) were given injections of 300 μ Ci of ¹³¹I labeled SWA11. From 4 days postinjection clear decrease in tumor volume was evident, continuing to day 16. From this point no increase in tumor volume has been evident and tumor histology revealed striking changes in morphology with extensive fibrosis, large areas of necrosis, and very few cells of SCC origin, all of which displayed atypical morphology. The clonogenic potential of these residual cells is now being evaluated by long term monitoring for tumor regrowth.

Small cell cancer may prove a very appropriate disease for the application of RIT. SCC often presents in a widely disseminated form (14) and, although initially sensitive to chemotherapy, is characterized by the rapid emergence of chemoresistance and clinical relapse. Disseminated tumors of this type are promising candidates for the application of RIT (15). The emergent refractory form of the disease originates from residual cells following first treatment and such residual cells may be more susceptible to the use of conventional chemotherapeutic protocols in conjunction with antibody-guided RIT as a combined treatment modality. We are now extending our *in vivo* RIT studies to observe long term survival of treated animals and the effects of dose fractionation. We hope to commence clinical imaging and distribution studies in the near future so that estimates can be made as to the likely efficacy of SWA11 as a radioimmunotherapeutic agent for the treatment of SCC.

Acknowledgments

We would like to thank Edith Gubler and Vroni Gruenefelder for their technical assistance and Professor G. Martz for his continued support, and we acknowledge the collaborative help of the Swiss Federal Institute for Reactor Research, Wurenlingen and the Biologisches

Zentrallabor, Universtaetsspital, Zurich. Parts of this paper have been reproduced with the kind permission of the *British Journal of Cancer*.

References

- Cuttitta, F., Rosen, S. T., Fedorko, J., Gregorio, T., Stephenson, S., Mulshine, J., Carney, D. N., Fargiom, S., Abrams, P. G., Moody, T. W., Gazdar, A. F., and Minna, J. D. Monoclonal antibodies to human lung tumor antigens. *In: G. L. Wright (ed.), Monoclonal Antibodies and Cancer*, pp. 161–180. New York: Marcel Dekker, 1984.
- Smedley, H. M., Finan, M. J., Lennox, E. S., Ritson, A., Takei, F., Wraight, P., and Sikora, K. Localisation of metastatic carcinoma by a radiolabeled monoclonal antibody. *Br. J. Cancer*, *47*: 253–259, 1983.
- LoBuglio, A. F., Saleh, M., and Peterson, L. Phase I clinical trial of CO17-1A monoclonal antibody. *Hybridoma*, *5* (Suppl. 1): 117–123, 1986.
- Beverly, P. C. L., Souhami, R. L., and Bobrow, L. *In: Proceedings of the First International Workshop on Small Cell Lung Cancer Antigens. Results of Central Data analysis. Lung Cancer*, *4* (Nos. 1–2): 15–36, 1988.
- Smith, A., Waibel, R., Westera, G., Martin, A., Zimmerman, A. T., and Stahel, R. A. Immunolocalisation and imaging of small cell cancer xenografts by the IgG2a monoclonal antibody SWA11. *Br. J. Cancer*, *59*:174–178, 1988.
- De Vita, V., Hellman, S., and Rosenberg, S. A. *In: Cancer: Principles and Practice of Oncology*, Ed. 2, pp. 507–597. Philadelphia: J. B. Lippincott Co., 1985.
- Carney, D. N. Clinical implications of the biology of small cell lung cancer. *Eur. J. Respir. Dis.* *70* (Suppl. 149): 5–9, 1987.
- Stahel, R. A., Speak, J. A., and Bernal, S. D. Murine monoclonal antibody LAM2 defines cell membrane determinant with preferential expression on human small cell carcinoma and squamous cell carcinoma. *Int. J. Cancer*, *35*: 11–17, 1985.
- Trucco, M., and de Petris, S. Determination of equilibrium binding parameters of monoclonal antibodies specific for cell surface antigens. *Immunol. Methods*, *2*: 1–26, 1981.
- Kopper, L., and Steel, G. G. The therapeutic response of three human lines maintained in immune-suppressed mice. *Cancer Res.*, *35*: 2704–2713, 1975.
- Stya, M., Wahl, R. L., Natale, R. B., and Beierwaltes, W. H. Radioimmunomaging of human small cell lung carcinoma xenografts in nude mice receiving several monoclonal antibodies. *NCI Monogr.* *3*: 19–23, 1987.
- Zimmer, A. M., Rosen, S. T., Spies, S. M., Polovina, M. R., Minna, J. D., Spies, W. C. and Silverstein, E. A. Radioimmunomaging of human small cell lung carcinoma with I-131 tumor specific monoclonal antibody. *Hybridoma*, *4*: 1–11, 1985.
- Endo, K., Kamma, H., and Ogata, T. Radiolocalization of xenografted human lung cancer with monoclonal antibody 8 in nude mice. *Cancer Res.*, *47*: 5427–5432, 1987.
- Stahel, R. A., Mabry, M., Skarin, A. T., Speak, J. A., and Bernal, S. D. Detection of bone marrow metastasis in small cell lung cancer by monoclonal antibody. *J. Clin. Oncol.*, *3*: 455–461, 1985.
- Dykes, P. W., Bradwell, A. R., Chapman, C. E., and Vaughan, A. T. M. Radioimmunotherapy of cancer: clinical studies and limiting factors. *Cancer Treat. Rev.*, *14*: 87–106, 1987.