

# Effects of Smoking and Irradiated Volume on Inflammatory Response in the Lung of Irradiated Breast Cancer Patients Evaluated with Bronchoalveolar Lavage

Leif Bjermer, Lars Franzén, Bo Littbrand, Kenneth Nilsson, Tord Ångström, and Roger Henriksson<sup>1</sup>

Department of Oncology, Lung Medicine and Pathology, University Hospital, S-901 87 Umeå, Sweden

## ABSTRACT

Quantitative measurements of the effects of irradiation on normal tissues in humans have been hard to obtain because most tissues are inaccessible and/or direct responses are difficult to quantify in a nondestructive manner. Pneumonitis and fibrotic lung disease are adverse effects seen in varying intensity in patients treated with radiotherapy for carcinomas of the thorax, *e.g.*, breast cancer. In the present study the aim was to evaluate the inflammatory reaction in the underlying parenchyma following postoperative irradiation with bronchoalveolar lavage technique. Twenty-one patients (11 smokers, 10 nonsmokers) with breast cancer stage T1N0M0 received radiotherapy with photons to a target dose of 56 Gy following breast conservative surgery. Nineteen healthy controls were also included. The results showed a clear elevation of neutrophils, mast cells, eosinophils, and lymphocytes in the total irradiated group, compared to controls. When subclassifying the material according to smoking habit, it was obvious that the smokers displayed a significantly decreased inflammatory reaction, *i.e.*, reduced levels of mast cells and lymphocytes, compared to both nonsmoking controls and patients. Eosinophils were seen in an elevated number in all irradiated patients. Radiological signs of pneumonitis were observed in three patients, all in the nonsmoking group. No correlation was found between the volume of lung irradiated and the inflammatory response. It is concluded that bronchoalveolar lavage is a suitable and sensitive method for investigating radiotherapy-induced reactions in the human lung. Furthermore, ongoing smoking during the treatment depressed the inflammatory response in the lung parenchyma induced by irradiation. The present study as well as earlier observations justify further studies concerning the possibility of interaction of smoking with cancer treatment, both from the view of therapeutic failures and reduced adverse effects.

## INTRODUCTION

The effects of irradiation on normal tissues have been studied rather extensively in experimental animals and in humans. However, quantitative and objective measurements in humans have been hard to obtain because most tissues are inaccessible and/or direct responses are difficult to quantify in a nondestructive manner. Pneumonitis and fibrotic lung disease, adverse effects of therapeutic irradiation of breast cancer and other carcinomas of the thorax, are such entities that have been difficult to directly evaluate in detail in humans (1, 2). Physiological parameters and radiological signs of pneumonitis and lung fibrosis are seen in a significant number of patients, usually within a period of 6 months (1, 3–5). Since BAL<sup>2</sup> has been introduced, it has been shown to be a valuable tool in the investigation of many different disorders in diseases affecting the lung (6, 7), especially different inflammatory reactions in the interstitium, such as sarcoidosis, as well as other diseases causing lung fibrosis (6–8).

In the present study we have used BAL as a tool for investigating inflammatory reactions in the lung underlying the treatment field of irradiated breast cancer patients, and we have shown that BAL is a sensitive approach for evaluating irradiation-induced changes.

Furthermore, the analysis revealed, supporting earlier preliminary observations, that ongoing cigarette smoking depressed the inflammatory reactions in the lung parenchyma.

## MATERIALS AND METHODS

**Patients.** Twenty-one patients (mean age, 48 years; range, 35–64 years) with a unilateral breast cancer, stage T1 N0 M0, were included. After resection of the tumor, postoperative irradiation was given, with an accumulated target dose of 56 Gy, 2 Gy/day 5 times a week for 5.5 weeks, with photon beams of 6 MV. The patients were examined 2 months after finishing irradiation therapy. As controls, 12 nonsmoking and 7 smoking healthy individuals were used. There were no age and sex correlations and the lavage findings in this control group are very much in accordance with data reported from healthy controls in other centers. There were no other obvious differences between the different test groups, *e.g.*, in cardiovascular function or pulmonary function. All patients and controls participated as volunteers after their informed consent. The study was also approved by the local ethics committee.

**Bronchoalveolar Lavage.** BAL was performed as previously described (8). Briefly, the patients were examined with a flexible bronchoscope (Olympus BF IT or BF 4BF) under local anesthesia, after premedication with atropine chloride. Depending on the breast irradiated, the anterior part of the lingula (left breast) or the anterior part of the right middle lobe (right breast) was lavaged with 240 ml phosphate-buffered saline divided into four aliquots. The fluid was gently suctioned after each fraction and collected in a siliconized plastic bottle kept on ice. The recovery was  $124 \pm 18$  ml (mean  $\pm$  SD), with no statistical differences between patients and controls. Neither did the recovery differ between left and right sides. The lavage was kept on ice (4°C), filtered through a nylon filter (pore diameter, 100  $\mu$ m), and centrifuged at  $400 \times g$  for 15 min. The supernatant was collected for albumin analysis, and the cells were resuspended in phosphate-buffered saline to a final concentration of  $10^6$ /ml. Differential counts were made on cytospin preparations (50,000 cells/slide) stained with May-Grünwald-Giemsa, counting 200 nonepithelial cells. Mast cells were identified with acid toluidine blue (9), counterstained with Mayer's acid hematoxylin. Ten visual fields with  $\times 16$  magnification were counted. All cells were expressed as percentage of total cells recovered.

**X-Ray and Treatment Volume.** Chest X-ray was performed with anterior and lateral views combined, with a 45-degree rotation (oblique) picture on the irradiated side. This projection made it possible to study the anterolateral part of the lung close behind the irradiated breast.

By use of computerized tomography scanning, the volume of lung parenchyma falling within the dose range down to 90% was calculated and used as a border limit for estimation of the amount of lung tissue involved in the target field.

**Statistics.** For the statistical analysis, we used Wilcoxon's nonparametric rank sum test.

## RESULTS

There was no significant difference in the lavage findings between left and right sides either in the amount of fluid recovered or in the degree of inflammation (data not shown). When irradiated patients were compared with the controls, a relative and significant increase of neutrophils, eosinophils, and mast cells was seen (Fig. 1). Albumin levels were also increased in the patient group, as compared to controls (mean  $\pm$  SE, 91

Received 8/8/89.

The costs of publication of this article were defrayed in part by the payment of page charges. This article must therefore be hereby marked *advertisement* in accordance with 18 U.S.C. Section 1734 solely to indicate this fact.

<sup>1</sup> To whom requests for reprints and all correspondence should be addressed.

<sup>2</sup> The abbreviation used is: BAL, bronchoalveolar lavage.

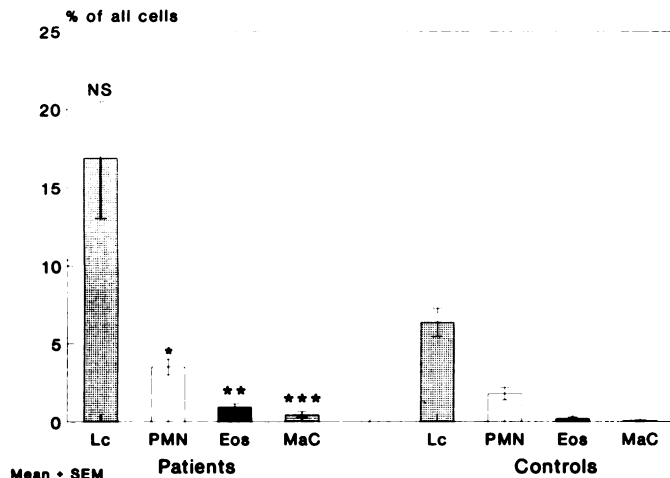


Fig. 1. Bronchoalveolar lavage cellular data showing the whole patient group compared to healthy controls. *Lc*, lymphocytes; *PMN*, polymorphonuclear neutrophils; *Eos*, eosinophils; *MaC*, mast cells, expressed as percentage of all cells. The statistical comparisons between groups were calculated with the Wilcoxon nonparametric rank sum test; \*  $P < 0.05$ ; \*\*  $P < 0.01$ ; \*\*\*  $P < 0.001$ . *NS*, not significant.

$\pm 15$  versus  $49 \pm 5$  mg/liter;  $P < 0.03$ ). The mean value of lymphocytes in the patient group also seemed to be much higher, compared to the controls. However, this difference did not reach statistical significance because of the large SD of the sample. The reason for this wide variability became obvious when the patients and controls were further subclassified according to smoking habit. The nonsmokers had a clear increase in lymphocytes in lavage fluid, whereas the smokers displayed low values (Fig. 3). The patients displayed a significant relative increase in neutrophils, compared to the healthy controls. There were no differences between smokers and nonsmokers (Fig. 4). It was obvious from the other cell parameters analyzed that the smokers displayed a significantly decreased inflammatory reaction, *i.e.*, reduced levels of mast cells and lymphocytes, compared to both nonsmoking patients and nonsmoking controls (Figs. 1, 3, and 6). The albumin levels displayed similar alterations (smoking patients,  $64 \pm 9$  mg/liter, versus smoking controls,  $50 \pm 5$  mg/liter; nonsmoking patients,  $117 \pm 26$  mg/liter, versus nonsmoking controls,  $49 \pm 8$  mg/liter;  $P < 0.03$ ). Among the smokers, the nonirradiated controls had a significant increase in total cell numbers, compared to the smoking patients (Fig. 2). While eosinophils were rarely seen in BAL from controls, a significant increase ( $P < 0.01$ ), both as a percentage (Fig. 5) and as total number, was seen in the patient group.

Radiological signs of pneumonitis were only seen in three patients, all in the nonsmoking group. This was especially evident on plain chest X-ray in the oblique view. These three patients displayed a pronounced increase in the inflammatory reaction measured in BAL. The mean volume hit by  $>90\%$  target dose in these three patients was 66 ml (range, 27–110 ml), compared to the whole patient group, 104 ml (range, 27–253 ml). There were no correlations between the amount of lung involved and inflammatory response in the lung.

## DISCUSSION

In humans, objective and quantitative estimations of normal tissue responses to radiotherapy are difficult because in general tissues are inaccessible to quantification in a nondestructive manner. The present study implies that BAL is a suitable and sensitive approach for directly investigating and evaluating irradiation-induced changes in the lung parenchyma in humans,

*i.e.*, inflammatory reactions in the lung caused by irradiation when treating breast cancer patients.

Radiation-induced pneumonitis is a dose-limiting adverse effect of the treatment of malignant disease of the thorax and hematological malignancies treated with total body irradiation. The detailed mechanism which explains this response still remains to be elucidated. At least two epithelial cells seem to be involved, type II cells lining the alveolar wall producing surfactant and/or the endothelial cells lining the small vessels (1). An increased vascular permeability following radiation, probably subsequent to an inflammatory reaction, seemed to be one important factor in the development of radiation fibrosis, since steroids suppressed this response (10). A role for an altered vessel permeability may be supported in the present study by the observation of an increased efflux of albumin to the lavage fluid. However, few BAL studies on irradiation effects in human lung are reported in the literature. Cordier *et al.* (11) investigated six lung cancer patients with roentgenologically defined "irradiation-induced pneumonitis." Most of these patients had elevated levels of lymphocytes, with varying degrees of neutrophilia in the lavage fluid. These findings are difficult to interpret, though, because no controls were used. It is also unclear whether a malignancy in the lung may influence the changes *per se* (12). An increase in lymphocytes and total cell number was observed in BAL from four patients with irradiated breast cancer 6–12 weeks after thoracic irradiation (13).

There are no reports of mast cell counts in lavage fluid. The mast cells may, however, have an important implication, since increases in mast cells in lavage fluid have been shown to be a valuable parameter predicting disease activity in interstitial lung diseases such as sarcoidosis and extrinsic allergic alveolitis (8, 14). Furthermore, a pronounced increase in tissue mast cells has also been observed in irradiation-induced pneumonitis and fibrosis in rats (15).

It is generally thought that an increased treatment volume should cause an increase in the tissue response (16). However, as observed in this study, we were not able to detect any correlations between the volume of lung parenchyma affected by irradiation and the cellular responses. This may be somewhat unwarranted but finds some support in other studies. It has been observed that the inflammatory response induced by ionizing radiation is not solely localized in the irradiated lung (13). These authors suggested that the observation that the cellular inflammatory response was about the same magnitude in the nonirradiated side indicated a secondary generalized immunological reaction, *i.e.*, hypersensitivity pneumonitis. A prompt improvement in this inflammatory response was seen after corticosteroid therapy.

The significance of eosinophilia in the patient group is hard to explain. The eosinophilic granulocyte is known to be a very hazardous cell, and an increase in eosinophils is commonly seen in idiopathic pulmonary fibrosis (17, 18). The eosinophil has the potential to cause tissue damage by releasing toxic enzymes and oxidative metabolites (19). Interestingly, enhanced numbers of activated eosinophils have also been shown in adult respiratory distress syndrome (20), a disease which displays many features in common with irradiation-induced pneumonitis.

It was also obvious from the present results that ongoing smoking during treatment may interact with the irradiation-induced inflammation in the lung. This is in agreement with previous observations. Smoking is less frequent in hypersensitive pneumonitis and sarcoidosis (21, 22). However, it could

not be excluded that smoking, beside the inflammatory-modulating effects, may also directly interact with the ionizing-induced tissue response. In this respect it might be of interest to recall the observations that smoking in combination with obesity seems to increase the frequency of metastasis in older

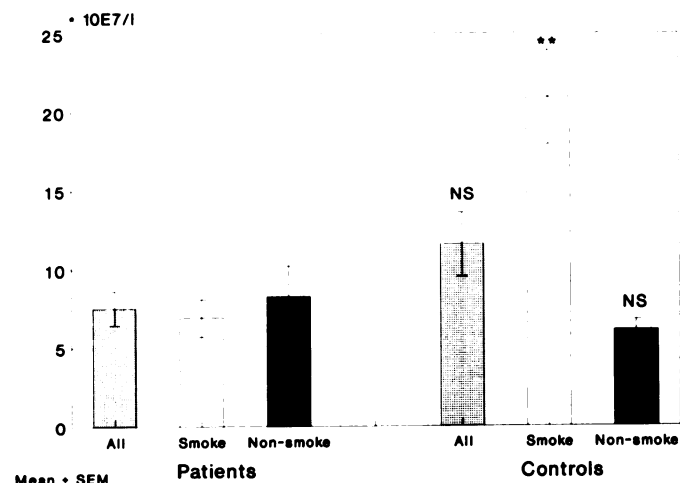


Fig. 2. Total number of lavage cells recovered from patients and controls as whole groups and subdivided to smokers and nonsmokers. \*  $P < 0.05$ ; \*\*  $P < 0.01$ ; \*\*\*  $P < 0.001$ ; NS, not significant.

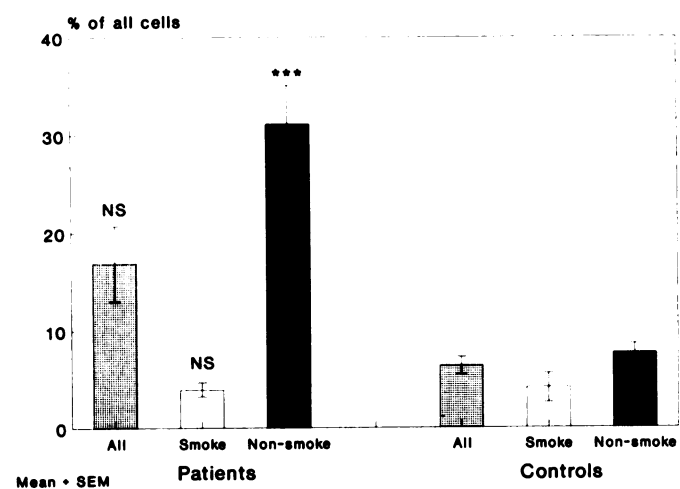


Fig. 3. Individual lavage cell data for lymphocytes. Patients are compared to controls according to methods in Fig. 2. NS, not significant.

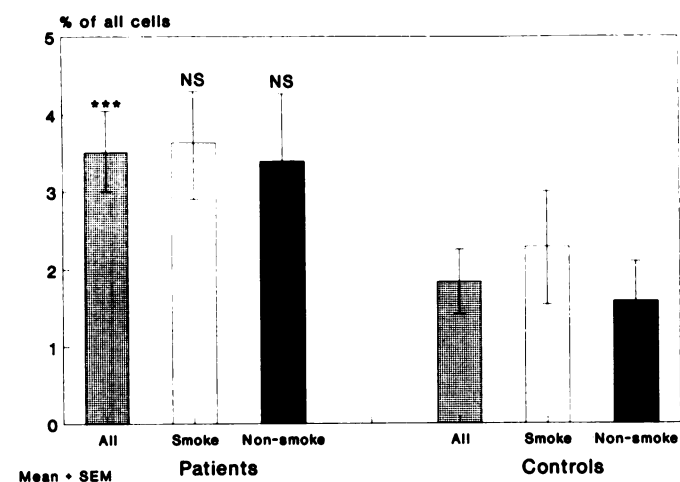


Fig. 4. Individual lavage cell data for neutrophils. Patients are compared to controls according to methods in Fig. 2. NS, not significant.

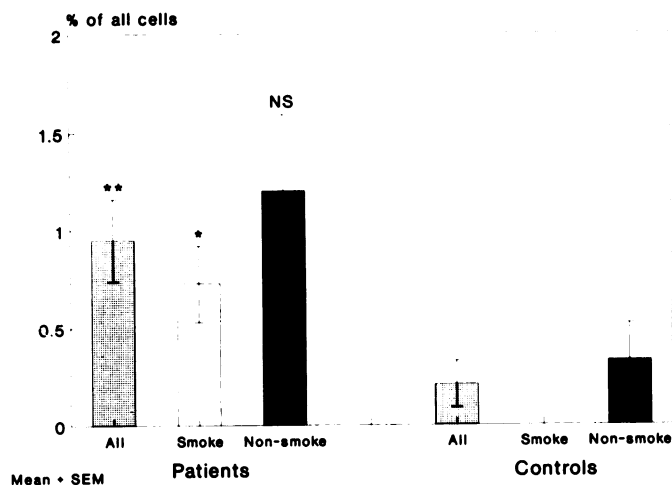


Fig. 5. Individual lavage cell data for eosinophils. Patients are compared to controls according to methods in Fig. 2. NS, not significant.

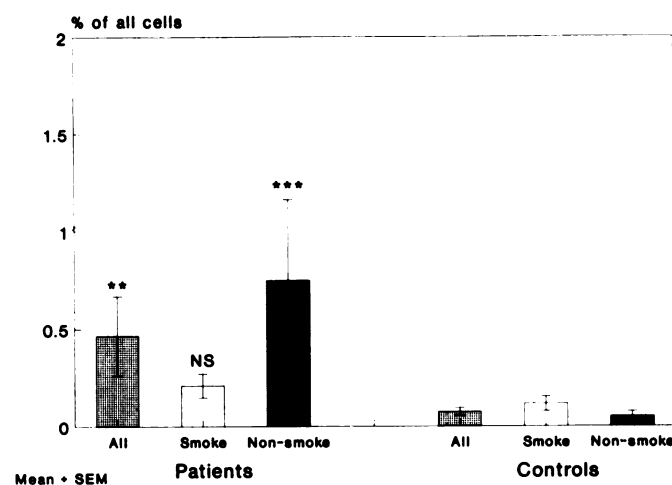


Fig. 6. Individual lavage cell data for mast cells. Patients are compared to controls according to methods in Fig. 2. NS, not significant.

women with breast cancer (23) and that in an animal model a reduced antitumor effect of radiation was seen (24). Recently it has also been demonstrated that smoking reduced the bleomycin-induced lung fibrosis in hamsters (25) and, most noteworthy, nicotine at concentrations corresponding to levels in heavy smokers reduced the activity of cyclophosphamide on transplanted rat leukemia (26). Thus, the results certainly justify further studies concerning the possibility of an interaction of smoking with irradiation, from the view of both therapeutic failures and reduced adverse effects.

Bronchoalveolar lavage in oncology research is not completely introduced and not yet fully appreciated. This is in contrast to the field of lung research and the clinic, where BAL is considered to be a very valuable tool in studying inflammatory processes in the lower respiratory tract (9, 10). Most important, it is a safe technique with only minor discomfort for the patients. It is our belief that BAL is of value in investigating irradiation effects, and surely effects of other treatment modalities, in the human lung. Whether the inflammatory reaction seen is representative is of course still an open question. However, we believe BAL in patients with irradiated but otherwise normal lung to be a good start. It is at present the most suitable method for evaluating such effects in patients.

In conclusion, BAL is suggested to be a suitable and sensitive tool for investigating and evaluating radiotherapy-induced reactions in the human lung. Furthermore, the analysis revealed,

supporting earlier preliminary observations, that ongoing cigarette smoking depressed the inflammatory reactions in the lung parenchyma induced by irradiation. Especially interesting will be a long term follow-up and correlation of the observed cellular changes with the degree of pulmonary dysfunction.

## REFERENCES

- Coggle, J. E., Lambert, B. E., and Moores, S. R. Radiation effects in the lung. *Environ. Health Perspect.* 70: 261-291, 1986.
- Adamsson, I. Y., Bowden, H., and Wyatt, J. P. A pathway to pulmonary fibrosis: an ultrastructural study of mouse and rat following radiation to the whole body and hemithorax. *Am. J. Pathol.*, 58: 481-498, 1970.
- Mattsson, K., Holsti, L. R., Poppius, H., Korhola, O., Stenman, S., Tammelehto, L., and Salmo, M. Radiation pneumonitis and fibrosis following split-course radiation therapy for lung cancer. A radiologic and physiologic study. *Acta Oncol.*, 26: 193-196, 1987.
- Jingu, K., Shimamura, Y., Hayabuchi, N., Miyoshi, M., and Masuda, K. Pulmonary fibrosis after postoperative tangential irradiation in breast cancer. *Gan. No. Rinsho.*, 33: 1139-1142, 1987.
- Slanina, J., Maschitzki, R., and Wannenmacher, M. Die pulmonale Strahlenreaktion im Röntgenbild des Thorax nach Megavolttherapie bei Mammakarzinom. *Radiologe*, 27: 181-191, 1987.
- Rossi, G. A. Bronchoalveolar lavage in the investigation of disorders of the lower respiratory tract. *Eur. J. Respir. Dis.*, 69: 293-315, 1986.
- Reynolds, H. Y. Bronchoalveolar lavage. *Am. Rev. Respir. Dis.*, 135: 250-263, 1987.
- Bjermer, L., Rosenhall, L., and Hällgren, R. The predictive value of bronchoalveolar lavage cell analysis in sarcoidosis. *Thorax*, 43: 284-282, 1988.
- Strobel, S., Miller, H. R. P., and Ferguson, A. Human interstitial mucosal mast cells: evaluation of fixation and staining techniques. *J. Clin. Pathol.*, 34: 851-858, 1981.
- Evans, M. L., Graham, M. M., Mahler, P. A., and Rasey, J. S. Use of steroids to suppress vascular response to radiation. *Int. J. Radiat. Oncol. Biol. Phys.*, 13: 563-567, 1987.
- Cordier, J., Mornex, J., Lassne, Y., *et al.* Bronchoalveolar lavage in radiation pneumonitis. *Bull. J. Physiopathol. Respir.*, 20: 369-374, 1984.
- Fedullo, A. J., and Effenson, D. B. Bronchoalveolar lavage in lymphangitic spread of adenocarcinoma to the lung. *Chest*, 87: 129-131, 1985.
- Gibson, P. G., Bryant, D. H., Morgan, G. W., *et al.* Radiation induced lung injury: a hypersensitivity pneumonitis? *Ann. Intern. Med.*, 109: 288-291, 1988.
- Bjermer, L., Engström-Laurent, A., Lundgren, R., Rosenhall, L., and Hällgren, R. Bronchoalveolar mastocytosis in farmer's lung is related to disease activity. *Arch. Int. Med.*, 148: 1362-1365, 1988.
- Watanabe, S., Watanabe, K., Ohishi, T., *et al.* Mast cells in the rat alveolar septa undergoing fibrosis after ionizing irradiation. Ultrastructural and histochemical studies. *Lab. Invest.*, 31: 555-567, 1974.
- Fletcher, G. H. Radiation and drug resistance of breast cancer. *Am. J. Clin. Oncol.*, 7: 617-624, 1984.
- Rudd, R. M., Haslam, P. L., and Turner-Warwick, M. Cryptogenic fibrosing alveolitis. Relationship of pulmonary physiology and bronchoalveolar lavage to response to treatment and prognosis. *Am. Rev. Respir. Dis.*, 124: 1-8, 1981.
- Hällgren, R., Bjermer, L., Lundgren, R., and Venge, P. The eosinophil component of the alveolitis in idiopathic pulmonary fibrosis: signs of eosinophil activation in the lungs are related to impaired lung function. *Am. Rev. Respir. Dis.*, 139: 373-377, 1989.
- Weller, P. F. Eosinophilia. *J. Allergy Clin. Immunol.*, 73: 1-10, 1984.
- Hällgren, R., Samuelsson, T., Venge, P., and Modig, J. Eosinophil activation in the lung is related to lung damage in adult respiratory distress syndrome. *Am. Rev. Respir. Dis.*, 135: 639-642, 1987.
- Grüchow, H. W. Precipitating antibodies to farmer's lung antigen in a Wisconsin farming population. *Am. Rev. Respir. Dis.*, 124: 411-415, 1981.
- Douglas, J. G., Midleto, W. G., Gaddie, J., *et al.* Sarcoidosis: a disorder commoner in non-smokers? *Thorax*, 41: 787-791, 1986.
- Daniell, H. W. Increased lymph node metastases at mastectomy for breast cancer associated with host obesity, cigarette smoking, age, and large tumor size. *Cancer (Phila.)*, 62: 429-435, 1988.
- Siemann, D. W., Hill, R. P., and Bush, R. S. Smoking: the influence of carboxyhemoglobin on tumor oxygenation and response to radiation. *Int. Radiat. Oncol. Biol. Phys.*, 4: 657-662, 1978.
- Osanai, K., Takahashi, K., Suwabe, A., Takada, K., Ikeda, H., Sato, S., and Yasui, S. The effect of cigarette smoke in bleomycin-induced pulmonary fibrosis in hamsters. *Am. Rev. Respir. Dis.*, 138: 1276-1281, 1989.
- Berger, M. R., and Zeller, W. J. Interaction of nicotine with anticancer treatment. *Klin. Wochenschr.*, 66: 127-133, 1988.