

Occurrence of Microsatellite Instability in Gastric Carcinoma Is Associated with Enhanced Expression of *erbB-2* Oncoprotein¹

Jaw-Town Lin,² Ming-Shiang Wu, Chia-Tung Shun, Wei-Jei Lee, Jin-Chuan Sheu, and Teh-Hong Wang

Departments of Internal Medicine [J-T. L., M-S. W., J-C. S., T-H. W.], Pathology [C-T. S.], and Surgery [W-J. L.], College of Medicine, National Taiwan University, Taipei, Taiwan

Abstract

To investigate the molecular mechanism of gastric carcinogenesis, we examined simultaneously the frequency of microsatellite instability and the immunoreactivities to *ras*, *erbB-2*, and *p53* in 42 gastric adenocarcinoma tissues. Microsatellite instability, measured by DNA replication error, was detected in 33.3% (14/42) of patients with gastric carcinoma while positive immunostaining was demonstrated in 3.1% (1/32) for *ras*, 40.5% (17/42) for *erbB-2*, and 28.6% (12/42) for *p53*. There was no statistical difference between the intestinal type and the diffuse type of carcinoma with respect to microsatellite instability, *ras*, or *erbB-2* expression. The expression of *p53* occurred more frequently in the intestinal type of carcinoma (41.7%, 10/24) than in the diffuse type of carcinoma (11.1%, 2/18; $P < 0.01$). There was no association between microsatellite instability and *ras* or *p53* expression, while enhanced expression of *erbB-2* occurred more frequently in carcinomas with microsatellite instability (64.3%, 9/14) than in those without microsatellite instability (28.6%, 8/28; $P < 0.05$). Such a strong association between microsatellite instability and *erbB-2* oncogene may be responsible for the increase of other oncogenic mutations and tumor progression in gastric carcinogenesis.

Introduction

Recent studies on the molecular genetics have a great impact on the understanding of carcinogenesis of colorectal carcinoma. A model of multistep carcinogenesis has been proposed involving activation of oncogenes and inactivation of tumor suppressor genes (1). The presence of the "mutator" phenotype due to alterations in the "stability" gene has been considered critical for promoting multistep carcinogenesis (2). Recently, DNA RER³ resulting in microsatellite instability has been demonstrated in hereditary nonpolyposis colorectal cancer and certain sporadic cancers (3–5). The existence of DNA RER, a marker for the mutator phenotype of cancers, may be responsible for the secondary mutations throughout the genome (2). However, preliminary studies in colorectal carcinomas failed to find an association between microsatellite instability and chromosomal losses of tumor suppressor genes such as the *APC* gene at 5q and the *p53* gene at 17p (4).

GC is one of the most common cancers in the world (6). Marked heterogeneity and functional difference exists in GC. It has been demonstrated that the prevalence of expression of several oncogenes and tumor suppressor genes may vary according to histological types of GC, and affect the biological behavior of GC (7, 8). Among them, the mutation of the *p53* gene has been found to correlate well with histological subtypes, while the presence of *ras* mutation usually implicates distant metastasis (7, 8). In addition, *erbB-2* overexpres-

sion generally indicates a more aggressive phenotype and a poor prognosis in GC (9). Recently, microsatellite instability has also been shown to occur in GC and play a role in tumor progression (10–13). However, because studies are scanty it remains unclear whether there is any relationship between RER and expression of different oncogenes or tumor suppressor genes in GC (7–13). To obtain a better understanding of the molecular mechanism of gastric carcinogenesis, we examined the frequency of DNA microsatellite instability and the immunoreactivity to *ras*, *erbB-2*, and *p53* in the same GC tissues. Our results revealed that GC tumors with the RER(+) phenotype tend to have enhanced expression of *erbB-2*, a marker indicative of tumor progression in GC (9).

Materials and Methods

GC Tissues. A total of 42 gastric specimens resected due to GC were studied. They are obtained from 24 males and 18 females with a mean age of 63.0 years. All GC tissues were examined histologically by the same pathologist, and subdivided into 6 early GC and 36 advanced GC according to the depth of invasion (14). Furthermore, these GCs were also subdivided into the intestinal type (24 patients) and the diffuse type (18 patients) based on Lauren's classification (15). Both tumorous tissues and nontumorous neighboring tissues were individually dissected off each resected GC specimen, immediately frozen in the optimal cooling temperature embedding compound (Miles Scientific), and then stored at -80°C until later use.

Microsatellite Analysis. Cryosections of 5–7 μm were prepared for each tumorous tissue, and sections containing predominantly neoplastic cells were used to prepare genomic DNA by a conventional procedure (1). DNA from nontumorous parts of the stomach was also extracted from the same patient to serve as a control. Analysis of microsatellite instability was performed by PCR using seven primers, *i.e.*, D2S114, D2S123, D3S1260, D5S395, D10S193, D10S197, and D17S785, obtained from Research Genetics. PCR was performed in a 25- μl reaction volume containing 5 μM each primer, 0.125 mM dATP, 1.25 mM each of dGTP, dCTP, and dTTP, 3 μCi [α -³⁵S]dATP, 25 ng DNA, and 0.75 units Taq DNA polymerase (Boehringer Mannheim, Mannheim, Germany). The reaction condition consisted of 30 s at 94°C , 75 s at 55°C , and 15 s at 72°C for 27 cycles followed by a final extension for 5 min at 72°C . The PCR products were diluted in a ratio of 3:2 by the loading buffer, heated at 95°C for 5 min, and loaded (5 μl) onto 7% polyacrylamide sequencing gels. After electrophoresis, gels were dried at 80°C and exposed to X-ray film from 24 to 72 h. The band pattern was compared between tumorous and nontumorous tissues for each patient.

Immunohistochemical Stainings of *ras*, *erbB-2*, and *p53*. To demonstrate the expression of *ras*, *erbB-2*, and *p53* proteins, frozen sections were stained immunohistochemically with each respective antibody purchased from Oncogene Science, Inc. using a standard avidin-biotin-peroxidase complex detection system. Briefly, cryosections mounted on slides were first treated with 3% hydrogen peroxide to block endogenous peroxidase. They were then incubated sequentially with normal nonimmune serum for 20 min to block nonspecific protein binding, primary mouse antibodies overnight at 4°C , biotinylated goat anti-mouse secondary antibody for 30 min, peroxidase-conjugated streptavidin for 10 min, and finally diaminobenzidine tetrahydrochloride/ H_2O_2 chromogen substrate for 10 min. Slides were then counterstained with Mayer's hematoxylin for *p53* and with methyl green for *ras* or *erbB-2*. Negative control sections were processed in the same manner by replacing the

Received 12/12/94; accepted 2/14/95.

The costs of publication of this article were defrayed in part by the payment of page charges. This article must therefore be hereby marked *advertisement* in accordance with 18 U.S.C. Section 1734 solely to indicate this fact.

¹ This study was supported by Grant DOH-84-TD-010 from the National Science Council and the Department of Health, Executive Yuan, Taiwan, Republic of China.

² To whom requests for reprints should be addressed, at Department of Internal Medicine, National Taiwan University Hospital, No. 7 Chung-Shan South Road, Taipei, Taiwan.

³ The abbreviations used are: RER, replication error; GC, gastric carcinoma.

primary antibody with buffered saline. Positive control sections were from breast adenocarcinoma known to express high levels of *ras*, *erbB-2*, and *p53*. Immunostainings were performed in all 42 patients for *p53* and *erbB-2*, but in 32 patients for *ras* due to limited tissues.

Results

Among the 42 patients examined, 14 (33.3%) manifested microsatellite instability at two or more chromosomal loci. The RER(+) tumors showed patterns of electrophoretic shifts or expansion of the microsatellite repeats (Fig. 1a), and all patterns were reproducible using repeated assays. Instability was found in 1 (16.7%) of 6 patients with early GC and in 13 (36.1%) of 36 patients with advanced GC ($P > 0.05$). There was no difference in the frequency of RER(+) between the intestinal type (29.2%, 7/24) and the diffuse (38.9%, 7/18) type of GC ($P > 0.05$).

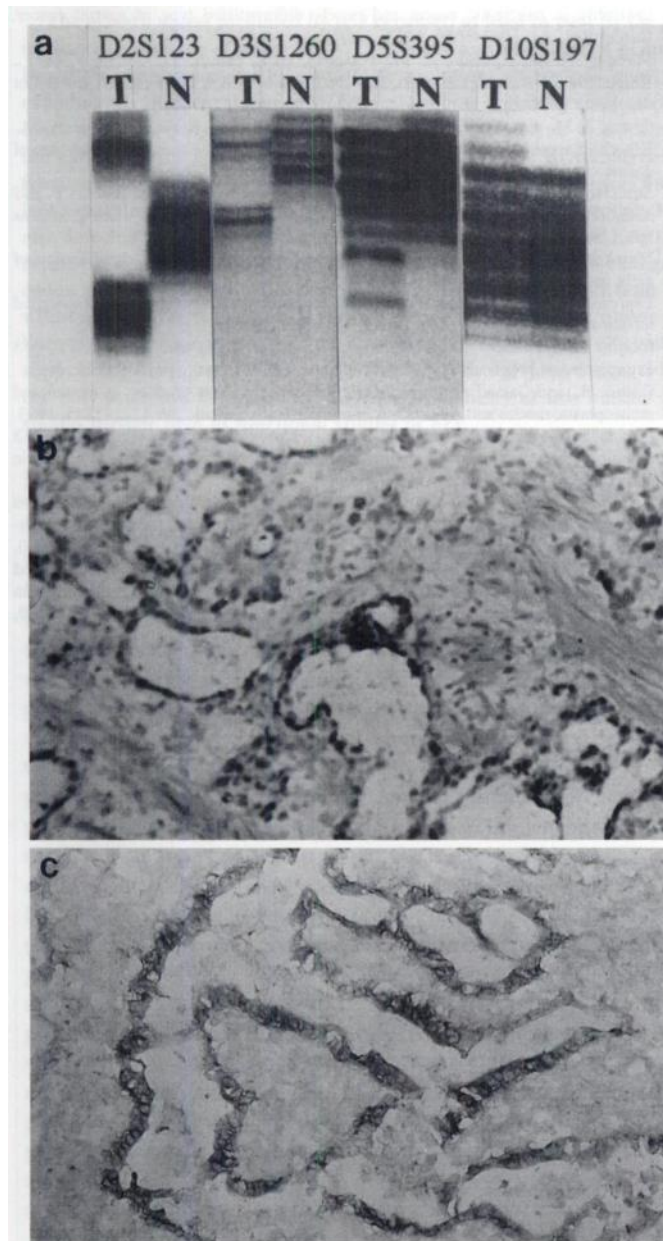


Fig. 1. In a, examples of microsatellite instability include electrophoretic shift and expansion of repeats. T, DNA from tumorous tissues; N, DNA from nontumorous tissues. In b, positive *p53* immunostaining shows strong nuclear immunoreactivity within the carcinoma tissue. In c, positive *erbB-2* immunostaining predominates in the membranes of carcinoma cells.

Table 1 Frequency of positive immunohistochemical stainings of *erbB-2*, *p53*, and *ras* in gastric carcinoma with and without microsatellite instability

	Microsatellite instability		Statistics ^a
	RER(+)	RER(-)	
<i>erbB-2</i>	9/14 ^b (64.3%)	8/28 (28.6%)	$P < 0.05$
<i>p53</i>	5/14 (35.7%)	7/28 (25.0%)	N.S.
<i>ras</i> ^c	1/12 (8.3%)	0/20 (0%)	N.S.

^a Fisher's exact test. N.S., not significant.

^b No. with positive immunohistochemical staining/no. examined.

^c Only 32 cases had enough tissues for analysis of *ras* expression.

Typical examples of positive immunohistochemical staining of *p53* and *erbB-2* are shown in Fig. 1, b and c. The positive rate of immunohistochemical stainings in *ras*, *erbB-2*, and *p53* was 3.1% (1/32), 40.5% (17/42), and 28.6% (12/42), respectively. GC of the intestinal type had a statistically higher positive rate of *p53* (41.7%, 10/24) than that of the diffuse type (11.1%, 2/18; $P < 0.01$ by Fisher's exact test). There is no statistical difference in the positive rate of *erbB-2* between the intestinal type and diffuse type [45.8% (11/24) versus 33.3% (6/18), respectively; $P > 0.05$].

The association between RER(+) and positive immunohistochemical stainings of *erbB-2*, *p53*, and *ras* is shown in Table 1. Nine (64.3%) of 14 cancers exhibiting microsatellite instability also exhibited overproduction of the *erbB-2* oncogene. In contrast, only 8 (28.6%) of 28 cancers without microsatellite instability exhibited *erbB-2* overexpression ($P < 0.05$ by Fisher's exact test). However, the frequency of positive immunostaining to *ras* or *p53* was not statistically different between RER(+) and RER(-) tumors.

Discussion

Microsatellite instability due to RER(+) is a novel genetic mechanism of tumorigenesis (3–5). It has been found in sporadic GC regardless of histological types and may play a role in tumor progression (10–13). The occurrence of RER(+) (33.3%) shown in this report was within the range reported in GC from 22.7 to 62.5% (10–13). Also consistent with other reports (12, 13), we did not find any significant difference in the frequency of RER(+) between the intestinal type and the diffuse type of GC.

Recent studies have indicated sequential changes in oncogenes and tumor suppressor genes in human colorectal carcinoma (1). It is, thus, also important to examine these genetic alterations in the same tumorous tissue so as to understand the multistep nature of carcinogenesis. In GC, abnormalities of *ras*, *erbB-2*, and *p53* have been reported to affect such biological behaviors of the tumor as histopathological type, depth of invasion, lymph node metastasis, and survival (7, 16–18). Mutations of the *p53* gene correlate well with histological subtypes, while the presence of *ras* mutation usually implicates distant metastases and a poor outcome (7). Because there is a good correlation between the genetic change and its oncoprotein production, immunohistochemical analysis is clinically useful and convenient to screen the expression of *ras*, *erbB-2*, and mutant *p53* (9, 17, 18). However, this method does present some limitations. For example, nonsense, frame shift, and silent mutations in the *p53* gene will not result in overexpression of the *p53* protein, which is to be detected by immunohistochemical staining (18). In the present study, enhanced expression of *p53* was noted both in early and advanced GC and was more frequently found in the intestinal type of carcinoma. These results were in agreement with others showing the molecular heterogeneity of these two distinct histological types (18). As for the *ras* expression, there has been marked disparity among previous reports presumably due to variations in the antibodies used, methods of tissue preservation, and extents of epitope presentation (17). Although a very low rate of *ras* expression was noted in the current study, which

is contradictory to some earlier studies, a recent report also confirmed infrequent *ras* mutations in GC using direct DNA sequencing (19).

The *erbB-2/neu* oncogene encodes a transmembranous protein of 185 KDa with tyrosine kinase activity, and its sequence is homologous to that of the epidermal growth factor receptor (20). Various immunohistochemical studies have demonstrated *erbB-2* overexpression ranging from 10 to 55% of patients with GC (9, 20). Despite the existence of conflicting data concerning *erbB-2* oncoprotein expression in different histological types, there is a consensus that *erbB-2* overexpression tends to have a more aggressive phenotype and a poor prognosis in GC (9). In this study, we noted a high positive rate of *erbB-2* (40.5%) in GC, a finding consistent with previous reports. Among them, although the intestinal type of GC appeared to have a higher positive rate of *erbB-2* immunostaining than the diffuse type, it did not reach a statistically significant level.

The interaction between RER and other genetic alterations remains unclear (10–13). Chong *et al.* (12) have demonstrated that chromosomal losses in 5q and 17p occur more frequently in GC with microsatellite instability. Nevertheless, Mironov *et al.* (11) and Strickler *et al.* (13) suggest that RER(+) and p53 mutations are two independent pathways in gastric carcinogenesis. In the present study, we noted that the RER(+) phenotype was not associated with enhanced expression of p53 or *ras*, a finding supporting those of others (11, 13). However, we noted that the RER(+) phenotype was associated with a significantly higher rate of *erbB-2* immunoreactivity, a marker indicative of tumor aggressiveness and poor prognosis (9). The follow-up period of the current study was not long enough to determine whether the strong association of RER with *erbB-2* expression can be used as another marker to predict tumor progression. Such strong association also implies that microsatellite instability may increase the probability of other oncogenic mutations (2). Since the biological significance of microsatellite instability in GC remains unclear, further studies to include more GC cases and to have a longer term of patient follow-ups will be necessary to verify our speculations.

References

1. Vogelstein, B., Fearon, E. R., Hamilton, S. R., Kern, S. E., Preisinger, A. C., Leppert, M., Nakamura, Y., White, R., Smits, A. M. M., and Bos, J. L. Genetic alterations during colorectal tumor development. *N. Engl. J. Med.*, 319: 525–532, 1988.

2. Loeb, L. A. Microsatellite instability: marker of mutator phenotype in cancer. *Cancer Res.*, 54: 5059–5063, 1994.
3. Peltomäki, P., Aaltonen, L. A., Sistonen, P., Pylkkänen, L., Mecklin, J. P., Järvinen, H., Green, J. S., Jass, J. R., Weber, J. L., Leach, F. S., Petersen, G. M., Hamilton, S. R., de la Chapelle, A., and Vogelstein, B. Genetic mapping of a locus predisposing to human colorectal cancer. *Science (Washington DC)*, 260: 810–812, 1993.
4. Aaltonen, L. A., Peltomäki, P., Leach, F. S., Sistonen, P., Pylkkänen, H., Powell, S. M., Jen, J., Hamilton, S. R., Petersen, G. M., Kinzler, K. W., Vogelstein, B., and de la Chapelle, A. Clue to the pathogenesis of familial colorectal cancer. *Science (Washington DC)*, 260: 812–816, 1993.
5. Thibodeau, S. N., Bren, G., and Schaid, D. Microsatellite instability in cancer of the proximal colon. *Science (Washington DC)*, 260: 816–819, 1993.
6. Parkin, D. M., Laara, E., and Muir, C. S. Estimates of the worldwide frequency of sixteen major cancers in 1980. *Int. J. Cancer*, 41: 184–197, 1988.
7. Tahara, E. Molecular mechanism of stomach carcinogenesis. *J. Cancer Res. Clin. Oncol.*, 119: 265–272, 1993.
8. Correa, P., and Shiao, Y. H. Phenotypic and genotypic events in gastric carcinogenesis. *Cancer Res.*, 54: 1941s–1943s, 1994.
9. Yonemura, Y., Ninomiya, I., Ohoyama, S., Kimura, H., Yamaguchi, A., Fushida, S., Kosaka, T., Miwa, K., Miyazaki, I., Endou, Y., Tanaka, M., and Sasaki, T. Expression of c-*erbB-2* oncoprotein in gastric carcinoma. *Cancer (Phila.)*, 67: 2914–2918, 1991.
10. Han, H. J., Yanagisawa, A., Kato, Y., Park, J. G., and Nakamura, Y. Genetic instability in pancreatic cancer and poorly differentiated type of gastric cancer. *Cancer Res.*, 53: 5087–5089, 1993.
11. Mironov, N. M., Aguelon, A. M., Potapova, G. I., Omori, Y., Gorbunov, O. V., Klimentov, A. A., and Yamasaki, H. Alterations of (CA)_n DNA repeats and tumor suppressor genes in human gastric cancer. *Cancer Res.*, 54: 41–44, 1994.
12. Chong, J. M., Fukayama, M., Hayashi, Y., Takizawa, T., Koike, M., Konishi, M., Kikuchi-Yanoshita, R., and Miyaki, M. Microsatellite instability in the progression of gastric carcinoma. *Cancer Res.*, 54: 4595–4597, 1994.
13. Strickler, J. G., Zheng, J., Shu, Q., Burgart, H., Alberts, S. R., and Shibata, F. p53 mutations and microsatellite instability in sporadic gastric cancer: when guardians fail. *Cancer Res.*, 54: 4750–4755, 1994.
14. Murakami, T. Pathomorphological diagnosis. Definition and gross classification of early gastric cancer. *Gann Monogr.*, 11: 53–55, 1971.
15. Lauren, P. The two histological main types of gastric carcinoma diffuse and so-called intestinal type carcinoma. *Acta Pathol. Microbiol. Scand.*, 64: 31–49, 1965.
16. Martin, H. M., Filipe, M. I., Morris, R. W., Lane, D. P., and Silvestre, F. F. p53 expression and prognosis in gastric carcinoma. *Int. J. Cancer*, 50: 859–862, 1992.
17. Gulbis, B., and Galand, P. Immunodetection of the p21-ras products in human and preneoplastic tissues and solid tumor: a review. *Hum. Pathol.*, 24: 1271–1285, 1993.
18. Uchino, S., Noguchi, M., Ochiai, A., Saito, T., Kobayashi, M., and Hirohashi, S. p53 mutation in gastric cancer: a genetic model for carcinogenesis is common to gastric and colorectal cancer. *Int. J. Cancer*, 54: 759–764, 1993.
19. Victor, T., Du Toit, R., Jordaan, A. M., Bester, A. J., and Van Helden, P. D. No evidence for point mutations in codon 12, 13, and 61 of the *ras* gene in a high-incidence area for esophageal and gastric cancers. *Cancer Res.*, 50: 4911–4914, 1990.
20. Kameda, T., Yusui, W., Yoshida, K., Tsujino, T., Nakayama, H., Ito, M., Ito, H., and Tahara, E. Expression of *ERBB2* in human gastric carcinomas: relationship between p185^{ERBB2} expression and the gene amplification. *Cancer Res.*, 50: 8002–8009, 1990.