

Clinicopathological Significance of Altered Loci of Replication Error and Microsatellite Instability-associated Mutations in Gastric Cancer¹

Ming-Shiang Wu, Chung-Wei Lee, Chia-Tung Shun, Hsiu-Po Wang, Wei-Jei Lee, Jin-Chuan Sheu, and Jaw-Town Lin²

Departments of Internal Medicine [M-S. W., C-W. L., J-C. S., J-T. L.], Pathology [C-T. S.], Emergency Medicine [H-P. W.], and Surgery [W-J. L.], National Taiwan University Hospital, Taipei, Taiwan, Republic of China

ABSTRACT

Replication errors (RERs) judged by microsatellite instability and its associated mutations have been recognized as an important mechanism in tumorigenesis of gastric cancers (GCs). To gain a deeper insight into its significance, we examined the frequency of RERs using nine microsatellite markers and screened mutations in the polydeoxyadenine tract of the transforming growth factor β type II receptor gene (*TGF- β RII*) and polydeoxyguanine tracts of insulin-like growth factor II receptor and *BAX* genes. Twenty-four (30%) of 80 patients with GC had RERs, of which 3, 8, and 13 had one, two, and three or more loci, respectively. In 13 tumors with RERs in three or more loci, frameshift mutations of *TGF- β RII*, insulin-like growth factor II receptor, and *BAX* were identified in 12, 3, and 2, respectively. Compared with GC with none, one or two RER-positive loci as a group, GC with RERs in three or more loci showed a significantly higher frequency of antral location (12 of 13 versus 35 of 67; $P = 0.01$), intestinal subtype (11 of 13 versus 30 of 67; $P = 0.01$), and previous *Helicobacter pylori* infection (12 of 13 versus 41 of 67; $P = 0.05$) and a lower incidence of lymph node metastasis (5 of 13 versus 49 of 67; $P = 0.02$) and tended to be in an advanced stage (12 of 13 versus 54 of 67; $P = 0.28$). These data indicate that GC with multiple RERs manifest distinct clinicopathological characteristics, and that a high frequency of frameshift mutations involving the *TGF- β RII* gene may be causatively linked with tumorigenesis and progression.

INTRODUCTION

Tumorigenesis is a multistep process leading to accumulation of multiple genetic alterations (1). Because the rate of spontaneous mutation is low in normal cells, a mutator phenotype characterized by an increased mutation rate is required to achieve final malignant transformation (2). This notion is strongly supported by recent demonstration of genome-wide instability of repetitive sequences (*i.e.*, microsatellites) in HNPCC³ and in a certain portion of sporadic tumors (3, 4). Such variations in microsatellites, namely, MSI or ubiquitous somatic mutations, are generated by errors in DNA replication, and hence the phenotype has been named RER-positive (3-5). RER-positive colonic cancer exhibits distinct clinicopathological characteristics and a tendency to accumulate frameshift mutations in polydeoxyadenine tract (A)₁₀ of the *TGF- β RII* gene and polydeoxyguanine tract (G)₈ of the *IGFIIR* and *BAX* genes (6-9). Additional information suggests that mutations of *TGF- β RII* and *IGFIIR* are mutually exclusive in RER-positive cancer (8). However, data concerning frameshift mutations of *TGF- β RII*, *IGFIIR*, and *BAX* genes

are scant in tumors other than colonic cancers, and their interrelationship remains unclear, especially with respect to clinicopathological characteristics of the tumor (10-15).

GC remains a common disease with a dismal prognosis in the world (16). Both genetic and environmental factors are important in gastric tumorigenesis. MSI has been reported as a feature of HNPCC-associated GC, and a certain portion of sporadic GCs also exhibit RER phenotypes (17). However, whether the RER-positive GC can be ascribed to a specific phenotype with distinct clinicopathological features is controversial (18). Moreover, the frequency of MSI and MSI-associated mutations vary widely, ranging from 15 to 64% for MSI (19-25) and 0 to 91% for *TGF- β RII* (10-15). Although variations in different susceptible populations and etiological factors partly explain the discrepancy, the lack of uniformity of criteria to define MSI could also contribute to the above variability (18). For example, different altered numbers of microsatellite markers have been used to distinguish intrinsic instability from pathological genome-wide instability germane to cancers with a mutator phenotype. Recently, Dos Santos *et al.* (26) have reported that GCs with multiple (three or more) RER-positive loci have a clinicopathological profile different from GCs with a single RER-positive locus or two RER-positive loci, of which the profile is similar to that of RER-negative GC. Others proposed further to adopt similar, more stringent criteria, such as the presence of more than one microsatellite alteration together with mutations in the target gene of *TGF- β RII* to ascribe a meaningful RER phenotype (27).

As a group, we have confirmed previously the frequent occurrence of an RER-positive phenotype in GC and have reported infrequent mutations of *hMSH2* gene in sporadic RER-positive GC (28-30). To define the precise role of MSI in GC better, we herein extended our study to 80 patients with GC by analyzing nine microsatellite markers and screening frameshift mutations of *TGF- β RII*, *IGFIIR*, and *BAX* genes. Specifically, we adopted similar stringent criteria to define the RER-positive phenotype and to elucidate the relationship among RER status, clinicopathological features, and MSI-associated mutations.

MATERIALS AND METHODS

Patients and Tissues Samples. In total, 80 patients with histologically confirmed GC were included in this study. Among them, 59 patients have been reported previously (29). All 80 patients underwent surgery at the National Taiwan University Hospital without receiving previous chemotherapy or radiation therapy. Surgical specimens were handled according to the guidelines issued by the Japanese Research Society of GC (31). All GC tissues were examined by the same pathologist (C-T. S.), who was unaware of the parameters to be investigated. These tumors were classified into 14 early GC and 66 advanced GC according to the depth of invasion (31). Furthermore, they were also categorized into 41 intestinal type and 39 diffuse type based on the classification of Lauren (32). Relevant demographic and clinicopathological information for each patient was obtained from medical records. None had a family history suggestive of HNPCC. The status of *Helicobacter pylori* infection was determined by the presence of a significantly high titer of anti-*H. pylori* IgG in the preoperative serum.

Both tumorous and nontumorous tissues were dissected separately from each resected specimen, frozen immediately in the embedding compound

Received 8/12/97; accepted 1/28/98.

The costs of publication of this article were defrayed in part by the payment of page charges. This article must therefore be hereby marked *advertisement* in accordance with 18 U.S.C. Section 1734 solely to indicate this fact.

¹ This work was supported by National Taiwan University Hospital Grant NTUH-M87103, National Science Council Grant NSC-85-2622-B002-011 and NSC87-2314-B002-187, and Department of Health, Executive Yuan, Taiwan Grants DOH87-TD-1045 and DOH87-HR-525.

² To whom requests for reprints should be addressed, at Department of Internal Medicine, National Taiwan University Hospital, 7 Chun-Shan S. Road, Taipei, Taiwan, Republic of China, 100.

³ The abbreviations used are: HNPCC, hereditary nonpolyposis colorectal cancer; MSI, microsatellite instability; RER, replication error; *TGF- β RII*, transforming growth factor β type II receptor; *IGFIIR*, insulin-like growth factor II receptor; GC, gastric cancer.

(Miles, Inc., Elkhart, IN), and stored at -80°C until use. Cryosections of 5-7 µm were prepared for each tumorous tissue, and sections containing predominantly neoplastic cells were used to prepare genomic DNA by a conventional procedure. From the same patient, the nontumorous tissue showing neither dysplasia nor metaplasia was similarly extracted as a control.

Microsatellite Analysis. Nine primers, including D2S114, D2S123, D3S1260, D3S1283, D2S1389, D5S395, D10S193, D10S197, and D17S785, were obtained from Research Genetics for the analysis of MSI. PCR was performed in 25-µl reaction volumes containing a 5 µM concentration of each primer, 0.125 mM dATP, 1.25 mM dGTP, dCTP, and dTTP, 3 µCi of [α -³²S]dATP, 25 ng of the patient's DNA, and 0.75 units of *Taq* DNA polymerase. Reaction conditions were 30 s at 94°C, 75 s at 55°C, and 15 s at 72°C for 27 cycles, followed by a final extension of 5 min at 72°C (28, 29). The PCR products were diluted in a ratio of 3:2 by the loading buffer, heated at 95°C for 5 min, and loaded (5 µl) onto 7% sequencing gels. After electrophoresis, gels were dried at 80°C and exposed to X-ray film. The band pattern was compared between tumorous and nontumorous tissues for each patient. To avoid PCR artifacts, all positive tests were duplicated.

Frameshift Mutation Analysis. The primers used for genomic *TGF-βRII*, *IGFIIR*, and *BAX* were synthesized from nucleotide positions containing (A)₁₀ for *TGF-βRII* and (G)₈ for *IGFIIR* and *BAX*. The sequences of these primers were as follows: *TGF-βRII*, 5'-ACTAGAGACAGTTTGGCCATGA-3' (sense) and 5'-ATATTCTTCTGAGAAGATGATG-3' (antisense); *IGFIIR*, 5'-GCAGGTCTCCTGACTCAGAA-3' (sense) and 5'-GAAGAAGATGGCTGTG-GAGC-3' (antisense); and *BAX*, 5'-ATCCAGGATCGAGCAGGGCG-3' (sense) and 5'-ACTCGCTCAGCTTCTGGTG-3' (antisense). After amplification, the PCR products were 73 bp for *TGF-βRII*, 111 bp for *IGFIIR*, and 94 bp for *BAX* (7-9). The PCR reaction buffer was similar to that used for microsatellite analysis as mentioned above, except that 5 nM 5'-³²P end labeling was used instead of internal labeling. The reaction condition consisted of hot start denaturing for 5 min at 94°C, followed by five cycles of 1 min at 94°C, 1 min at 58°C, and 40 s at 72°C, and then followed by 26 cycles of 1 min at 94°C, 40 s at 55°C, and 20 s at 72°C. No final extension was used. DNA denaturation, electrophoresis, and autoradiography were performed as that used for the microsatellite analysis. Mutations appeared as alterations in the PCR-specific length in tumorous DNA compared with that detected in nontumorous DNA.

Statistical Analysis. Statistical evaluation was performed with the χ^2 test, Fisher's exact test, or Student's *t* test. *P* < 0.05 was considered statistically significant.

RESULTS

Alterations of electrophoretic patterns of PCR products of nine microsatellite markers, the (A)₁₀ tract of the *TGF-βRII* gene, and (G)₈ tracts of *IGFIIR* and *BAX* genes were compared between tumorous and nontumorous DNA in each patient. MSI was found in at least one locus in 24 (30%) of the 80 GC patients. The demographic data, tumor characteristics, RER status, and MSI-associated mutations of these 24 patients with MSI are listed in Table 1. Among them 3, 8, and 13 patients had RER at one, two, and three or more loci, respectively. Altered band patterns of *TGF-βRII*, *IGFIIR*, and *BAX* were identified in 12, 3, and 2, respectively, of these 24 patients with RER-positive tumors but none in the remaining 56 patients with RER-negative tumors (Fig. 1; *P* < 0.05). Variable amounts of host stromal tissues were noted in tumor sites, thus precluding accurate determination of the heterozygous or homozygous status of these genes with respect to frameshift mutations. Nevertheless, comparison of the proportion of wild-type versus mutant alleles suggested that some patients (Fig. 1, *GC-15* and *GC-16*) might have homozygous *TGF-βRII* mutations. Intriguingly, 12 of 13 tumors with three or more RER-positive loci showed frameshift mutations involving *TGF-βRII*. Among these 12 patients, 3 had an additional mutation involving *IGFIIR* (1 patient), *BAX* (1 patient), and *IGFIIR* and *BAX* (1 patient). No anticorrespondence of these three gene mutations was noted in our tumors. Furthermore, these 12 GCs with *TGF-βRII* mutations exhibited tended to have distal location (11 antrum and 1 body), an advanced stage (11 advanced GC and 1 early GC), and the intestinal subtype (10 intestinal and 2 diffuse).

After having verified that frameshift mutations of all three *TGF-βRII*, *IGFIIR*, and *BAX* genes occurred exclusively in tumors with RER in three or more loci, we divided these 80 patients into the following three groups: a group of 56 RER-negative patients, a group of 11 RER-positive patients with one or two loci, and a group of 13 RER-positive patients with three or more loci. Their clinicopathological profiles and genetic alterations are summarized in Table 2. Compared with the first two groups with none or one to two RER-positive loci, the last group with at least three RER-positive loci showed a

Table 1 Summary of clinicopathologic data, RER status, and frameshift mutations of *TGFβRII*, *IGFIIR*, and *BAX* genes in 24 GCs with MSI

Case	Sex	Age (yr)	Stage ^a	Subtype ^b	Location ^c	RER ^d	<i>TGFβRII</i> ^e	<i>IGFIIR</i>	<i>BAX</i>
1	M	35	A	D	B	+	N	N	N
2	M	74	A	I	A	+++	-1	N	N
3	M	65	A	I	C	++	N	N	N
4	F	47	A	D	A	+++	-1	N	N
5	F	80	A	I	A	+++	-2	N	N
6	M	75	A	I	A	+++	N	N	N
7	M	75	A	I	C	+	N	N	N
8	F	65	A	I	A	+++	-2	N	N
9	M	42	A	I	A	+++	-1	N	N
10	M	66	A	I	A	+++	-1	N	N
11	M	70	A	I	C	++	N	N	N
12	F	41	E	D	A	++	N	N	N
13	M	68	A	I	B	+++	-2	-1	-1
14	F	63	A	D	C	++	N	N	N
15	M	79	E	I	A	+++	-1	-1	N
16	M	67	A	I	A	+++	-1	N	N
17	F	42	A	D	B	+	N	N	N
18	M	68	A	I	A	+++	-2	N	-1
19	F	38	A	D	A	+++	-1	+1	N
20	M	61	A	D	B	++	N	N	N
21	F	68	A	I	A	+++	-2	N	N
22	M	67	A	I	B	++	N	N	N
23	F	58	A	D	A	++	N	N	N
24	F	73	E	I	A	++	N	N	N

^a E, early gastric cancer; A, advanced gastric cancer.

^b D, diffuse type; I, intestinal type.

^c A, antrum; B, body; C, cardia.

^d +, RER at one locus; ++, RER at two loci; +++, RER at three or more loci.

^e N, negative for mutation; -1, one base deletion; -2, two base deletions; +1, one base insertion.

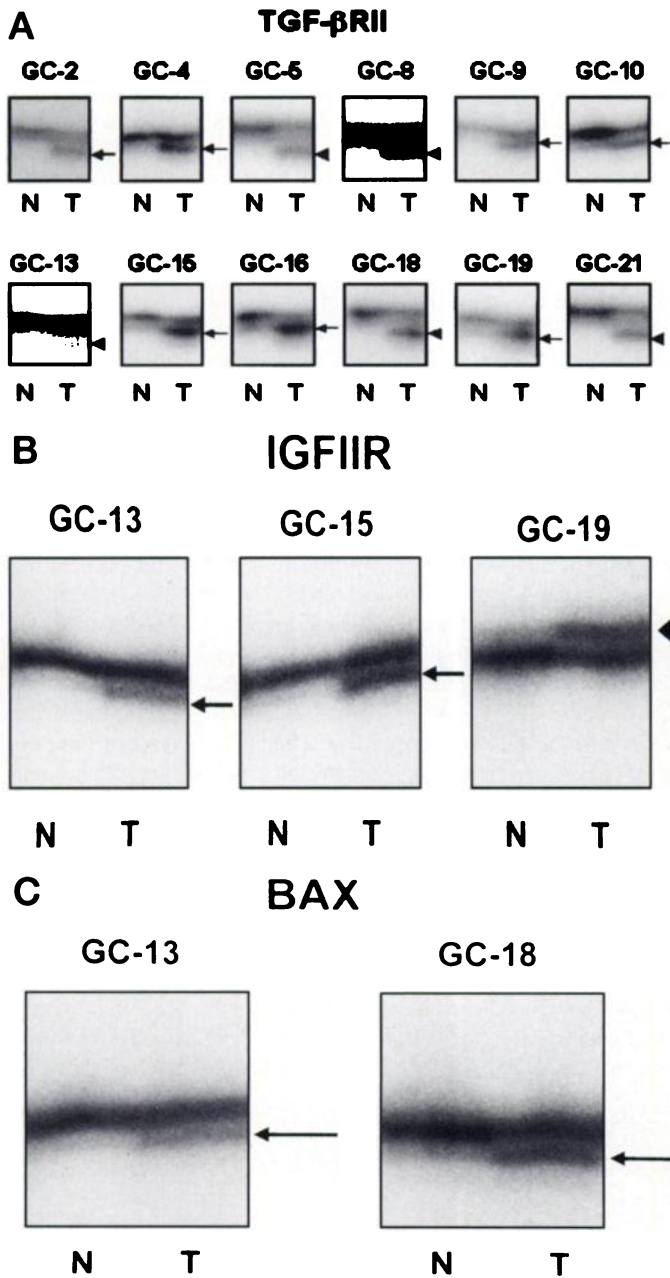


Fig. 1. A, mutation at 10 deoxyadenine repeats of the *TGF-βRII* gene. Abnormal bands with one base deletion (arrows) or two base deletions (arrowhead) are noted in tumorous DNA (T) but not in nontumorous DNA (N). B, mutation at eight deoxyguanine repeats of the *IGFIIR* gene. Abnormal bands with one base deletion (arrow) or one base insertion (arrowhead) are noted. C, mutation at eight deoxyguanine repeats of the *BAX* gene. Abnormal bands with one base deletion (arrow) are noted.

significantly higher frequency of antral location (12 of 13 versus 35 of 67; $P = 0.01$), intestinal subtype (11 of 13 versus 30 of 67; $P = 0.01$), and positive *H. pylori* infection by serology (12 of 13 versus 41 of 67; $P = 0.05$) and a lower incidence of lymph node metastasis (5 of 13 versus 49 of 67; $P = 0.02$). There was also a trend for these tumors with multiple RER to be in an advanced stage (12 of 13 versus 54 of 67, without reaching a statistical difference; $P = 0.28$).

DISCUSSION

Our study shows that 30% of 80 sporadic GCs have MSI in at least one locus, a frequency falling within the reported range of 15–64% (19–26). As in colonic cancers, our study further shows that distinct

clinicopathological features can be identified in GC with MSI reflected by RER. Specifically, a similar clinicopathological profile was noted between RER-negative GC and RER-positive GC with one or two loci. In contrast, RER-positive GCs with three or more loci prefer antral location, an intestinal type, and a more advanced stage, but less lymph node metastasis. Our result is in agreement with that reported by Dos Santos *et al.* (26), who suggested that multiple RER-positive GCs show distinct features indicative of a mutator phenotype. However, it should be noted that discrepancies in stage, histology, or location between RER-positive and RER-negative GC have been reported (19–26). Such discrepancies have been attributed to ethnic or etiological factors and recently to inconsistent criteria used to define MSI (18). As demonstrated herein and consistent with others (13, 26), there are indeed two kinds of GC phenotypes when a more stringent criterion to assign the RER phenotype is adopted to distinguish the high-level (or widespread) instability and the low-level instability.

The significance of such a distinction can be shown by the study of MSI-associated mutations. Our result showed that 12 of 13 tumors with multiple RER foci had deletions of one or two bases in the polydeoxyadenine tract of *TGF-βRII*. This finding is supportive of those of Myeroff *et al.* (10) and Chung *et al.* (13) but different from that of Souza *et al.* (14). Given the important role of *TGF-β* in controlling cell growth, differentiation, morphogenesis, and immune function (33), inactivation of *TGF-βRII* might affect the development and progression of RER-positive tumors. With regard to the pathological phenotype, we noted that 10 of 12 such tumors were of the intestinal type, exhibiting well-formed tubules, and the remaining two had the diffuse type, with signet ring cells expressing mucins. Both histological features of tubular formation and mucin expression have been correlated with *in vitro* *TGF-β1* effects (33). Unlike HNPCC, in which MSI and *TGF-βRII* mutations are an early event (34), 12 of 13 GCs with multiple RER and *TGF-βRII* mutations were all associated with an advanced stage, and the remaining one was an early adenoma with a malignant change. Therefore, we speculate that MSI in GC targeting the *TGF-βRII* gene may lead to the development of a more-differentiated phenotype at a more advanced stage.

Table 2 Clinicopathologic characteristics and genetic alterations of 80 GCs with relation to altered numbers of replication RER

	RER(-) (n = 56)	RER(+) at 1 or 2 loci (n = 11)	RER(+) at ≥3 loci (n = 13)	P ^a
Sex (F/M)	27/29	5/6	5/8	>0.05
Age (yr)	61.6 ± 10.2	59.7 ± 12.8	64.4 ± 13.6	>0.05
Tumor diameter (cm)	5.27 ± 2.41	5.19 ± 3.11	5.92 ± 2.96	>0.05
Tumor location				
Antrum	32	3	12	
Body	17	4	1	0.01
Cardia	7	4	0	
Depth of invasion				
Advanced	45	9	12	
Early	11	2	1	0.28
Histologic subtype				
Intestinal	25	5	11	0.01
Diffuse	31	6	2	
<i>H. pylori</i> infection				
Positive	35	6	12	0.05
Negative	21	5	1	
Lymph node metastasis				
Positive	40	9	5	0.02
Negative	16	2	8	
<i>TGFβRII</i> mutation				
Positive	0	0	12	<0.01
Negative	56	11	1	
<i>IGFIIR</i> mutation				
Positive	0	0	3	<0.01
Negative	56	11	10	
<i>BAX</i> mutation				
Positive	0	0	2	0.03
Negative	56	11	11	

^a P: RER(+) at three or more loci versus RER(-) and RER(+) at one or two loci.

In addition to the *TGF-βRII* gene, genetically unstable tumor cells also express mutations in polydeoxyguanine tracts of *IGFIIR* and *BAX* genes (7–9). It has been shown that 25% of RER-positive GCs have frameshift mutations in the *IGFIIR* gene (17), whereas 50% of RER-positive colonic cancers exhibit frameshift mutations in the *BAX* gene (9). Unlike Souza *et al.* (8), who reported that mutations of *IGFIIR* and *TGF-βRII* are mutually exclusive in RER-positive GC, the present study showed that 3 (23.1%) and 2 (15.4%) of 13 GCs with multiple RER foci had mutations of *IGFIIR* and *BAX*, respectively. All of these tumors with *IGFIIR* or *BAX* mutations also had mutations in *TGF-βRII*. These data prompt us to surmise that mutation rates exist in different repeat sequences of different genes in cancer cells of a mutator phenotype, and that disruption of the TGF-β signaling pathway by inactivating *TGF-βRII* may be a common oncogenic pathway in RER-positive tumors.

Another identified feature of RER-positive GC is previous *H. pylori* infection, which has been considered one of risk factors for GC (16). It has been speculated that *H. pylori*-induced chronic inflammation of gastric mucosa may enhance the cell turnover rate, which in turn can increase the likelihood of DNA damage in response to environmental mutagens (35). Thus we wonder whether *H. pylori*-induced DNA damage may result in somatic mutations and may cause MSI and subsequent *TGF-βRII* mutation (13). Because both features of distal tumor location and the intestinal subtype can be associated frequently with *H. pylori* infection or GC with multiple RER independently (16), additional studies are needed to clarify the role of *H. pylori* in gastric tumorigenesis.

REFERENCES

1. Fearon, E. R., and Vogelstein, B. A genetic model for colorectal tumorigenesis. *Cell*, 61: 759–767, 1990.
2. Loeb, L. A. Mutator phenotype may be required for multistage carcinogenesis. *Cancer Res.*, 51: 3075–3079, 1991.
3. Peltomaki, P., Lothe, R. A., Aaltonen, L. A., Pylkkanen, L., Nystrom-Lahti, M., Seruca, R., David, L., Holm, R., Ryberg, D., Haugen, A., Brogger, A., Borresen, A. L., and de la Chapelle, A. Microsatellite instability is associated with tumor that characterized the hereditary nonpolyposis colorectal carcinoma syndrome. *Cancer Res.*, 53: 5853–5855, 1993.
4. Ionov, Y., Peinado, M. A., Malkhosyan, S., Shibata, D., and Perucho, M. Ubiquitous somatic mutations in simple repeated sequences reveal a new mechanism for colonic carcinogenesis. *Nature (Lond.)*, 363: 558–561, 1993.
5. Aaltonen, L. A., Peltomaki, P., Leach, F. S., Sistonen, P., Pylkkanen, L., Mecklin, J. P., Jarvinen, H., Powell, S. M., Jen, J., Hamilton, S. R., Petersen, G. M., Kinzler, K. W., Vogelstein, B., and de la Chapelle, A. Clues to the pathogenesis of familial colorectal cancer. *Science (Washington DC)*, 260: 812–816, 1993.
6. Thibodeau, S. N., Bren, G., and Schaid, D. Microsatellite instability in cancer of the proximal colon. *Science (Washington DC)*, 260: 816–819, 1993.
7. Markowitz, S., Wang, J., Myeroff, L., Parson, R., Sun, L., Lutterbaugh, J., Fan, R. S., Zborowska, E., Kinzler, K. W., Vogelstein, B., Brattain, M., and Willson, J. K. V. Inactivation of the type II TGF-β receptor in colon cancer cells with microsatellite instability. *Science (Washington DC)*, 268: 1336–1338, 1995.
8. Souza, R. F., Appel, R., Yin, J., Wang S., Smolinski, K. N., Abraham, J. M., Zou, T. T., Shi, Y. Q., Lei, J., Cottrell, J., Cymes, K., Biden, K., Simms, L., Leggett, B., Lynch, P. M., Frazier, M., Powell, S. M., Harpaz, N., Sugimura, H., Young, J., and Meltzer, S. J. Microsatellite instability in the insulin-like growth factor II receptor gene in gastrointestinal tumors. *Nat. Genet.*, 14: 255–257, 1996.
9. Rampino, N., Yamamoto, H., Ionov, Y., Li, Y., Sawai, H., Reed, J. C., and Perucho, M. Somatic frameshift mutations in the *BAX* gene in colon cancers of the microsatellite mutator phenotype. *Science (Washington DC)*, 275: 967–969, 1997.
10. Myeroff, L. L., Parsons, R., Kim, S. J., Hedrick, L., Cho, K. R., Orth, K., Mathis, M., Kinzler, K. W., Lutterbaugh, J., Park, K., Bang, Y. J., Lee, H. W., Park, J. G., Lynch, H. T., Roberts, A. B., Vogelstein, B., and Markowitz, S. D. A transforming growth factor β receptor type II gene mutation common in colon and gastric but rare in endometrial cancers with microsatellite instability. *Cancer Res.*, 55: 5545–5547, 1995.

11. Ohue, M., Tomita, N., Monden, T., Miyoshi, Y., Ohnishi, T., Izawa, H., Kawabata, Y., Sasaki, M., Sekimoto, M., Nishisho, I., Shiozaki, H., and Monden, M. Mutations of the transforming growth factor β type II receptor gene and microsatellite instability in gastric cancer. *Int. J. Cancer*, 68: 203–206, 1996.
12. Renault, B., Calistri, D., Buonsanti, G., Nanni, O., Amadori, D., and Ranzani, G. N. Microsatellite instability and mutations of p53 and TGF-βRII genes in gastric cancer. *Hum. Genet.*, 98: 601–607, 1996.
13. Chung, Y. J., Song, J. M., Lee, S. Y., Jung, Y. T., Seo, E. J., Choi, S. W., and Rhyu, M. G. Microsatellite instability-associated mutations associate preferentially with intestinal type of primary gastric carcinomas in a high-risk population. *Cancer Res.*, 56: 4662–4665, 1996.
14. Souza, R. F., Lei, J., Yin, J., Appel, R., Zou, T. T., Zhou, X., Wang, S., Rhyu, M. G., Cymes, K., Chan, O., Park, W. S., Krasna, M. J., Greenwald, B. D., Cottrell, J., Abraham, J. M., Simms, L., Leggett, B., Young, J., Harpaz, N., and Meltzer, S. J. A transforming growth factor β receptor type II mutation in ulcerative colitis-associated neoplasms. *Gastroenterology*, 112: 40–45, 1997.
15. Ouyang, H., Shiwaku, H. O., Hagiwara, H., Miura, K., Abe, T., Kato, Y., Ohtani, H., Shiiba, K., Souza, R. F., Meltzer, S. J., and Horii, A. The insulin-like growth factor II receptor gene is mutated in genetically unstable cancers of the endometrium, stomach, and colorectum. *Cancer Res.*, 57: 1851–1854, 1997.
16. Fuchs, C. S., and Mayer, R. J. Gastric carcinoma. *N. Engl. J. Med.*, 333: 32–41, 1995.
17. Chung, D. C., and Rustgi, A. K. DNA mismatch and cancer. *Gastroenterology*, 109: 1685–1699, 1995.
18. Grady, W., Rajput, A., Myeroff, L., and Markowitz, S. What's new with RII. *Gastroenterology*, 112: 297–302, 1997.
19. Han, H. J., Yanagisawa, A., Kato, Y., Park, J. G., and Nakamura, Y. Genetic instability in pancreatic cancer and poorly differentiated type of gastric cancer. *Cancer Res.*, 53: 5087–5089, 1993.
20. Chong, J. M., Fukayama, M., Hayashi, Y., Takizawa, T., Koike, M., Konishi, M., Kikuchi-Yanoshita, R., and Miyaki, M. Microsatellite instability in the progression of gastric cancer. *Cancer Res.*, 54: 4595–4597, 1994.
21. Mironov, N. M., Aguelon M. A. M., Potapova, G. I., Omori, Y., Gorbunov, O. V., Klimenkov, A. A., and Yamasaki, H. Alterations of (CA)_n DNA repeats and tumor suppressor genes in human gastric cancer. *Cancer Res.*, 54: 41–44, 1994.
22. Rhyu, M. G., Park, W. S., and Meltzer, S. J. Microsatellite instability occurs frequently in human gastric carcinoma. *Oncogene*, 9: 29–32, 1994.
23. Strickler, J. G., Zheng, J., Shu, Q., Burgart, L. J., Alberts, S. R., and Shibata, D. p53 mutations and microsatellite instability in sporadic gastric cancer: when guardians fail. *Cancer Res.*, 54: 4750–4755, 1994.
24. Tamura, G., Sakata, K., Maesawa, C., Suzuki, Y., Terashima, M., Satoh, K., Sekiyama, S., Suzuki, A., Eda, Y., and Satodate, R. Microsatellite alterations in adenoma and differentiated adenocarcinoma of the stomach. *Cancer Res.*, 55: 1933–1936, 1995.
25. Semba, S., Yokozaki, H., Yamamoto, S., Yasui, W., and Tahara, E. Microsatellite instability in precancerous lesions and adenocarcinomas of the stomach. *Cancer (Phila.)*, 77: 1620–1627, 1996.
26. Dos Santos, N. R., Seruca, R., Constanca, M., Seixas, M., and Sobrinho-Simoes, M. Microsatellite instability at multiple loci in gastric carcinoma: clinicopathologic implications and prognosis. *Gastroenterology*, 110: 38–44, 1996.
27. Perucho, M. Microsatellite instability: the mutator that mutates the other mutator. *Nat. Med.*, 2: 630–631, 1996.
28. Lin, J. T., Wu, M. S., Shun, C. T., Lee, W. J., Sheu, J. C., and Wang, T. H. Occurrence of microsatellite instability in gastric cancer is associated with enhanced expression of erbB-2 oncoprotein. *Cancer Res.*, 55: 1428–1430, 1995.
29. Lin, J. T., Wu, M. S., Shun, C. T., Lee, W. J., Wang, J. T., Wang, T. H., and Sheu, J. C. Microsatellite instability in gastric carcinoma with special reference to histopathology and cancer stages. *Eur. J. Cancer*, 31: 1874–1882, 1995.
30. Wu, M. S., Sheu, J. C., Shun, C. T., Lee, W. J., Wang, J. T., Wang, T. H., Cheng, A. L., and Lin, J. T. Infrequent hMSH2 mutations in sporadic gastric adenocarcinoma with microsatellite instability. *Cancer Lett.*, 112: 161–166, 1997.
31. Japanese Research Society for Gastric Cancer. Japanese Classification of Gastric Carcinoma, 1st English Ed. Tokyo: Kanehara Co., 1995.
32. Lauren, P. The two histological main types of gastric carcinoma diffuse and so-called intestinal type carcinoma. *Acta. Pathol. Microbiol. Scand.*, 64: 31–49, 1965.
33. Fynan, T. M., and Reiss, M. Resistance to inhibition of cell growth by transforming growth factor-β and its role in oncogenesis. *Crit. Rev. Oncog.*, 4: 493–540, 1993.
34. Konishi, M., Kikuchi-Yanoshita, R., Tanaka, K., Muraoka, M., Onda, A., Okumura, Y., Kishi, N., Iwama, T., Mori, T., Koike, M., Ushio, K., Chiba, M., Nomizu, S., Konishi, F., Utsunomiya, J., and Miyaki, M. Molecular nature of colon tumors in hereditary nonpolyposis colon cancer, familial polyposis, and sporadic colon cancer. *Gastroenterology*, 111: 307–317, 1996.
35. Blaser, M. J., and Parsonnet, J. Parasitism by the “slow” bacterium *Helicobacter pylori* leads to altered gastric homeostasis and neoplasia. *J. Clin. Invest.*, 94: 4–8, 1994.

Downloaded from http://asciournals.org/ascancer/article-pdf/58/7/1497/2469250/e0580071494.pdf by guest on 10 December 2022