

## Brief Genetics Report

# PPARG F388L, a Transactivation-Deficient Mutant, in Familial Partial Lipodystrophy

Robert A. Hegele,<sup>1</sup> Henian Cao,<sup>1</sup> Christy Frankowski,<sup>2</sup> Suresh T. Mathews,<sup>3</sup> and Todd Leff<sup>3</sup>

**Autosomal dominant familial partial lipodystrophy (FPLD) due to mutant *LMNA* encoding nuclear lamin A/C is characterized by adipose tissue repartitioning together with multiple metabolic disturbances, including insulin resistance and dyslipidemia. There is emerging evidence that some rare mutations in peroxisome proliferator-activated receptor- $\gamma$  (PPAR- $\gamma$ ), encoded by *PPARG*, might be associated with human lipodystrophy. We report a three-generation Canadian kindred ascertained based upon partial lipodystrophy, with a normal *LMNA* gene sequence. Candidate gene sequencing showed that all four affected subjects were heterozygous for a novel T $\rightarrow$ A mutation at *PPARG* nucleotide 1164 in exon 5 that predicted substitution of phenylalanine at codon 388 by leucine (F388L). The mutation was absent from normal family members and normal unrelated subjects, and altered a highly conserved residue within helix 8 of the predicted ligand-binding pocket of PPAR- $\gamma$ . The mutant receptor had significantly decreased basal transcriptional activity and impaired stimulation by a synthetic ligand. The germline transmission of a transactivation-deficient mutation in *PPARG* suggests that autosomal dominant partial lipodystrophy is genetically heterogeneous. Our findings are consistent with the idea that mutant *PPARG* can underlie the partial lipodystrophy phenotype. *Diabetes* 51:3586–3590, 2002**

**A**utosomal dominant familial partial lipodystrophy (FPLD) is characterized by adipose tissue repartitioning, typically with peripheral fat loss and central fat accumulation (1,2). In Dunnigan-type partial lipodystrophy (FPLD; MIM 151660), affected subjects have total loss of subcutaneous adipose tissue from extremities, with sparing of head, neck, and abdominal fat depots, and multiple metabolic disturbances including insulin resistance, diabetes, and dyslipidemia (1,2). Early atherosclerosis is seen in some FPLD kindreds (3). Mutations in *LMNA* (MIM 150330) encoding nuclear

lamin A/C cause FPLD (4–6). However, there may be other genetic etiologies for partial lipodystrophy. For instance, a single patient with partial lipodystrophy and normal *LMNA* was heterozygous for a missense mutation, R425C, in *PPARG* (MIM 601487) encoding peroxisome proliferator-activated receptor (PPAR)- $\gamma$  (7). Mutation of this gene would not be an unexpected cause of partial lipodystrophy, given the role of the gene product in adipocyte biology (8). However, there was no functional assessment of *PPARG* R425C and no demonstration of germline transmission (7). Heterozygotes for dysfunctional *PPARG* mutations had insulin resistance (9). We now report a family with three generations of subjects with partial lipodystrophy in whom the *LMNA* gene was normal and a dysfunctional mutation in *PPARG* cosegregated with the lipodystrophy phenotype.

The study kindred was ascertained by a clinical diagnosis of partial lipodystrophy through the Endocrinology Clinic, which had earlier diagnosed 22 Canadian FPLD patients with mutant *LMNA* (3,4). A clinical diagnosis of partial lipodystrophy was made in the proband (Fig. 1; III-2) and her daughter (Fig. 1; IV-1). The proband (III-2) was a 46-year-old woman of Anglo-Saxon descent who had been diagnosed with partial lipodystrophy based upon prominent muscularity of her calves and lower arms, marked atrophy of gluteal fat, and marked centripetal distribution of adipose tissue, with accumulation of subcutaneous facial, neck, suprascapular, and abdominal fat. The abnormal fat distribution had been present since adolescence. Clinically, the phenotype was similar to FPLD seen in the Canadian index probands with missense mutations in *LMNA* (3,4). However, differentiating features included the presence of some subcutaneous upper arm fat to the level of the surgical neck of the humerus, no phlebectasia, and less prominent muscularity of the arms and calves. She had type 2 diabetes since age 38 years. On metformin 1,500 mg daily and rosiglitazone 8 mg daily, she had good glycemic control, with glycosylated hemoglobin always <7.6%. She had been treated for hypertension for 8 years, recently with fosinopril 20 mg daily. She had a history of irregular menses and had bilateral polycystic ovarian disease, which was treated at age 44 years with bilateral salpingo-oophorectomy. She had hyperinsulinemia and type IV hyperlipoproteinemia and hypoalbuminemia, which was treated by diet alone.

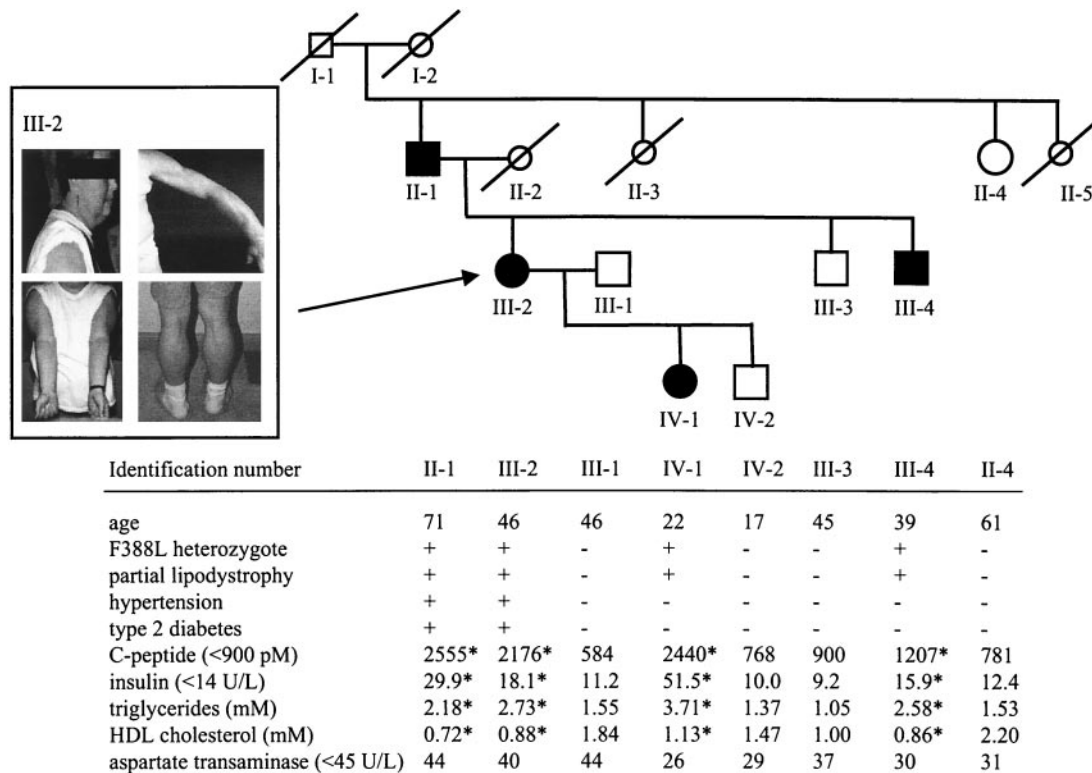
The proband's daughter (IV-1) was 22 years old when clinically diagnosed with FPLD based on prominent muscularity of her calves and lower arms due to paucity of

From the <sup>1</sup>Robarts Research Institute, London, Ontario, Canada; <sup>2</sup>Pfizer Global Research and Development, Ann Arbor, Michigan; and the <sup>3</sup>Department of Pathology and the Center for Integrative Metabolic and Endocrine Research, Wayne State University School of Medicine, Detroit, Michigan.

Address correspondence and reprint requests to Robert A. Hegele, Blackburn Cardiovascular Genetics Laboratory, Robarts Research Institute, 406–100 Perth Dr., London, Ontario, Canada N6A 5K8. E-mail: hegele@robarts.ca

Received for publication 12 August 2002 and accepted in revised form 19 August 2002.

FPLD, familial partial lipodystrophy; PPAR- $\gamma$ , peroxisome proliferator-activated receptor- $\gamma$ ; SNP, single nucleotide polymorphism.



**FIG. 1.** *PPARG* F388L partial lipodystrophy kindred. Solid symbols indicate clinically affected subjects. “+” and “-” indicate presence and absence, respectively, of the attribute. All subjects had blood pressure <130/80 mmHg, so “hypertension” was diagnosed according to a history of medical treatment of hypertension. “Type 2 diabetes” refers to a medical diagnosis according to American Diabetes Association criteria, with treatment. Glucose tolerance was not formally assessed. Asterisks indicate hyperinsulinemia, hypertriglyceridemia, and hypoalphalipoproteinemia that were diagnosed based upon concentrations of C-peptide, triglyceride, and HDL cholesterol >95th, >95th, and <5th percentiles for age and sex, respectively. The insert shows fat distribution from the proband, subject III-2.

subcutaneous fat on her arms and legs. Similar to her mother, she had atrophy of gluteal fat, with subcutaneous fat on her upper arms to the level of the surgical neck of the humerus, in addition to excess subcutaneous facial, neck, suprascapular, and abdominal fat since her teenage years. She had regular menses with no evidence of polycystic ovarian disease clinically. She had no medical problems and took no medications. She had hyperinsulinemia and mild type IV hyperlipoproteinemia, which was treated by diet alone.

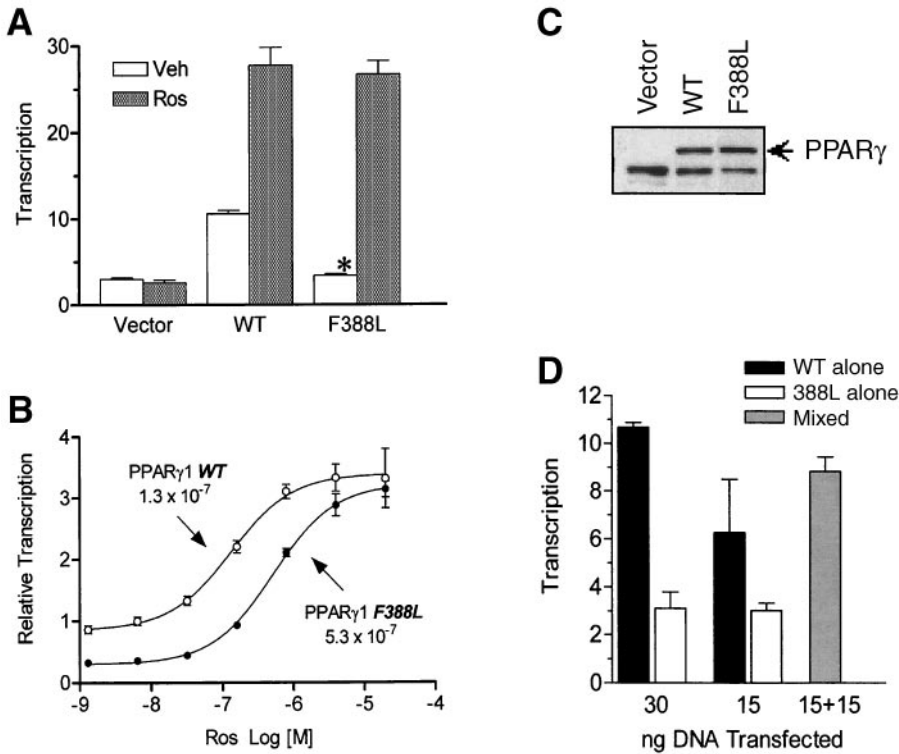
The proband’s father (II-1) was 71 years old. He had prominent muscularity of calves and lower arms due to paucity of subcutaneous fat, atrophy of gluteal fat, with some subcutaneous fat on his upper arms to the level of the surgical neck of the humerus, in addition to excess subcutaneous facial, neck, suprascapular, and abdominal fat. He had treated hypertension of 20 years’ duration and type 2 diabetes of 18 years’ duration, treated with metformin 1,500 mg daily. Despite no smoking history, at age 56 he suffered an anterior wall myocardial infarction. He had hyperinsulinemia and hypoalphalipoproteinemia, and took atorvastatin for secondary prevention of coronary disease.

The proband’s youngest brother (III-4) was 39 years old, with prominent muscularity of calves and lower arms and accumulation of subcutaneous facial, neck, suprascapular, and abdominal fat. He was physically active, with no medical problems and took no medications. He had mild type IV hyperlipoproteinemia and hypoalphalipoproteinemia.

Clinically, there was no hepatosplenomegaly, phlebotasia, or acanthosis nigricans in any subject. No female subjects had hirsutism. The proband’s husband, aunt, son, and brother (Fig. 1 III-1, II-4, IV-1, and III-4, respectively) had normal anthropometry, with neither diabetes nor hypertension, and normal serum biochemistry. Abdominal ultrasound for subjects II-1 and III-2 showed no fatty liver. No subject had an elevated aspartate transaminase (Fig. 1). All subjects had resting blood pressure below 130/80 mmHg on duplicate determinations, but only subjects II-1 and III-2 were receiving antihypertensive medications.

Sequencing of genomic DNA showed that the proband was heterozygous for a novel T→A mutation at *PPARG* nucleotide 1164 in exon 5 that predicted substitution of the phenylalanine at codon 388 by leucine (F388L). The four affected family members were each heterozygous for the F388L mutation, and the four unaffected family members did not have the mutation (Fig. 1). No other mutations or single nucleotide polymorphisms (SNPs) in *PPARG* were detected. Younger subjects with the mutation had only the characteristic adipose repartitioning and hyperinsulinemia, while older subjects also had diabetes and hypertension. The maximal logarithm of odds (LOD) score for cosegregation of the mutation with affected status was 2.11 at 0% recombination. The F388L allele was absent from 520 normal Caucasian alleles ( $P < 3 \times 10^{-7}$ ).

In the absence of ligand, the transcriptional activity of the mutant receptor was 3.1-fold lower than the wild-type receptor (Fig. 2A, light bars). However, both wild-type and mutant receptors displayed the same degree of transcrip-



**FIG. 2.** Transcriptional activity of wild-type (WT) and F388L PPAR- $\gamma$ 1 receptors. **A:** Transfected cells were treated with DMSO (Veh) or 20  $\mu$ mol/l rosiglitazone (Ros) for 16 h. Shown are means  $\pm$  SD ( $n = 3$ ) of luciferase activity normalized to a cotransfected  $\beta$ -galactosidase reference standard. \* $P = 6.7 \times 10^{-5}$  for F388L compared with WT ( $t$  test). **B:** Rosiglitazone (Ros) dose-response curves of WT and F388L in NIH 3T3 cells transfected with either WT or mutant PPAR- $\gamma$ 1 together with the pFATP-Luc reporter. Data are means  $\pm$  SD ( $n = 3$ ). The EC50 for each binding curve is shown. **C:** Western analysis of COS7 cells transfected with WT and F388L PPAR- $\gamma$ 1 showing similar expression levels. **D:** WT and F388L receptors transfected individually (at 30 or 15 ng as indicated) or in combination (15 ng of each receptor).

tional activity in the presence of a saturating amount of the synthetic PPAR- $\gamma$  ligand rosiglitazone (Fig. 2A, dark bars). Rosiglitazone dose-response curves showed that F388L caused a fourfold rightward shift in the EC50 for PPAR- $\gamma$ -mediated transcriptional activation (Fig. 2B), suggesting a reduced affinity for the ligand. Similar findings were observed when the transfections were carried out in the murine C2C12 myoblast cell line (data not shown). Western analysis showed no reduction in F388L expression (Fig. 2C). To determine if the F388L receptor had dominant-negative activity against wild-type PPAR- $\gamma$ , a preliminary mixing experiment was performed in which wild-type and mutant receptors were cotransfected into NIH 3T3 cells. In the absence of ligand, the transcriptional activity of the combination of receptors (15 ng each) was slightly higher than 15 ng of wild-type receptor alone (Fig. 2D). These results suggest that the F388L mutation does not have dominant-negative activity against the wild-type receptor.

The mutation was within helix 8 of the predicted ligand-binding pocket of PPAR- $\gamma$ , and the specific phenylalanine residue was conserved across all members of the PPAR gene family and also across all species (10). The mutation was absent from 520 normal alleles. In vitro studies showed that the PPAR- $\gamma$  F388L mutation caused a reduction in the in vitro affinity of the receptor for its ligand rosiglitazone and reduced transcriptional activity in the absence of exogenous rosiglitazone. The low basal activity of the mutant receptor could have been caused either by reduced affinity for a subsaturating amount of the endogenous ligand or by a disrupted interaction with transcriptional cofactors that mediate basal transcriptional activity. It was perhaps of some interest that the proband had good glycemic control with pharmacologic doses of rosiglitazone, although this treatment was used in combination with metformin.

While the partial lipodystrophy phenotype in the *PPARG* F388L family was similar to the clinical phenotype of FPLD subjects with mutations in *LMNA* (3,4), there were some distinguishing features. For instance, subcutaneous fat was present on the upper arms to the surgical neck of the humerus, compared with absence of such fat depots in FPLD probands (3–5). Also, no affected subject had phlebectasia of forearm or leg veins, and the muscularity of arms and legs was less prominent than that seen in FPLD due to mutant *LMNA* (3–5). Acanthosis nigricans and hepatic steatosis were absent, but the proband's father had early atherosclerosis and the proband had polycystic ovarian disease. Also, the biochemical disturbances, particularly dyslipidemia, were less severe than those reported in FPLD due to mutant *LMNA* (3). However, the increase in mean C-peptide concentration in *PPARG* F388L subjects compared with family members without the mutation was 2.8-fold (95% CI 1.7- to 4.1-fold), but the increase in subjects with *LMNA* mutations was only 1.6-fold (95% CI 1.2- to 2.1-fold) (3). This suggests a milder clinical and biochemical phenotype in partial lipodystrophy due to mutant *PPARG* compared with *LMNA*. The seemingly worse insulin resistance seems out of proportion to the degree of lipodystrophy, perhaps reflecting another effect of F388L. While unlikely, F388L could be in linkage disequilibrium with an unmeasured functional variant.

Earlier studies indicated that subjects with lipodystrophy had no germline *PPARG* mutations (11,12). A few rare mutations in *PPARG* have been reported. For instance, heterozygosity for *PPARG* R115Q was reported in nonlipodystrophic subjects ascertained based upon obesity and diabetes (13). Simple heterozygosity for either *PPARG* V290M or P467 I was also reported in nonlipodystrophic subjects ascertained based upon severe insulin resistance (9). However, recent magnetic resonance imaging found

attenuation of some adipose tissue depots (14), and clinical reevaluation suggested paucity of subcutaneous limb fat and atrophy of buttock fat (15). Heterozygosity for *PPARG* R425C was found in another patient ascertained on partial lipodystrophy, but there was no demonstration of vertical germline transmission or in vitro functional impairment (7). Taken together, these findings indicate that mutation in *PPARG* can lead to partial lipodystrophy. More refined biochemical, physiological, and noninvasive imaging studies may help to further clarify phenotypic distinctions between partial lipodystrophy due to mutant *PPARG* and mutant *LMNA*.

How might heterozygosity for mutant *PPARG* lead to lipodystrophy? Studies of PPAR- $\gamma$  null mice showed that embryonic stem cells lacking one copy of the *PPARG* gene exhibited impaired adipogenesis (16). Also, dominant-negative mutations in *PPARG* inhibit adipogenesis (17), although it appears that F388L may not be a dominant-negative mutation. Heterozygosity for the common *PPARG* P12A variant was associated with both protection (18) and susceptibility (19) to type 2 diabetes, through uncertain mechanisms. In addition, PPAR- $\gamma$  null heterozygous mice had increased insulin sensitivity (20). Perhaps different missense mutations in *PPARG* could have specific functional consequences. The findings from the *PPARG* F388L kindred indicate that inherited partial lipodystrophy is clinically and genetically heterogeneous, extending the spectrum of metabolic phenotypes caused by *PPARG* mutations.

## RESEARCH DESIGN AND METHODS

**Clinical assessment.** The study received approval from the University of Western Ontario Ethics Review Panel, and all subjects gave informed consent.

**Biochemical studies.** Blood from all subjects was centrifuged at 2,000 rpm for 30 min and the plasma was stored at  $-70^{\circ}\text{C}$ . Assays of fasting plasma concentrations of lipids and lipoproteins were performed using established procedures (3). Concentrations of fasting plasma insulin were determined by radioimmunoassay (Pharmacia, Mississauga, ON), which had a sensitivity of 0.4 ng/ml and intra- and interassay coefficients of variation of 5.2 and 8.7%, respectively. Concentrations of C-peptide were determined using a radioimmunoassay (Diagnostic Products, Los Angeles, CA) that had a minimal detection limit of 43 pmol/l and 0% cross-reactivity with insulin.

**DNA analysis.** DNA sequencing showed no mutation in *LMNA* (4). We amplified and sequenced the six exons of *PPARG* plus at least 100 nucleotides at each intron-exon boundary and  $\sim 700$  bp of the promoter. A rapid, allele-specific genotyping method was then developed, which involved amplification of the 603-bp fragment containing exon 5 using primers 5' TTC ACT GTG AGT TAG AAA TC and 3' CAA TGC AGA CTA ACA CTA AGG. This was followed by electrophoresis in 2% agarose gel purification and ddNTP extension (SnaPSHOT; Perkin-Elmer Applied Biosystems, Foster City, CA) with primer 5' AAG AGC CTG CGA AAG CCT TT, analyzed on a Prism 377 DNA Sequencer (Applied Biosystems, Mississauga, ON). A total of 260 normal Caucasian subjects were studied.

**Functional assays.** To assess transcriptional activity, the T $\rightarrow$ A mutation was introduced into wild-type human PPAR- $\gamma$  cDNA generated from a human fat cell Quick-clone cDNA library (Clontech, Palo Alto, CA). The PCR product was cloned into the eukaryotic expression vector pcDNA4/HisMax-TOPO (Invitrogen, Carlsbad, CA). The resulting clone produced a fusion protein containing polyhistidine and Xpress-epitope tags at the NH<sub>2</sub>-terminus of full-length human PPAR- $\gamma$ 1. The F $\rightarrow$ L388 mutation was introduced into this plasmid in vitro using the Quick-Change mutagenesis kit (Stratagene, La Jolla, CA). Both wild-type and mutant clones were fully sequenced.

For transcription experiments, NIH 3T3 mouse fibroblasts ( $5.5 \times 10^4$  cells/well, 24-well plates) were transfected with either wild-type (WT) or F388L mutant PPAR- $\gamma$  expression plasmid (67 ng), an equal amount of RXR $\alpha$  expression plasmid, and the PPAR-dependent luciferase reporter pFATP-Luc (135 ng), which contained three copies of the mouse FATP gene PPRE inserted upstream of the minimal thymidine kinase promoter. The low endogenous expression of PPAR- $\gamma$  in NIH 3T3 cells ensured that transcription

from a cotransfected PPAR response element-containing reporter would depend almost entirely on exogenous receptor. Cells were transfected for 4 h (Lipofectamine-plus; Invitrogen, Carlsbad, CA) and treated with DMSO or 20  $\mu\text{mol/l}$  rosiglitazone for 16 h. Similar conditions were used to transfect murine C2C12 myoblasts and COS7 cells, the latter for Western analysis using an anti-PPAR- $\gamma$  antibody (a gift from Dr. Heidi Camp, Pfizer Global Research and Development). Rosiglitazone dose-response of WT and F388L was determined in NIH 3T3 cells transfected with 45 ng of either wild-type or mutant PPAR- $\gamma$ 1 together with the pFATP-Luc reporter, across a wide range of drug concentrations.

## ACKNOWLEDGMENTS

This work was supported by grants from Canadian Institutes for Health Research (MT13430), the Canadian Diabetes Association (in honor of Hazel E. Kerr), the Canadian Genetic Diseases Network, and the Blackburn Group. Pearl Campbell provided outstanding technical assistance.

Dr. Irene Hramiak originally referred the proband for assessment. R.A.H. holds a Canada Research Chair (Tier I) in Human Genetics and a Career Investigator award from the Heart and Stroke Foundation of Ontario.

## REFERENCES

- Garg A: Lipodystrophies. *Am J Med* 108:143–152, 2000
- Hegele RA: Familial partial lipodystrophy: a monogenic form of the insulin resistance syndrome. *Mol Genet Metab* 71:539–544, 2000
- Hegele RA: Premature atherosclerosis associated with monogenic insulin resistance. *Circulation* 103:2225–2229, 2001
- Cao H, Hegele RA: Nuclear lamin A/C R482Q mutation in Canadian kindreds with Dunnigan-type familial partial lipodystrophy. *Hum Mol Gene* 9:109–112, 2000
- Shackleton S, Lloyd DJ, Jackson SN, Evans R, Niermeijer MF, Singh BM, Schmidt H, Brabant G, Kumar S, Durrington PN, Gregory S, O'Rahilly S, Trembath RG: *LMNA*, encoding lamin A/C, is mutated in partial lipodystrophy. *Nat Genet* 24:153–156, 2000
- Speckman RA, Garg A, Du F, Bennett L, Veile R, Arioglu E, Taylor SI, Lovett M, Bowcock AM: Mutational and haplotype analyses of families with familial partial lipodystrophy (Dunnigan variety) reveal recurrent missense mutations in the globular C-terminal domain of lamin A/C. *Am J Hum Genet* 66:1192–1198, 2000
- Agarwal AK, Garg A: A novel heterozygous mutation in peroxisome proliferator-activated receptor-gamma gene in a patient with familial partial lipodystrophy. *J Clin Endocrinol Metab* 87:408–411, 2002
- Spiegelman BM: PPAR- $\gamma$ : adipogenic regulator and thiazolidinedione receptor. *Diabetes* 47:507–514, 1998
- Barroso I, Gurnell M, Crowley VE, Agostini M, Schwabe JW, Soos MA, Maslen GL, Williams TD, Lewis H, Schafer AJ, Chatterjee VL, O'Rahilly S: Dominant negative mutations in human PPARgamma associated with severe insulin resistance, diabetes mellitus and hypertension. *Nature* 402:880–883, 1999
- Nolte RT, Wisely GB, Westin S, Cobb JE, Lambert MH, Kurokawa R, Rosenfeld MG, Willson TM, Glass CK, Milburn MV: Ligand binding and co-activator assembly of the peroxisome proliferator-activated receptor-gamma. *Nature* 395:137–143, 1998
- Okazawa H, Mori H, Tamori Y, Araki S, Niki T, Masugi J, Kawanishi M, Kubota T, Shinoda H, Kasuga M: No coding mutations are detected in the peroxisome proliferator-activated receptor-gamma gene in Japanese patients with lipotrophic diabetes. *Diabetes* 46:1904–1906, 1997
- Vigouroux C, Fajias L, Khallouf E, Meier M, Gyapay G, Lascos O, Auwerx J, Weissenbach J, Capeau J, Magre J: Human peroxisome proliferator-activated receptor- $\gamma$ 2: genetic mapping, identification of a variant in the coding sequence, and exclusion as the gene responsible for lipotrophic diabetes. *Diabetes* 47:490–492, 1998
- Ristow M, Muller-Wieland D, Pfeiffer A, Krone W, Kahn CR: Obesity associated with a mutation in a genetic regulator of adipocyte differentiation. *N Engl J Med* 339:953–959, 1998
- Chatterjee VK: Resistance to thyroid hormone, and peroxisome-proliferator-activated receptor gamma resistance. *Biochem Soc Trans* 29:227–231, 2001
- Savage DB, Acerine C, Jebb S, Cinti S, Dixon A, Umphey M, Vidal-Puig A, O'Rahilly S: Insights into the physiological effects of PPAR $\gamma$  from humans with dominant negative mutations. In *Proceedings of the First Interna-*

- tional Workshop on Lipotrophic Diabetes*. Bethesda, MD, Office of Rare Diseases, National Institutes of Health Publication, 2001, p. 53
16. Rosen ED, Sarraf P, Troy AE, Bradwin G, Moore K, Milstone DS, Spiegelman BM, Mortensen RM: PPAR gamma is required for the differentiation of adipose tissue *in vivo* and *in vitro*. *Mol Cell* 4:611–617, 1999
  17. Gurnell M, Wentworth JM, Agostini M, Adams M, Collingwood TN, Provenzano C, Browne PO, Rajanayagam O, Burris TP, Schwabe JW, Lazar MA, Chatterjee VK: A dominant-negative peroxisome proliferator-activated receptor gamma (PPARgamma) mutant is a constitutive repressor and inhibits PPARgamma-mediated adipogenesis. *J Biol Chem* 275:5754–5759, 2000
  18. Altshuler D, Hirschhorn JN, Klannemark M, Lindgren CM, Vohl MC, Nemesh J, Lane CR, Schaffner SF, Bolk S, Brewer C, Tuomi T, Gaudet D, Hudson TJ, Daly M, Groop L, Lander ES: The common PPARgamma Pro12Ala polymorphism is associated with decreased risk of type 2 diabetes. *Nat Genet* 26:76–80, 2000
  19. Hegele RA, Cao H, Harris SB, Zinman B, Hanley AJ, Anderson CM: Peroxisome proliferator-activated receptor-gamma2 P12A and type 2 diabetes in Canadian Oji-Cree. *J Clin Endocrinol Metab* 85:2014–2019, 2000
  20. Miles PD, Barak Y, He W, Evans RM, Olefsky JM: Improved insulin-sensitivity in mice heterozygous for PPAR-gamma deficiency. *J Clin Invest* 105:287–292, 2000