

Maggot Therapy for Treating Diabetic Foot Ulcers Unresponsive to Conventional Therapy

RONALD A. SHERMAN, MD, MSC

OBJECTIVE— To assess the efficacy of maggot therapy for treating foot and leg ulcers in diabetic patients failing conventional therapy.

RESEARCH DESIGN AND METHODS— Retrospective comparison of changes in necrotic and total surface area of chronic wounds treated with either maggot therapy or standard (control) surgical or nonsurgical therapy.

RESULTS— In this cohort of 18 patients with 20 nonhealing ulcers, six wounds were treated with conventional therapy, six with maggot therapy, and eight with conventional therapy first, then maggot therapy. Repeated measures ANOVA indicated no significant change in necrotic tissue, except when factoring for treatment ($F [1.7, 34] = 5.27, P = 0.013$). During the first 14 days of conventional therapy, there was no significant debridement of necrotic tissue; during the same period with maggot therapy, necrotic tissue decreased by an average of 4.1 cm^2 ($P = 0.02$). After 5 weeks of therapy, conventionally treated wounds were still covered with necrotic tissue over 33% of their surface, whereas after only 4 weeks of therapy maggot-treated wounds were completely debrided ($P = 0.001$). Maggot therapy was also associated with hastened growth of granulation tissue and greater wound healing rates.

CONCLUSIONS— Maggot therapy was more effective and efficient in debriding nonhealing foot and leg ulcers in male diabetic veterans than was continued conventional care.

Diabetes Care 26:446–451, 2003

Impaired wound healing is a common and costly problem for those with diabetes. Nonhealing diabetic foot ulcers account for 25–50% of all diabetic hospital admissions, and most of the 60,000–70,000 yearly amputations in the U.S. (1,2). Almost 15% of all diabetic patients will develop one or more foot ulcers, and 15–25% of those ultimately will require amputation (2). It is no wonder that one of the disease prevention objectives outlined in the “Healthy People 2000” project was a 40% reduction in the amputation rate for diabetic patients. That ob-

jective has not been met (3), despite many advances in wound care.

We evaluated the efficacy of an unconventional but simple treatment, long acclaimed as an effective last resort: maggot therapy. For 70 years, maggot therapy has been recognized as an aid in debridement and wound healing (4–6). Medicinal maggots secrete digestive enzymes that selectively dissolve necrotic tissue (7), disinfect the wound (8–10), and stimulate wound healing (11–13). During the 1930s, maggot debridement therapy (MDT) was routinely used in hundreds of

hospitals around the world for treating bone and soft-tissue infections (14). With the introduction of antibiotics and other improvements in wound care, by the 1960s maggot therapy was used only as salvage therapy for the most serious wounds.

Over the past few years, there has been a resurgence in the use of maggot therapy (15), even though its optimal role has not been clearly defined. Large prospective clinical trials have not been conducted for maggot therapy, and there are no commercial backers to support such studies. To assess the utility of maggot therapy, we analyzed the clinical course and outcomes of a cohort of diabetic patients whose foot and leg ulcers were treated with conventional (control) or maggot therapy.

RESEARCH DESIGN AND METHODS

Patient selection

Between 1990 and 1995, 143 patients with 260 nonhealing wounds were referred to the maggot therapy service for evaluation and found to be appropriate candidates for maggot therapy. Non-candidates were referred elsewhere, usually for surgical resection of osteomyelitis or rapidly advancing soft-tissue infection. After documenting informed consent, maggot therapy candidates were followed weekly, and their wounds were traced and photographed for at least 8 weeks or until hospital discharge. Whenever possible, patients continued receiving the treatments prescribed by their primary or wound care team for the first 2 weeks of observation. If the wound did not improve, and if the patient and primary care team consented, then maggot therapy was initiated. Maggot therapy occasionally was initiated without baseline observation, especially with patients who refused further attempts at standard wound care or patients who were already scheduled for amputation. In all, 20 nonhealing foot and leg wounds in 18 diabetic patients

From the Veterans Affairs Medical Center, Long Beach, California and the Department of Medicine, University of California, Irvine, California.

Address correspondence and reprint requests to Dr. Ronald A. Sherman, Department of Pathology, Medical Sciences Bldg, Room D-440, University of California, Irvine, CA 92697-4800. E-mail: rsherman@uci.edu.

Received for publication 14 January 2002 and accepted in revised form 1 November 2002.

Abbreviations: MDT, maggot debridement therapy.

A table elsewhere in this issue shows conventional and Système International (SI) units and conversion factors for many substances.

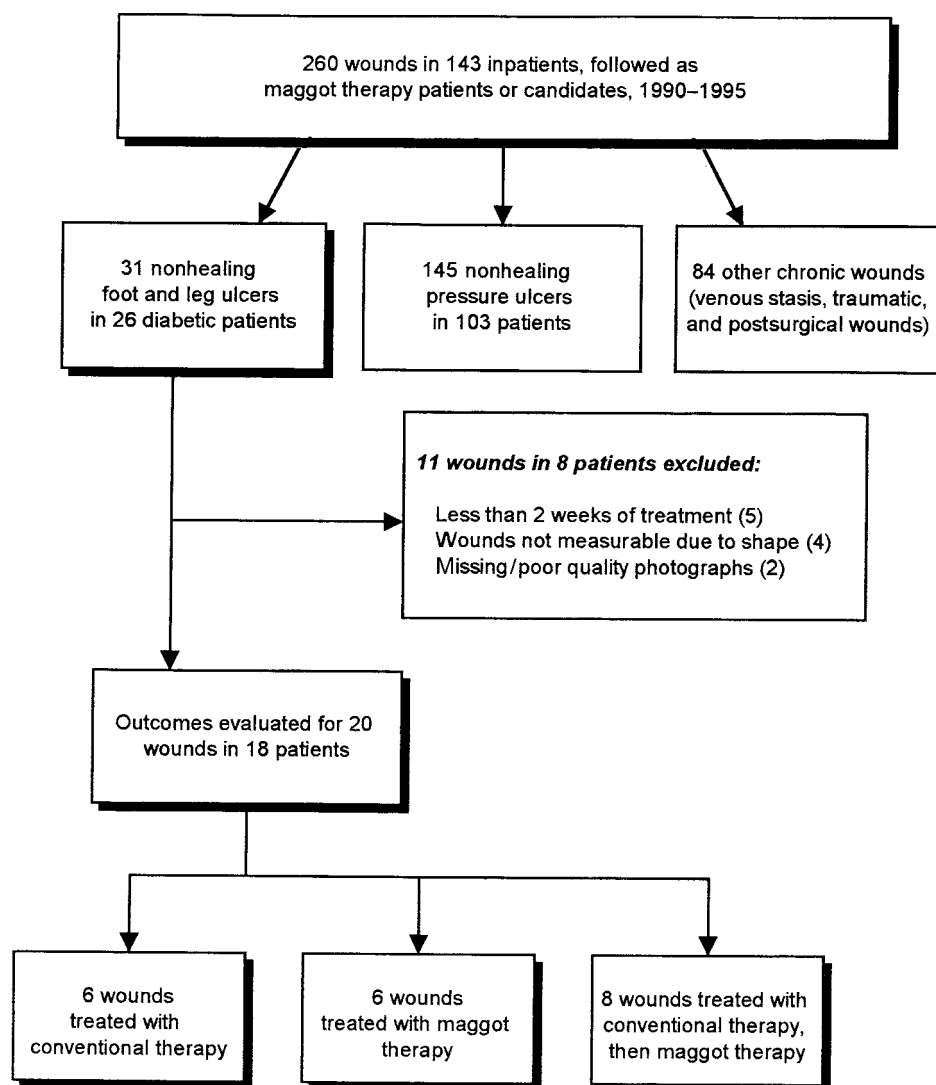


Figure 1—Flow diagram of patients referred to and followed by the maggot therapy service, 18 of whom had wounds and data that qualified for this analysis.

monitored by our service for at least 2 weeks were found to have contours that could be measured by planimetry, making them eligible for this study (Fig. 1).

Administration of therapy

Maggot therapy was administered by applying disinfected fly larvae to the wound, within a cage-like dressing, as previously described (16,17). Larvae of *Phaenicia* (= *Lucilia*) *sericata*, reared and disinfected in our insectary (18), were placed within the wound (five to eight larvae per square centimeter) with loose gauze. A ring of hydrocolloid (cut from Duoderm; Convatec, Princeton, NJ) was placed onto the skin surrounding the wound. A covering

of porous dacron chiffon or a nylon stocking was secured to the hydrocolloid ring with glue and tape (16,17). This cage-like dressing was then topped with a light gauze pad to absorb the necrotic drainage. The top layer of gauze was replaced every 4–6 h, but the cage dressing and maggots were left in place for cycles of about 48 h. Maggots were removed by peeling back the dressing with one hand while wiping up the larvae with a wet gauze pad held in the other hand. One or two cycles were applied each week; saline- or 0.125% sodium hypochlorite-moistened gauze dressings were applied during the period between MDT cycles and after maggot treatment was complete. Patients not receiving maggot therapy received the “con-

ventional” surgical or nonsurgical therapy selected by their primary care staff or the hospital’s wound care team.

Wound evaluations

Ulcer length, width, circumference, and surface area were calculated from digitized photographic images (Mocha; Jandell Scientific, San Rafael, CA). Primary outcome measures included 1) change in relative and absolute amounts of necrotic tissue (defined as nonperfused, nonviable soft tissue); 2) change in relative amounts of granulation tissue (defined as viable, well-vascularized, undifferentiated tissue); 3) change in wound surface area over time; and 4) the length of time until complete wound healing. The wound

Table 1—Characteristics of 18 patients and 20 wounds undergoing treatment with standard care or maggot therapy

	Conventional therapy	MDT
<i>n</i> wounds monitored	14	14
Duration (weeks)	40 (13.5;4–312)	44 (21;4–318)
Size (cm ²)	6.3 (6.6;0.5–15.5)	13.3 (7.8;0.9–42)
Circumference (cm)	9.4 (10.3;2.5–16.6)	13.5 (10.7;3.3–27.7)
Depth to periosteum or into bone (%)	14	21
Necrotic tissue (% total surface)	44 (35;0–100)	38 (38;0–90)
Granulation tissue (% total surface)	18 (0;0–90)	19 (1;0–100)
Pathologic precursors (26)		
Ischemic (%)	7	7
Neuropathic (%)	86	64
Mixed or undefined (%)	7	29
Prior treatment (<i>n</i> [%])		
Dry gauze, saline, petrolatum, aloe, other gel	3 (21.4)	3 (21.4)
Topical antimicrobial	1 (7.1)	1 (7.1)
Chemical debriding agent	1 (7.1)	0
Sharp debridement, incision and drainage, other surgical procedure	5 (35.7)	8 (57.1)
Three or more different nonsurgical methods	4 (28.6)	2 (14.3)
Patient age (years)	68 (72;53–82)	63 (62;53–74)
Underlying illnesses		
Peripheral venous or arterial disease (%)	64	93
Cigarette smoker (%)	23	14
Mean ideal body weight (%)	114	129
Mean albumin (g/dl)	3.7	3.7
Mean hemoglobin (g/dl)	12.4	13.2
Receiving systemic antibiotics (<i>n</i> [%])	2 (14)	3 (21)

Data are means (median and range), unless otherwise specified. Six wounds received conventional therapy only, six received maggot therapy only, and eight received conventional therapy followed by maggot therapy.

healing rate, based on studies by Gilman (19) and Margolis et al. (20), was defined as the change in surface area divided by

(except when less than five cases were expected, thereby invoking Fisher's exact test). Changes in tissue quality and sur-

apy, and one patient was taken for a below-knee amputation before maggot therapy was initiated.

$$\frac{\Delta SA_{(t_2 - t_1)}}{\text{circumference}(t_2 - t_1)} \div (t_2 - t_1) = \frac{(\text{surface area at time } t_2) - (\text{surface area at time } t_1)}{[(\text{circumference at time } t_1) + (\text{circumference at time } t_2)]/2} \div t_2 - t_1$$

the mean circumference over time: where t_1 = initial time of observation, t_2 = final time of observation, and $t_2 - t_1$ = the period of observation ($t_2 - t_1$), in weeks. Wound healing rates were calculated for $t_2 - t_1 = 4$ weeks, $t_2 - t_1 = 8$ weeks, and $t_2 - t_1 =$ duration of treatment.

Statistical analysis

Normally distributed ordinal and interval data were analyzed using Student's *t* test or logistic regression when variance was equal, and Welch's *t* test when variance was not equal. Ordinal and interval data not normally distributed were evaluated using the Mann-Whitney *U* test. Nominal data were analyzed using Pearson's χ^2 test

face area over time were evaluated using repeated measures ANOVA. The hypothesis of equality of means was discarded when the probability (*P*) of a type I error was $\leq 5\%$. Analyses were performed with SPSS statistical software (SPSS, Chicago, IL).

RESULTS — Of the 20 ischemic and neuropathic ulcers in these 18 patients, six wounds were treated only with conventional therapy, six with MDT, and eight with conventional therapy first, then MDT. For the six wounds (in five patients) not treated with maggot therapy, one patient did not consent to MDT, three patients' spouses did not consent to ther-

Differences between patients receiving conventional or maggot treatments are described in Table 1. Maggot-treated wounds tended to be larger and contain more necrotic tissue than wounds treated with conventional therapy, but these differences were not statistically significant. The average and median number of maggot treatments per wound was 15 and 10, respectively. Conventional treatments prescribed by the patients' primary providers or wound care team were consistent with the standard of wound care practiced in our facility: nonmedicated dry dressings or saline-moistened "wet-to-dry" gauze changed every 8 h (four wounds); topical antimicrobials adminis-

Table 2—Results of 28 treatments with conventional wound care or maggot therapy

	Conventional therapy	MDT
<i>n</i> wounds monitored	14	14
Average duration of therapy (weeks)	5.3 (4.1–6.4)	4.7 (3.5–6.0)
Debridement		
Initial necrotic tissue (% total area)	44 (22–67)	38 (22–55)
Initial surface area of necrotic tissue (cm ²)	2.7 (1.2–4.4)	5.0 (2.0–8.0)
Necrotic tissue (% total surface area) at week 2	39 (19–58)*	7 (1–13)*
Percent change in surface area of necrotic tissue	+8% (–8 to 25)*	–59 (–125 to 7)*
Weekly change in surface area of necrotic tissue (cm ²)	+0.4 (–0.4 to 1.2)	–3.9 (–8.4 to –0.6)
Wound size and healing		
Initial surface area (cm ²)	6.3 (4.2–8.5)	13.3 (6.4–20.2)
Surface area at 4 weeks (cm ²)	10.9 (6.1–15.7)	11.8 (4.8–18.7)
Change in surface area (cm ²)	+5.0 (0.19–9.8)*	–3.8 (–7.0 to 0.6)*
Weekly change in surface area (cm ²)	+1.15 (0.24–2.1)*	–0.78 (–1.6 to 0.1)*
Weekly % change in surface area (final/initial)	+27 (4.1–50)	–2 (–22 to 18)
Healing rate at 4 weeks	–0.08 (–0.15 to –0.0002)*	0.08 (0.20–0.14)*
Healing rate at 8 weeks	–0.02 (–0.08 to 0.04)*	0.07 (0.04–0.11)*
Wounds completely closed (%)	21 (0–44)	36 (7–65)
Average time until wound closure (weeks)	18 (8–28)	15 (3–26)
Quality of wound base: preparation for graft or surgical closure		
Initial granulation tissue (% total area)	18 (2–33)	19 (4–35)
Granulation tissue at 4 weeks (% total area)	15 (1–30)*	56 (34–77)*

Data are means (median and range), unless otherwise specified. Six wounds received conventional therapy only, six received maggot therapy only, and eight received conventional therapy followed by maggot therapy. *Differences in mean values where the probability (*P*) of a type I error is ≤ 0.05 .

tered three times daily (three wounds); acemannan hydrogel applied 1–3 times daily (one wound); hydrocolloid pads 1–2 times weekly (one wound); multiple nonsurgical modalities (two wounds); or bedside surgical debridement up to three times weekly (three wounds).

Maggot therapy was associated with faster debridement and wound healing than conventional therapy (Table 2, Figs. 2, 3). MDT-treated wounds saw a 50% reduction in necrotic surface area (“half-debrided”) in 9 days, whereas conventionally treated wounds did not reach that stage until day 29 ($P < 0.001$). Within 2 weeks, maggot-treated wounds were covered by only 7% necrotic tissue (0.9 cm²), compared with 39% necrotic tissue (3.1 cm²) for conventionally treated wounds ($P = 0.009$). Within 4 weeks, maggot-treated wounds were completely debrided, whereas wounds treated with conventional therapy for an average of 5 weeks were still covered with necrotic tissue over 33% of their surface ($P = 0.001$).

The efficacy of MDT was further evaluated using repeated measures ANOVA, with necrotic tissue surface area as a within-subject factor, treatment group (MDT versus conventional therapy) as

the between-subject factor, and initial surface area of necrotic tissue as a covariate in the analysis. The sphericity assumption was not met, so the Huyn-Feldt correction was applied. The ANOVA in-

dicated no significant change in necrotic tissue, except when factoring for treatment ($F [1.7, 34] = 5.27, P = 0.013$). Repeated measures ANOVA for each treatment arm alone demonstrated that

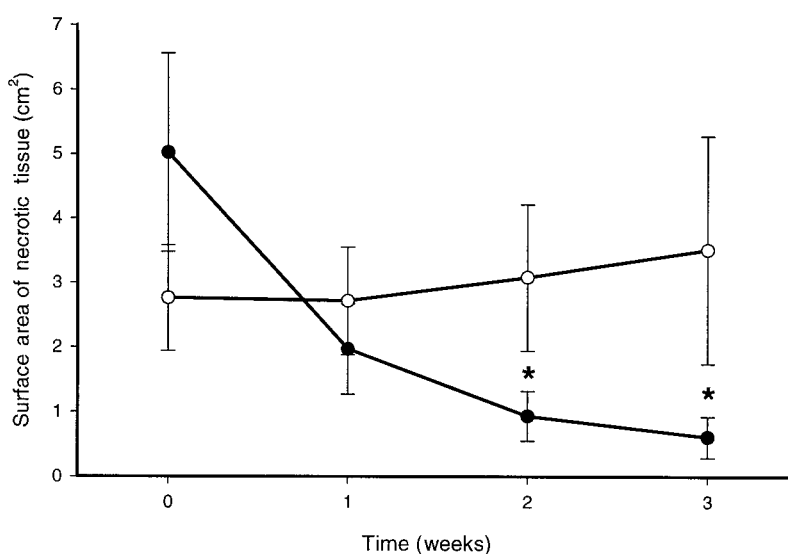


Figure 2—Surface area of necrotic tissue over time, during treatment with maggots (●; *n* = 14) or standard therapy (○; *n* = 14). Six wounds received conventional therapy only, six received maggot therapy only, and eight received conventional therapy followed by maggot therapy. Error bars indicate standard error. * $P < 0.05$.

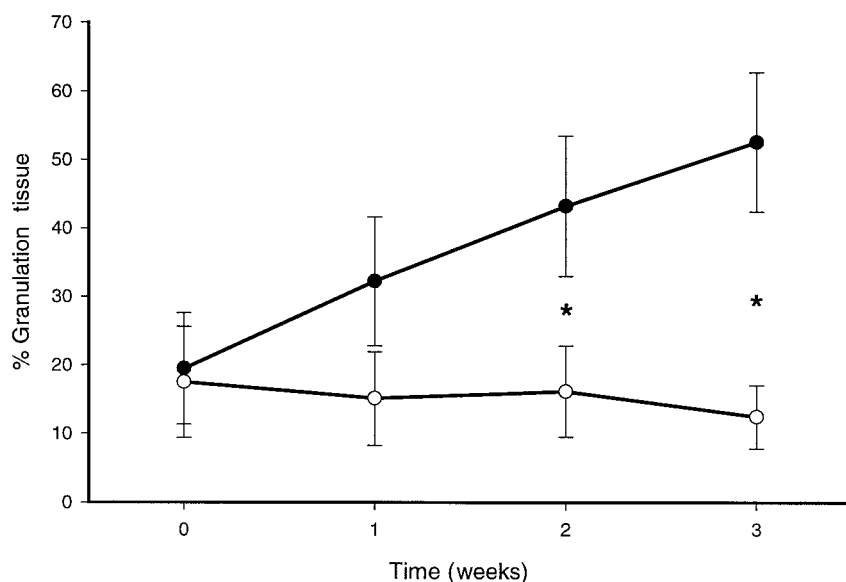


Figure 3—Percent of wound base covered by granulation tissue, over time, during treatment with maggots (●; n = 14) or standard therapy (○; n = 14). Six wounds received conventional therapy only, six received maggot therapy only, and eight received conventional therapy followed by maggot therapy. Error bars indicate standard error. *P < 0.05.

MDT was associated with a significant decrease in necrotic tissue (mean debridement of 4.1 cm² within 2 weeks; P = 0.02), whereas conventional therapy was not associated with any decrease in necrotic tissue over the same period.

Maggot therapy was associated with hastened growth of granulation tissue and greater wound healing rates. Within 4 weeks, maggot-treated wounds were not only debrided, but were covered with healthy granulation tissue over about 56% of their wound base. In contrast, granulation tissue covered only 15% of the base of those wounds treated conventionally (P = 0.016).

Debridement and healing rates of the eight wounds treated first with conventional therapy, then with maggot therapy, were compared by paired *t* tests. Surface areas at the beginning of conventional therapy (3.8 cm²) and maggot therapy (9.7 cm²) were not significantly different, but their weekly change was significant (increase of 1.0 cm²/week in surface area of wounds during conventional therapy versus decrease of 0.9 cm²/week in surface area of the same wounds during maggot therapy; P = 0.018). Similarly, the average portion of wound base covered with necrotic tissue was equivalent at the start of conventional therapy (43%) and ~5.6 weeks later when maggot therapy was initiated (37%). Just 1 week of mag-

got therapy completely debrided all but 17% of the wound base, whereas 1 week of standard therapy failed to debride necrotic tissue from 39% of the wound base (P = 0.012).

Two maggot-treated patients complained of pain during therapy, but the pain was not severe enough to cause them to abandon maggot debridement. The same two patients complained of pain during conventional dressing changes also.

CONCLUSIONS— The current enthusiasm for maggot debridement has been fueled more by anecdotal reports and personal experience than by scientific studies. Until now, there has not been a study comparing maggot therapy to conventional treatments for diabetic foot wounds. The present analysis demonstrated that maggot therapy is more effective and efficient in debriding nonhealing foot and leg ulcers in diabetic male veterans than the typical conventional treatment currently prescribed. Maggot therapy was also associated with a more rapid decrease in wound size and an increase in granulation tissue, making the wounds ready for surgical closure. The higher number of patients actually achieving complete wound closure within the 8-week study period (14% with maggot therapy vs. 0% with conventional

therapy) did not reach statistical significance.

These findings support the benefits of maggot therapy claimed by earlier authors. Mumcuoglu et al. (24) reported effective debridement for 24 of 27 non-healing wounds in 22 diabetic patients treated with an average of six maggot treatments over the course of 2 weeks; 12 wounds were debrided within just 1 week. Rayman et al. (25) and Fleischmann et al. (26) similarly found maggot therapy to be a valuable treatment for debriding diabetic foot wounds. However, reported outcomes were subjective, there were no control groups, and the effects on wound closure were not evaluated. Only two prior studies of maggot therapy incorporated control groups. Sherman et al. (22) demonstrated that maggot therapy enhanced the closure rate of pressure ulcers in spinal cord injury patients, and Wayman et al. (23) demonstrated that maggot therapy was associated with more rapid debridement and reduced cost when compared to hydrogel for the treatment of venous stasis ulcers. Neither of these prospective studies evaluated diabetic foot ulcers.

The present study demonstrated that the benefits of maggot debridement therapy reported for pressure and venous stasis ulcers can also be realized by diabetic patients with chronic ischemic and neuropathic wounds. The results of this study should not be misinterpreted as suggesting that conventional therapy is generally ineffective. The overall efficacy of conventional therapy was not assessed in this study, and it is likely that conventional treatments are very effective in treating most wounds. This study simply evaluated wounds that were not responding to conventional care, and demonstrated that MDT was far more effective in treating these chronic wounds than was a trial of another standard therapy. The findings suggest that we should not consider maggot therapy only as a last resort (an alternative to amputation); rather, we should consider using MDT earlier during the course of therapy, as a second- or third-line option.

Many questions remain unanswered, and a large prospective evaluation is warranted. Although MDT debrided wounds, decreased their size, and prepared them for closure more rapidly than did conventional therapy, the rate of wound closure was not significantly higher than that as-

sociated with standard therapy. A larger study, preferably with subjects whose disease is not as advanced, might better demonstrate the impact of maggot therapy on complete wound closure. In addition to issues of efficacy and safety, future studies also must address the cost-effectiveness of MDT and conditions in which maggot therapy is likely to be futile (e.g., at what measurable level of hypoperfusion is an extremity wound unlikely to respond to maggot therapy).

Acknowledgments— This work was supported, in part, by grants from the Spinal Cord Research Foundation of the Paralyzed Veterans of America (1990), the California Paralyzed Veterans of America (1991), and the Andrus Foundation of the American Association of Retired Persons (1992–1995).

Toni Espinoza Ferrel, MPH, provided critical statistical assistance. Many individuals contributed to patient care, wound assessment, data-entry, chart reviews, or administrative support, including, Julie Sherman; Randall Sullivan, RN; Rodney Wishnow, MD; and Frederic Wyle, MD.

References

- Moss SE, Klein R, Klein BEK: The prevalence and incidence of lower extremity amputation in a diabetic population. *Arch Intern Med* 152:610–616, 1992
- Frykberg RG: Epidemiology of the diabetic foot: ulcerations and amputations. *Adv Wound Care* 12:139–141, 1999
- National Center for Health Statistics: Healthy People 2000 Final Review. Hyattsville, MD, Public Health Service, 2001 (DHHS publ. no. 01-0256)
- Baer W: Sacro-iliac joint—Arthritis deformans—viable antiseptic in chronic osteomyelitis. *Proceedings of the International Assembly of the Inter-state Postgraduate Medical Association of North America* 371:365–372, 1929
- Pechter EA, Sherman RA: Maggot therapy: the medical metamorphosis. *Plast Reconstr Surg* 72: 567–570, 1983
- Mumcuoglu KY: Clinical applications for maggots in wound care. *Am J Clin Dermatol* 2:219–227, 2001
- Vistnes LM, Lee R, Ksander GA: Proteolytic activity of blowfly larvae secretions in experimental burns. *Surgery* 90:835–841, 1986
- Robinson W, Norwood VH: Destruction of pyogenic bacteria in the alimentary tract of surgical maggots implanted in infected wounds. *J Lab Clin Med* 19:581–586, 1934
- Simmons SW: A bactericidal principle in excretions of surgical maggots which destroys important etiological agents of pyogenic infections. *J Bacteriol* 30:253–267, 1935
- Pavillard ER, Wright EA: An antibiotic from maggots. *Nature* 180:916–917, 1957
- Baer WS: The treatment of chronic osteomyelitis with the maggot (larva of the blow fly). *J Bone Joint Surg Am* 13:438–475, 1931
- Robinson W: The role of surgical maggots in the disinfection of osteomyelitis and other infected wounds. *J Bone Joint Surg Am* 15:409–412, 1933
- Prete PE: Growth effects of *Phaenicia sericata* larval extracts on fibroblasts: mechanism for wound healing by maggot therapy. *Life Sci* 60:505–510, 1997
- Sherman RA: Maggot therapy in modern medicine. *Infect Med* 15:651–656, 1998
- Sherman RA: Maggot therapy: the last five years. *Eur Tissue Repair Soc Bull* 7:97–98, 2000
- Sherman RA, Tran J, Sullivan R: Maggot therapy for treating venous stasis ulcers. *Arch Dermatol* 132:254–256, 1996
- Sherman RA: A new dressing design for treating pressure ulcers with maggot therapy. *Plast Reconstr Surg* 100:451–456, 1997
- Sherman RA, Wyle FA: Low-cost, low-maintenance rearing of maggots in hospitals, clinics, and schools. *Am J Trop Med Hyg* 54:38–41, 1996
- Gilman TH: Parameter for measurement of wound closure. *Wounds* 3:95–101, 1990
- Margolis DJ, Gross EA, Wood CR, Lazarus GS: Planimetric rate of healing in venous ulcers of the leg treated with pressure bandage and hydrocolloid dressing. *J Am Acad Dermatol* 28:418–421, 1993
- Levin ME: The diabetic foot: pathophysiology, evaluation, and treatment. In *The Diabetic Foot*. 4th ed. Levin ME, O'Neal LW, Eds. St. Louis, C.V. Mosby, 1988, p. 1–50
- Sherman RA, Wyle FA, Vulpe M: Maggot debridement therapy for treating pressure ulcers in spinal cord injury patients. *J Spinal Cord Med* 18:71–74, 1995
- Wayman J, Nirojogi V, Walker A, Sowinski A, Walker MA: The cost effectiveness of larval therapy in venous ulcers. *J Tissue Viability* 10: 91–96, 2000
- Mumcuoglu KY, Ingber A, Gilead L, Stessman J, Friedmann R, Schulman H, Bichucher H, Ioffe-Uspensky I, Miller J, Galun R, Raz I: Maggot therapy for the treatment of diabetic foot ulcers (Letter). *Diabetes Care* 21:2030–2031, 1998
- Rayman A, Stansfield G, Woollard T, Mackie A, Rayman G: Use of larvae in the treatment of the diabetic necrotic foot. *The Diabetic Foot* 1:7–13, 1998
- Fleischmann W, Russ M, Moch D, Marquardt C: [Biosurgery: Maggots, are they really the better surgeons?]. *Chirurg* 70: 1340–1346, 1999