

# Diabetic Retinopathy and Diabetic Macular Edema

## Pathophysiology, screening, and novel therapies

THOMAS A. CIULLA, MD<sup>1</sup>  
 ARMANDO G. AMADOR, MD<sup>2</sup>  
 BERNARD ZINMAN, MDCM, FRCP(C), FACP<sup>3</sup>

Diabetic retinopathy (DR) and diabetic macular edema (DME) are leading causes of blindness in the working-age population of most developed countries. The increasing number of individuals with diabetes worldwide suggests that DR and DME will continue to be major contributors to vision loss and associated functional impairment for years to come. Early detection of retinopathy in individuals with diabetes is critical in preventing visual loss, but current methods of screening fail to identify a sizable number of high-risk patients. The control of diabetes-associated metabolic abnormalities (i.e., hyperglycemia, hyperlipidemia, and hypertension) is also important in preserving visual function because these conditions have been identified as risk factors for both the development and progression of DR/DME. The currently available interventions for DR/DME, laser photocoagulation and vitrectomy, only target advanced stages of disease. Several biochemical mechanisms, including protein kinase C- $\beta$  activation, increased vascular endothelial growth factor production, oxidative stress, and accumulation of intracellular sorbitol and advanced glycosylation end products, may contribute to the vascular disruptions that characterize DR/DME. The inhibition of these pathways holds the promise of intervention for DR at earlier non-sight-threatening stages. To implement new therapies effectively, more individuals will need to be screened for DR/DME at earlier stages—a process requiring both improved technology and interdisciplinary cooperation among physicians caring for patients with diabetes.

*Diabetes Care* 26:2653–2664, 2003

### CURRENT EPIDEMIOLOGY, NEW PATHOPHYSIOLOGY INSIGHTS, UPDATED DIAGNOSTIC STAGING SYSTEM, RECENT SCREENING TECHNOLOGIES, AND TREATMENT —

Diabetic retinopathy (DR) and diabetic macular edema (DME) are common microvascular complications in patients with diabetes and may have a sudden and debilitating impact on visual acuity (VA), eventually leading to blindness. Advanced stages of DR are characterized by the growth of abnormal retinal blood vessels secondary to isch-

From the <sup>1</sup>Midwest Eye Institute, Indianapolis, Indiana; the <sup>2</sup>Lilly Research Laboratories, Indianapolis, Indiana; and the <sup>3</sup>Leadership Sinai Centre for Diabetes, Mount Sinai Hospital, University of Toronto, Toronto, Canada.

Address correspondence and reprint requests to Bernard Zinman, MDCM, FRCP(C), FACP, Director, Leadership Sinai Centre for Diabetes, 600 University Ave., Suite 782, Toronto, Ontario, Canada. E-mail: zinman@mshri.on.ca.

Received for publication 10 September 2002 and accepted in revised form 11 May 2003.

T.A.C. is a member of the PKC Eli Lilly Advisory Board and has acted as a consultant for Eli Lilly. A.G.A. serves on the editorial board of Ophthalmology Coding Alert, holds stock in Eli Lilly, and is a paid consultant for ReproGen. B.Z. is a member of the PKC Eli Lilly Advisory Board and is the chair of the Eli Lilly North American Diabetes Advisory Board; he has received consulting fees, honoraria, and grant support from Eli Lilly.

**Abbreviations:** AGE, advanced glycation end product; ARI, aldose reductase inhibitor; CSME, clinically significant macular edema; DAG, diacylglycerol; DME, diabetic macular edema; DR, diabetic retinopathy; ETDRS, Early Treatment Diabetic Retinopathy Study; FA, fluorescein angiography; IC<sub>50</sub>, half-maximal inhibition concentration; PEDR, pigment endothelium-derived factor; PDR, proliferative diabetic retinopathy; PKC, protein kinase C; ROS, reactive oxygen species; VA, visual acuity; VEGF, vascular endothelial growth factor.

A table elsewhere in this issue shows conventional and Système International (SI) units and conversion factors for many substances.

© 2003 by the American Diabetes Association.

emia. These blood vessels grow in an attempt to supply oxygenated blood to the hypoxic retina. At any time during the progression of DR, patients with diabetes can also develop DME, which involves retinal thickening in the macular area. DME occurs after breakdown of the blood-retinal barrier because of leakage of dilated hyperpermeable capillaries and microaneurysms. The current management strategy for DR/DME requires early detection and optimal glycemic control to slow the progression of disease. Adherence to these recommendations is hampered by the fact that the condition is generally asymptomatic at early stages. Current treatments for DR/DME, such as laser photocoagulation, only target advanced stages of disease. Several pharmacological therapies are being developed to treat early stages of DR/DME, but will require a renewed emphasis on early detection. This review will focus on the current understanding of the epidemiology and pathophysiology of DR/DME, the updated clinical diagnostic grading system, screening and management, and the rationale behind the potential for pharmacological treatments.

### Epidemiology

Type 2 diabetes has reached epidemic proportions, fueled by an aging population and the rapid increase in obesity (1). DR is a major cause of vision loss in patients with diabetes. The longer patients have diabetes, the higher the prevalence of DR (2). In developed countries, DR is recognized as the leading cause of blindness in the working-age population (20–74 years old) and is responsible for 12% of new cases of blindness each year (3).

In patients with type 1 diabetes, the cumulative 14-year incidences of visual impairment (VA 20/40 or worse in the better eye), doubling of the visual angle, and blindness were 12.7, 14.2, and 2.4%, respectively (4). DME is a frequent manifestation of DR (5) and is a leading cause

of legal blindness in patients with type 2 diabetes. Over a 10-year period, non-clinically significant DME and clinically significant DME will, respectively, develop in 14 and 10% of Americans with known diabetes (6). Approximately half of patients with DME will lose two or more lines of VA within 2 years (7).

Even in cases where retinopathy has not yet progressed to blindness, loss in VA because of diabetes is a major problem and may lead to significant reductions in functional status. DR is the third leading cause of severe visual impairment among inner-city adults  $\geq 40$  years of age (8).

Diabetes-related blindness and visual impairment places a significant burden on society. The federal budgetary cost of blindness was estimated to be \$4.1 billion in the U.S. for the year 1990, and 97% of these costs were accounted for by the working-age adult group (9). Health care and economic burdens of DR are further compounded by the resulting decline in quality of life (10); thus, the true impact on society cannot be estimated on a monetary basis alone.

**Pathophysiology**

Many studies have demonstrated that chronic hyperglycemia, as well as hyperlipidemia and hypertension, contribute to the pathogenesis of DR (11–14). The exact mechanisms by which elevated glucose initiates the vascular disruption in retinopathy remain poorly defined, and, not surprisingly, several pathways have been implicated. The vascular disruptions of DR/DME are characterized by abnormal vascular flow, disruptions in permeability, and/or closure or nonperfusion of capillaries.

A hallmark of early DR is the change in the structure and cellular composition of the microvasculature (15–17). Endothelial cells are responsible for maintaining the blood-retinal barrier, and damage to them results in increased vascular permeability. In early stages of DME, breakdown of the inner blood-retinal barrier may occur, resulting in accumulation of extracellular fluid in the macula (7,18).

Pericytes are essential cellular components in the regulation of retinal capillary perfusion, and damage to these cells in diabetes leads to altered retinal hemodynamics, including abnormal autoregulation of retinal blood flow (19). Loss of retinal pericytes represents another early feature of DR (20–22) and correlates with

**Table 1—International clinical diabetic retinopathy disease severity scale**

Proposed disease severity level	Dilated ophthalmoscopy findings
No apparent retinopathy	No abnormalities
Mild nonproliferative DR	Microaneurysms only
Moderate nonproliferative DR	More than just microaneurysms, but less than severe NPDR
Severe nonproliferative DR	No signs of PDR, with any of the following: <ul style="list-style-type: none"> <li>● More than 20 intraretinal hemorrhages in each of four quadrants</li> <li>● Definite venous beading in two or more quadrants</li> <li>● Prominent intraretinal microvascular anomalies in one or more quadrants</li> </ul>
PDR	One or more of the following: <ul style="list-style-type: none"> <li>● Neovascularization</li> <li>● Vitreous or preretinal hemorrhage</li> </ul>

NPDR = nonproliferative DR.

microaneurysm formation (15,20,23). Another common feature of DR is the thickening of the capillary basement membrane and increased deposition of extracellular matrix components. This feature may contribute to the development of abnormal retinal hemodynamics (24–26), including abnormal autoregulation of retinal blood flow.

There is evidence that retinal leukostasis may also play an important role in the pathogenesis of DR. Leukocytes possess large cell volume, high cytoplasmic rigidity, a natural tendency to adhere to the vascular endothelium, and a capacity to generate toxic superoxide radicals and proteolytic enzymes (27). In diabetes, there is increased retinal leukostasis, which affects retinal endothelial function, retinal perfusion, angiogenesis, and vascular permeability. In particular, leukocytes in diabetes are less deformable, a higher proportion are activated, and they may be involved in capillary nonperfusion, endothelial cell damage, and vascular leakage in the retinal microcirculation (27). A recent study showed that diabetic vascular leakage and nonperfusion are temporally and spatially associated with retinal leukostasis in streptozotocin-induced diabetic rats (28). There are many capillary occlusions by leukocytes and capillary dropout or degeneration associated with leukocytes in the diabetic retina (27). Serial acridine orange leukocyte fluorography and fluorescein angiography (FA) show trapped leukocytes directly associated with areas of down-

stream nonperfusion in the diabetic retinal microcirculation (27). Whereas leukostasis probably plays a key role in the pathogenesis of DR, platelets and erythrocytes are also involved in this process.

As a result of occluded capillaries, retinal ischemia stimulates a pathologic neovascularization mediated by angiogenic factors, such as vascular endothelial growth factor (VEGF), which results in proliferative diabetic retinopathy (PDR) (29,30). This neovascularization is the predominant feature of PDR. Hemorrhaging of new vessels into the vitreous may also lead to tractional retinal detachment (5).

Understanding the diabetes-induced mechanisms that contribute to pericyte loss, endothelial cell proliferation, neovascularization, and alterations in basement membrane structure is therefore central to the design of pharmacological therapeutic strategies to treat and prevent early diabetes-related microvascular changes.

**Diagnostic staging**

**Diabetic retinopathy.** DR is a progressive disease that includes the following stages: no apparent DR, nonproliferative DR, and PDR. Nonproliferative DR is characterized by the presence of venous dilatation, microaneurysms, retinal hemorrhages, retinal edema, and hard exudates (5). Neovascularization in DR can originate from the optic disk or elsewhere (5). The gold standard for grading the se-

Downloaded from <http://diabetesjournals.org/care/article-pdf/29/9/2653/685186/400903002653.pdf> by guest on 25 January 2025

verity of DR is stereoscopic fundus photography through dilated pupils, using seven standard fields (31–33), and grading guidelines for these photographs established by the Early Treatment Diabetic Retinopathy Study (ETDRS) group (34). Although this staging system is used in research studies, it is rarely used clinically, given its complexity. To facilitate communication between retina specialists and health care professionals, International Clinical Diabetic Retinopathy and Diabetic Macular Edema Disease Severity Scales have recently been proposed (35) that were derived from the ETDRS (34) and the Wisconsin Epidemiologic Study of Diabetic Retinopathy (14,36) studies. The International Clinical Diabetic Retinopathy Disease Severity Scale identifies five levels of DR that are clinically meaningful to practitioners and facilitate communication between practitioners (Table 1).

**Diabetic macular edema.** Some DR patients may develop vision loss from DME. Clinically significant macular edema (CSME) occurs if there is thickening of the retina involving the center of the retina (macula) or the area within 500  $\mu\text{m}$  of it, if there are hard exudates at or within 500  $\mu\text{m}$  of the center of the retina with thickening of the adjacent retina, or if there is a zone of retinal thickening one disk area or larger in size, any part of which is within one disk diameter of the center of the retina (37). This definition of CSME generally refers to the threshold level at which laser photocoagulation is carried out. However, it is important to appreciate that the majority of visual loss occurs when macular edema involves the center.

The International Clinical Diabetic Macular Edema Disease Severity Scale includes two major levels: absent and present. If DME is present, it is divided into mild (some retinal thickening or hard exudates in the posterior pole, but distant from the center of the macula), moderate (retinal thickening or hard exudates approaching the center of the macula but not the center), and severe (involving retinal thickening or hard exudates involving the center).

### Recent screening techniques and technologies

Early detection of retinal abnormalities is essential in preventing DR/DME and loss of vision. Treatments, such as photoco-

agulation, can decrease vision loss (33, 37,38). However, it is generally not possible to restore VA once it has deteriorated. Because DR can progress to irreversible stages with relatively few symptoms (33), the optimal time for treatment is before VA is impaired. Studies have confirmed that the clinical outcome is better if patients are screened and treated early (39). The benefits of early management, such as intensive diabetes control, persist for years, even with subsequent hyperglycemia (40). Thus, regular screening and early treatment for DR/DME can potentially save years of vision and reduce societal costs (33).

**Fundus photography and telemedicine.** Current methods of color fundus photography use either a stereoscopic or nonstereoscopic camera to take seven 30°, three wide-angle 60°, or nine overlapping 45° fields (41,42). Fundus photography can also be used to track the progression of disease or efficacy of treatments. The utility of fundus photography as a large-scale screening procedure is limited because of its cost and the requirement for special equipment and trained personnel (32). Pupil dilation is another inconvenient aspect and may reduce compliance even further. Several technologies that offer simple, low-cost, and more accessible photographic screening for DR/DME are currently being evaluated.

To make fundus photography easier and more widely accessible, investigators have evaluated the potential for the use of digital cameras to obtain fundus images through nondilated pupils. The sensitivity and specificity of these nonstereoscopic digital screening methods have most often been compared with the ETDRS seven standard field images. Overall, these methods were in substantial agreement with the ETDRS classification for the grading of DR and in fair to moderate agreement for the grading of DME (43,44).

Another advantage of digital technologies is the ability to transmit images to a centralized reading center for grading. E-mailed digital images from dilated pupils were found to be suboptimal for detecting DME, but sensitive and specific enough to detect sight-threatening DR (45). Although image quality is reduced compared with that of 35-mm photographs, telemedicine-transmitted images appear to be useful for the detection of sight-threatening DR in the hands of experi-

enced graders (46). A recent study showed that four 45° field nonstereoscopic color digital fundus photographs of each eye could be transmitted over the Internet and be used with great accuracy for the screening of DR (47). These methods have also been shown to have good sensitivity and specificity when using a centrally based trained grader.

This ability to digitally photograph and transmit retinal images has led to efforts to develop complete telemedicine screening programs for DR. The Joslin Diabetes Center in Boston has recently developed the Joslin Vision Network, which includes a remote imaging system, a centralized grading center at the Joslin Diabetes Center, and a data storage system. One recent study validated the agreement between nonmydriatic Joslin Vision Network images and dilated ETDRS photographs and suggested that this digital technique may be an effective telemedicine tool for remotely determining the level of DR, suggesting timing of next retinal evaluation and identifying the need for prompt referral to ophthalmology specialists (44). There are also commercial efforts underway, including Inoveon, based in Oklahoma City, and EyeTel, based in Virginia. EyeTel uses a novel approach that places an imaging system, called the Digiscope, in primary care offices to transmit images via a modem to a reading center at the Wilmer Eye Institute, Johns Hopkins Hospital, Baltimore, Maryland.

In addition to these efforts, newly developed automated methods for detection of DR have sensitivity and specificity ranges of 77.5–88.5 and 88.7–99.7%, respectively (48). However, tele-ophthalmology should not be currently viewed as a substitute for comprehensive eye examinations. Photographic techniques can miss disease occurring outside the photographic fields and are less effective than angiography at detecting capillary closure and leakage (see below). Given the lower sensitivity of nonstereoscopic digital photography to detect DME, supplemental measurement of VA may also be warranted (45). A more appropriate use of these technologies is the identification of patients with retinal lesions that warrant further evaluation by an ophthalmologist (44).

**Ophthalmoscopy.** Ophthalmoscopy is a useful screening procedure, easy to use and accessible to ophthalmologists and

other physicians, and requires no specialized equipment. Compared with fundus photography, ophthalmoscopy by an experienced examiner was found to agree with grading by fundus photography >85% of the time (49). In the hands of primary care physicians, ophthalmoscopy was less sensitive than fundus photography in detecting both any DR and sight-threatening DR (sensitivity 63 vs. 79% and 66 vs. 87%, respectively) (50). With additional training, however, ophthalmologic screening by primary care physicians may be a clinically acceptable and cost-saving strategy to refer patients for evaluation by an ophthalmologist. Ophthalmoscopy compared favorably with fundus photography, with 100% sensitivity for referral or follow-up within 1 year (51).

Even in the hands of experienced ophthalmologists, ophthalmoscopy is less sensitive than photography for detecting some of the earliest lesions of retinopathy (52). Ophthalmoscopy was less sensitive than photography for detecting DR/DME in patients with only a few microaneurysms (53). Fundus photography and ophthalmoscopy can be viewed as complementary techniques and may be particularly informative when used adjunctionally (31).

**Fluorescein angiography.** FA is generally used for treatment planning. It is a method in which sodium fluorescein is intravenously administered followed by rapid sequence photography of the retina to evaluate its circulation. A method using orally administered fluorescein has also been developed (54). Normally, fluorescein cannot pass through the tight junctions of retinal capillaries; however, in some disease states, such as DR and DME, dye leakage occurs. The method is useful in detecting early alterations of the blood-retinal barrier, capillary closure, and microaneurysm formation (55). The major advantage of FA over fundus photography is its ability to detect macular ischemia denoted by nonperfusion of the retinal capillaries and to detect subtle DME as evidenced by fluorescein leakage from the capillaries (55). An automated method of quantitating microaneurysms from digitized fluorescein angiograms was shown to reliably detect microaneurysms with a sensitivity of 82% (56). Further improvement and automation may increase the utility and accessibility of FA.

FA and fundus photography are com-

parable for the detection of no or mild and moderate DR (57). Similar results were reported for comparing digital color photography and oral FA (sensitivity for DR, 87% for both methods), although FA was more sensitive for detecting DME (sensitivity 48% for photography and 87% for FA;  $P < 0.01$ ) (43). In the Diabetes Control and Complications Trial, FA was able to detect "preretinopathy" in 21 and 42% of adults with diabetes, deemed negative with photography or ophthalmoscopy, respectively (58,59).

Drawbacks to using FA as a screening procedure are its invasiveness, time constraints, expensive equipment, and adverse reactions. Allergic-type reactions to sodium fluorescein have been reported in patients undergoing FA, although the incidence of serious complications are rare (60). In general, the use of FA is limited to determining method and location of laser photocoagulation for DME and for assessing the extent of nonperfusion. It has limited value over photography as a diagnostic tool and is not recommended for routine use.

**Screening for DR: current guidelines.** Recent data indicate that annual dilated eye examinations should be implemented from the initial diagnosis of both type 1 and type 2 diabetes (32,61). Referral to an experienced ophthalmologist is required if any level of DME, severe nonproliferative DR, or PDR is detected in the examination (32). Regular follow-up is also essential to ensure early detection, even if no DR was found initially; this is especially important for high-risk patients (32).

Adherence to American Diabetes Association guidelines for annual ophthalmic examination is poor, ranging only from 34 to 65% (62–65). Even among patients at high risk for vision loss (pre-existent DR or long duration of diabetes), the rates of adherence were only 61 and 57%, respectively (62). These findings suggest a need for practitioner and patient education about DR and its consequences. A standardized method of referring patients with diabetic eye disease for further evaluation may also be of great value in improving early detection.

### Management and treatment

**Prevention.** Control of the metabolic abnormalities of diabetes has a major effect on the development of diabetic microvascular complications (66). The

Diabetes Control and Complications Trial and the U.K. Prospective Diabetes Study showed that optimal metabolic control could reduce the incidence and progression of DR (67,68). The benefits of intensive glycemic control persisted over an extended follow-up (40). Thus, optimal metabolic control should be an important treatment goal and should be implemented early and maintained for as long as it is safely possible (40). Rigid control of hypertension is also effective in reducing disease progression (69–71). Hyperlipidemia has been linked to the presence of retinal hard exudates in patients with DR (13,72), and some evidence suggests that lipid-lowering therapy may reduce hard exudates and microaneurysms (73).

The recommended values for HbA<sub>1c</sub>, blood pressure, and LDL cholesterol are <6.5–7%, <130/< 85 mmHg, and <100 mg/dl, respectively (32,74). However, many patients fail to achieve or maintain these levels of metabolic control. In patients who do achieve a significant reduction in HbA<sub>1c</sub>, there is an associated increased risk of severe hypoglycemia (67,68,75). Primary care physicians need to recognize correctable risk factors (i.e., hyperglycemia, hypertension, and/or hyperlipidemia) so that appropriate monitoring and referral for eye care can be implemented.

**Treatment.** Once sight-threatening DR has been detected, the treatment options are limited. Laser photocoagulation therapy has proven effective in reducing DR progression, and vitrectomy can in many cases prevent severe vision loss in patients with advanced stages of DR. Unfortunately, both treatments carry a risk of additional vision loss, and neither is effective at reversing loss of VA.

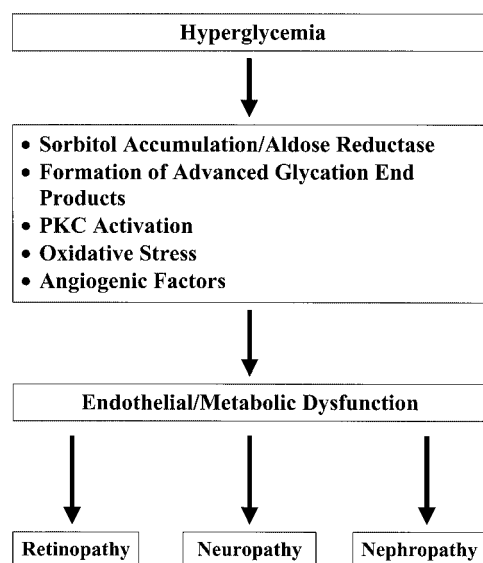
**Laser photocoagulation.** Laser photocoagulation is used to treat both DR and DME. The goal of macular laser photocoagulation for DME is to limit vascular leakage through a series of focal laser burns at leaking microaneurysms or grid laser burns in regions of diffuse breakdown of the blood-retinal barrier. The rationale of panretinal photocoagulation for DR is to ablate ischemic areas of the peripheral retina and thereby reduce the induction of angiogenic growth factors. Results of the Diabetic Retinopathy Study demonstrated that panretinal photocoagulation effectively reduces the risk of vision loss in a majority (60%) of patients with PDR (38,76). The ETDRS compared

outcomes in eyes assigned to either deferral of macular laser photocoagulation or immediate treatment for clinically significant DME (37). Results showed that macular laser photocoagulation reduced the risk of vision loss by 50% for patients with clinically significant DME (33,37,77,78). Macular focal and grid laser photocoagulation is indicated for clinically significant DME, and panretinal photocoagulation is indicated for high-risk PDR (37,38,79,80).

**Vitrectomy.** In more severe cases of DR, specifically those with tractional retinal detachment or severe nonclearing vitreous hemorrhage, vitrectomy is indicated to prevent blindness and/or severe visual loss (80–83). During vitrectomy, incisions are made at the pars plana, a portion of the sclera located posterior to the cornea and lens but anterior to the retina. The procedure may also be used to release vitreoretinal traction by excising membranes causing tractional detachments of the retina (38). In addition, panretinal photocoagulation can be applied during pars plana vitrectomy to treat the underlying PDR. This is typically performed with a fiber optic endolaser probe intraoperatively.

Vitrectomy is clearly beneficial for the treatment of advanced active PDR (84). Early vitrectomy increased the percentage of eyes with a VA of  $\geq 10/20$  to 44%, compared with 28% in a conventionally managed group (84). The use of early vitrectomy is also warranted for eyes with very severe PDR, but not for patients with less severe DR (84,85). However, recent advances in surgical techniques and technology since the Diabetic Retinopathy Vitrectomy Study have led to enhancement of the risk-to-benefit ratio for pars plana vitrectomy and widening indications for this procedure.

**Benefits and disadvantages.** Given the risk of blindness without treatment, laser photocoagulation and/or vitrectomy will continue to have a major role in the management of DR/DME. Both laser photocoagulation and vitrectomy improve quality of life for patients with DR and are cost-effective (86,87). However, these interventions are indicated only when DR has progressed to a measurably advanced stage in which some VA may already be lost. Side effects, such as loss of peripheral, night, or color vision, are rarely noted by some photocoagulation-treated patients (77). Vitrectomy can accelerate



**Figure 1**—Metabolic pathways implicated in the development of diabetic microvascular complications.

cataract formation and includes risks of retinal detachment and endophthalmitis, which fortunately are rare (88). In some patients treated with photocoagulation, DR continues to progress and ongoing treatment is necessary. DME can also occur.

### POTENTIAL PHARMACOLOGICAL THERAPIES

— Because of the limitations of current treatments, new pharmacological therapies are being developed, targeting the underlying biochemical mechanisms that cause DR/DME. The rationale behind the use of these agents is the prevention of diabetes-induced damage to the retinal microvasculature. The mechanisms that contribute to cellular damage in the retina include increased flux through the polyol pathway leading to sorbitol accumulation, production of advanced glycation end products (AGEs), increased oxidative stress, and activation of the protein kinase C (PKC)- $\beta$  pathway (Fig. 1). Each of these mechanisms has been targeted with specific inhibitory compounds, some of which may become viable therapies to treat DR/DME. Blood vessel formation plays a pivotal role in the development of PDR, and various antiangiogenic agents are also under investigation as potential therapies for DR. Because there is considerable overlap among these and other pathways in the pathogenesis of DR (89,90), combinations of therapies may prove to be more effective in preventing DR.

### Role of sorbitol accumulation and use of aldose reductase inhibitors

The hyperglycemia of diabetes leads to an increased flux through the polyol pathway, resulting in elevated levels of sorbitol (91). The net effect is a buildup of intracellular sorbitol and fructose. The ensuing disruption of the osmotic balance in the cell is believed to result in cellular damage (91), which may be important in the loss of integrity of the blood-retinal barrier, among other complications. Loss of retinal pericytes in the earliest stages of DR may be due to their sensitivity to polyols (20,21,92). The “*myo*-inositol depletion hypothesis” has also been put forth to explain the physiological impairment of retinal pigment epithelial cells and pericytes by hyperglycemia (93–95). Retinal pigment epithelial cells grown under high glucose conditions show marked increases in sorbitol and decreases in *myo*-inositol content, which were prevented by sorbinil, an aldose reductase inhibitor (ARI) (93). Pericytes grown under high glucose conditions also demonstrate ARI- and *myo*-inositol-reversible alterations in inositol phospholipid metabolism and DNA synthesis (94). Reducing the intracellular load of sorbitol in the retina and other tissues susceptible to microvascular damage (e.g., nerves and kidney) is a goal of these experimental therapies.

Clinical trials of ARI (sorbinil, ponalrestat, and tolrestat) have been conducted for the treatment of DR (96–99). Unfortunately, ARIs have shown little therapeutic promise for DR thus far. Treatment

effects, such as decreases in microaneurysm count (96) and fluorescein leakage (99), are observed in patients. However, there appears to be little significance of these effects on the progression of DR (97,98). One study found that ARI treatment normalized nerve conduction abnormalities in diabetic dogs but had no effect on the development of DR (99,100). Despite numerous attempts to target inhibition of the aldose reductase pathway alone, it appears that this is insufficient to impact diabetic microvascular complications.

### Role of AGEs and use of AGE inhibitors

Carbohydrates interact with protein side chains in a nonenzymatic fashion to form Amadori products, and these may subsequently form AGEs, especially in the presence of high glucose (101,102). Excessive formation of AGEs has been proposed as another biochemical link between diabetes and the development of microvascular complications. AGEs may affect such functions as enzyme activity, binding of regulatory molecules, and susceptibility of proteins to proteolysis (101). The chronic interaction of these products with at least one specific cell surface receptor for AGEs (AGE-specific receptor) may perpetuate a proinflammatory signaling process and a pro-atherosclerotic state in vascular tissues (103,104). In vitro, the AGE-AGE-specific receptor interaction has been associated with oxidative stress and the activation of nuclear factor- $\kappa$ B, which leads to hyperexpression of proinflammatory cytokines, lymphocyte adhesion molecules (e.g., V-CAM-1), vasoactive mediators, and pro-coagulant factors (104). These processes may result in disruptions of retinal hemodynamics and/or damage to vascular endothelial cells. Accordingly, strategies to reduce AGE formation in the absence of achieving euglycemia have been investigated as potential preventive therapies for diabetic microvascular complications (102).

The inhibition of AGE formation using compounds such as aminoguanidine has been investigated to prevent some of the diabetic vascular abnormalities. AGE accumulation in the retinal capillaries of diabetic rats can be blocked with the use of aminoguanidine (105). The reduction in AGE accumulation was also associated with a reduced number of acellular capillaries and pericyte loss (105). In another

rodent model of DR, aminoguanidine reduced retinal oxidative stress and PKC activity caused by diabetes or galactosemia (106), suggesting that these pathways may also be involved in its beneficial effects on DR. In diabetic dogs, aminoguanidine effectively prevented the development of DR but did not have a significant effect on AGE formation (107). The utility of these compounds for the prevention of DR remains to be proven in humans (108).

### Role of the PKC- $\beta$ pathway and use of PKC- $\beta$ inhibitors

Experimental studies have shown that PKC activity and levels of diacylglycerol (DAG), an activator of PKC, are increased after exposure of vascular tissues to elevated glucose (109,110). Diabetes-induced DAG may derive from hydrolysis of phosphatidylinositides, metabolism of phosphatidylcholine, or de novo synthesis of phosphatidic acid (26). PKC activity is also increased after exposure of vascular endothelial cells to oxidative stress, another mechanism implicated in the development and progression of diabetic microvascular complications (90,111). PKC- $\beta$  and - $\delta$  have been identified as the predominant isoforms activated in vascular tissues in response to hyperglycemia (26,109). PKC- $\beta$  has been shown to have an important role in regulating endothelial cell permeability (112) and is an important signaling component for VEGF (113). Transgenic animals overexpressing PKC- $\beta$  in vascular tissues developed retinal hemodynamic abnormalities similar to those observed in human DR (114).

The role of PKC in many cellular processes suggests that inhibition of all PKC isoforms would cause unacceptable toxicity (115). Ruboxistaurin (LY333531), a specific inhibitor of PKC- $\beta$ 1 and - $\beta$ 2 (115), has been shown to prevent and reverse microvascular complications in animal models of diabetes (116), to block neovascularization associated with retinal ischemia (117), and to inhibit the effect of VEGF on retinal permeability and endothelial cell growth (118). In patients with minimal DR, ruboxistaurin reversed retinal blood flow abnormalities and was well tolerated (119). Additional trials are evaluating the utility of ruboxistaurin for the treatment and prevention of DR and DME.

PKC412 inhibits the  $\alpha$ ,  $\beta$ , and  $\gamma$  isoforms with similar half-maximal inhibi-

tion concentration ( $IC_{50}$ ) values ranging from 22 to 31 nmol/l and may be useful in the treatment of DR and other disorders (120,121). The kinase domain of the human VEGF receptor-2 (KDR) and the platelet-derived growth factor receptor  $\beta$  are also inhibited by PKC412 at  $IC_{50}$  values ranging from 20 to 100 nmol/l (120). In an animal model of neovascularization, PKC412 inhibited ischemia-induced angiogenesis as well as retinal vessel formation during development (120). However, early pharmacodynamic studies of PKC412 have resulted in some adverse outcomes, which may reflect PKC412's relative lack of specificity (122). Further trials will be needed to determine whether this compound will be useful in the treatment of DR in humans.

### Role of oxidative stress and use of antioxidant compounds

Production of reactive oxygen species (ROS) has been implicated in the development of diabetic complications (123). Diabetes may cause ROS production through glucose auto-oxidation, increased flux through the polyol pathway, and increases in protein glycation (123). ROS may activate aldose reductase and PKC and increase AGE production and DAG formation (90).

The pervading role of ROS in the biochemical processes leading to microvascular damage has prompted an investigation of antioxidants as preventive therapy for diabetic complications (124). Inhibition of superoxide production can effectively block sorbitol accumulation, AGE formation, and PKC activation (125). These findings suggest that ROS production is associated with at least three mechanisms of diabetes-induced vascular damage. Antioxidants are effective inhibitors of pericyte loss secondary to diabetes in experimental models (21,126). Tocopherol also inhibits hyperglycemia-induced DAG production and PKC (124,127). Tocopherol prevents retinal hemodynamic abnormalities in diabetic rats (127). In patients with type 1 diabetes and little or no baseline retinopathy, retinal blood flow was significantly increased after 4 months of tocopherol therapy ( $P < 0.001$ ) (128). Recent results of the Heart Outcomes Prevention Evaluation study and other trials showed a lack of effect of tocopherol in the prevention of cardiovascular risks, despite suggestive evidence to the contrary (129–131).

### Role of angiogenic factors and the use of anti-angiogenic agents

New blood vessel (angiogenesis) formation is central to the pathology of PDR and is stimulated by such factors as VEGF in response to retinal ischemia, which occurs because of capillary loss and/or microaneurysm formation (29). VEGF is a key mediator of angiogenesis in the retina (30). Clinical studies have shown that VEGF levels increase in patients as they progress from nonproliferative DR to active PDR (29,30). Successful panretinal photocoagulation has been found to reduce intraocular VEGF levels by 75% ( $P = 0.008$ ) in patients treated for ocular neovascularization (29). This suggests that specific inhibition of VEGF activity may prevent retinal neovascularization and associated blood flow abnormalities. Inhibition of VEGF signaling using ruboxistaurin prevented VEGF-induced increases in vascular permeability (118).

The importance of angiogenesis in the pathology of DR has prompted the investigation of angiostatic therapies for the treatment of DR and DME (132). Early results in mice have been encouraging (133). The role of VEGF in retinal neovascularization has also prompted the development of VEGF-specific inhibitors such as antibodies to VEGF (134). These antibodies may be especially useful for the prevention of neovascularization during the very early stages of PDR. Another potent endogenous inhibitor of angiogenesis is pigment endothelium-derived factor (PEDF). PEDF inhibits angiogenesis induced by a wide variety of growth factors in addition to VEGF (135,136). In a mouse model of ischemia-induced retinopathy, systemic administration of recombinant PEDF completely inhibited the development of ischemia-provoked retinal vascular anomalies without affecting the development of normal retinal vessels (136). These findings suggest that PEDF may be useful as a primary intervention in the treatment of early DR.

### Other potential therapies for retinopathy prevention

Somatostatin activity is linked with the progression of DR (137,138), and hypophysectomy has been proposed as an intervention for severe treatment-resistant DR. Consequently, somatostatin has been evaluated for the treatment of DR (137–139). Early results in patients with PDR were encouraging, although

some evidence for resistance to the drug was noted (137,139). In a recent trial of patients with severe nonproliferative DR or early PDR, therapy with octreotide (a somatostatin analog) decreased the need for retinal photocoagulation compared with conventional treatment (1/22 vs. 9/24 eyes) (138). However, the incidence of progression to severe PDR was not significantly different between the treatment arms (138). Additional controlled trials will determine whether somatostatin analog therapy is a viable therapeutic option for patients with more advanced stages of DR.

Experimental results indicate that high-dose aspirin suppresses diabetes-induced retinal TNF expression, nuclear factor- $\kappa$ B activity, and leukocyte cell adhesion molecule expression, which are implicated in endothelial cell injury and breakdown of the blood-retinal barrier (140). There is evidence that aspirin alone or in combination with dipyridamole could decrease the yearly increase in microaneurysms in patients with early DR (141). However, among patients with mild to severe nonproliferative DR, aspirin therapy (650 mg/day) was shown to have no significant effect on DR progression nor to confer any increased risk of vitreous hemorrhage (142). Thus, whereas aspirin prophylaxis may be useful in the early stages of DR and DME, this benefit appears to be lost in later stages of disease.

There is evidence suggesting that inhibitors of the renin-angiotensin system may have additional effects on DR that are independent of their hypotensive abilities (69,71,143). Lisinopril, an ACE inhibitor, reduced retinal neovascularization, VEGF, and VEGF type 2 receptor expression in a rat model of retinopathy of prematurity (144). Similarly, diabetes-induced retinal VEGF expression and hyperpermeability were also inhibited by a similar treatment (145). Whether these beneficial effects are independent of the hypotensive action of these compounds is not yet known; nonetheless, their inhibitory effects on VEGF expression may be especially important in the early stages of PDR. Candesartan, a potent angiotensin II receptor antagonist, decreases VEGF expression and ameliorates retinal abnormalities in diabetic rats (146).

### Staging and assessing efficacy of potential therapies

**Limitations of current staging methods.** The evaluation of pharmacological interventions for a given condition requires standardized clinically meaningful end points that can be assessed in a quantitative manner. In the case of DR, the scale most widely used is the ETDRS DR severity scale (34). As discussed above, this scale has been used to assess the severity of retinopathy in major intervention trials for diabetes control (67). Other trials evaluated the effects of diabetes control on the development and progression of DR, using such end points as the need for photocoagulation or the development of PDR or severe nonproliferative DR. The use of these clinical end points implies that some degree of sight-threatening DR already exists in a subject, and end points such as these are of limited value in discerning the effects of pharmacological therapies on early DR. A more efficient way to assess these earlier stages in clinical trials would be to assess stepwise progression on the ETDRS scale. Data from the Wisconsin Epidemiologic Study of Diabetic Retinopathy demonstrate that a progression of one or more steps on the ETDRS scale is predictive of the development of PDR or clinically significant DME (relative risk, 5.9 and 3.8, respectively) (36). The use of the  $\geq 1$  step ETDRS progression as an end point in clinical trials of new pharmacological agents will reduce the sample size and trial duration needed to assess efficacy (36). Although the ETDRS staging system is widely used in clinical trials, it is rarely used clinically, given its complexity. Consequently, pharmacological agents that alter the risk of progression along steps of the ETDRS scale may not be clinically meaningful to practitioners. It will be necessary to correlate changes in steps of ETDRS progression to the International Clinical Diabetic Retinopathy and Diabetic Macular Edema Disease Severity Scales.

**Surrogate outcomes.** As new treatments become available, alternative outcomes must also be devised that can accurately predict the progression of DR from its initial stages. For example, the detection and quantitation of microaneurysm formation and/or other retinal capillary abnormalities using FA may be a sufficiently sensitive means to evaluate the effect of pharmacological therapy on early changes in the blood-retinal barrier

(55). The situation is greatly complicated by the nonlinear progression of DR. Clinical signs may spontaneously resolve and thus may mask true progression of the disease (55). There is no straightforward method to address this issue at present and more research is needed in this area. The use of multiple surrogate end points, such as a two-step ETDRS progression, measurement of retinal thickness, and assessment of fluorescein leakage, has been proposed as one means to overcome this obstacle (55). Such outcomes will need to be validated in clinical trials to determine whether they can accurately predict progression of DR in a clinically useful manner.

**CONCLUSIONS**— Diabetic eye disease severely affects quality of life for patients with diabetes by decreasing VA and increasing the risk of blindness. The DR condition results in loss of capillary integrity, microaneurysm formation, and ischemia, which in turn drive the progression of PDR. Accumulation of fluid in the retina secondary to capillary leakage and/or microaneurysms results in DME, which contributes to loss of vision in DR. There is substantial evidence that control over metabolic factors can effectively prevent the development and progression of DR/DME. However, many patients fail to achieve or maintain optimal levels of metabolic control. For such patients, early detection and timely treatment of DR remains the standard of care. Although they are effective, sight-saving interventions, laser photocoagulation therapy, and vitrectomy are invasive, associated with destructive side effects, and only treat the late stages of disease. A number of pharmacological agents that could slow the progression of DR/DME in earlier stages are now being tested. These therapies have derived from improved understanding of the complex and often overlapping pathways involved in diabetes-induced microvascular damage. It is likely that one or more of these pharmacological interventions, or possibly combinations thereof, will be effective in reducing the progression of DR and DME and the associated vision loss. With the introduction of these therapies in the coming years, there will be a need for improved screening. It is critical that health care providers interact with one another in managing patients to ensure that high-risk individuals are screened early. Technological advances are giving patients

more access to proper screening and may make this a more achievable goal.

**Acknowledgments**— The authors thank Drs. Erin A. Kingshill and Peter D. Ho for their help with the manuscript.

**References**

1. Mokdad AH, Ford ES, Bowman BA, Nelson DE, Engelgau MM, Vinicor F, Marks JS: Diabetes trends in the U.S.: 1990–1998. *Diabetes Care* 23:1278–1283, 2000
2. MacKinnon JR, Forrester JV: Diabetic retinopathy. In *Oxford Textbook of Endocrinology and Diabetes*. Wass JAH, Shalet SM, Eds. Oxford, U.K., Oxford University Press, 2002, p. 1764–1778
3. Centers for Disease Control and Prevention: Blindness caused by diabetes: Massachusetts, 1987–1994. *MMWR* 45:937–941, 1996
4. Moss SE, Klein R, Klein BE: The 14-year incidence of visual loss in a diabetic population. *Ophthalmology* 105:998–1003, 1998
5. Riordan-Eva P: Eye. In *Current Medical Diagnosis and Treatment*. 42nd ed. Tierney LM, McPhee SJ, Papadakis MA, Eds. New York, Lange Medical Books/McGraw-Hill, 2003, p. 146–177
6. Klein R, Klein BEK, Moss SE, Cruickshanks K: The Wisconsin Epidemiologic Study of Diabetic Retinopathy, XV: the long-term incidence of macular edema. *Ophthalmology* 102:7–16, 1995
7. Ferris FL III, Patz A: Macular edema: a complication of diabetic retinopathy. *Surv Ophthalmol* 28 (Suppl.):452–461, 1984
8. Rahmani B, Tielsch JM, Katz J, Gottsch J, Quigley H, Javitt J, Sommer A: The cause-specific prevalence of visual impairment in an urban population: the Baltimore Eye Survey. *Ophthalmology* 103:1721–1726, 1996
9. Chiang YP, Bassi LJ, Javitt JC: Federal budgetary costs of blindness. *Milbank Q* 70:319–340, 1992
10. Brown MM, Brown GC, Sharma S, Shah G: Utility values and diabetic retinopathy. *Am J Ophthalmol* 128:324–330, 1999
11. Klein R, Klein BE, Moss SE, Davis MD, DeMets DL: Glycosylated hemoglobin predicts the incidence and progression of diabetic retinopathy. *JAMA* 260:2864–2871, 1988
12. Vitale S, Maguire MG, Murphy RP, Hiner CJ, Rourke L, Sackett C, Patz A: Clinically significant macular edema in type I diabetes. *Ophthalmology* 102:1170–1176, 1995
13. Chew EY, Klein ML, Ferris FL III, Rema-

- ley NA, Murphy RP, Chantry K, Hoogwerf BJ, Miller D: ETDRS Research Group: association of elevated serum lipid levels with retinal hard exudate in diabetic retinopathy: Early Treatment of Diabetic Retinopathy Study (ETDRS) Report No 22. *Arch Ophthalmol* 114:1079–1084, 1996
14. Klein R, Klein BEK, Moss SE, Cruickshanks K: The Wisconsin Epidemiologic Study of Diabetic Retinopathy, XVII: the 14-year incidence and progression of diabetic retinopathy and associated risk factors in type I diabetes. *Ophthalmology* 105:1801–1815, 1998
15. Kubawara T, Cogan DG: Retinal vascular patterns, VI: mural cells of the retinal capillaries. *Arch Ophthalmol* 69:492–502, 1962
16. Sims DE: The pericyte: a review. *Tissue Cell* 18:153–174, 1986
17. Antonelli-Orlidge A, Smith SR, D'Amore PA: Influence of pericytes on capillary endothelial cell growth. *Am Rev Respir Dis* 140:1129–1131, 1989
18. Antcliff RJ, Marshall J: The pathogenesis of edema in diabetic maculopathy. *Semin Ophthalmol* 14:223–232, 1999
19. Ciulla TA, Harris A, Latkany P, Piper HC, Arend O, Garzosi H, Martin B: Ocular perfusion abnormalities in diabetes. *Acta Ophthalmol Scand* 80:468–477, 2002
20. Speiser P, Gittelsohn AM, Patz A: Studies on diabetic retinopathy, III: influence of diabetes on intramural pericytes. *Arch Ophthalmol* 80:332–337, 1968
21. Ansari NH, Zhang W, Fulep E, Mansour A: Prevention of pericyte loss by trolox in diabetic rat retina. *J Toxicol Environ Health A* 54:467–475, 1998
22. Paget C, Lecomte M, Ruggiero D, Wiernperger N, Lagarde M: Modification of enzymatic antioxidants in retinal microvascular cells by glucose or advanced glycation end products. *Free Radic Biol Med* 25:121–129, 1998
23. Cogan DG, Toussaint D, Kubawara T: Retinal vascular patterns, IV: diabetic retinopathy. *Arch Ophthalmol* 66:366–378, 1961
24. Mogensen CE, Osterby R, Gundersen HJ: Early functional and morphologic vascular renal consequences of the diabetic state. *Diabetologia* 17:71–76, 1979
25. Williamson JR, Kilo C: Extracellular matrix changes in diabetes mellitus. In *Comparative Pathobiology of Major Age-Related Diseases*. Scarpelli DG, Migahi DG, Eds. New York, Liss, 1984, p. 269–288
26. Koya D, King GL: Protein kinase C activation and the development of diabetic complications. *Diabetes* 47:859–866, 1998
27. Miyamoto K, Ogura Y: Pathogenetic potential of leukocytes in diabetic retinop-

Downloaded from http://diabetesjournals.org/care/article-pdf/25/9/2653/685186/40903002653.pdf by guest on 25 January 2025



- athy. *Semin Ophthalmol* 14:233–239, 1999
28. Miyamoto K, Khosrof S, Bursell SE, Rohan R, Murata T, Clermont AC, Aiello LP, Ogura Y, Adamis AP: Prevention of leukostasis and vascular leakage in streptozotocin-induced diabetic retinopathy via intercellular adhesion molecule-1 inhibition. *Proc Natl Acad Sci U S A* 96:10836–10841, 1999
  29. Aiello LP, Avery RL, Arrigg PG, Keyt BA, Jampel HD, Shah ST, Pasquale LR, Thiem H, Iwamoto MA, Park JE, Nguyen HV, Aiello LM, Ferrara N, King GL: Vascular endothelial growth factor in ocular fluid of patients with diabetic retinopathy and other retinal disorders. *N Engl J Med* 331:1480–1487, 1994
  30. Miller JW, Adamis AP, Aiello LP: Vascular endothelial growth factor in ocular neovascularization and proliferative diabetic retinopathy. *Diabetes Metab Rev* 13:37–50, 1997
  31. Hutchinson A, McIntosh A, Peters J, O’Keeffe C, Khunti K, Baker R, Booth A: Effectiveness of screening and monitoring tests for diabetic retinopathy: a systematic review. *Diabet Med* 17:495–506, 2000
  32. American Diabetes Association: Diabetic retinopathy. *Diabetes Care* 23 (Suppl. 1):S73–S76, 2000
  33. Singer DE, Nathan DM, Fogel HA, Schachat AP: Screening for diabetic retinopathy. *Ann Intern Med* 116:660–671, 1992
  34. Early Treatment Diabetic Retinopathy Study Research Group: Grading diabetic retinopathy from stereoscopic color fundus photographs: an extension of the modified Airlie House classification: ETDRS Report No 10. *Ophthalmology* 98(Suppl.):786–806, 1991
  35. American Academy of Ophthalmology: Diabetic Retinopathy Disease Severity Scale. 2002. Available from [http://www.aao.org/aao/education/library/international\\_DR.cfm](http://www.aao.org/aao/education/library/international_DR.cfm). Accessed 14 January 2003
  36. Klein R, Klein BE, Moss SE: How many steps of progression of diabetic retinopathy are meaningful? The Wisconsin Epidemiologic Study of Diabetic Retinopathy. *Arch Ophthalmol* 119:547–553, 2001
  37. Early Treatment Diabetic Retinopathy Study Research Group: Photocoagulation for diabetic macular edema: Early Treatment Diabetic Retinopathy Study Report No. 1. *Arch Ophthalmol* 103:1796–1806, 1985
  38. Ferris FL III: How effective are treatments for diabetic retinopathy? *JAMA* 269:1290–1291, 1993
  39. Bailey CC, Sparrow JM, Grey RH, Cheng H: The National Diabetic Retinopathy Laser Treatment Audit, III: clinical outcomes. *Eye* 13:151–159, 1999
  40. Diabetes Control and Complications Trial/Epidemiology of Diabetes Interventions and Complications Research Group: Retinopathy and nephropathy in patients with type 1 diabetes four years after a trial of intensive therapy. *N Engl J Med* 342:381–389, 2000
  41. Aldington SJ, Kohner EM, Meuer S, Klein R, Sjolie AK: Methodology for retinal photography and assessment of diabetic retinopathy: the EURODIAB IDDM complications study. *Diabetologia* 38:437–444, 1995
  42. Shiba T, Yamamoto T, Seki U, Utsugi N, Fujita K, Sato Y, Terada H, Sekihara H, Hagura R: Screening and follow-up of diabetic retinopathy using a new mosaic 9-field fundus photography system. *Diabetes Res Clin Pract* 55:49–59, 2002
  43. Newsom R, Moate B, Casswell T: Screening for diabetic retinopathy using digital colour photography and oral fluorescein angiography. *Eye* 14:579–582, 2000
  44. Bursell SE, Cavallerano JD, Cavallerano AA, Clermont AC, Birkmire-Peters D, Aiello LP, Aiello LM: Stereo nonmydriatic digital-video color retinal imaging compared with Early Treatment Diabetic Retinopathy Study seven standard field 35-mm stereo color photos for determining level of diabetic retinopathy. *Ophthalmology* 108:572–585, 2001
  45. Liesenfeld B, Kohner E, Piehlmeier W, Kluthe S, Aldington S, Porta M, Bek T, Obermaier M, Mayer H, Mann G, Holle R, Hepp KD: A telemedical approach to the screening of diabetic retinopathy: digital fundus photography. *Diabetes Care* 23:345–348, 2000
  46. Cook HL, Heacock GL, Stanford MR, Marshall J: Detection of retinal lesions after telemedicine transmission of digital images. *Eye* 14:563–571, 2000
  47. Gómez-Ulla F, Fernandez MI, Gonzalez F, Rey P, Rodriguez M, Rodriguez-Cid MJ, Casanueva FF, Tome MA, Garcia-Tobio J, Gude F: Digital retinal images and teleophthalmology for detecting and grading diabetic retinopathy. *Diabetes Care* 25:1384–1389, 2002
  48. Sinthanayothin C, Boyce JF, Williamson TH, Cook HL, Mensah E, Lal S, Usher D: Automated detection of diabetic retinopathy on digital fundus images. *Diabet Med* 19:105–112, 2002
  49. Moss SE, Klein R, Kessler SD, Richie KA: Comparison between ophthalmoscopy and fundus photography in determining severity of retinopathy. *Ophthalmology* 92:62–67, 1985
  50. Owens DR, Gibbins RL, Lewis PA, Wall S, Allen JC, Morton R: Screening for diabetic retinopathy by general practitioners: ophthalmoscopy or retinal photography as 35 mm colour transparencies? *Diabet Med* 15:170–175, 1998
  51. Griffith SP, Freeman WL, Shaw CJ, Mitchell WH, Olden CR, Figgs LD, Kinyoun JL, Underwood DL, Will JC: Screening for diabetic retinopathy in a clinical setting: a comparison of direct ophthalmoscopy by primary care physicians with fundus photography. *J Fam Pract* 37:49–56, 1993
  52. Harding SP, Broadbent DM, Neoh C, White MC, Vora J: Sensitivity and specificity of photography and direct ophthalmoscopy in screening for sight threatening eye disease: the Liverpool Diabetic Eye Study. *Br Med J* 311:1131–1135, 1995
  53. Kinyoun JL, Martin DC, Fujimoto WY, Leonetti DL: Ophthalmoscopy versus fundus photographs for detecting and grading diabetic retinopathy. *Invest Ophthalmol Vis Sci* 33:1888–1893, 1992
  54. Hara T, Inami M, Hara T: Efficacy and safety of fluorescein angiography with orally administered sodium fluorescein. *Am J Ophthalmol* 126:560–564, 1998
  55. Cunha-Vaz JG: Diabetic retinopathy: surrogate outcomes for drug development for diabetic retinopathy. *Ophthalmologica* 214:377–380, 2000
  56. Cree MJ, Olson JA, McHardy KC, Sharp PF, Forrester JV: A fully automated comparative microaneurysm digital detection system. *Eye* 11:622–638, 1997
  57. Agardh E, Cavallin-Sjoberg U: Peripheral retinal evaluation comparing fundus photographs with fluorescein angiograms in patients with diabetes mellitus. *Retina* 18:420–423, 1998
  58. Diabetes Control and Complications Trial Research Group: Color photography vs fluorescein angiography in the detection of diabetic retinopathy in the diabetes control and complications trial. *Arch Ophthalmol* 105:1344–1351, 1987
  59. Ivanisevic M, Stanic R: Importance of fluorescein angiography in the early detection and therapy of diabetic retinopathy. *Ophthalmologica* 201:9–13, 1990
  60. Pacurariu RI: Low incidence of side effects following intravenous fluorescein angiography. *Ann Ophthalmol* 14:32–36, 1982
  61. Malone JI, Morrison AD, Pavan PR, Cuthbertson DD: Prevalence and significance of retinopathy in subjects with type 1 diabetes of less than 5 years’ duration screened for the Diabetes Control and Complications Trial. *Diabetes Care* 24:522–526, 2001
  62. Brechner RJ, Cowie CC, Howie LJ, Herman WH, Will JC, Harris MI: Ophthalmic examination among adults with diagnosed diabetes mellitus. *JAMA* 270:1714–1718, 1993
  63. Mukamel DB, Bresnick GH, Wang Q, Dickey CF: Barriers to compliance in screening guidelines for diabetic reti-

- nopathy. *Ophthalmic Epidemiol* 6:61–72, 1999
64. Schoenfeld ER, Greene JM, Wu SY, Leske MC: Patterns of adherence to diabetes vision care guidelines: baseline findings from the Diabetic Retinopathy Awareness Program. *Ophthalmology* 108:563–571, 2001
  65. Klein R, Klein BE: Screening for diabetic retinopathy, revisited. *Am J Ophthalmol* 134:261–263, 2002
  66. Aiello LP, Cahill MT, Wong JS: Systemic considerations in the management of diabetic retinopathy. *Am J Ophthalmol* 132:760–776, 2001
  67. Diabetes Control and Complications Trial Research Group: The effect of intensive treatment of diabetes on the development and progression of long-term complications in insulin-dependent diabetes mellitus. *N Engl J Med* 329:977–986, 1993
  68. UK Prospective Diabetes Study Group: Intensive blood-glucose control with sulphonylureas or insulin compared with conventional treatment and risk of complications in patients with type 2 diabetes: UKPDS 33. *Lancet* 352:837–853, 1998
  69. Chaturvedi N, Sjolie A-K, Stephenson JM, Abrahamian H, Keipes M, Castellarin A, Rogulja-Pepeonik Z, Fuller JH: EUCLID Study Group: Effect of lisinopril on progression of retinopathy in normotensive people with type 1 diabetes. *Lancet* 351:28–31, 1998
  70. UK Prospective Diabetes Study Group: Efficacy of atenolol and captopril in reducing risk of macrovascular and microvascular complications in type 2 diabetes: UKPDS 39. *Br Med J* 317:713–720, 1998
  71. UK Prospective Diabetes Study Group: Tight blood pressure control and risk of macrovascular and microvascular complications in type 2 diabetes: UKPDS 38. *Br Med J* 317:703–713, 1998
  72. Klein BEK, Moss SE, Klein R, Surawicz TS: The Wisconsin Epidemiologic Study of Diabetic Retinopathy, XIII: relationship of serum cholesterol to retinopathy hard exudate. *Ophthalmology* 98:1261–1265, 1991
  73. Gordon B, Chang S, Kavanagh M, Berrocal M, Yannuzzi L, Robertson C, Drexler A: The effects of lipid lowering on diabetic retinopathy. *Am J Ophthalmol* 112:385–391, 1991
  74. American Association of Clinical Endocrinologists: The American Association of Clinical Endocrinologists Medical Guidelines for the Management of Diabetes Mellitus: the AACE system of intensive diabetes self-management: 2000 update. *Endocr Pract* 6:43–84, 2000
  75. Chase HP, Lockspeiser T, Peery B, Shepherd M, MacKenzie T, Anderson J, Garg SK: The impact of the Diabetes Control and Complications Trial and humalog insulin on glycohemoglobin levels and severe hypoglycemia in type 1 diabetes. *Diabetes Care* 24:430–434, 2001
  76. The Diabetic Retinopathy Study (DRS) Research Group: Preliminary report on the effects of photocoagulation therapy: DRS Report No. 1. *Am J Ophthalmol* 81:383–396, 1976
  77. Early Treatment Diabetic Retinopathy Study Research Group: Early photocoagulation for diabetic retinopathy: ETDRS Report No 9. *Ophthalmology* 98 (Suppl.):766–785, 1991
  78. Ai E: Current management of diabetic retinopathy. *West J Med* 157:67–70, 1992
  79. Early Treatment Diabetic Retinopathy Study Research Group: Treatment techniques and clinical guidelines for photocoagulation of diabetic macular edema: Early Treatment Diabetic Retinopathy Study Report No. 2. *Ophthalmology* 94:761–774, 1987
  80. Raskin P, Arauz-Pacheco C: The treatment of diabetic retinopathy: a view for the internist. *Ann Intern Med* 117:226–233, 1992
  81. Ho T, Smiddy WE, Flynn HW Jr: Vitrectomy in the management of diabetic eye disease. *Surv Ophthalmol* 37:190–202, 1992
  82. Arrigg PG, Cavallerano J: The role of vitrectomy for diabetic retinopathy. *J Am Optom Assoc* 69:733–740, 1998
  83. Capone A Jr, Panozzo G: Vitrectomy for refractory diabetic macular edema. *Semin Ophthalmol* 15:78–80, 2000
  84. Diabetic Retinopathy Vitrectomy Study Research Group: Early vitrectomy for severe proliferative diabetic retinopathy in eyes with useful vision: results of a randomized trial: Diabetic Retinopathy Vitrectomy Study Report No 3. *Ophthalmology* 95:1307–1320, 1988
  85. Diabetic Retinopathy Vitrectomy Study Research Group: Early vitrectomy for severe vitreous hemorrhage in diabetic retinopathy: four-year results of a randomized trial: Diabetic Retinopathy Vitrectomy Study Report No 5. *Arch Ophthalmol* 108:958–964, 1990
  86. Sharma S, Brown GC, Brown MM, Hollands H, Shah GK: The cost-effectiveness of grid laser photocoagulation for the treatment of diabetic macular edema: results of a patient-based cost-utility analysis. *Curr Opin Ophthalmol* 11:175–179, 2000
  87. Sharma S, Hollands H, Brown GC, Brown MM, Shah GK, Sharma SM: The cost-effectiveness of early vitrectomy for the treatment of vitreous hemorrhage in diabetic retinopathy. *Curr Opin Ophthalmol* 12:230–234, 2001
  88. Lewis H, Abrams GW, Blumenkranz MS, Campo RV: Vitrectomy for diabetic macular traction and edema associated with posterior hyaloidal traction. *Ophthalmology* 99:753–759, 1992
  89. Kowluru RA: Diabetes-induced elevations in retinal oxidative stress, protein kinase C and nitric oxide are interrelated. *Acta Diabetol* 38:179–185, 2001
  90. Nishikawa T, Edelstein D, Brownlee M: The missing link: a single unifying mechanism for diabetic complications. *Kidney Int* 58 (Suppl. 77):S26–S30, 2000
  91. Gabbay KH: Hyperglycemia, polyol metabolism, and complications of diabetes mellitus. *Annu Rev Med* 26:521–535, 1975
  92. Sato S, Secchi EF, Lizak MJ, Fukase S, Ohta N, Murata M, Tsai JY, Kador PF: Polyol formation and NADPH-dependent reductases in dog retinal capillary pericytes and endothelial cells. *Invest Ophthalmol Vis Sci* 40:697–704, 1999
  93. Del Monte MA, Rabbani R, Diaz TC, Latimer SA, Nakamura J, Brennan MC, Greene DA: Sorbitol, myo-inositol, and rod outer segment phagocytosis in cultured hRPE cells exposed to glucose: in vitro model of myo-inositol depletion hypothesis of diabetic complications. *Diabetes* 40:1335–1345, 1991
  94. Li WY, Tang L, Zhou Q, Qin M, Hu TS: DNA-synthesis regulation and correlation with inositol trisphosphate levels in cultured bovine retinal capillary pericytes. *Exp Eye Res* 49:677–683, 1989
  95. Li WY, Zhou Q, Qin M, Tao L, Lou M, Hu TS: Reduced absolute rate of myo-inositol biosynthesis of cultured bovine retinal capillary pericytes in high glucose. *Exp Eye Res* 52:569–573, 1991
  96. Sorbinil Retinopathy Trial Research Group: A randomized trial of sorbinil, an aldose reductase inhibitor, in diabetic retinopathy. *Arch Ophthalmol* 108:1234–1244, 1990
  97. Tromp A, Hooymans JM, Barendsen BC, van Doormaal JJ: The effects of an aldose reductase inhibitor on the progression of diabetic retinopathy. *Doc Ophthalmol* 78:153–159, 1991
  98. Arauz-Pacheco C, Ramirez LC, Pruneda L, Sanborn GE, Rosenstock J, Raskin P: The effect of the aldose reductase inhibitor, ponalrestat, on the progression of diabetic retinopathy. *J Diabetes Complications* 6:131–137, 1992
  99. van Gerven JM, Boot JP, Lemkes HH, van Best JA: Effects of aldose reductase inhibition with tolrestat on diabetic retinopathy in a six months double blind trial. *Doc Ophthalmol* 87:355–365, 1994
  100. Engerman RL, Kern TS, Larson ME: Nerve conduction and aldose reductase inhibition during 5 years of diabetes or galactosemia in dogs. *Diabetologia* 37:141–144, 1994

101. Brownlee M, Vlassara H, Cerami A: Non-enzymatic glycosylation and the pathogenesis of diabetic complications. *Ann Intern Med* 101:527–537, 1984
102. Friedman EA: Advanced glycosylated end products and hyperglycemia in the pathogenesis of diabetic complications. *Diabetes Care* 22 (Suppl. 2):B65–B71, 1999
103. Schmidt AM, Yan SD, Wautier J-L, Stern D: Activation of receptor for advanced glycation end products: a mechanism for chronic vascular dysfunction in diabetic vasculopathy and atherosclerosis. *Circ Res* 84:489–497, 1999
104. Singh R, Barden A, Mori T, Beilin L: Advanced glycation end-products: a review. *Diabetologia* 44:129–146, 2001
105. Hammes HP, Martin S, Federlin K, Geisen K, Brownlee M: Aminoguanidine treatment inhibits the development of experimental diabetic retinopathy. *Proc Natl Acad Sci U S A* 88:11555–11558, 1991
106. Kowluru RA, Engerman RL, Kern TS: Abnormalities of retinal metabolism in diabetes or experimental galactosemia, VIII: prevention by aminoguanidine. *Curr Eye Res* 21:814–819, 2000
107. Kern TS, Engerman RL: Pharmacological inhibition of diabetic retinopathy: aminoguanidine and aspirin. *Diabetes* 50:1636–1642, 2001
108. Freedman BI, Wuerth JP, Cartwright K, Bain RP, Dippe S, Hershon K, Mooradian AD, Spinowitz BS: Design and baseline characteristics for the aminoguanidine clinical trial in overt type 2 diabetic nephropathy (ACTION II). *Control Clin Trials* 20:493–510, 1999
109. Inoguchi T, Battan R, Handler E, Sportsman JR, Heath W, King GL: Preferential elevation of protein kinase C isoform beta II and diacylglycerol levels in the aorta and heart of diabetic rats: differential reversibility to glycemic control by islet cell transplantation. *Proc Natl Acad Sci U S A* 89:11059–11063, 1992
110. Xia P, Inoguchi T, Kern TS, Engerman RL, Oates PJ, King GL: Characterization of the mechanism for the chronic activation of diacylglycerol-protein kinase C pathway in diabetes and hypergalactosemia. *Diabetes* 43:1122–1129, 1994
111. Taher MM, Garcia JG, Natarajan V: Hydroperoxide-induced diacylglycerol formation and protein kinase C activation in vascular endothelial cells. *Arch Biochem Biophys* 303:260–266, 1993
112. Nagpala P, Malik AB, Vuong PT, Lum H: Protein kinase C b1 overexpression augments phorbol ester-induced increase in endothelial permeability. *J Cell Physiol* 166:249–255, 1996
113. Xia P, Aiello LP, Ishii H, Jiang ZY, Park DJ, Robinson GS, Takagi H, Newsome WP, Jirousek MR, King GL: Characterization of vascular endothelial growth factor's effect on the activation of protein kinase C, its isoforms, and endothelial cell growth. *J Clin Invest* 98:2018–2026, 1996
114. Takahara N, Clermont A, Kagokawa H, Takahara H, Kurihara H, Bursell S, King GL: Transgenic mice overexpressing protein kinase C  $\beta$  isoform mimicked the early changes of diabetes (Abstract). *Diabetes* 48:A138, 1999
115. Jirousek MR, Gillig JR, Gonzalez CM, Heath WF, McDonald JH III, Neel DA, Rito CJ, Singh U, Stramm LE, Melikian-Badalian A, Baevsky M, Ballas LM, Hall SE, Winneroski LL, Faul MM: (S)-13-[(dimethylamino)methyl]-10,11,14,15-tetrahydro-4,9:16,21-dimetheno-1H,13H-dibenzole,*k*]pyrrolo[3,4-*h*][1,4,13]oxadiazacyclohexadecene-1,3(2H)-dione (LY333531) and related analogues: isozyme selective inhibitors of protein kinase C  $\beta$ . *J Med Chem* 39:2664–2671, 1996
116. Ishii H, Jirousek MR, Koya D, Takagi C, Xia P, Clermont A, Bursell SE, Kern TS, Ballas LM, Heath WF, Stramm LE, Feener EP, King GL: Amelioration of vascular dysfunctions in diabetic rats by an oral PKC  $\beta$  inhibitor. *Science* 272:728–731, 1996
117. Danis RP, Bingaman DP, Jirousek MR, Yang Y: Inhibition of intraocular neovascularization caused by retinal ischemia in pigs by PKC $\beta$  inhibition with LY333531. *Invest Ophthalmol Vis Sci* 39:171–179, 1998
118. Aiello LP, Bursell S-E, Clermont A, Duh E, Ishii H, Takagi C, Mori F, Ciulla TA, Ways K, Jirousek M, Smith LE, King GL: Vascular endothelial growth factor-induced retinal permeability is mediated by protein kinase C in vivo and suppressed by an orally effective  $\beta$ -isoform-selective inhibitor. *Diabetes* 46:1473–1480, 1997
119. Aiello LP, Bursell S, Devries T, Alatorre C, King GL, Ways K: Protein kinase C  $\beta$  selective inhibitor LY333531 ameliorates abnormal retinal hemodynamics in patients with diabetes (Abstract). *Diabetes* 48:A19, 1999
120. Seo MS, Kwak N, Ozaki H, Yamada H, Okamoto N, Yamada E, Fabbro D, Hofmann F, Wood JM, Campochiaro PA: Dramatic inhibition of retinal and chorioidal neovascularization by oral administration of a kinase inhibitor. *Am J Pathol* 154:1743–1753, 1999
121. Fabbro D, Ruetz S, Bodis S, Pruschy M, Csermak K, Man A, Campochiaro P, Wood J, O'Reilly T, Meyer T: PKC412: a protein kinase inhibitor with a broad therapeutic potential. *Anticancer Drug Des* 15:17–28, 2000
122. Propper DJ, McDonald A, Man P, Thavasu P, Balkwill F, Braybrooke JP, Caponigro F, Graf P, Dutreix C, Blackie R, Kaye SB, Ganesan TS, Talbot DC, Harris AL, Twelves C: Phase I and pharmacokinetic study of PKC412, an inhibitor of protein kinase C. *J Clin Oncol* 19:1485–1492, 2001
123. Giugliano D, Ceriello A, Paolisso G: Oxidative stress and diabetic vascular complications. *Diabetes Care* 19:257–267, 1996
124. Bursell SE, Clermont AC, Aiello LP, Aiello LM, Schlossman DK, Feener EP, Laffel L, King GL: High dose vitamin E supplementation normalizes retinal blood flow and creatinine clearance in patients with type I diabetes. *Diabetes Care* 22:1245–1251, 1999
125. Nishikawa T, Edelstein D, Du XL, Yamagishi S, Matsumura T, Kaneda Y, Yorek MA, Beebe D, Oates PJ, Hammes HP, Giardino I, Brownlee M: Normalizing mitochondrial superoxide production blocks three pathways of hyperglycaemic damage. *Nature* 404:787–790, 2000
126. Brignardello E, Beltramo E, Molinatti PA, Aragno M, Gatto V, Tagagno E, Danni O, Porta M, Boccuzzi G: Dehydroepiandrosterone protects bovine retinal capillary pericytes against glucose toxicity. *J Endocrinol* 158:21–26, 1998
127. Kunisaki M, Bursell S-E, Clermont AC, Ishii H, Ballas LM, Jirousek MR, Umeda F, Nawata H, King GL: Vitamin E prevents diabetes-induced abnormal retinal blood flow via the diacylglycerol-protein kinase C pathway. *Am J Physiol* 269:E239–E246, 1995
128. Bursell S-E, King GL: Can protein kinase C inhibition and vitamin E prevent the development of diabetic vascular complications? *Diabetes Res Clin Pract* 45:169–182, 1999
129. Gey KF: The antioxidant hypothesis of cardiovascular disease: epidemiology and mechanisms. *Biochem Soc Trans* 18:1041–1045, 1990
130. Hoogwerf BJ, Young JB: The HOPE study: ramipril lowered cardiovascular risk, but vitamin E did not. *Cleveland Clin J Med* 67:287–293, 2000
131. Pruthi S, Allison TG, Hensrud DD: Vitamin E supplementation in the prevention of coronary heart disease. *Mayo Clin Proc* 76:1131–1136, 2001
132. Fotsis T, Zhang Y, Pepper MS, Adlercreutz H, Montesano R, Nawroth PP, Schweigerer L: The endogenous oestrogen metabolite 2-methoxyoestradiol inhibits angiogenesis and suppresses tumor growth. *Nature* 368:237–239, 1994
133. Penn JS, Rajaratnam VS, Collier RJ, Clark AF: The effect of an angiostatic steroid on neovascularization in a rat model of

- retinopathy of prematurity. *Invest Ophthalmol Vis Sci* 42:283–290, 2001
134. Presta LG, Chen H, O'Connor SJ, Chisholm V, Meng YG, Krummen L, Winkler M, Ferrara N: Humanization of anti-vascular endothelial growth factor monoclonal antibody for the therapy of solid tumors and other disorders. *Cancer Res* 57:4593–4599, 1997
  135. Dawson DW, Volpert OV, Gillis P, Crawford SE, Xu H, Benedict W, Bouck NP: Pigment epithelium-derived factor: a potent inhibitor of angiogenesis. *Science* 285:245–248, 1999
  136. Stellmach V, Crawford SE, Zhou W, Bouck N: Prevention of ischemia-induced retinopathy by the natural ocular antiangiogenic agent pigment epithelium-derived factor. *Proc Natl Acad Sci USA* 98:2593–2597, 2001
  137. Mallet B, Vialettes B, Haroche S, Escoffier P, Gastaut P, Taubert JP, Vague P: Stabilization of severe proliferative diabetic retinopathy by long-term treatment with SMS 201–995. *Diabetes Metab* 8:438–444, 1992
  138. Grant MB, Mames RN, Fitzgerald C, Hazariwala KM, Cooper-DeHoff R, Caballero S, Estes KS: The efficacy of ocreotide in the therapy of severe nonproliferative and early proliferative diabetic retinopathy. *Diabetes Care* 23: 504–509, 2000
  139. McCombe M, Lightman S, Eckland DJ, Hamilton AM, Lightman SL: Effect of a long-acting somatostatin analogue (BIM23014) on proliferative diabetic retinopathy: a pilot study. *Eye* 5:569–575, 1991
  140. Jousseaume AM, Poulaki V, Mitsiades N, Kirchhof B, Koizumi K, Dohmen S, Adamis AP: Nonsteroidal anti-inflammatory drugs prevent early diabetic retinopathy via TNF-alpha suppression. *FASEB J* 16: 438–440, 2002
  141. The DAMAD Study Group: Effect of aspirin alone and aspirin plus dipyridamole in early diabetic retinopathy: a multicenter randomized controlled clinical trial. *Diabetes* 38:491–498, 1989
  142. Early Treatment Diabetic Retinopathy Study Research Group: Effects of aspirin treatment on diabetic retinopathy: ETDRS report number 8. *Ophthalmology* 98 (Suppl.):757–765, 1991
  143. UK Prospective Diabetes Study Group: Efficacy of atenolol and captopril in reducing risk of macrovascular and microvascular complications in type 2 diabetes: UKPDS 39. *Br Med J* 317:713–772, 1998
  144. Moravski CJ, Kelly DJ, Cooper ME, Gilbert RE, Bertram JF, Shahinfar S, Skinner SL, Wilkinson-Berka JL: Retinal neovascularization is prevented by blockade of the renin-angiotensin system. *Hypertension* 36:1099–1104, 2000
  145. Gilbert RE, Kelly DJ, Cox AJ, Wilkinson-Berka JL, Rumble JR, Osicka T, Panagiotopoulos S, Lee V, Hendrich EC, Jerums G, Cooper ME: Angiotensin converting enzyme inhibition reduces retinal overexpression of vascular endothelial growth factor and hyperpermeability in experimental diabetes. *Diabetologia* 43:1360–1367, 2000
  146. Nagisa Y, Shintani A, Nakagawa S: The angiotensin II receptor antagonist candesartan cilaxetil (TCV-116) ameliorates retinal disorders in rats. *Diabetologia* 44: 883–888, 2001