

Is One 60° Fundus Photograph Sufficient for Screening of Proliferative Diabetic Retinopathy?

FLEMMING MØLLER, PHD¹
MERETE HANSEN, MD¹
ANNE KATRIN SJØLIE, DSCI¹

OBJECTIVE — To compare one 60° fundus photograph to seven field stereo fundus photographs in identifying proliferative diabetic retinopathy.

RESEARCH DESIGN AND METHODS — A total of 44 eyes in 23 patients with moderate/severe nonproliferative diabetic retinopathy were included. Evaluation of each eye was based on one 60° fundus photograph. Eyes were re-examined using seven field 30° stereo fundus photographs according to the protocol of the Early Treatment Diabetic Retinopathy Study, and the photographs were examined independently by three ophthalmologists to identify retinal neovascular lesions. In addition, fluorescein angiography was performed in all patients to verify the presence of the lesions.

RESULTS — In four eyes of three patients (11.1% of eyes) evaluated based on seven field stereo photographs, retinal neovascularization was found. This condition was not found on examination of 60° fundus photographs.

CONCLUSIONS — Examination of one 60° fundus photograph was found to be insufficient as a screening procedure in patients with moderate/severe nonproliferative diabetic retinopathy.

Diabetes Care 24:2083–2085, 2002

The incidence of type 1 and type 2 diabetes is increasing (1–3), and because diabetic retinopathy is already a leading cause of blindness in the Western world (4), cost-effective screening programs for diabetic retinopathy may become even more important in the near future. Screening for diabetic retinopathy is essential because the Early Treatment Diabetic Retinopathy Study (ETDRS) has shown that the risk of severe visual loss may be reduced by 50–90% when retinal photocoagulation is applied for patients with high-risk proliferative retinopathy and/or clinically significant macular edema (5). In the ETDRS, assessment of diabetic retinopathy was based on seven

field 30° stereo fundus photographs, a procedure that may be unpleasant for the patient as well as time consuming and expensive for the community and therefore not ideal for large-scale screening programs.

In the present study, one 60° fundus photograph centered on the macula was compared with seven field 30° stereo fundus photographs in 23 patients with moderate/severe nonproliferative retinopathy, as determined by assessment of 60° fundus photographs. The purpose was to estimate the sensitivity of one 60° fundus photograph for finding retinal neovascularization in patients at high risk for developing sight-threatening retinopathy.

RESEARCH DESIGN AND METHODS

Patients were recruited from the photographic screening clinic at the Department of Ophthalmology, Odense University Hospital, during a 6-month period. In each patient, retinopathy was assessed using one 60° photograph taken with a Canon CF-60 fundus camera (Canon, Amstelveen, the Netherlands) using Kodak Ektachrom 64 ASA film (Eastman Kodak, Rochester, NY). The disease was graded into five levels (no retinopathy, mild nonproliferative, moderate nonproliferative, severe nonproliferative, and proliferative) according to the EURODIAB protocol (6) by two senior consultants (A.K.S. and M.H.). In case of disagreement in grading, photographs were re-evaluated by the two consultants in plenum to obtain consensus. A total of 44 eyes in 23 patients with moderate/severe diabetic retinopathy were included (8 women and 15 men; 10 patients with type 2 diabetes and 13 patients with type 1 diabetes). The mean age of the patients was 54.4 years (range 25–75), and the duration of diabetes ranged from 8 to 39 years. Moderate/severe nonproliferative retinopathy was defined as present when the following retinal lesions were identified: multiple intraretinal hemorrhages and/or multiple hard exudates and/or multiple cotton wool spots and/or intra retinal microvascular abnormalities. For each of these patients, seven field 30° stereo fundus photographs were performed according to the ETDRS protocol (Fig. 1) using a Topcon FD-31 (Topcon, Hoersholm, Denmark) fundus camera with Kodak Ektachrom 64 ASA film (Eastman Kodak). Finally, fluorescein angiography was performed in all patients. A total of 5 ml of 10% fluorescein was injected into an antecubital vein, and photographs were taken during the filling phase as well as 5 min after the injection.

Presence or absence of retinal neovascularization on the seven field stereo fundus photographs was evaluated independently by three experienced ophthalmologists. The results from each

From the ¹Department of Ophthalmology, Odense University Hospital, DK-5000 C, Odense, Denmark.

Address correspondence and reprint requests to F. Møller, Department of Ophthalmology, Odense University Hospital, Sdr. Boulevard, DK 5000 C, Odense, Denmark. E-mail: f.moeller@dadlnet.dk.

Received for publication 26 April 2001 and accepted in revised form 30 July 2001.

Abbreviations: ETDRS, Early Treatment Diabetic Retinopathy Study.

A table elsewhere in this issue shows conventional and Système International (SI) units and conversion factors for many substances.

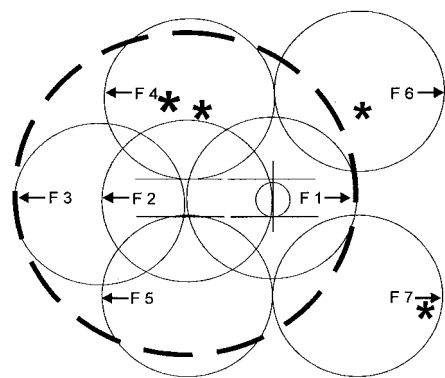


Figure 1—Seven standard fields (F1–F7) of the ETDRS protocol (shown for right eye) superimposed on one 60° fundus photograph (broken circle) centered on the macula. An asterisk indicates the location of each area of neovascularization missed on the 60° photograph.

investigator were compared, and if there was disagreement between investigators, the fluorescein angiogram was used to determine whether retinal neovascularization was present (profuse fluorescein leakage on late-phase angiogram indicates retinal neovascularization). All fluorescein angiograms were finally evaluated by the investigators in plenum to determine whether any retinal neovascularization had been missed on the seven field stereo fundus photographs.

RESULTS— Four patients were excluded due to lack of assessable fields or focusing of photographs. In the remaining 19 patients (8 women and 11 men), 36 eyes were evaluated. In four eyes of three patients (corresponding 11.1%, 95% CI 3.1–26.2%), retinal neovascularization was found by all reviewers on seven field fundus stereo photographs that were not identified on the 60° fundus photographs. This result corresponds with a sensitivity of 88.9% correct assessment of nonproliferative retinopathy when using one 60° photograph. Figure 1 shows the localization of the neovascularization in the four eyes with reference to the ETDRS seven field standard photographs and the 60° photograph. Fluorescein angiography confirmed the presence of retinal neovascularization in these four eyes, whereas no retinal neovascular lesions were identified in the remaining 32 eyes.

CONCLUSIONS— Evaluation of fundus photographs by trained health

professionals has been proven, overall, to be a more sensitive method for grading the severity of diabetic retinopathy when compared with ophthalmoscopy (7–9), which is an examination that depends highly on the skills of the examiner (6). However, grading of diabetic retinopathy from fundus photographs has limitations, because only part of the retina is evaluated due to technical limitation of the fundus cameras. In the ETDRS study, 75–65% of the central retina was covered using seven field 30° stereo fundus photographs. The advantage of this standard is the large area of the retina visualized in stereo at high magnification. The disadvantage of the method is the number of fundus photographs (14 photographs of each eye), which are technically difficult and time-consuming to obtain and may be uncomfortable for some patients. Furthermore, evaluation of seven field photographs is time-consuming and costly. Therefore, other photographic strategies have been used for large-scale screening programs (10), and in the present study, we compared the sensitivity of one 60° fundus photograph centered on the macula with that of seven field 30° stereo photographs in identifying retinal neovascularization.

In four eyes, comprising 11.1% of the total number of eyes, we found retinal neovascularization that was not identified on the 60° photograph. Two of the retinal neovascular lesions were found in field number 4 and, therefore, were expected to be present on the 60° photograph (Fig. 1). However, the lesions were not primarily identified, illustrating the limitations of wide-angle photographs in losing details due to lower magnification. The last two retinal neovascular lesions were found in field numbers 6 and 7. The retinal neovascularization in field number 6 would have been covered by a 60° photograph centered on the disk, whereas the retinal neovascularization in field number 7 was localized in the periphery of this field and, therefore, would only be covered using seven field photographs.

Several studies have evaluated alternative photographic strategies to seven field photographs for evaluating diabetic retinopathy. Retinal imaging through a nondilated pupil using either one or three 45° photographs provides a sensitivity of 61% (11) and 57–87% (6,12) correct assessment of nonproliferative diabetic retinopathy, respectively, when compared with seven field photographs. This sensitivity

may be increased to 81–86.5% when retinal photographs of equal number and angular width are taken through a dilated pupil (11,13). Moss et al. (14) determined the sensitivity in finding severe nonproliferative retinopathy using two field 30° photographs to be 81 and 91% for four fields when compared with seven field 30° fundus photographs. These results are in accordance with our data, confirming that the procedure with seven field photographs is superior. However, as previously mentioned, this standard is not ideal for large-scale screening programs due to the large amount of photographs. Therefore, each screening clinic must decide to either use a limited number of low-angle, high-magnification photographs, giving a high sensitivity in finding all retinal lesions in a limited area, or to use one or two wide-angle, low-magnification photographs covering larger retinal areas but with a lower sensitivity in finding all retinal lesions. Due to these limitations in photographic screening procedures, an additional clinical evaluation should be considered for patients with moderate or severe nonproliferative diabetic retinopathy.

In conclusion, 11.1% of our patients with moderate/severe nonproliferative diabetic retinopathy evaluated based on one 60° fundus photograph had retinal neovascularization when evaluated based on seven field 30° stereo fundus photographs. Consequently, one 60° fundus photograph is insufficient as a screening procedure in patients with moderate/severe nonproliferative diabetic retinopathy.

Acknowledgments— We thank photographer Norman Nielsen for his skillful assistance in performing the seven field stereo photographs.

References

1. Amos AF, McCarty DJ, Zimmet P: The rising global burden of diabetes and its complications: estimates and projections to year 2010. *Diabetes Med* 14 (Suppl. 5):1–85, 1997
2. Green A, Andersen PK, Svendsen AJ, Mortensen K: Increasing incidence of early onset type 1 (insulin dependent) diabetes mellitus: a study of Danish male birth cohorts. *Diabetologia* 35:178–182, 1992
3. Green A, Sjølie AK, Eshøj O: Trends in the epidemiology of IDDM during 1970–2020 in Fyn County, Denmark. *Diabetes*

- Care 19:801–806, 1996
4. Klein R: Recent developments in the understanding of diabetic retinopathy. *Med Clin North Am* 72:1415–1433, 1988
 5. Early Treatment of Diabetic Retinopathy Study Group: Early photocoagulation for diabetic retinopathy, ETTRS report number 9. *Ophthalmology* 98:766–785, 1991
 6. Hutchinson A, McIntosh A, Peters J, O'Keefe C, Khunti K, Baker R, Booth A: Effectiveness of screening and monitoring test for diabetic retinopathy: a systematic review. *Diabet Med* 17:495–506, 2000
 7. Moss SE, Klein R, Kessler SD, Richie KA: Comparison between ophthalmoscopy and fundus photography in determining severity of diabetic retinopathy. *Ophthalmology* 92:62–67, 1985
 8. Kinyoun JL, Martin DC, Fujimoto WY, Leonetti DL: Ophthalmoscopy versus fundus photographs for detecting and grading diabetic retinopathy. *Invest Ophthalmol Vis Sci* 33:1888–1893, 1992
 9. Harding SP, Broadbent DM, Neoh C, White MC, Vora J: Sensitivity and specificity of photography and direct ophthalmoscopy in screening for sight threatening eye disease: the Liverpool Diabetic Eye Study. *BMJ* 28:1131–1135, 1992
 10. Aldington SJ, Kohner EM, Meuer S, Klein R, Sjølie AK: Methodology for retinal photography and assessment of diabetic retinopathy: the EURODIAB IDDM complications study. *Diabetologia* 38:437–444, 1995
 11. Pugh JA, Jacobson JM, Van Heuven WAJ, Watters JA, Tuley MR, Lairson DR, Lormor RJ, Kapadia AS, Velez R: Screening for diabetic retinopathy: the wide-angle retinal camera. *Diabetes Care* 16:889–895, 1993
 12. Newsom R, Moate B, Casswell T: Screening for diabetic retinopathy using digital colour photography and oral fluorescein angiography. *Eye* 14:579–582, 2000
 13. Klein R, Klein BE, Neider MW, Hubbard LD, Meuer SM, Brothers RJ: Diabetic retinopathy as detected using ophthalmoscopy, a nonmydriatic camera and a standard fundus camera. *Ophthalmology* 92:485–491, 1985
 14. Moss SE, Meuer SM, Klein R, Hubbard LD, Brothers RJ, Klein BE: Are seven standard photographic fields necessary for classification of diabetic retinopathy? *Invest Ophthalmol Vis Sci* 30:823–828, 1989