

Macular Edema Reflects Generalized Vascular Hyperpermeability in Type 2 Diabetic Patients With Retinopathy

SØREN T. KNUDSEN, MD, PHD¹
TOKE BEK, MD, DMSC²
PER L. POULSEN, MD, PHD¹

MARIANNE N. HOVE, MD²
MICHAEL REHLING, MD, DMSC³
CARL E. MOGENSEN, MD, DMSC¹

OBJECTIVE — Diabetic maculopathy (DMa) is the most prevalent sight-threatening type of retinopathy in type 2 diabetes and a leading cause of visual loss in the western world. The disease is characterized by hyperpermeability of retinal blood vessels and subsequent formation of hard exudates and macular edema, the degree of which can be estimated by measurement of retinal thickness. We examined associations between retinal thickness as evaluated by optical coherence tomography scanning (OCT), glomerular leakage as evaluated by urinary albumin excretion rate (UAE), and general vascular leakage as evaluated by the transcapillary escape rate of albumin (TER_{alb}) in type 2 diabetic patients with and without DMa.

RESEARCH DESIGN AND METHODS — In 20 type 2 diabetic patients with DMa and 20 type 2 diabetic patients without retinopathy matched for age, sex, and duration of diabetes, we performed OCT, fundus photography, fluorescein angiography, and 24-h ambulatory blood pressure measurement. UAE was determined by radioimmunoassay. TER_{alb} was determined as the initial disappearance of intravenously injected ¹²⁵I-labeled human serum albumin.

RESULTS — Patients with diabetic maculopathy had higher HbA_{1c} (8.5 ± 1.5 vs. $7.4 \pm 1.2\%$, $P < 0.05$) and higher total cholesterol (5.8 ± 0.7 vs. 5.2 ± 0.9 mmol/l, $P < 0.05$) than patients without retinopathy. UAE was higher in the DMa group than in the group with no retinopathy ($9.3 \times / \div 3.1$ vs. $3.9 \times / \div 1.9$ $\mu\text{g}/\text{min}$, $P < 0.01$). There was no difference in TER_{alb} between the two groups (6.0 ± 1.6 vs. $6.6 \pm 1.5\%$, NS). In the group with DMa, OCT, TER_{alb}, and UAE correlated significantly (OCT versus TER_{alb}: $r = 0.55$, $P < 0.05$; OCT versus UAE: $r = 0.58$, $P < 0.01$; UAE versus TER_{alb}: $r = 0.81$, $P < 0.01$). Conversely, there were no correlations between these three parameters in the group without retinopathy.

CONCLUSIONS — Macular edema seems to reflect a generalized vascular leakage in type 2 diabetic patients.

Diabetes Care 25:2328–2334, 2002

Diabetic retinopathy remains a leading cause of vision loss in the western world (1). Diabetic maculopathy (DMa) is the most prevalent sight-threatening manifestation of retinopathy in type 2 diabetes (2). Therefore, this type of retinopathy is

anticipated to predominate in the future, as the number of type 2 diabetic patients escalates (3). DMa is characterized by a variety of morphological changes in the retina, including hemorrhages, cotton wool spots, exudates, and edema. The pathogenic mecha-

nisms initiating this eye disease are unknown, but lesions such as hard exudates and edema can be ascribed to a pathologically increased permeability of retinal blood vessels.

Retinal edema is considered the most important indicator of retinal damage leading to visual impairment. Hitherto, quantitative assessment of retinal edema has been difficult. However, with the advent of the new diagnostic modality, optical coherence tomography scanning (OCT) (4), measurement of retinal thickness, and thereby quantification of retinal edema, has become feasible. Several studies have introduced OCT for evaluation of diabetic retinopathy (5,6).

Whether the vascular hyperpermeability leading to macular edema is an isolated retinal phenomenon or an ocular manifestation of a generalized vascular hyperpermeability is currently unknown. Therefore, the purpose of our study was to evaluate the association between the degree of macular edema, as assessed by OCT, and two measures of vascular permeability in the systemic circulation, namely urinary albumin excretion (UAE) rate and transcapillary escape rate of albumin (TER_{alb}) (7) in type 2 diabetic patients with and without DMa. Furthermore, study patients were characterized with regard to glycemic control (8), blood lipid levels (9), ambulatory blood pressure (AMBP) (10), and autonomic neuropathy (11).

RESEARCH DESIGN AND METHODS

Patients

Case group. A total of 20 type 2 diabetic patients with DMa, defined as retinal hemorrhages and/or microaneurysms combined with hard exudates and/or retinal edema in the macular area, were identified in the database of eye examinations in our screening clinic for diabetic retinopathy. For each patient in the case group, we defined the study eye as the eye with the most severe degree of retinopathy. **Control group.** A total of 20 type 2 diabetic patients with no signs of retinopathy

From the ¹Medical Department M (Diabetes & Endocrinology), Aarhus Kommunehospital, Aarhus, Denmark; the ²Department of Ophthalmology, Aarhus Kommunehospital, Aarhus, Denmark; and the ³Department of Clinical Physiology and Nuclear Medicine, Aarhus Kommunehospital, Aarhus, Denmark.

Address correspondence and reprint requests to Søren Tang Knudsen, Medical Department M (Diabetes & Endocrinology), Aarhus Kommunehospital, DK-8000 Aarhus C, Denmark. E-mail: stk@dadlnet.dk.

Received for publication 30 January 2002 and accepted in revised form 23 August 2002.

Abbreviations: AMBP, 24-h ambulatory blood pressure; BP, blood pressure; DMa, diabetic maculopathy; OCT, optical coherence tomography scanning; TER_{alb}, transcapillary escape rate of albumin; UAE, urinary albumin excretion.

A table elsewhere in this issue shows conventional and Système International (SI) units and conversion factors for many substances.

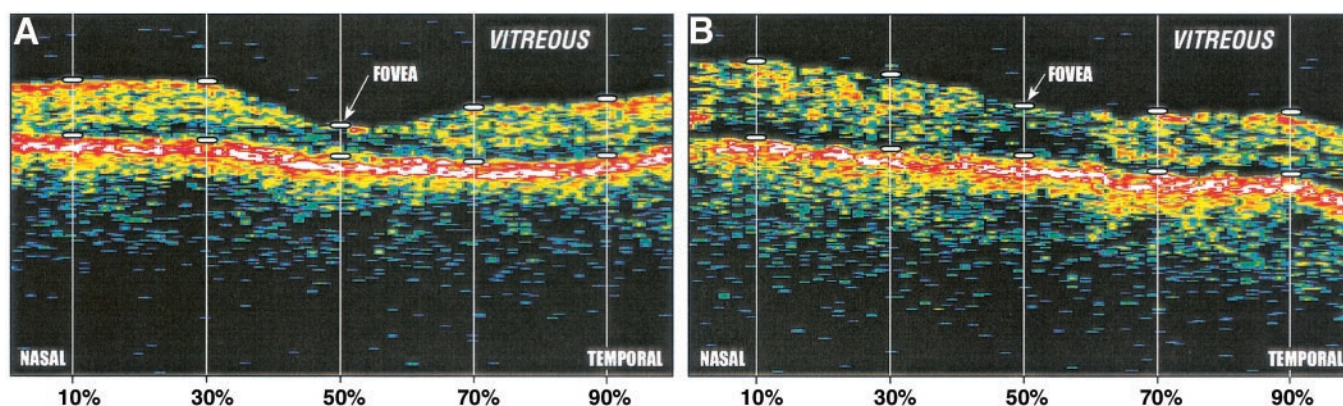


Figure 1—Horizontal OCT scans (length 2.83 mm) through the fovea from two different type 2 diabetic patients. Points used for measurements of retinal thickness are indicated by white, horizontal bars. A: OCT scan of a patient with no diabetic retinopathy. B: OCT scan of a patient with macular edema. Note the diffuse thickening of the retina and the disappearance of the foveal depression.

were identified in the above-mentioned database. For each patient in the DMA group, we identified and ranked the 10 patients in the database with no retinopathy that matched best with regard to age, sex, and known duration of diabetes. The patients were invited to participate in the study according to rank. For each control patient, we included the eye corresponding to the study eye of the matching case.

Patients were considered to have type 2 diabetes if they had onset of diabetes after age 30 years, had no need for insulin treatment for at least 1 year after the diagnosis of diabetes, and had no history of ketoacidosis. Because ACE inhibitors are known to affect UAE and have been suggested to affect TER_{alb} (12) and retinal vascular permeability (13), patients treated with ACE inhibitors or angiotensin II receptor antagonists were not included. Likewise, patients previously treated with laser photocoagulation were not included.

Leisure time physical activity was graded as follows: passive (not participants), moderate (physical exercise once or twice a week), and active (physical exercise more than twice a week). Patients were classified as nonsmokers (without daily use of tobacco for the preceding year), moderate smokers (<15 cigarettes per day), or heavy smokers (>15 cigarettes per day). Patients were classified as having macrovascular disease if one or more of the following were present: symptoms of angina pectoris; history of myocardial infarction, coronary artery bypass grafting, or percutaneous transluminal coronary angioplasty; symptoms of or operation for intermittent claudication;

or history of amputation, transient ischemic attack, or stroke. All subjects included in the study were Caucasian.

Eye examinations

The patients underwent routine ophthalmological examinations for diabetic retinopathy, including measurement of visual acuity, slit-lamp examination, fundus photography, fluorescein angiography, as well as OCT of the central retina. **Retinal photography.** Fundus photography was performed using a Canon 60UV fundus camera on Kodak Ektachrome 64 color diapositive film. In each eye, one 60° image centered on the fovea and a nasally displaced field centered on the optic disk were taken. Fluorescein angiography was performed using Ilford Delta 400 black/white film. A fast sequence was taken during the filling phase of the retinal vessels of the study eye, and late-phase images were taken of both eyes 5–10 min after injection of fluorescein. The fluorescein angiograms verified that all maculopathies were of an exudative type.

OCT. The OCT method is analogous to ultrasound B-scanning, in that distance information is extracted from the time delays of reflected signals. Optical (laser) instead of acoustic waves are used in OCT, which allows a much higher resolution (10 μm) and thereby a more precise assessment of retinal thickness (14). Therefore, this method is very sensitive and, in addition, noninvasive. In this study, we used the Humphrey optical coherence tomography scanner (version A4.1; Humphrey Instruments, San Leandro, CA). Six

radial scans centered on the fixation point were performed with a 30° interval (Fig. 1). Each scan had a length of 2.83 mm, and the sequence of scanning was the same for all patients, as performed using the default settings of the scanner.

Analysis of OCT scans was performed by an ophthalmologist who had not participated in the examination of study patients. Therefore, this ophthalmologist had no knowledge of the patients' clinical or laboratory data and did not know whether individual patients were case or control subjects. The scans were displayed on the OCT monitor, and the distance from the retinal surface to the zone with highest reflectivity at the choriocapillaris/pigment epithelium was measured with a ruler. The measured distances on the monitor were converted to distances on the retinal plane using the standard calibration of the OCT apparatus. For each scan, five thickness measurements were obtained, at points 10, 30, 50, 70, and 90% of the length of the scan from its beginning (Fig. 1) (15,16). The average thickness of a scan was calculated as the mean of the five measured thicknesses, and the average retinal thickness in the macular area was then calculated as the mean thickness of the six scans. One patient in the control group had no identifiable high reflectivity zone at the choriocapillaris/pigment epithelium, and for this reason, we were not able to measure retinal thickness in this patient. The OCT scans of this patient were excluded, leaving 20 sets of OCT scans in the case group and 19 sets in the control group for analysis.

Table 1—Clinical characteristics, retinal thickness, UAE, TER_{alb}, and AMBP values of type 2 diabetic patients without retinopathy or DMA

| | Type 2 diabetic patients without retinopathy (n = 20) | Type 2 diabetic patients with DMA (n = 20) | P |
|--|--|---|-------|
| Sex (% male) | 60 | 60 | NR |
| Age (years) | 61.9 ± 6.4 | 60.9 ± 6.7 | NR |
| Known duration of diabetes (years) | 10.0 ± 7.0 | 9.2 ± 7.3 | NR |
| Treatment (diet/oral hypoglycemic agent/insulin) (%) | 30/35/35 | 20/55/25 | NS |
| Antihypertensive treatment (%) | 30 | 50 | NS |
| Macrovascular disease (%) | 20 | 20 | NS |
| Smoking status (nonsmoking/moderate/heavy) (%) | 70/10/20 | 70/15/15 | NS |
| Physical activity (not active/moderate/active) (%) | 45/10/45 | 80/20/0 | <0.01 |
| BMI (kg/m ²) | 30.3 ± 5.8 | 29.0 ± 5.1 | NS |
| HbA _{1c} (%) | 7.4 ± 1.2 | 8.5 ± 1.5 | <0.05 |
| Fasting blood glucose (mmol/l) | 8.1 ± 2.9 | 9.4 ± 3.2 | NS |
| Plasma total cholesterol (mmol/l) | 5.2 ± 0.9 | 5.8 ± 0.7 | <0.05 |
| Serum creatinine (μmol/l) | 77.6 ± 10.7 | 84.3 ± 23.1 | NS |
| Average retinal thickness (μm) | 227 ± 13 | 247 ± 29 | <0.01 |
| Urinary albumin excretion rate (μg/min) | 3.9 ×/÷ 1.9 | 9.3 ×/÷ 3.1 | <0.01 |
| Transcapillary escape rate of albumin (%) | 6.6 ± 1.5 | 6.0 ± 1.6 | NS |
| 24-h systolic AMBP (mmHg) | 132 ± 17 | 137 ± 14 | NS |
| 24-h diastolic AMBP (mmHg) | 77 ± 10 | 79 ± 8 | NS |

Data are means ± SD except UAE, which are geometric means ×/÷ tolerance factor. NR, not relevant; NS, not significant.

TER_{alb}

In the first 15 patients included in each group, we measured the TER_{alb} as described by Parving et al. (17,18). We were unable to perform this examination in the last five patients in each group because of a sudden withdrawal of ¹²⁵I-labeled albumin from the market.

The examination was performed in the morning after an overnight fast. After resting for 1 h in the supine position, the patient received an intravenous bolus injection containing 0.2 MBq ¹²⁵I-labeled human albumin (HSA for metabolic studies, IsoPharma IT.235). Blood samples were collected from a cubital vein in the other arm before and 10, 15, 20, 30, 40, 50, 55, and 60 min after the injection for counting of plasma radioactivity and measurement of total plasma protein concentration in duplicate by refractometry (Bellingham & Stanley, Tunbridge Wells, U.K.). Radioactivity was corrected for total plasma protein concentration, and the slope of the linear regression of radioactivity on time was used to calculate TER_{alb} (i.e., the plasma tracer disappearance rate). TER_{alb} measurements were accepted only if the correlation coefficient between the time points for blood collection and the corresponding values of a specific radioactivity exceeded 0.85. On the basis of this criterium, two TER_{alb} examinations (one case subject and one

control subject) were excluded from the analyses.

24-h blood pressure measurements

AMBP was measured using an oscillometric technique (Spacelabs 90207, validated by the British Hypertension Society) (19). Readings were obtained at 20-min intervals over 24 h. Individually reported sleeping times were implemented in the calculation of day and night blood pressure (BP).

Autonomic function tests

Three bedside cardiovascular reflex tests were performed: heart rate variation to deep breathing (inspiration/expiration difference, average of two determinations), heart rate response to standing up (30:15 ratio), and blood pressure response to standing up. These tests were performed and evaluated as described by Ewing et al. (20).

Biochemical analyses

UAE was measured by radioimmunoassay and expressed as the geometric mean of three overnight collections made within 1 week. HbA_{1c} was determined by high-performance liquid chromatography (nondiabetic range 4.4–6.4%). Blood glucose was determined using the Reflolux II (Boehringer Mannheim, Mannheim, Germany).

All subjects included in the study gave their written informed consent to participate. The study was approved by the regional ethics committee.

Statistical analysis

To approximate normal distribution, UAE measurements were log-transformed before analysis. Differences between groups were tested by the unpaired Student's *t* test. For noncontinuous variables, the χ^2 test with Yates' correction was used. Correlations were analyzed using Pearson's test. A two-tailed *P* value <0.05 was considered significant. Results for normally distributed variables are expressed as mean ± SD, whereas UAE values are expressed as geometric mean ×/÷ tolerance factor.

RESULTS— Clinical characteristics, retinal thicknesses, UAE, TER_{alb}, and AMBP values of the patients are shown in Table 1.

The groups were well matched with regard to age, sex, and known duration of diabetes. The median pairwise difference was 1.4 years for age and 1.2 years for duration of diabetes. Values of HbA_{1c} and total cholesterol were significantly higher in the patients with DMA than in the patients without retinopathy. Interestingly, the level of physical activity was higher in the control group than in the case group,

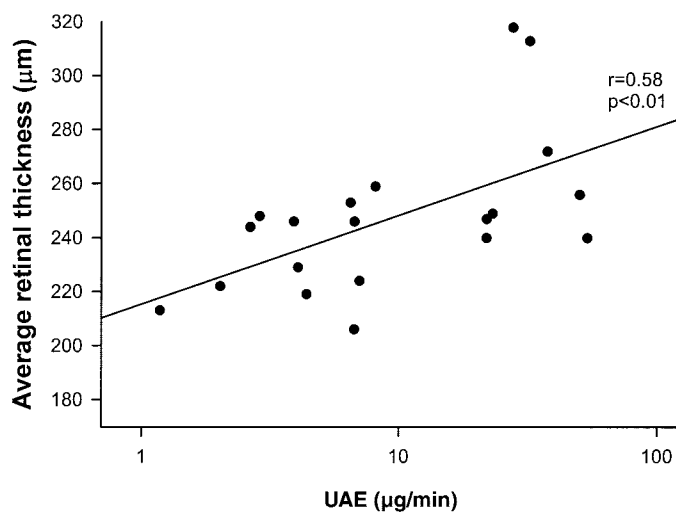


Figure 2—UAE versus average retinal thickness as measured by OCT in type 2 diabetic patients with DMA.

whereas there were no differences in use of antidiabetic medication, prevalence of macrovascular disease, smoking habits, BMI, or serum creatinine level between the groups. The cardiovascular reflex tests revealed no statistically significant differences in autonomic function between the groups (data not shown).

Average UAE and retinal thickness, as measured by OCT, were higher in the group with DMA than in the control group. There was no significant difference in TER_{alb} between the groups. AMBP values, pulse pressures, and night/day ratios were uniformly higher in the case group than in the control group, although the differences between groups did not reach the level of statistical significance (all data not shown). Because more case subjects than control subjects received antihypertensive treatment, true differences in BP between the groups might have been missed. Restricting the analysis to the subgroup of patients not receiving antihypertensive treatment (10 case subjects, 14 control subjects), BP values were still uniformly higher in the case group than in the control group, but the differences were numerically larger, reaching statistical significance for night systolic BP (131 ± 14 vs. 117 ± 14 mmHg, $P < 0.05$) and night pulse pressure (60 ± 9 vs. 49 ± 9 mmHg, $P < 0.01$).

In the total group of patients ($n = 40$), retinal thickness (OCT), UAE, and TER_{alb} showed a significant correlation (OCT versus UAE: $r = 0.56$, $P < 0.01$; OCT versus TER_{alb} : $r = 0.36$, $P = 0.069$; UAE

versus TER_{alb} : $r = 0.38$, $P < 0.05$). In a subgroup analysis, there was a strong correlation between OCT, UAE, and TER_{alb} in the group with DMA (Figs. 2–4) (OCT versus UAE: $r = 0.58$, $P < 0.01$; OCT versus TER_{alb} : $r = 0.55$, $P < 0.05$; UAE versus TER_{alb} : $r = 0.81$, $P < 0.01$), whereas there were no correlations between these three parameters in the group without retinopathy (OCT versus UAE: $r = 0.04$, $P = 0.86$; OCT versus TER_{alb} : $r = 0.37$, $P = 0.22$; UAE versus TER_{alb} : $r = 0.14$, $P = 0.63$).

CONCLUSIONS— Our study is the first to examine associations between retinal thickness as assessed by OCT and

measures of glomerular and vascular permeability in diabetes. In type 2 diabetic patients with DMA, we found significant correlations between retinal thickness, UAE, and TER_{alb} , whereas no such association was seen in type 2 diabetic patients without retinopathy. Increased retinal thickness has previously been shown to coincide with increased leakage of retinal blood vessels in type 2 diabetes (21). Therefore, our findings indicate that in type 2 diabetic patients with DMA, the pathologically increased permeability of the retinal vessels, as reflected by increased retinal thickness, corresponds to equivalent permeability changes in kidney capillaries and in small vessels throughout the circulation of the diabetic patient.

A decade ago, the hypothesis of albuminuria as a marker of widespread endothelial damage was introduced (22). Several studies have established a relationship between abnormal UAE and increased TER_{alb} (23–25). Because retinopathy and nephropathy are often coexisting in diabetes, it has been difficult to establish an independent association between the presence of retinopathy and increased TER_{alb} (24,25). In the present study, we were not able to demonstrate differences in TER_{alb} between the groups with and without retinopathy. This could be because the included cases had varying degrees of DMA, ranging from a single hard exudate to macular edema. However, when considering the varying degree of macular edema, as evaluated by OCT measurements of retinal thickness,

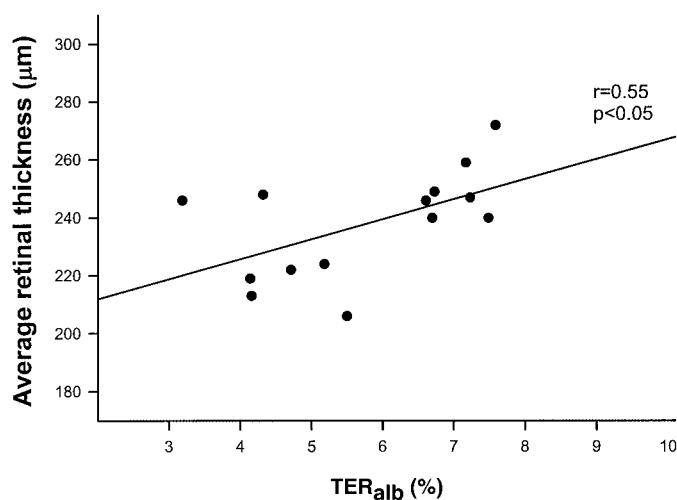


Figure 3— TER_{alb} versus average retinal thickness as measured by OCT in type 2 diabetic patients with DMA.

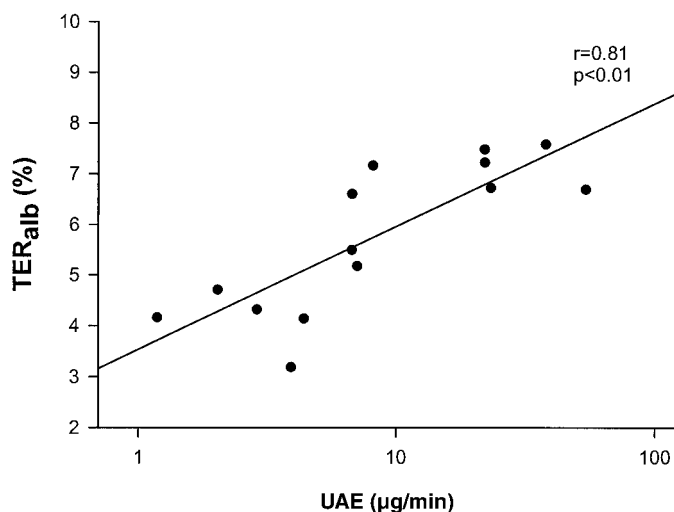


Figure 4—UAE versus TER_{alb} in type 2 diabetic patients with DMA.

we found a significant association between retinal thickening and TER_{alb} .

Several studies have established a statistical association between retinopathy and nephropathy in type 1 diabetes (26) as well as in type 2 diabetes (27), and these complications were also strongly correlated in the present study. Both DMA and diabetic nephropathy are characterized by a pathologically increased permeability of a vascular barrier. In DMA, leakage of lipoproteins and water from the retinal vessels results in formation of hard exudates and macular edema, whereas increased permeability of glomerular capillaries in diabetic nephropathy leads to an increased UAE. Hemodynamic as well as structural abnormalities are believed to initiate these changes. It is well known that systemic hypertension is a risk factor for development of both retinopathy and nephropathy in diabetes (28,29), conceivably because elevated blood pressure is transmitted to the microcirculation, thus resulting in capillary/glomerular hyperperfusion and hypertension (30–32). Because the retinal vessels have no autonomic innervation, blood flow in response to increased blood pressure is dependent on local factors, e.g., autoregulation. As the autoregulatory capacity of the retinal circulation is impaired when blood glucose is elevated (33), simultaneous hypertension and hyperglycemia is anticipated to be particularly detrimental for the microvasculature.

In accordance with this hypothesis, our patients without retinopathy had significantly better glycemic control and also

tended to have lower blood pressure than patients with DMA. These findings are in line with results from the U.K. Prospective Diabetes Study, in which poor glycemic control and elevated blood pressure have been pointed out as major risk factors for development of diabetic complications (34). We have recently shown that increased pulse pressure is associated with a higher frequency of complications in type 2 diabetic patients (35). Furthermore, lowering of blood pressure and glycemia has been proven to slow the development and progression of microvascular complications in diabetes (36–40).

In several studies, treatment with ACE inhibitors has been proposed to provide specific organ-protective effects beyond what would be expected from the relatively modest reductions in BP achieved in these studies (38,41,42). A study in type 2 diabetic patients with nephropathy comparing 12 months of treatment with either lisinopril or atenolol showed a reduction in albuminuria and TER_{alb} in patients treated with ACE inhibitors, whereas this was not seen in the patients treated with atenolol, even though reduction in BP was similar in the two groups (12). This finding indicates that ACE inhibitors have direct effects on the microvasculature, thus reestablishing the barrier function of the leaky capillaries in diabetes. This theory is supported by the fact that retinal blood vessels have receptors for angiotensin II (43) and that ACE inhibition reduces the permeability of these vessels (13,44). Our patients with

DMA seemed to have a systemic microvascular hyperpermeability, the degree of which was reflected by retinal thickness. Because treatment with ACE inhibitors is known to have beneficial effects on UAE and TER_{alb} , treatment with ACE inhibitors or angiotensin II receptor antagonists could be a promising treatment modality for this group of patients. OCT might then be the instrument of choice to evaluate the efficacy of such intervention in reducing macular edema.

In conclusion, our data show that retinal thickness in the macular area is associated with a glomerular and generalized vascular leakage in type 2 diabetic patients with DMA. Therefore, hyperpermeability of blood vessels seems to coexist in different organs in diabetic patients, and this pathological feature might represent a common target for medical intervention. Quantitative assessment of retinal thickness, e.g., by OCT, may become a useful instrument in evaluating such intervention effects in DMA.

Acknowledgments—Financial support for this study was received from the Sehested Hansen Foundation, the Novo Nordisk Foundation, the Beckett Foundation, the Jochum Jensen Memorial Grant, and the Illum Foundation.

We thank Theis Bacher, Merete Møller, Hanne Petersen, Lisbet Vester, and Helle Hedegaard for their excellent technical assistance.

References

1. Aiello LP, Gardner TW, King GL, Blankenship G, Cavallerano JD, Ferris FL, Klein R: Diabetic retinopathy. *Diabetes Care* 21:143–156, 1998
2. Klein R, Klein BE, Moss SE, Davis MD, DeMets DL: The Wisconsin epidemiologic study of diabetic retinopathy. IV. Diabetic macular edema. *Ophthalmology* 91:1464–1474, 1984
3. Amos AF, McCarty DJ, Zimmet P: The rising global burden of diabetes and its complications: estimates and projections to the year 2010. *Diabet Med* 14 (Suppl. 5): S1–S85, 1997
4. Huang D, Swanson EA, Lin CP, Schuman JS, Stinson WG, Chang W, Hee MR, Flotte T, Gregory K, Puliafito CA: Optical coherence tomography. *Science* 254:1178–1181, 1991
5. Shahidi M, Ogura Y, Blair NP, Rusin MM, Zeimer R: Retinal thickness analysis for quantitative assessment of diabetic macular edema. *Arch Ophthalmol* 109:1115–1119, 1991

6. Schaudig UH, Glaefke C, Scholz F, Richard G: Optical coherence tomography for retinal thickness measurement in diabetic patients without clinically significant macular edema. *Ophthalmic Surg Lasers* 31:182–186, 2000
7. Parving HH: Microvascular permeability to plasma proteins in hypertension and diabetes mellitus in man: on the pathogenesis of hypertensive and diabetic microangiopathy. *Dan Med Bull* 22:217–233, 1975
8. Kohner EM, Aldington SJ, Stratton IM, Manley SE, Holman RR, Matthews DR, Turner RC: United Kingdom Prospective Diabetes Study 30: diabetic retinopathy at diagnosis of non-insulin-dependent diabetes mellitus and associated risk factors. *Arch Ophthalmol* 116:297–303, 1998
9. Chew EY, Klein ML, Ferris FL, Remaley NA, Murphy RP, Chantry K, Hoogwerf BJ, Miller D: Association of elevated serum lipid levels with retinal hard exudate in diabetic retinopathy: Early Treatment Diabetic Retinopathy Study (ETDRS) Report 22. *Arch Ophthalmol* 114:1079–1084, 1996
10. Poulsen PL, Bek T, Ebbelhøj E, Hansen KW, Mogensen CE: 24-h ambulatory blood pressure and retinopathy in normoalbuminuric IDDM patients. *Diabetologia* 41:105–110, 1998
11. Krolewski AS, Barzilay J, Warram JH, Martin BC, Pfeifer M, Rand LI: Risk of early-onset proliferative retinopathy in IDDM is closely related to cardiovascular autonomic neuropathy. *Diabetes* 41:430–437, 1992
12. Nielsen FS, Rossing P, Gall MA, Smidt UM, Chen JW, Sato A, Parving HH: Lisinopril improves endothelial dysfunction in hypertensive NIDDM subjects with diabetic nephropathy. *Scand J Clin Lab Invest* 57:427–434, 1997
13. Parving HH, Larsen M, Hommel E, Lund Andersen H: Effect of antihypertensive treatment on blood-retinal barrier permeability to fluorescein in hypertensive type 1 (insulin-dependent) diabetic patients with background retinopathy. *Diabetologia* 32:440–444, 1989
14. Hee MR, Puliafito CA, Wong C, Duker JS, Reichel E, Rutledge B, Schuman JS, Swanson EA, Fujimoto JG: Quantitative assessment of macular edema with optical coherence tomography. *Arch Ophthalmol* 113:1019–1029, 1995
15. Koozekanani D, Roberts C, Katz SE, Herderick EE: Intersession repeatability of macular thickness measurements with the Humphrey 2000 OCT. *Invest Ophthalmol Vis Sci* 41:1486–1491, 2000
16. Massin P, Vicaud E, Haouchine B, Erginay A, Paques M, Gaudric A: Reproducibility of retinal mapping using optical coherence tomography. *Arch Ophthalmol* 119:1135–1142, 2001
17. Parving HH, Rossing N: Simultaneous determination of the transcapillary escape rate of albumin and IgG in normal and long-term juvenile diabetic subjects. *Scand J Clin Lab Invest* 32:239–244, 1973
18. Parving HH, Gynzelberg F: Albumin transcapillary escape rate and plasma volume during long-term beta-adrenergic blockade in essential hypertension. *Scand J Clin Lab Invest* 32:105–110, 1973
19. O'Brien E, Coats A, Owens P, Petrie J, Padfield PL, Littler WA, de Swiet M, Mee F: Use and interpretation of ambulatory blood pressure monitoring: recommendations of the British hypertension society. *BMJ* 320:1128–1134, 2000
20. Ewing DJ, Martyn CN, Young RJ, Clarke BF: The value of cardiovascular autonomic function tests: 10 years experience in diabetes. *Diabetes Care* 8:491–498, 1985
21. Lobo CL, Bernardes RC, Cunha-Vaz JG: Alterations of the blood-retinal barrier and retinal thickness in preclinical retinopathy in subjects with type 2 diabetes. *Arch Ophthalmol* 118:1364–1369, 2000
22. Deckert T, Feldt Rasmussen B, Borch Johnsen K, Jensen T, Kofoed Enevoldsen A: Albuminuria reflects widespread vascular damage: the Steno hypothesis. *Diabetologia* 32:219–226, 1989
23. Jensen T, Bjerre Knudsen J, Feldt Rasmussen B, Deckert T: Features of endothelial dysfunction in early diabetic nephropathy. *Lancet* 1:461–463, 1989
24. Nannipieri M, Rizzo L, Rapuano A, Pilo A, Penno G, Navalesi R: Increased transcapillary escape rate of albumin in microalbuminuric type II diabetic patients. *Diabetes Care* 18:1–9, 1995
25. Parving HH, Nielsen FS, Bang LE, Smidt UM, Svendsen TL, Chen JW, Gall MA, Rossing P: Macro-microangiopathy and endothelial dysfunction in NIDDM patients with and without diabetic nephropathy. *Diabetologia* 39:1590–1597, 1996
26. Stephenson JM, Fuller JH, Viberti GC, Sjolie AK, Navalesi R: Blood pressure, retinopathy and urinary albumin excretion in IDDM: the EURODIAB IDDM Complications Study. *Diabetologia* 38:599–603, 1995
27. Gall MA, Hougaard P, Borch Johnsen K, Parving HH: Risk factors for development of incipient and overt diabetic nephropathy in patients with non-insulin dependent diabetes mellitus: prospective, observational study. *BMJ* 314:783–788, 1997
28. Moss SE, Klein R, Klein BE: The 14-year incidence of visual loss in a diabetic population. *Ophthalmology* 105:998–1003, 1998
29. Adler AI, Stratton IM, Neil HA, Yudkin JS, Matthews DR, Cull CA, Wright AD, Turner RC, Holman RR: Association of systolic blood pressure with macrovascular and microvascular complications of type 2 diabetes (UKPDS 36): prospective observational study. *BMJ* 321:412–419, 2000
30. Kohner EM, Patel V, Rassam SM: Role of blood flow and impaired autoregulation in the pathogenesis of diabetic retinopathy. *Diabetes* 44:603–607, 1995
31. Imanishi M, Yoshioka K, Konishi Y, Okumura M, Okada N, Sato T, Tanaka S, Fujii S, Kimura G: Glomerular hypertension as one cause of albuminuria in type II diabetic patients. *Diabetologia* 42:999–1005, 1999
32. Bek T: Diabetic maculopathy caused by disturbances in retinal vasomotion: a new hypothesis. *Acta Ophthalmol Scand* 77:376–380, 1999
33. Rassam SM, Patel V, Kohner EM: The effect of experimental hypertension on retinal vascular autoregulation in humans: a mechanism for the progression of diabetic retinopathy. *Exp Physiol* 80:53–68, 1995
34. Stratton IM, Kohner EM, Aldington SJ, Turner RC, Holman RR, Manley SE, Matthews DR: UKPDS 50: risk factors for incidence and progression of retinopathy in type II diabetes over 6 years from diagnosis. *Diabetologia* 44:156–163, 2001
35. Knudsen ST, Poulsen PL, Hansen KW, Ebbelhøj E, Bek T, Mogensen CE: Pulse pressure and diurnal blood pressure variation: association with micro- and macrovascular complications in type 2 diabetes. *Am J Hypertens* 15:244–250, 2002
36. Diabetes Control and Complications Trial Research Group: The effect of intensive treatment of diabetes on the development and progression of long-term complications in insulin-dependent diabetes mellitus. *N Engl J Med* 329:977–986, 1993
37. EUCLID Study Group: Randomised placebo-controlled trial of lisinopril in normotensive patients with insulin-dependent diabetes and normoalbuminuria or microalbuminuria. *Lancet* 349:1787–1792, 1997
38. Chaturvedi N, Sjolie AK, Stephenson JM, Abrahamian H, Keipes M, Castellarin A, Rogulja-Pepeonik Z, Fuller JH: Effect of lisinopril on progression of retinopathy in normotensive people with type 1 diabetes: the EUCLID Study Group. EURODIAB controlled trial of lisinopril in insulin-dependent diabetes mellitus. *Lancet* 351:28–31, 1998
39. UK Prospective Diabetes Study (UKPDS) Group: Intensive blood-glucose control with sulphonylureas or insulin compared with conventional treatment and risk of complications in patients with type 2 diabetes (UKPDS 33). *Lancet* 352:837–853, 1998
40. UK Prospective Diabetes Study (UKPDS) Group: Tight blood pressure control and

- risk of macrovascular and microvascular complications in type 2 diabetes: UKPDS 38. *BMJ* 317:703–713, 1998
41. Lewis EJ, Hunsicker LG, Bain RP, Rohde RD: The effect of angiotensin-converting-enzyme inhibition on diabetic nephropathy: the Collaborative Study Group. *N Engl J Med* 329:1456–1462, 1993
42. Heart Outcomes Prevention Evaluation Study Investigators: Effects of ramipril on cardiovascular and microvascular outcomes in people with diabetes mellitus: results of the HOPE study and MICRO-HOPE substudy. *Lancet* 355: 253–259, 2000
43. Ferrari Dileo G, Davis EB, Anderson DR: Angiotensin binding sites in bovine and human retinal blood vessels. *Invest Ophthalmol Vis Sci* 28:1747–1751, 1987
44. Engler CB, Parving HH, Mathiesen ER, Larsen M, Lund Andersen H: Blood-retina barrier permeability in diabetes during acute ACE- inhibition. *Acta Ophthalmol Copenh* 69:581–585, 1991