



T-Lymphocyte Infiltration to Islets in the Pancreas of a Patient Who Developed Type 1 Diabetes After Administration of Immune Checkpoint Inhibitors

Diabetes Care 2019;42:e116–e118 | <https://doi.org/10.2337/dc18-2518>

Sho Yoneda,¹ Akihisa Imagawa,²
Yoshiya Hosokawa,¹
Megu Yamaguchi Baden,¹
Takekazu Kimura,¹ Sae Uno,¹
Kenji Fukui,¹ Kunihiro Goto,³
Motohide Uemura,⁴ Hidetoshi Eguchi,³
Hiromi Iwahashi,^{1,5} Junji Kozawa,¹ and
Ichihiro Shimomura¹

Type 1 diabetes is a disease characterized by destruction of the β -cells in the pancreatic islets. The inhibitory receptor programmed cell death-1 (PD-1) and its ligands, programmed cell death ligand-1 (PD-L1) and PD-L2, have been shown to play an important role in regulating T-cell activation and peripheral tolerance. Inhibitors targeting PD-1 or PD-L1 are especially advantageous in the treatment of cancer. There are several reports where type 1 diabetes developed after administration of anti-PD-1 antibody (1). However, there is no report containing an immunohistochemical study of the pancreas.

At the age of 55 years, a male patient underwent left radical nephrectomy for kidney cancer. At age 60, he was diagnosed with type 2 diabetes. Under the administration of vildagliptin, his hemoglobin A_{1c} was maintained at ~6% (41 mmol/mol). He was diagnosed with gallbladder metastasis of renal carcinoma at age 61 and underwent a cholecystectomy. Thereafter, he was diagnosed with renal carcinoma pancreatic metastasis, which increased in size, whereupon anti-CTLA4 antibody (ipilimumab) and anti-PD-1 antibody (nivolumab) combination therapy was started. Ipilimumab and nivolumab were administered four times over 2 months

and nine times over 5 months, respectively. At age 63, 5 months after the start of administration, he developed diabetic ketoacidosis, his serum C-peptide was 1.8 ng/mL at that time, and insulin treatment was started. Anti-glutamic acid decarboxylase, anti-IA-2, and anti-IAA antibodies were negative, and his HLA haplotype was *DRB1*11:01-DQB1*03:01* and *DRB1*09:01-DQB1*03:03*. Two weeks after hospitalization, his serum C-peptide was <0.1 ng/mL. Thereafter, the combination therapy was discontinued. At age 65, for radical treatment, total pancreatectomy was performed.

Immunohistochemistry was performed on six paraffin blocks in the nontumor region of the pancreas from the patient. We quantified the entire section of five of six paraffin blocks for evaluation of inflammatory cell infiltration. Seven patients with normal glucose tolerance who had undergone pancreatic resection were evaluated for use as control subjects (2). The study protocol was approved by the Ethics Committee of Osaka University. All patients provided informed consent before their participation.

In this patient, the mean total pancreas area was $88 \pm 11 \text{ mm}^2$, and very few single and clustered β -cells were occasionally observed. CD3-positive T

lymphocytes were found in and around the pancreatic islets with residual α -cells but also diffusely throughout the section of pancreas (Fig. 1A–F). The number of CD3-positive T lymphocytes infiltrating into pancreatic islets (>100 μm in diameter) and per section was 1.1 ± 0.2 cells/islet (67 ± 41 islets) and 31.1 ± 4.9 cells/ mm^2 , which was more than 15 times and 8 times higher than that of the control group (0.07 ± 0.10 cells/islet [16 ± 12 islets] and 3.5 ± 3.0 cells/ mm^2), respectively. The composition of infiltrating T lymphocytes was dominated by CD8-positive T lymphocytes more than CD4-positive T lymphocytes. The infiltration of CD3-positive T lymphocytes was observed in the vicinity of the single and clustered β -cells. CD68-positive macrophages were not observed markedly around the pancreatic islets. The expression of PD-L1 was not observed in a residual single β -cell (Fig. 1G–I). There were some pancreatic islets with PD-L1-positive α -cells and non- α -cells, but most islets were PD-L1 negative (Fig. 1J–L). In contrast, expression of PD-L1 was observed in all pancreatic islets (10.2 ± 8.0 islets) of the control patients (Fig. 1M–R).

Residual β -cells were very few in the pancreas with marked infiltration of T

¹Department of Metabolic Medicine, Graduate School of Medicine, Osaka University, Suita, Japan

²Department of Internal Medicine (I), Osaka Medical College, Takatsuki, Japan

³Department of Gastroenterological Surgery, Graduate School of Medicine, Osaka University, Suita, Japan

⁴Department of Urology, Graduate School of Medicine, Osaka University, Suita, Japan

⁵Department of Diabetes Care Medicine, Graduate School of Medicine, Osaka University, Suita, Japan

Corresponding author: Sho Yoneda, yoneda@endmet.med.osaka-u.ac.jp

Received 9 December 2018 and accepted 21 April 2019

© 2019 by the American Diabetes Association. Readers may use this article as long as the work is properly cited, the use is educational and not for profit, and the work is not altered. More information is available at <http://www.diabetesjournals.org/content/license>.

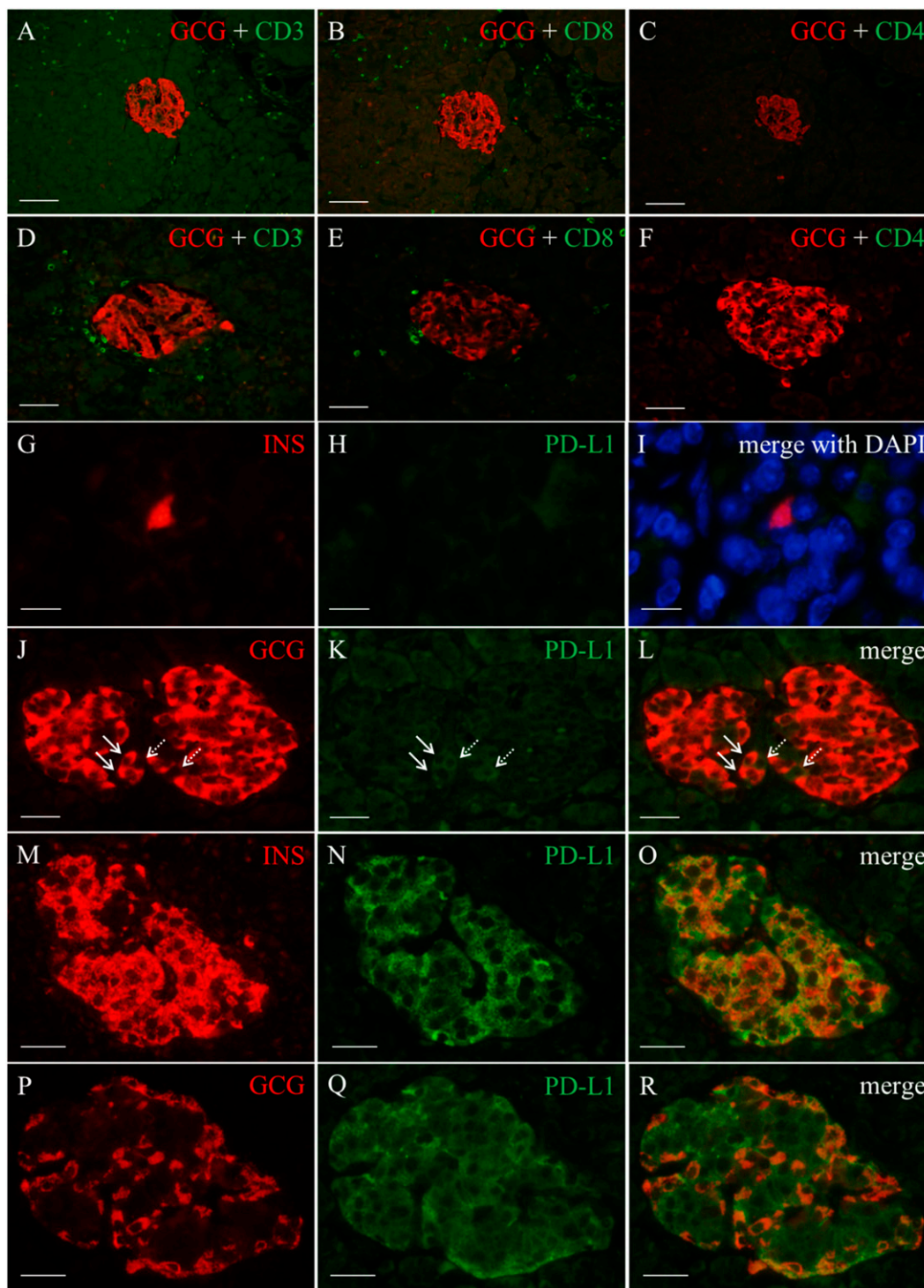


Figure 1—Marked T-lymphocyte infiltration around islets and exocrine region with a predominance of CD8-positive T lymphocytes and expression of PD-L1 in β -cells and α -cells. Immunohistochemical analyses in the case patient (A–F and G–L) and the control patient (M–R). Double immunofluorescence staining for glucagon (GCG) (red) and CD3 (green) (A and D), CD8 (green) (B and E), and CD4 (green) (C and F) in serial sections (A–C and D–F). CD3-positive T lymphocytes were observed diffusely throughout the pancreatic section (A) and around the pancreatic islets with residual α -cells (D). The composition of infiltrating T lymphocytes was dominated by CD8-positive T lymphocytes more than CD4-positive T lymphocytes in both the pancreatic islet region and the exocrine region. The numbers of CD8-positive and CD4-positive T lymphocytes infiltrating into pancreatic islets ($>100 \mu\text{m}$ in diameter) and per section were 1.0 ± 0.2 cells/islet (69 ± 38 islets) and 0.2 ± 0.1 cells/islet (66 ± 36 islets), 27.6 ± 3.9 cells/ mm^2 and 1.8 ± 0.7 cells/ mm^2 , respectively (B, C, E, and F). Double immunofluorescence staining for insulin (INS) (red) (G and M) and PD-L1 (green) (H and N) with DAPI (I), and glucagon (red) (J and P) and PD-L1 (green) (K and Q). L, O, and R are a merge of J and K, M and N, and P and Q, respectively. Expression of PD-L1 was not observed in the single β -cell (G–I), including all other residual β -cells ($n = 4$) in 11 sections of six paraffin blocks, but was evident in some α -cells (solid arrows) and non- α -cells (dotted arrows) (J–L) in the patient who developed type 1 diabetes after immune checkpoint inhibitor therapy. In contrast, expression of PD-L1 was observed in both β -cells and α -cells in patients with normal glucose tolerance (M–R). Scale bars: $100 \mu\text{m}$ (A–C), $50 \mu\text{m}$ (D–F), $10 \mu\text{m}$ (G–I), and $25 \mu\text{m}$ (J–R).

lymphocytes, which lead to the histological confirmation of type 1 diabetes, and the number seemed to be smaller in comparison with previously reported type 1 diabetes cases (3). Therefore, it is suggested that in type 1 diabetes that developed after the administration of immune checkpoint inhibitors, β -cells are likely to be more thoroughly injured compared with typical autoimmune type 1 diabetes. PD-L1-deficient mice on a NOD background develop rapid onset of disease (4). Therefore, lower levels of PD-L1 expression in the pancreatic islets are hypothesized to be associated with β -cell injury in this patient.

CTLA4 expression was reduced in the peripheral CD4-positive T cells of fulminant type 1 diabetes (5), suggesting that CTLA4 might play a role in its development. Further studies are needed to clarify the association between ipilimumab administration and the onset of type 1 diabetes.

In conclusion, we immunohistochemically analyzed the pancreas of a patient who developed type 1 diabetes after administration of anti-CTLA4 and anti-PD-1 antibodies. Infiltration of T lymphocytes into pancreatic islets with low levels of PD-L1 expression was hypothesized to be associated with β -cell injury and type 1 diabetes onset in the patient.

Acknowledgments. The authors thank Misako Kobayashi, Department of Metabolic Medicine, Graduate School of Medicine, Osaka University, for her excellent technical assistance.

Duality of Interest. No potential conflicts of interest relevant to this article were reported.

Author Contributions. S.Y. researched data and wrote the manuscript. A.I., H.I., and J.K. contributed to the discussion and reviewed and edited the manuscript. Y.H. researched data for relative α -cell area. S.U. collected HLA data. Y.H., M.Y.B., T.K., and K.F. contributed to the discussion. K.G. and H.E. performed surgical treatment and provided the resected pancreatic tissues. M.U. performed urology treatment. I.S. contributed to the discussion and reviewed the manuscript. S.Y. is the guarantor of this work

and, as such, had full access to all the data in the study and takes responsibility for the integrity of the data and the accuracy of the data analysis.

References

1. Baden MY, Imagawa A, Abiru N, et al.; consultation of the Japan Diabetes Society Committee on Type 1 Diabetes Mellitus Research. Characteristics and clinical course of type 1 diabetes mellitus related to anti-programmed cell death-1 therapy. *Diabetol Int* 2018;10:58–66
2. Yoneda S, Imagawa A, Fukui K, et al. A histological study of fulminant type 1 diabetes mellitus related to human cytomegalovirus reactivation. *J Clin Endocrinol Metab* 2017;102:2394–2400
3. Butler AE, Galasso R, Meier JJ, Basu R, Rizza RA, Butler PC. Modestly increased beta cell apoptosis but no increased beta cell replication in recent-onset type 1 diabetic patients who died of diabetic ketoacidosis. *Diabetologia* 2007;50:2323–2331
4. Keir ME, Liang SC, Guleria I, et al. Tissue expression of PD-L1 mediates peripheral T cell tolerance. *J Exp Med* 2006;203:883–895
5. Haseda F, Imagawa A, Murase-Mishiba Y, et al. Low CTLA-4 expression in CD4+ helper T-cells in patients with fulminant type 1 diabetes. *Immunol Lett* 2011;139:80–86