



Saving the Diabetic Foot During the COVID-19 Pandemic: A Tale of Two Cities

Laura Shin,¹ Frank L. Bowling,²
David G. Armstrong,¹ and
Andrew J.M. Boulton^{2,3}

Diabetes Care 2020;43:1704–1709 | <https://doi.org/10.2337/dc20-1176>

Of all the late complications of diabetes, those involving the foot have traditionally required more face-to-face patient visits to clinics to treat wounds by debridement, offloading, and many other treatment modalities. The advent of the coronavirus disease 2019 (COVID-19) pandemic has resulted not only in the closing of most outpatient clinics for face-to-face consultations but also in the inability to perform most laboratory and imaging investigations. This has resulted in a paradigm shift in the delivery of care for those with diabetic foot ulcers. The approaches to this challenge in two centers with an interest in diabetic foot disease, including virtual consultations using physician-to-patient and physician-to-home nurse telemedicine as well as home podiatry visits, are described in this review and are illustrated by several case vignettes. The outcomes from these two centers suggest that we may be witnessing new possibilities in models of care for the diabetic foot.

The coronavirus disease 2019 (COVID-19) global pandemic has presented many challenges in the management of people with diabetes across the world. New modes of patient consultation are being widely used, and these include telephone consultations and telemedicine using a video consultation. Whereas many people with diabetes can be managed using these new methods of consultation, the diabetic foot, the most common reason for hospital admission among people with diabetes, presents unique challenges because of the frequent need for “face-to-face” consultation and treatment of foot lesions. In this review, the approaches from two centers with a major interest in diabetic foot problems are compared and contrasted. Although from the Dickensian title readers may be expecting this to be London and Paris, in this review it is Manchester, U.K., and Los Angeles, CA. The approaches of each center to the management of diabetic foot problems are examined in detail with a clear description of how the service has changed to meet the challenge presented by the pandemic. Data are presented in terms of numbers of patients seen in different settings, with individual case presentations from each center demonstrating how the challenge was met.

BACKGROUND

The current COVID-19 pandemic has presented major challenges to those looking after people with noncommunicable diseases. At the time of writing, there have been >1.5 million cases in the U.S. and >240,000 in the U.K., with >125,000 deaths between the two countries. The outpatient management of people with diabetes and its complications is facing a huge challenge as routine face-to-face clinics have been canceled in many countries and the ability to order even basic tests has been severely restricted. This has produced many challenges but also opportunities for the delivery of diabetes care.

¹Southwestern Academic Limb Salvage Alliance (SALSA), Department of Surgery, Keck School of Medicine, University of Southern California, Los Angeles, CA

²Division of Diabetes, Endocrinology & Gastroenterology, The University of Manchester, and Diabetes Centre, Manchester Royal Infirmary, Manchester, U.K.

³Diabetes Research Institute, Miller School of Medicine, University of Miami, Miami, FL

Corresponding author: Andrew J.M. Boulton, aboulton@med.miami.edu

Received 18 May 2020 and accepted 21 May 2020

This article is part of a special article collection available at <https://care.diabetesjournals.org/collection/diabetes-and-COVID19>.

© 2020 by the American Diabetes Association. Readers may use this article as long as the work is properly cited, the use is educational and not for profit, and the work is not altered. More information is available at <https://www.diabetesjournals.org/content/license>.

Of all the chronic complications of diabetes, foot problems are the most common cause of hospital admissions (1,2) in Western countries. Such admissions are usually precipitated by serious infections in neuropathic or neuroischemic feet. Moreover, such patients frequently have multiple comorbidities, especially cardiovascular and renal disease (2,3), which affect the risk of lower-extremity amputation and mortality (2–4). Thus, the cancellation of most outpatient clinical services has posed a potential threat to those with diabetic foot problems including active diabetic foot ulcers (DFUs), significant ischemia, and Charcot neuroarthropathy. Many reviews on the impact and management of COVID-19 in patients with diabetes have been published (e.g., Hussain et al. [5] and Bornstein et al. [6]), but none has focused on the impact of the COVID-19 pandemic on patients with diabetes with foot problems. A special communication from the American Podiatric Medical Association (7) recently emphasized the importance of appropriate management of DFUs and other complications and speculated how these might be managed at several different settings, including home, during this pandemic. Subsequently, multiple stakeholders with an interest in wound care have proposed a new strategy for wound management during the COVID-19 pandemic (8).

Two centers with a major interest in the management of diabetic foot problems, at the Manchester Royal Infirmary, Manchester, U.K., and the Keck School of Medicine of the University of Southern California (USC), Los Angeles, CA, have adapted to a new model of care for those with active diabetic foot problems during and likely after the pandemic. These are now described in detail with initial results of the patients seen in the 6 weeks prior to the pandemic lockdown compared with those in the 6 weeks after this was established.

THE TWO CITIES

Manchester, U.K.

Greater Manchester is a metropolitan county in the North West of the U.K. with a population of just under 3 million. According to the 2011 Census, 84% of the population was white, 10% Asian (predominantly Indian subcontinent Asia), 3% black, and 3% other. One of the main university teaching hospitals in Manchester is the Royal Infirmary; the multidisciplinary

diabetic foot clinic has been operational for more than 30 years (9) and includes a number of different specialties: diabetologists, vascular surgeon, podiatric surgeon, podiatrists, diabetes specialist nurses, and an orthotist.

Los Angeles

The Southwestern Academic Limb Salvage Alliance (SALSA) at the Keck School of Medicine of USC consists of four core hospital-based clinics and inpatient units serving a remarkably diverse population of 10 million people in Los Angeles County. The four sites (Keck Medical Center of USC, Los Angeles County USC Medical Center, Rancho Los Amigos National Rehabilitation Center, and Verdugo Hills Hospital) collectively see over 230 patients monthly with DFUs. The Los Angeles County population estimate in 2018 included the following: 50.7% female, 48.8% Hispanic or Latino, 8.5% black or African American, 14.5% Asian, 0.2% American Indian and Alaska Native, 0.2% Native Hawaiian and other Pacific Islander, 27.8% white, and 3% two or more races.

REPORTS FROM CENTERS

Manchester

Prior to the lockdown, patients with complex diabetic foot wounds or active Charcot neuroarthropathy were seen in a weekly clinic held off-site at a community ambulatory care center. Many other patients with DFUs were seen by podiatrists in the Manchester Diabetes Centre, which is on the site of the Manchester Royal Infirmary. As a result of the expertise in diabetic foot problems, many patients seen in these clinics are referred from centers throughout the North West of England. A second center within Greater Manchester is included in this study and is located at one of the district hospitals. The multidisciplinary diabetic foot clinic

there is held off-site at the Diabetes Centre; this is similarly staffed by a multidisciplinary team.

Data have been collected from the 6 weeks prior to lockdown (ending 20 March) and compared with the 6 weeks post-lockdown ending 1 May 2020. Whereas some patients were seen in the Manchester Diabetes Centre on the site of the main hospital, post-lockdown, most patients were seen either at the community ambulatory care center in Manchester or at home visits by podiatrists. Additionally, some patients have been contacted via telephone for consultations. Data are presented in terms of number of patient attendances and the number of patients that were admitted from the clinics for inpatient care, normally surgical (Table 1).

Los Angeles

Prior to the pandemic, patients with ulceration were seen in the multidisciplinary SALSA clinic, which incorporates a combination of podiatry, vascular surgery, plastic surgery, and physical therapy wound care specialists to provide comprehensive care for diabetic ulcerations and reconstructive lower-extremity surgery. When the “shelter in place” (lockdown) orders began in mid-March, all nonemergency patient encounters were rescheduled or switched to telemedicine encounters. All surgical cases were canceled unless they were emergent, and all imaging and noninvasive vascular testing, radiography, and even laboratory work were placed on hold. All nonemergent or noncritically ill patients were directed away from the hospital to conserve resources and personal protective equipment. The first weeks were spent reaching out to patients to coordinate care remotely. This included establishing dressing change instructions and education and distributing materials

Table 1—Data for patient contacts pre- and post-lockdown in the two cities.

	Clinic visits	Telecare	Home (domicile) visits	Hospitalization
Manchester				
Pre-lockdown	373	0	0	13
Post-lockdown	208	78	227	2
Los Angeles				
Pre-lockdown	282	0	0	18
Post-lockdown	86	113	0	6

Telecare refers to either telephone or video consultations. Home (domicile) visits refers to home visits for treatment by a podiatrist.

to the families, caretakers, and home care nursing agencies. Patients with wounds that required further surveillance and monitoring were sent to our physical therapy wound care center. Serial debridement and offloading were some of the challenges that we immediately faced from the lockdown. Less than 10% of patients with foot ulcers were able to be seen in the clinic after the lockdown began. Patient visits were spread out so that no more than one patient would be in the waiting room at one time. Telemedicine or virtual visits were implemented immediately using photographs and video connection—enabled conferencing to evaluate wounds and to direct care to the patient. Virtual education was also provided to home-visiting nurses for clinical management including dressing changes, monitoring for signs of infection, and light local debridement. It was also possible, by guiding health nurses via telehealth, to practice less commonly used therapies safely and effectively in the community such as larval (maggot) therapy (case 3) (Fig. 3). Most patients had undergone vascular studies prior to lockdown, but new patients were evaluated with handheld Doppler probes and clinical examination. Any patients with critical limb-threatening ischemia or severe rest pain were directed to our vascular counterparts for admission to get vascular testing and intervention. Our data set includes all patient encounters in the 6 weeks prior to and the 6 weeks after the lockdown orders were placed. We have included hospitalizations and the number of telemedicine visits, which did not exist prior to our lockdown (Table 1).

RESULTS FROM MANCHESTER AND LOS ANGELES

Table 1 presents patient contacts with foot lesions in the 6 weeks prior to lockdown and the 6 weeks post-lockdown in both Manchester and Los Angeles. It also identifies the number of telecare visits (either telephone or “virtual” with audio and video connection), actual visits, and, in Manchester, home visits by podiatrists. As can be seen from Table 1, there has been a marked reduction in the number of hospital admissions post-lockdown in both Manchester and Los Angeles. In Los Angeles, 57% of clinical encounters were converted to telemedicine visits, whereas in Manchester, the figure was 18%.

Clinical Vignettes

A number of clinical vignettes are presented from both centers, with the first two from Manchester and the remaining three from Los Angeles. Four involve patients who would normally have been admitted to hospital but have successfully been managed by techniques described above without the need for hospitalization, whereas the fifth is a cautionary case of a patient who should have been admitted for urgent inpatient care. In Manchester, these cases are of patients with presumed osteomyelitis due to clinical signs who might normally have been admitted for local surgery but have been successfully managed on oral antibiotics. Clinical photographs of the lesions before and after treatment are presented. Similarly, from Los Angeles, case vignettes are presented particularly regarding how telemedicine has been successful in enabling patients who would normally have been seen in the hospital to be managed at home or at a clinic away from a hospital. After lockdown, localized infections were treated with in-office procedures and antibiotics in efforts to offload burden on the emergency rooms (ERs). All patients with ulcerations in the hospital were discharged to home with coordination of outpatient care.

Case Vignette 1

A 73-year-old male with longstanding type 2 diabetes, known peripheral neuropathy, and ischemic heart disease attended the Manchester high-risk diabetic foot clinic 3 weeks prior to the lockdown. He had extensive soft tissue loss over the medial side of the interphalangeal joint of his right hallux, also spreading to the proximal and distal phalanges (Fig. 1A). A plain radiograph was possible at this juncture and demonstrated extensive osteomyelitis involving the proximal end of the distal phalanx, the distal end of the proximal phalanx, and the interphalangeal joint (Fig. 1B). Clinical examination confirmed a dense peripheral neuropathy in both feet with normal peripheral pulses and Doppler arterial signals in the pedal arteries. There was a positive “probe-to-bone” test, and after the positive X-ray, he was started on ciprofloxacin 750 mg b.i.d. and clindamycin 450 mg q.i.d. This would normally have been managed by a local surgical procedure as an inpatient, but with the rising COVID-19 problem, we elected to continue with oral antibiotic therapy. Over the next 6 weeks,

the healing trajectory progressed and the sausage-shaped distension of the digit was reduced; by 8 weeks post-lockdown, the ulcer had completely healed (Fig. 1C). Unfortunately, due to lockdown, a post-healing radiograph has not been possible to date.

Case Vignette 2

A 59-year-old male patient with long-standing type 2 diabetes and known peripheral neuropathy presented to the off-site “hot clinic” in Manchester during the first week of lockdown with a grossly swollen right second toe with tracking cellulitis dorsally (Figs. 2A and B) and sausage-shaped distension of the second toe (Fig. 2A). There was a purulent discharge (Fig. 2B) and malodor; the probe-to-bone test was positive directly onto the metatarsal head. Doppler ultrasound signals using a handheld Doppler instrument were monophasic in the dorsalis pedis artery but biphasic in the posterior tibial artery, suggesting some distal vascular disease. A clinical diagnosis of osteomyelitis with septic arthritis was made, but a radiograph was impossible because it was in the first week of lockdown and routine radiographs were not being performed. He was started on the same combination of antibiotics as described in the case vignette 1, and over the next 6 weeks, the sausage-shaped distension of the digit reduced significantly and the plantar lesion was on a healing trajectory (Fig. 2C).

Case Vignette 3

A 68-year-old male with a complex medical history including type 2 diabetes, cardiac disease with ejection fraction of 20%, and peripheral arterial disease with bilateral popliteal-to-peroneal bypass had undergone an open transmetatarsal amputation secondary to gangrene and extensive forefoot tissue loss 2 weeks prior to the lockdown. The patient underwent negative pressure wound therapy but developed significant maceration in the periwound border. He had biofilm and fibrin that required weekly debridement prior to the lockdown orders. Given his comorbidities and frailty, there was significant concern by his family to continue in-person visits. In view of the high risk of infection, we offered the patient maggot debridement therapy. The patient’s home care nurse did not have experience with this modality, so we provided a video conference and education as to how to apply and remove the

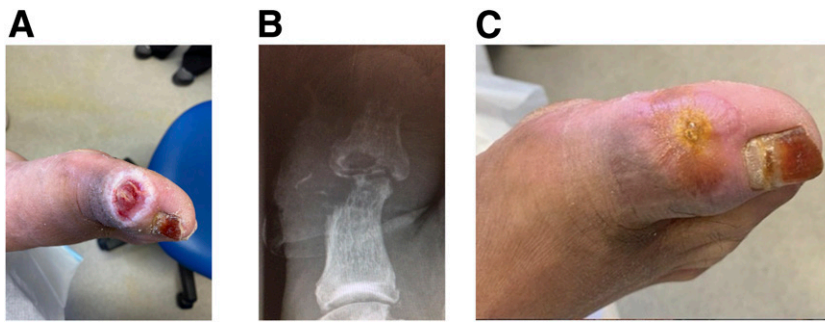


Figure 1—Images from case 1. *A*: Foot ulcer on medial side of right hallux prior to lockdown. *B*: Radiograph of right hallux prior to lockdown showing extensive osteomyelitis and septic arthritis in both phalanges and interphalangeal joints. *C*: After 8 weeks of antibiotics, 6 weeks post-lockdown showing healed wound on right hallux.

larvae at home prior to telehealth guidance (10). Figure 3 shows the dressing with the larvae at time of removal. All education and dressing changes were conducted by telehealth guiding the home-visiting nurse as to how to perform this procedure.

Case Vignette 4

A 68-year-old male patient with a history of type 2 diabetes, renal transplantation, and peripheral arterial disease with residual tissue loss and dry gangrene to the digits was being followed in our clinic after angioplasty. He later developed wet gangrene with localized infection in the proximal borders and developed some post-vascular intervention pain in the region (Fig. 4A). Despite antibiotic treatment, his condition was worsening, but he was terrified about any hospital admission as he was living with his pregnant daughter and her family and did therefore not want to attend as an inpatient in hospital or a skilled nursing facility. When on antibiotics, at the time of dressing changes his tissues were well demarcated. An open partial amputation of

digits 1–3 of the right foot was therefore performed in clinic using local anesthesia. The infection resolved within days, and his amputation sites began to heal and the wound was closed within three 3 weeks (Fig. 4B). In this case, hospitalization was avoided and his care was managed by both aggressive clinic-based procedures together with telehealth guidance.

Case Vignette 5: A Cautionary Tale

An 80-year-old patient with type 2 diabetes, neuropathy, peripheral vascular disease, and bilateral foot gangrene presented to the clinic 5 weeks after lockdown complaining of an increasingly painful right heel over a span of 2 weeks. He had attempted to see his primary care physician but was advised to stay home, was directed away from the hospital and clinic, and was placed on oral antibiotics. He contacted the operator at our university and made an appointment for our limb salvage unit. He was seen by our vascular surgery counterparts who saw that he had sufficient arterial perfusion for healing. Upon evaluation, the patient had significant tenderness, purulent drainage,

and putrid odor with exposed bone. He was hypertensive and febrile. He was admitted immediately and was found to have gas gangrene infection of his heel that had spread into every compartment of his foot and extended into his leg. He went on to a below-knee amputation and suffered a myocardial infarction in the hospital. Even with technology and close monitoring, our patients with active ulceration need access to inpatient care.

CONCLUSIONS

At the time of any pandemic, it is understandable that priorities for inpatient care should focus on those with severe cases of the infection. However, as recently pointed out by the editor in chief of *The BMJ*, this has led to the neglect of many conditions, particularly noncommunicable diseases (11). Although early plans to restart regular services have been announced by the U.K. National Health Service (12), those prioritized services did not include diabetes. Appropriate care for those with diabetic foot disease during and after the lockdown precipitated by the pandemic is therefore critical, as they frequently require face-to-face appointments for wound care. It is very worrisome therefore that the U.K. Government recently reported that the number of ER attendances for non-COVID-19 emergencies were >50% lower in April 2020 than in April 2019, suggesting that people with serious medical conditions are, for whatever reason, failing to attend hospital for treatment.

Data from China confirmed not only that diabetes is a risk factor for the progression and progress of COVID-19 infections (13) but also that among inpatients with diabetes and COVID-19 infection, nonsurvivors were older, mostly male, and more likely to have hypertension and cardiovascular disease (14). Similarly, those at risk for diabetic foot disease are older, 1.5 times more likely to be male, and typically have other comorbidities, especially cardiovascular and renal disease (1,2,4,15). Thus, the purpose of this review is to describe the steps that have been taken in two centers with expertise in diabetic foot disease to manage diabetic foot problems and, most importantly, to prevent the need for hospital admission if at all possible. The most common reason for those with DFUs to attend the ER is foot infection, often with

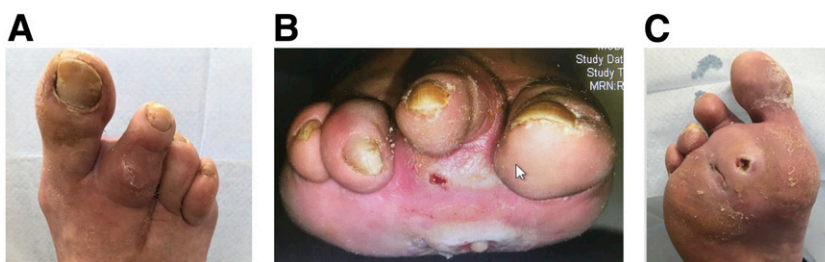


Figure 2—Images from case 2. *A*: Dorsal view of the right foot showing sausage-shaped swelling of the second toe with tracking cellulitis (note previous amputation of third toe) when the patient first presented. *B*: Frontal view of same toes showing purulent discharge from metatarsal head wound at presentation. *C*: Plantar view of the right foot 6 weeks later after continuous treatment with oral antibiotics showing near healing of the wound, reduced erythema, and reduced swelling of the toe.

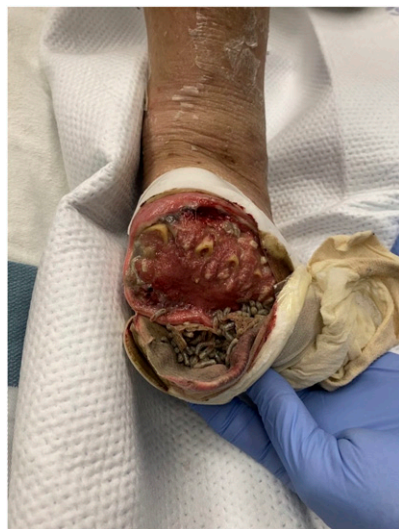

Figure 3—Image taken during telehealth-guided removal of maggots after 3 days of maggot debridement therapy in case 3. This patient had previously undergone a transmetatarsal amputation and received maggot debridement therapy at home rather than in the clinic or operating room.

underlying osteomyelitis (1,16). However, as those with diabetic neuropathy have lost “the gift of pain” (2,15), they may attend the ER with a high fever (pyrexia) and fail to mention a foot ulcer, and a careful foot exam may not occur. Indeed, a previous report described one such patient who was investigated for a fever of unknown origin for several days before the correct diagnosis was made (17). At present, all patients with a fever attending the ER are likely to undergo screening for COVID-19, including those with possible osteomyelitis, with the risk of them being exposed to others with

COVID-19. Thus, the aim of both centers has been to manage DFU patients as outpatients if possible. The two case reports from Manchester demonstrate that even those with extensive osteomyelitis who would previously have been managed in hospital with intravenous antibiotics and likely local surgery can successfully be managed with oral antibiotics. Fortunately, some recent randomized controlled trials support this approach. First, a randomized controlled trial from Spain confirmed that antibiotics alone are as efficacious as local surgery for foot osteomyelitis in diabetes (18), and second, the OVIVA (Oral Versus IntraVenous Antibiotics for bone and joint infection) study showed no difference in outcomes between intravenous and oral antibiotics in the treatment of osteomyelitis (19). In addition to long courses of oral antibiotics, in Manchester we have also used calcium sulfate pellets impregnated with tobramycin (OSTEOSET-T; Wright Medical, Memphis, TN) for the local treatment of osteomyelitis: the pellets are inserted into bony osteomyelitic cavities (20). In view of our observations that osteomyelitis, even with cellulitis, may be successfully treated by oral antibiotics alone, this may necessitate further changes to international guidelines (21), should future studies confirm the efficacy of this approach. The institution of home visits by podiatrists for DFU treatment and the adoption of telephone consultations for some DFU patients are both new developments in DFU management. Similarly, in Los Angeles, the adoption and widespread use of telemedicine virtual consultations have proved to be

successful, and many hospital admissions and treatments have been avoided. Larval therapy is used widely for wound cleansing and slough removal (22), and this can be applied successfully in the patient’s home with expert tuition to home-visiting nurses via a virtual link. However, the worrying nature of case 5 reminds us of the possibility that there is the potential for a tsunami of problems, resulting in major surgery, amputation, and mortality, to occur in the months and even years after the full lockdown finishes.

It seems likely that many of these changes in the management of those with DFUs will become the new normal in our approach to those with this common clinical problem, representing a paradigm shift in clinical management. The success of the approaches in each center certainly presents us with the possibility to inform future guidelines in DFU management.

The art of clinical observation has never been as important as it is now: osteomyelitis can be suspected by clinical appearance including a sausage-shaped swelling of the toes (23), as in Figs. 1 and 2. In the absence of any imaging or blood tests such as C-reactive protein, the likelihood of osteomyelitis can be increased by a positive probe-to-bone test (16). Local minor procedures have been performed in community clinics such as the removal of bony sequestrae. With such an approach, we have observed clinical resolution of presumed osteomyelitis in several cases; it is also likely that signs of radiologic healing will have occurred (24). Most importantly, we have managed to see a significant reduction in the need to hospitalize patients in both centers. This clinical experience during the COVID-19 pandemic has demonstrated the need to maintain the art of clinical medicine in terms of history taking and careful examination. The removal of tests that many doctors rely upon these days has shown that the art of clinical medicine has survived and is thriving. We have yet to discover the secondary effects of this pandemic and the lives and limbs lost due to delayed care. We must continue to be vigilant with our patients and work quickly to prevent serious complications.

It was Professor James Alexander Lindsay from Belfast who taught his medical students a number of aphorisms 100 years ago; one of these was, “For one mistake

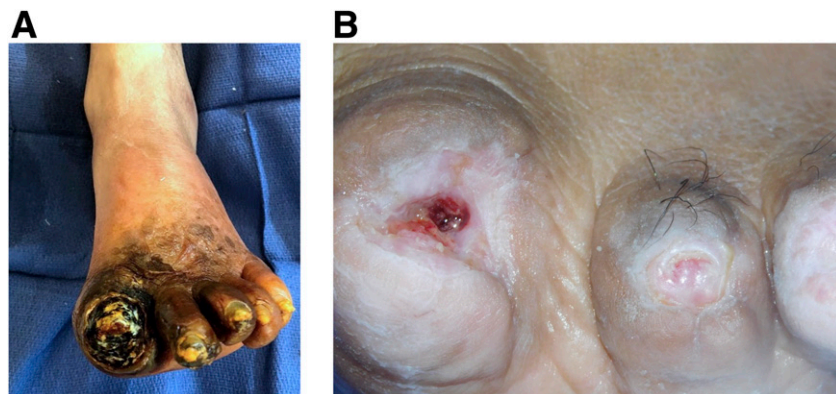


Figure 4—Images from case 4. A: Gangrene and infection of the toes prior to amputation of toes performed under local anesthesia in a clinic setting. B: Four weeks post—partial amputation of digits 1–3, showing signs of healing.

made for not knowing, ten mistakes are made for not looking” (25). Nothing could be more important than remembering the need to carefully examine the feet of patients with diabetes. The danger is that those who have “lost the gift of pain” as a consequence of diabetic peripheral neuropathy will be less likely to attend the ER when needed, so vigilance of very high-risk patients is essential during this challenging time.

Acknowledgments. The authors thank Georgina Bosson and the podiatry teams in Manchester for their help in providing patient contact numbers pre- and post-lockdown in Manchester and thank Ruth Myers for secretarial help. The authors are similarly grateful to Karen D’Huyvetter in Los Angeles for patient data abstraction.

Funding. Funding support for D.G.A. was partly from National Institutes of Health grant R44 DK102244-02.

Duality of Interest. No potential conflicts of interest relevant to this article were reported.

References

1. Armstrong DG, Boulton AJM, Bus SA. Diabetic foot ulcers and their recurrence. *N Engl J Med* 2017;376:2367–2375
2. Boulton AJM, Whitehouse RW. The diabetic foot. In *Endotext*. Feingold KR, Anawalt B, Boyce A, et al., Eds. South Dartmouth, MA, MDText.com, Inc. 2020
3. Ndiip A, Lavery LA, Boulton AJM. Diabetic foot disease in people with advanced nephropathy and those on renal dialysis. *Curr Diab Rep* 2010; 10:283–290
4. Armstrong DG, Swerdlow MA, Armstrong AA, Conte MS, Padula WV, Bus SA. Five year mortality and direct costs of care for people with diabetic foot complications are comparable to cancer. *J Foot Ankle Res* 2020;13:16
5. Hussain A, Bhowmik B, do Vale Moreira NC. COVID-19 and diabetes: knowledge in progress. *Diab Res Clin Pract* 2020;162:108142
6. Bornstein SR, Rubino F, Khunti K, et al. Practical recommendations for the management of diabetes in patients with COVID-19. *Lancet Diab Endocrinol* 2020;8:546–550
7. Rogers LC, Lavery LA, Joseph WS, Armstrong DG. All feet on deck – the role of podiatry during the COVID-19 pandemic: preventing hospitalizations in an overburdened healthcare system, reducing amputation and death in people with diabetes. *J Am Podiatr Med Assoc*. 25 March 2020 [Epub ahead of print]. DOI: 10.7547/20-051
8. Rogers LC, Armstrong DG, Capotorto J, et al. Wound center without walls: the new model of providing care during the COVID-19 pandemic. *Wounds*. 24 April 2020 [Epub ahead of print]
9. Boulton AJM. The diabetic lower limb – a 40 year journey: from clinical observation to clinical science: the 2017 Banting Memorial Lecture. *Diabet Med* 2019;36:1539–1549
10. Armstrong DG, Rowe VL, D’Huyvetter KD, Sherman RA. Telehealth-guided home-based maggot debridement therapy (MDT) for chronic complex wounds: peri and post-pandemic potential. *Int Wound J*. In press
11. Godlee F. Surviving the long road ahead. *BMJ* 2020;369:m1840
12. Lacobucci G. NHS prioritizes services to restart in the next six weeks. *BMJ* 2020;369:m1793
13. Guo W, Li M, Dong Y, et al. Diabetes is a risk factor for the progression and prognosis of COVID-19. *Diabetes Metab Res Rev*. 31 March 2020 [Epub ahead of print]. DOI: 10.1002/dmrr.3319
14. Shi Q, Zhang X, Jiang F, et al. Clinical characteristics and risk factors for mortality of COVID-19 patients with diabetes in Wuhan, China: a two-center, retrospective study. *Diabetes Care* 2020;43:1382–1391
15. Boulton AJM. The pathway to foot ulceration in diabetes. *Med Clin North Am* 2013;97:775–790
16. Boulton AJM, Armstrong DG, Hardman MJ, et al. *Diagnosis and Management of Diabetic Foot Infections*. Arlington, VA, American Diabetes Association, 2020
17. Boulton AJM. Pyrexia of unknown origin? In *Case Studies in Diabetes*. Betteridge DJ, Ed. London, Martin Dunitz, 2003, p. 205–207
18. Lázaro-Martínez JL, Aragón-Sánchez J, García-Morales E. Antibiotics versus conservative surgery for treating diabetic foot osteomyelitis: a randomized comparative trial. *Diabetes Care* 2014;37: 789–795
19. Li H-K, Rombach I, Zambellas R, et al.; OVIVA Trial Collaborators. Oral versus intravenous antibiotics for bone and joint infection. *N Engl J Med* 2019;380:425–436
20. Salgami EV, Bowling FL, Whitehouse RW, Boulton AJ. Use of tobramycin-impregnated calcium sulphate pellets in addition to oral antibiotics: an alternative treatment to minor amputation in a case of diabetic foot osteomyelitis. *Diabetes Care* 2007;30:181–182
21. Lipsky BA, Senneville É, Abbas ZG, et al.; International Working Group on the Diabetic Foot (IWGDF). Guidelines on the diagnosis and treatment of foot infection in persons with diabetes (IWGDF 2019 update). *Diabetes Metab Res Rev* 2020;36(Suppl. 1):e3280
22. Armstrong DG, Salas P, Short B, et al. Maggot therapy in “lower-extremity hospice” wound care: fewer amputations and more antibiotic-free days. *J Am Podiatr Med Assoc* 2005;95:254–257
23. Rajbhandari SM, Sutton M, Davies C, Tesfaye S, Ward JD. ‘Sausage toe’: a reliable sign of underlying osteomyelitis. *Diabet Med* 2000; 17:74–77
24. Game FL, Jeffcoate WJ. Primarily non-surgical management of osteomyelitis of the foot in diabetes. *Diabetologia* 2008;51:962–967
25. Lindsay JA. *Medical Axioms, Aphorisms and Clinical Memoranda*. New York, Paul B. Hoeber, Inc., 1924. Accessed 9 May 2020. Available from <https://play.google.com/books/reader?id=PiK6AAAAIAAJ&hl=en&pg=GBS.PA1>