

Meningioma Treated with Interferon- α , Evaluated with [^{11}C]-L-Methionine Positron Emission Tomography¹

Carin Muhr,² Olafur Gudjonsson, Anders Lilja, Magdalena Hartman, Zhi-Jia Zhang, and Bengt Långström

Departments of Neurology [C. M., Z.-J. Z.], Neurosurgery [O. G.], Radiology [A. L.], and Pathology [M. H.], and PET Center [B. L.], University Hospital, SE-75185 Uppsala, Sweden

ABSTRACT

Purpose: In meningioma patients with postoperative residual masses, recurrent or primarily inoperable tumors, positron emission tomography (PET) with [^{11}C]-L-methionine was used to evaluate treatment efficacy of IFN- α .

Experimental Design: Twelve patients were treated with IFN- α at a dose of 1.5–5 million IU s.c. daily. PET, computed tomography, and/or magnetic resonance imaging were performed in all patients before and, at regular intervals, during IFN- α treatment. The ratio of tumor hot-spot uptake to cerebellar uptake or to cortex uptake was calculated. This ratio estimates the relative methionine accumulation in the tumor and presumably the proliferative activity in the tumor.

Results: During IFN- α treatment, PET demonstrated a mean relative percentage of reduction in the uptake ratio (MReIR) of 22.3% in the meningiomas. In nine patients who were considered responders, defined as patients with a positive MReIR, the MReIR was 30.4%. For the three nonresponders, defined as patients with a negative MReIR, the MReIR was –1.8%. Three patients were followed for a long time: two patients for 8 years and one patient for 4 years and 6 months; the two patients followed for 8 years are still on IFN. The volumes of these tumors were constant or showed a slight decrease. No correlation was found between histopathological diagnosis (PAD) WHO grading I–III of meningiomas and response to IFN- α treatment.

Conclusions: PET was judged a useful method to predict which patients are suitable for long-term treatment with IFN- α and also for dose finding. In five patients treated from 9 months to 8 years, IFN- α seemed to be an effective oncostatic drug. The clinical usefulness of IFN- α , taking

adverse reactions into account, must be evaluated in a larger series of patients.

INTRODUCTION

Total surgical resection of the meningioma and its associated dural base is the treatment of choice. Further treatment is required for patients with postoperative residual tumor mass, recurrent tumor, multiple tumors, or primarily inoperable tumor (1–3).

Angiostatic treatment for tumors has within recent years become highly interesting because it has been shown that tumors need angiogenesis to be able to grow (4). Several endogenous angiostatic factors, *e.g.*, angiostatin and endostatin, have been identified and demonstrated in animal models to be effective in tumors, and a number of different angiostatic treatments are now being evaluated in clinical trials (5, 6).

The IFNs are glycoproteins belonging to the family of cytokines. They are related to transforming growth factor- β and tumor necrosis factor and play a role in the control of cell growth. The IFNs have been demonstrated to work mainly via angiostatic mechanisms in tumors, and this has increased interest in these substances for tumor treatment (7–13). IFN- α , in particular, has been of interest for the treatment of certain hematological malignancies as well as solid tumors, including craniopharyngiomas (14–16). IFN- α has been reported to have an effect on meningiomas *in vivo* and *in vitro* (17–20).

PET³ is a technique suitable for *in vivo* biochemical characterization of intracranial tumors and for follow-up of medical treatment (21–24). We have demonstrated the potential of PET to evaluate medical therapy in a large series of pituitary adenomas and in some meningiomas (25, 26). In these studies, PET with [^{11}C]-L-methionine in particular has been valuable in delineating tumors and in following the effect of treatment. The uptake of [^{11}C]-L-methionine is related to tumor metabolism, and in our experience with pituitary tumors, we have shown that a marked decrease in the uptake of [^{11}C]-L-methionine in these tumors represents a positive treatment effect (26). Because meningiomas usually are slowly growing tumors, techniques for demonstrating the effect of treatment at an early stage are of special value.

We therefore evaluated treatment efficacy using the PET technique with [^{11}C]-L-methionine in the present series of patients with intracranial meningiomas treated with IFN- α . To our

Received 8/31/00; revised 4/27/01; accepted 5/14/01.

The costs of publication of this article were defrayed in part by the payment of page charges. This article must therefore be hereby marked *advertisement* in accordance with 18 U.S.C. Section 1734 solely to indicate this fact.

¹ This study was supported by The Swedish Medical Research Council, The Söderberg Foundation, and The Selander Foundation.

² To whom requests for reprints should be addressed, at Department of Neuroscience, Neurology, University Hospital SE-75185 Uppsala, Sweden. Phone: 46-18-6110000, ext. 15025; Fax: 46-18-6112635; E-mail: Carin.Muhr@neurologi.uu.se.

³ The abbreviations used are: PET, positron emission tomography; CT, computed tomography; MRI, magnetic resonance imaging; Hs/Ce, ratio of hot-spot uptake to cerebellar uptake; Hs/Ct, ratio of hot-spot uptake to cortex uptake; Ct/Ce, ratio between temporal cortex and cerebellum; ReIR, relative percentage of reduction of tumor [^{11}C]-L-methionine uptake ratio; MReIR, mean ReIR; 95% CI, 95% confidence interval; SLE, systemic lupus erythematoses; PAD, histopathological diagnosis.

Table 1 Clinical data

Patients			Tumor				
No.	Sex	Age (yr)	Localization	No. of operation	PAD	Initial volume (ml)	Operation-to-treatment time interval (yr/month/day)
1	F	45	Skull base ^a	1	WHO I	6	2-09-07
2	F	75	Convexity	4	WHO III	7	>20 years
3	F	51	Skull base	3	WHO I	47	>20 years
4	F	35	Parasagittal	1 ^b	WHO I-(II)	22	2-11-16
5	F	71	Parasagittal	2	WHO II	4	0-08-20
6	F	46	Skull base	4	WHO I	93	2-08-14
7	M	24	Parasagittal	3	WHO I	49	0-11-06
8	M	80	Parasagittal	0	Not operated	32	Not operated
9	M	49	Parasagittal	1 ^c	WHO III	10	0-02-04
10	F	34	Skull base	2	WHO III	8	0-02-05
11	F	78	Parasagittal	0	Not operated	94	Not operated
12	M	87	Parasagittal	0	WHO I ^d	35	Not operated

^a Skull base: tumors located in the skull base with supra- and parasellar and orbital tumor extension to various degrees.

^b Embolizations 2 years and 8 months prior to start of treatment.

^c Stereotactic irradiation 4 years and 11 months prior to start of treatment.

^d Autopsy.

knowledge, no other series of patients with meningiomas treated with IFN- α and followed-up with PET has been reported.

PATIENTS AND METHODS

Twelve patients with meningiomas, 8 females and 4 males, were included in the study. The mean age of the patients was 56 years (range, 24–87 years) when IFN treatment was started. Nine of the patients had been treated with surgery. Of these, two patients had been operated on twice, two patients had been operated on three times, and two patients four times. Three patients (age, 78, 80, and 87 years, respectively) had not been operated on because of their physical condition. Many of the 12 patients were severely ill from their tumors, and the IFN α treatment was a last trial to improve their situation. See Table 1 for details regarding the clinical features of the patients.

Clinical. All of the patients were examined clinically, including complete neurological and neuroophthalmological examination.

CT and MRI. All patients were examined in a standardized manner with CT and/or MRI (with and without contrast enhancement) before and at regular intervals during IFN- α treatment. The same neuroradiologist evaluated all CT and MRI examinations.

Estimation of the initial tumor volume was made by measuring its three largest perpendicular diameters, assuming an ellipsoid shape, although most tumors had a more irregular outline.

PET. [¹¹C]-L-Methyl-methionine with a high specific activity was synthesized. The radiochemical purity was tested in each batch (27). The tracer substance was given in doses of 50–200 MBq as an i.v. bolus injection in an antecubital vein. PET with [¹¹C]-L-methionine was performed in all patients before and at least 7 days after the start of treatment or a change in IFN- α dose.

All patients were examined at least once before the start of treatment. Follow-up PET examinations were undertaken regularly 2–4 weeks after the initiation of, and after changes in,

IFN- α treatment. At least two examinations were performed in every patient, with a mean of 5.4 examinations/patients.

Nine of the patients were examined with a PET camera type PC 384-3B and five patients with a PET camera type GEMS 2048B; two patients were examined with both cameras (28).

The PET studies were performed as dynamic examination sequences with 10–15 scans obtained over 20–40 min, starting immediately after a rapid i.v. bolus injection of the tracer substance. The scanning times were successively increased from 1 to 5 min. The PET unit Scanditronix PC-384-3B simultaneously produced three slices with a slice thickness and spacing of ~11 and 14 mm, respectively. Its plane resolution was 8 mm full-width half maximum. The PET unit GEMS 2048B simultaneously produced 15 slices with a slice thickness and spacing of ~6.5 mm, respectively. The spatial resolution was 5 mm full-width half maximum. For the attenuation correction, an automatic contour-finding algorithm was used in both scanners (29). Before the study in the Scanditronix PC-384-3B PET unit, a CT examination was performed with an individual head fixation system to select the appropriate sections for PET studies. The same fixation device was then used to position the patient during the PET study.

One region of interest was selected in the PET images to represent tumor tissue in the slice where the tumor had its “hot spot” [defined as the 10 adjacent picture elements, *i.e.*, $(2.5 \times 2.5 \times 6.5 \text{ mm}^3) = 0.4 \text{ ml}$ with the highest activity in the tumor], and another in normal cerebellum (eight patients) or the contralateral temporal cortex (four patients) where the cerebellum was not included in the slices. These regions of interest were outlined manually with a cursor.

The quantitative analysis was performed by calculating the Hs/Ce or Hs/Ct ratio. The average Hs/Ce or Hs/Ct ratio was evaluated from images taken >10 min after the tracer injection for the PC 384-3B scans and 14–34 min for the GEMS 2048B. This ratio represents an estimate of the relative methionine accumulation in the tumor.

Table 2 Treatment data

Patient no.	IFN dose ($\times 10^6$ IU/day)	Observation interval (yr/month/day)	Treatment interval (yr/month/day)	No. of PET scans
1	2.5-5	8-00-00	8-00-00	7
2	5	0-02-17	0-02-13	4
3	3-5	0-00-28	0-00-26	3
4	2.5-3-5	8-00-00	8-00-00	10
5	5	0-05-01	0-04-01	6
6	2.5-4-5	4-06-20	4-06-20	15
7	5	1-00-13	0-10-07	7
8	2.5	0-06-17	0-03-04	4
9	5	0-08-26	0-08-26	3
10	5	0-01-21	0-00-09	2
11	5	0-00-21	0-00-13	2
12	1.5-2.5-4	0-00-21	0-00-20	2

Histopathology. The same neuropathologist reevaluated the routine histology according to the WHO classification from eight tumor specimens collected during operations prior to the study (30). One tumor specimen (patient 3) was not found for reevaluation, but the initial evaluation was WHO I. Three patients had not been operated on, but the autopsy in one (patient 12) showed WHO grade I. The meningioma diagnoses in the latter patients were judged to be certain because they presented with typical clinical, CT, MRI, and PET findings.

Treatment. The patients were treated with recombinant IFN- α at a dose of 1.5–5 million IU s.c. daily. The initial dose was usually 1.5–3 million IU for 2–6 weeks and was, if tolerated, increased thereafter to 5 million IU s.c. daily. The mean observation period was 2 years (range, 21 days to 8 years). The observation period was defined as the period from the first to the last PET study. The mean treatment period was 21 months (range, 9 days to 7 years). When a PET study was performed, a patient was regarded as being on treatment if at least 7 days had elapsed since initiation of the treatment and as being off treatment if at least 7 days had elapsed since treatment was withdrawn (Table 2).

Calculations. To evaluate the degree of reduction of [^{11}C]-L-methionine uptake in the tumor during treatment, we used the formula:

Relative percentage of reduction in tumor

$$\begin{aligned} \text{[}^{11}\text{C}\text{]-L-Methionine uptake ratio} &= \text{ReIR} \\ &= \frac{(\text{IR} - \text{mean of treatment ratios})}{\text{IR}} \times 100 \end{aligned}$$

where IR is the initial ratio, and the uptake ratio is the ratio Hs/Ce or Hs/Ct.

Tumor volume was estimated using the formula:

$$\text{Volume} = \pi \times 4/3 \times X/2 \times Y/2 \times Z/2$$

where X, Y, and Z are the maximum tumor dimensions in three planes.

Statistical Methods. For each patient, the ReIR value was tested for significance using a *t* test (against zero) of the difference between the initial value and the mean of the treatment values. The Kendall nonparametric correlation coefficient was used to measure the correlation between tumor hot-spot

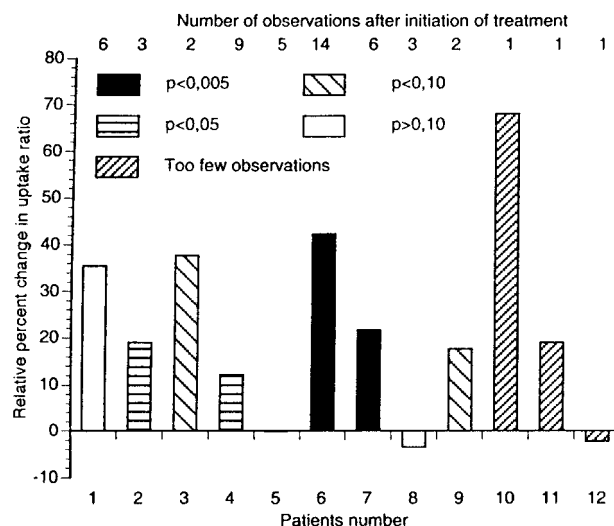


Fig. 1 Relative percentage of change in tumor [^{11}C]-L-methionine uptake ratio (ReIR). Positive values denote a reduction of the ReIR during treatment; negative values indicate increased methionine uptake during treatment. *Ps* refer to a test of the difference between the initial value and the mean of treatment values against zero in each individual patient.

uptake, cerebellar uptake (Hs/Ce), and temporal cortex/cerebellum (Ct/Ce). The sign test was used to evaluate the effect of dose change on the tumor hot-spot uptake.

RESULTS

For [^{11}C]-L-methionine PET, the MReIR was 22.3% (95% CI, 9.1–35.6%) for all patients.

Tumors with a positive ReIR were defined as metabolically reactive. Those with a negative reduction, *i.e.*, an increased uptake ratio during treatment, were labeled metabolically nonreactive. In the nine patients who were considered to have metabolically reactive tumors, the MReIR was 30.4% (95% CI, 16.9–43.9%). In the three metabolically nonreactive tumors, the MReIR was -1.8% (95% CI, -7.0 to 3.4%).

Figs. 1 and 2 give obvious visual justification for the subdivision of patients into a “metabolically reactive tumor group” and a “metabolically nonreactive tumor group.”

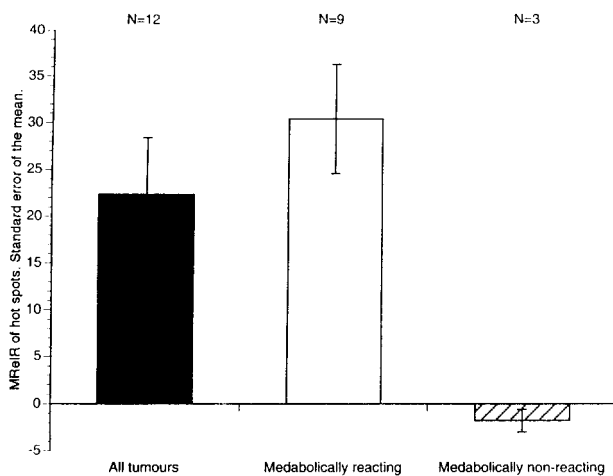


Fig. 2 MRelR in all tumors and two subgroups. Metabolically reactive tumors (*Metabolically reacting*) are defined as tumors with a positive relative percentage of reduction in tumor [^{11}C]-L-methionine uptake ratio (RelR) and metabolically nonreactive tumors (*Metabolically non-reacting*) are defined as tumors with a negative RelR, *i.e.*, those in which the methionine uptake increased during therapy.

In one patient (patient 3), we observed an increased effect on tumor metabolism from IFN- α up to a dose of 5 million IU s.c. daily but a slightly smaller effect at a dose of 8 million IU s.c. daily (Fig. 3).

Three patients (patients 1, 4, and 6) had a long follow-up: two were followed for 8 years, and one was followed for 4 years and 6 months. The MRelR was 30% (95% CI, 9.1–69.2%) for those three patients. The volumes of the tumors were constant or showed a slight decrease. In one of these patients (patient 6), the dose of IFN- α was decreased by 50% after 2 years of treatment. However, after an additional year, a moderate elevation of methionine uptake was observed. The dosage was increased, and the methionine uptake decreased again. Because this patient developed SLE-like symptoms, the IFN- α was withdrawn. However, 1 year later MRI demonstrated considerable tumor progression, and PET with [^{11}C]-L-methionine showed increased uptake in the tumor (Fig. 4).

In three patients (patients 1, 4, and 6), the Ct/Ce ratio was measured to study stability over time of the uptake ratio in nontumor tissue. As is obvious from Table 3, the variance of the Ct/Ce ratio over time was a small fraction of the variance of the Hs/Ce ratio. This was partly because the Ct/Cs ratio is very stable over time and partly because of the effect of the numerous changes of treatment on the Hs/Ce ratio.

The correlation between the Hs/Ce and Ct/Ce ratios was calculated in seven patients, four of whom did not belong to this study. A positive correlation as measured by Kendall's nonparametric correlation coefficient was found in only two cases, but the *P*s were far from significance. This finding is quite compatible with the interpretation that the Hs/Ce ratio mainly reflects changes in methionine uptake in the tumor and not in the surrounding brain.

Assuming that IFN reduces the Hs/Ce ratio when administered daily for at least 7 days and that this effect has mainly disappeared after withdrawal of the drug for at least 7 days, it is

possible to test statistically whether changes in the Hs/Ce ratio depend on changes in the IFN medication. A change in the expected direction is defined as a reduced Hs/Ce or Hs/Ct ratio after initiation of IFN therapy or an increase of the dose. Inversely, an increased ratio would follow a reduction of the dose or withdrawal of the drug.

When we considered all 12 patients described in Table 2, 22 of 30 (0.73) changes in the IFN dosage were associated with a change of the Hs/Ce or Hs/Ct ratio in the expected direction. This ratio differs significantly ($P < 0.02$) from 0.5, the value expected by chance. When we restricted the analyses to the nine metabolically reactive tumors, the corresponding values were 21 of 26 (0.81; $P < 0.002$).

Of the nine patients with a positive PET methionine response, three patients had received very long-term treatment with IFN- α : two patients received treatments for 8 years (patients 1 and 4), and one patient had received treatment for 4.5 years (patient 6); during this time, tumor size remained stable. The two patients with the 8-year treatment period are still on IFN- α treatment; one of them has a tumor of considerable size. The third patient showed stable tumor size and decreased PET methionine during the IFN- α treatment periods compared with before treatment. When IFN was stopped because of side effects, the tumor progressed and increased [^{11}C]-L-methionine uptake was observed. When IFN- α was reintroduced, tumor progression stopped and a decrease in [^{11}C]-L-methionine was again achieved. The patient later died from intracranial hemorrhage.

One patient (patient 10) had rapid tumor growth before the start of IFN- α treatment; the tumor became stable during treatment and showed decreased [^{11}C]-L-methionine uptake, but the patient also received irradiation therapy in parallel. Unfortunately, however, the patient later died from irradiation reactions.

Three patients (patients 2, 3, and 11) with positive PET response were severely ill, and only short-term treatment was possible. One patient (patient 7) with neurofibromatosis II and positive PET response was treated for 1 year, during which tumor size stable remained stable, and died 7 years later from his tumors. The ninth patient with positive PET response had such poor compliance that IFN treatment had to be stopped, and the patient underwent additional surgery. Of the three patients with no response on PET methionine, one (patient 5) was kept on IFN for 6 months, but there was no PET response and IFN was stopped because the tumor progressed. The patient died 1 month later from her tumor. In this patient, IFN apparently had no effect. One other patient with no PET response was treated for only a short time, 1 month and 12 days, and died 1.5 months later from his tumor. The third patient (patient 12) was treated with IFN, but PET showed no response and the IFN was stopped; the patient died in a ferry accident soon afterward. During the follow-up time, no tumor progression was seen.

No correlation was found between the PAD grading of the meningiomas into I–III and response to IFN- α treatment.

Most of the patients reacted with moderate fever and/or fatigue during the first week of treatment. A few patients experienced a continued moderate fatigue, but were kept on medication for various periods. Almost all patients reacted with a moderate leukopenia, but this did not lead to further complications.

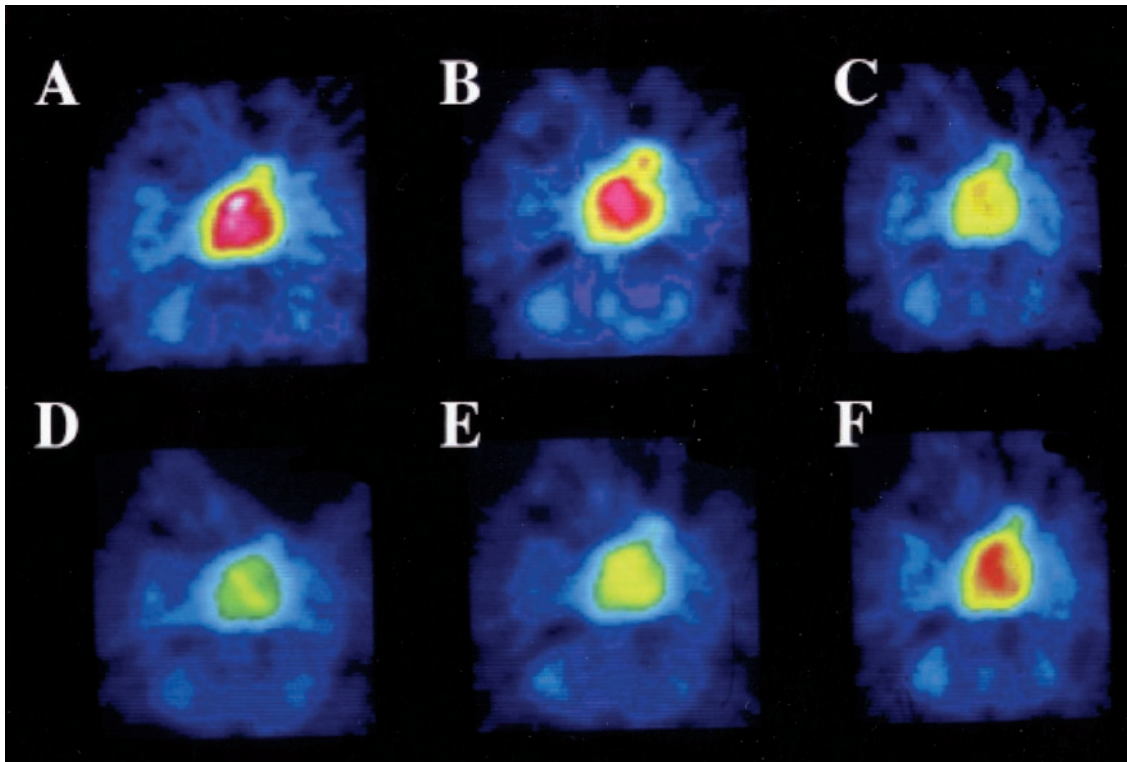


Fig. 3 $[^{11}\text{C}]$ -L-Methionine PET of patient 3 at different doses of IFN- α , demonstrating a successively increased effect up to 5 million IU s.c. daily (D) but less effect at 8 million IU s.c. daily (E). A, before treatment. B and C, decreased methionine uptake at 3 million IU of IFN s.c. daily. B, 6% decrease after 2 days; C, 29% decrease after 2 weeks. D, further decreased methionine (47%) after 5 million IU of IFN s.c. daily for 2 weeks. E, slightly less effect (38% decrease) after 8 million IU of IFN s.c. for 2 weeks. F, almost resumed methionine uptake after IFN was withdrawn.

One patient (patient 10) was irradiated in parallel with the IFN- α treatment because of fast-growing recurrent malignant meningioma. This patient died from a severe irradiation reaction in the brainstem. (See Table 4 for further details.) However, the two patients (patients 1 and 4) with the longest follow-up time (8 years each) are still on IFN- α treatment. Their tumors remain stable and with continued decreased methionine uptake. These patients are tolerating their treatment well.

DISCUSSION

In this series of 12 patients with recurrent, often malignant, meningiomas that were treated with IFN- α administered as a daily s.c. dose of 1.5–5 million IU and monitored by $[^{11}\text{C}]$ -L-methionine PET, our results demonstrate that (a) IFN- α treatment was effective in reducing tumor metabolism in 9 of 12 patients with meningiomas, without correlation with PAD grading; (b) PET using $[^{11}\text{C}]$ -L-methionine was a sensitive method to evaluate the metabolic effect of IFN- α treatment in the meningiomas; and (c) $[^{11}\text{C}]$ -L-methionine uptake in the tumor was not correlated with uptake in the normal brain.

In tumor treatment, it is of interest to demonstrate decreased tumor metabolism as a sign of decreased tumor growth but not necessarily a sign of diminished tumor volume. This issue has been discussed in connection with IFN- α treatment of carcinoid. After IFN- α treatment, these tumors were observed at biopsy to be changed into fibrous-rich tissue with less viable

tumor cells but not decreased in tumor size compared with before IFN- α treatment (31). This type of effect in tumor tissue would readily be observed by $[^{11}\text{C}]$ -L-methionine PET (Fig. 5).

Because the three patients who were treated and followed for a period of 4.5–8 years (patients 1, 4, and 6) and another two (patients 7 and 9) who were followed for 9–10 months showed no increase in tumor volume, it can be assumed that IFN- α treatment is effective in controlling tumor growth even during long-term treatment. This needs to be verified in a larger patient population.

In the patient who was examined at different doses of IFN- α , it was of interest to observe that the effect increased up to 5 million IU s.c. daily but showed a smaller effect at 8 million IU s.c. daily (Fig. 3). This finding is in accordance with the viewpoint that IFN should be given in a low-moderate dose (32).

In one of these patients (patient 6), a reduced dose of IFN- α after 2 years of treatment led to a moderate elevation of the methionine uptake after an additional year and was followed by a decrease in methionine uptake when the dose was again increased. When the patient developed SLE-like symptoms, IFN- α was withdrawn; subsequently, considerable tumor progression was seen on MRI, and PET with $[^{11}\text{C}]$ -L-methionine demonstrated increased uptake in the tumor. When IFN- α was reintroduced, a decrease in methionine uptake as measured by PET was achieved, and tumor progression stopped. This patient

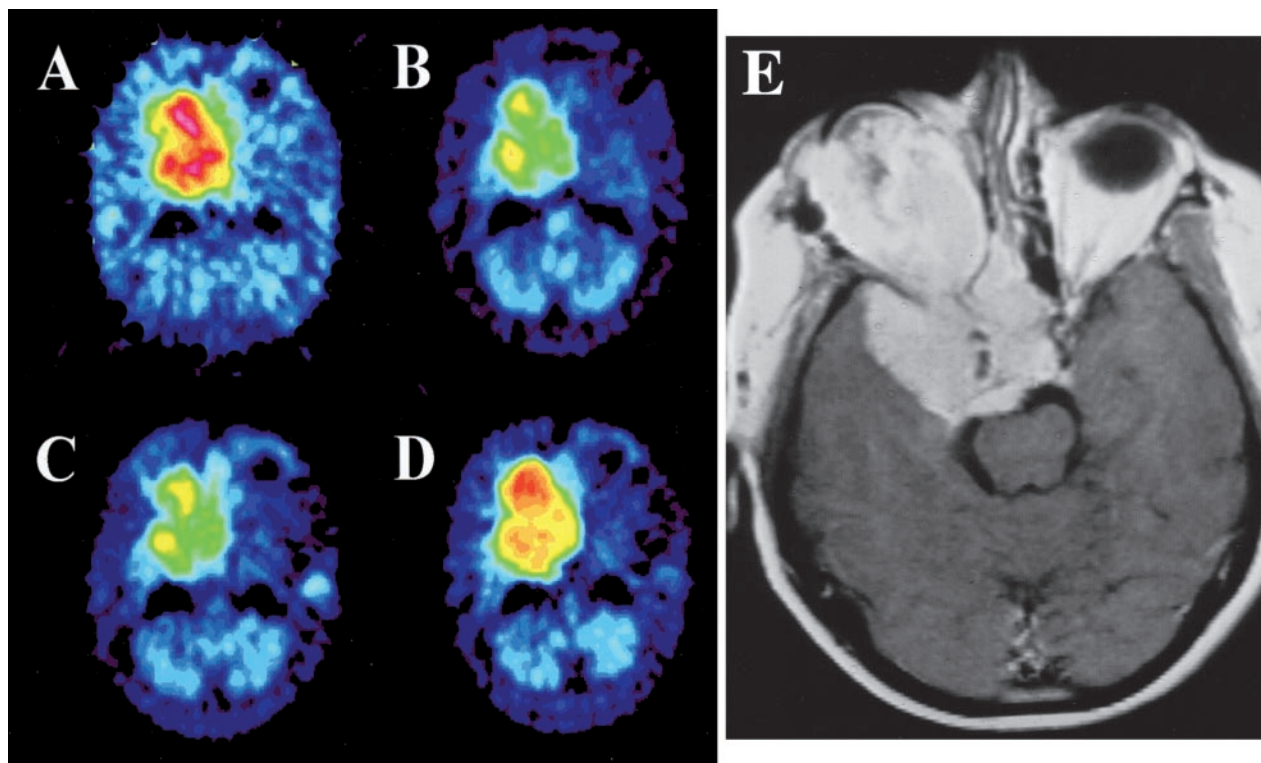


Fig. 4 PET analysis for patient 6. A, before treatment. B, decreased methionine uptake after treatment with IFN-α for 42 months and 24 days. C, decreased methionine uptake before withdrawal of IFN-α treatment after 54 months and 20 days. D, increased methionine uptake 11 months and 10 days after withdrawal of treatment. E, MR image in axial projection demonstrating the large skull base meningioma with tumor growth extending into the orbit.

Table 3 Comparison of the variance over time of Ct/Ce and Hs/Ce ratios during treatment in three patients

Patient no.	N1 ^a	N2 ^b	Variance ratio ^c
1	4	4	0.004
4	6	5	0.02
6	14	6	0.01

^a N1, number of estimates of the Hs/Ce ratio.

^b N2, number of estimates of the Ct/Ce ratio.

^c Variance ratio = $\frac{\text{Variance of Ct/Ce ratios}}{\text{Variance of Hs/Ce ratios}}$

exemplifies the dependency of control of tumor metabolism and growth on ongoing IFN-α treatment (Fig. 4).

The antitumoral effect of IFN-α has within the recent years been demonstrated to be exerted mainly via inhibition of angiogenesis (7–11). IFN had earlier been shown to influence cell proliferation and differentiation (14, 18, 19, 33, 34). It may act via immunomodulatory mechanisms and induce apoptotic cell death (35). IFN in combination with cytotoxic drugs in the treatment of solitary tumors that showed little or no response to either type of drug given as monotherapy has shown a modulator effect on the antiproliferative and cytotoxic effect of different chemotherapeutic drugs (36–38). IFN-α in combination with 5-fluorouracil *in vitro* has shown promising effects on cultured meningioma cells (39).

Table 4 Side effects

Patient no.	Symptom
1	Fatigue
2	Akinesia/apathy; fever
3	Fatigue; temporalis arteritis
4	Fatigue/fever; leukopenia/alopecia
5	
6	Leukopenia/fatigue; SLE
7	Leukopenia; thrombocytopenia
8	Leukopenia; depression
9	Fever
10	CNS ^a irradiation late damage
11	Apathy
12	Fatigue; leukopenia

^a CNS, central nervous system.

The side effects of IFN-α observed in these studies were mostly those known earlier (fever, fatigue, leukopenia, and psychiatric symptoms; Table 4; Ref. 40).

One female patient (patient 10) with a malignant recurrent skull base meningioma received IFN-α and irradiation simultaneously. This patient died from irradiation lesions in the brain stem; a possible increased sensitivity to irradiation in combination with IFN-α could have caused this (41). Combined treatment of this kind should therefore be avoided as long as it is not possible to predict the effect.

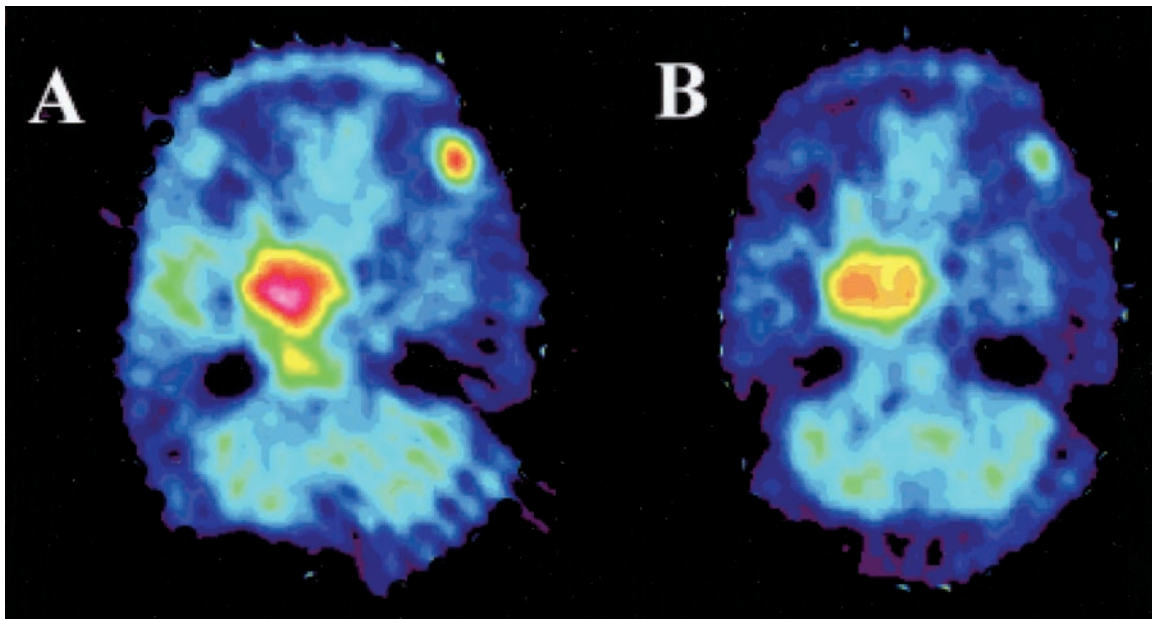


Fig. 5 PET for patient 10. A, before start of treatment with IFN- α . B, considerable decrease in methionine uptake after 9 days of treatment with IFN- α .

We have also treated patients with multiple intracranial meningiomas, which is one patient group where there is a strong need for further treatment alternatives. One of these patients who had 11 intracranial meningiomas of different sizes, 1 of which was verified at biopsy, was treated with IFN- α at 3 million IU s.c. daily. The patient is still on treatment, and the follow-up time has been 9 years. All of the tumors have remained stable in volume, and the methionine uptake is decreased compared with before treatment. When we analyzed methionine uptake in the multiple tumors during IFN treatment, the decrease in metabolism differed between the tumors in the same patient. To simplify the statistics in the total evaluation, we therefore only included patients with single tumors. We, however, think it is of interest to report on this patient with multiple meningiomas because especially these patients with multiple meningiomas who might not be suitable for other treatment regimes could thus benefit from IFN treatment.

We consider PET to be the most valuable method presently available to predict positive response to IFN- α and that long-term treatment is possible with continued positive response. A method such as PET is very valuable to predict tumor response, especially in slow-growing tumors without other markers for tumor response. This is especially true when the treatment is demanding for the patient, with daily injections, and also is costly.

Our results indicate that IFN- α can be an effective onco-static treatment for certain patients with postoperative residual tumor masses, recurrent tumors, multiple tumors, or primarily inoperable meningiomas. The effect of the therapy seems to be sustained during long periods of treatment. PET using [^{11}C]-L-methionine can be used to predict which patients will respond to IFN- α treatment and to define the lowest effective dose. How-

ever, because of the side effects in long-term treatment, our experiences have been limited to a few patients, and the clinical usefulness of IFN- α must be evaluated in a larger series of patients.

ACKNOWLEDGMENTS

We express our thanks to honorate doctorate Carl-Einar Westerberg (Uppsala, Sweden) for valuable support.

REFERENCES

- Rachlin, J. R. Etiology and biology of meningiomas. *In*: O. Al-Mefty, (ed.), Meningiomas, pp. 27–35. New York: Raven Press, 1991.
- Philippon, J. The recurrence of meningiomas. *In*: O. Al-Mefty, (ed.), Meningiomas, pp. 87–105. New York: Raven Press, 1991.
- Mathiesen, T., Lindquist, C., Kihlstrom, L., and Karlsson, B. Recurrence of cranial base meningiomas. *Neurosurgery*, 39: 2–7, 1996.
- Hanahan, D., and Folkman, J. Patterns and emerging mechanisms of the angiogenic switch during tumorigenesis. *Cell*, 86: 353–364, 1996.
- Gastl, G., Hermann, T., Steurer, M., Zmija, J., Gonsilius, E., Unger, C., and Kraft, A. Angiogenesis as a target for tumor treatment. *Oncology*, 54: 177–184, 1997.
- Harris, A. L. Antiangiogenesis for cancer therapy. *Lancet*, 349 (Suppl. 2): SIII3–SIII5, 1997.
- Dinney, C. P., Bielenberg, D. R., Perrotte, P., Reich, R., Eve, B. Y., Bucana, C. D., and Fidler, I. J. Inhibition of basic fibroblast growth factor expression, angiogenesis, and growth of human bladder carcinoma in mice by systemic interferon- α administration. *Cancer Res.*, 58: 808–814, 1998.
- Maheshwari, R. K., Srikantan, V., Bhartiya, D., Kleinman, H. K., and Grant, D. S. Differential effects of interferon γ and α on *in vitro* model of angiogenesis. *J Cell Physiol.*, 146: 164–169, 1991.
- Sidky, Y. A., and Borden, E. C. Inhibition of angiogenesis by interferons: effects on tumor- and lymphocyte-induced vascular responses. *Cancer Res.*, 47: 5155–5161, 1987.

10. Singh, R. K., Gutman, M., Bucana, C. D., Sanchez, R., Llansa, N., and Fidler, I. J. Interferons α and β down-regulate the expression of basic fibroblast growth factor in human carcinomas. *Proc. Natl. Acad. Sci. USA*, *92*: 4562–4566, 1995.
11. Ricketts, R. R., Hatley, R. M., Corden, B. J., Sabio, H., and Howell, C. G. Interferon- α -2a for the treatment of complex hemangiomas of infancy and childhood. *Ann. Surg.*, *219*: 605–612, discussion 612–614, 1994.
12. Baron, S. *The Interferon System. A Current Review to 1987*. Austin, TX: University of Texas Press, 1987.
13. Baron, S., Tyring, S. K., Fleischmann, W. R., Jr., Coppenhaver, D. H., Niesel, D. W., Klimpel, G. R., Stanton, G. J., and Hughes, T. K. The interferons. Mechanisms of action and clinical applications [see comments]. *JAMA*, *266*: 1375–1383, 1991.
14. Dorr, R. T. Interferon- α in malignant and viral diseases. A review. *Drugs*, *45*: 177–211, 1993.
15. Itri, L. M. The interferons. *Cancer (Phila.)*, *70*: 940–945, 1992.
16. Jakacki, R. I., Cohen, B. H., Jamison, C., Mathews, V. P., Arenson, E., Longee, D. C., Hilden, J., Cornelius, A., Needle, M., Heilman, D., Boaz, J. C., and Luerssen, T. G. Phase II evaluation of interferon- α -2a for progressive or recurrent craniopharyngiomas. *J. Neurosurg.*, *92*: 255–260, 2000.
17. Kaba, S. E., DeMonte, F., Bruner, J. M., Kyritsis, A. P., Jaeckle, K. A., Levin, V., and Yung, W. K. The treatment of recurrent unresectable and malignant meningiomas with interferon α -2B. *Neurosurgery*, *40*: 271–275, 1997.
18. Koper, J. W., Zwarthoff, E. C., Hagemeyer, A., Braakman, R., Avezaat, C. J., Bergstrom, M., and Lamberts, S. W. Inhibition of the growth of cultured human meningioma cells by recombinant interferon- α . *Eur. J. Cancer*, *27*: 416–419, 1991.
19. Zhang, Z. J., Muhr, C., and Wang, J. L. Interferon- α inhibits the DNA synthesis induced by PDGF and EGF in cultured meningioma cells. *Anticancer Res.*, *16*: 717–723, 1996.
20. Wober Bingol, C., Wober, C., Marosi, C., and Prayer, D. Interferon- α -2b for meningioma. *Lancet*, *345*: 331, 1995.
21. Jansson, T., Westlin, J. E., Ahlstrom, H., Lilja, A., Langstrom, B., and Bergh, J. Positron emission tomography studies in patients with locally advanced and/or metastatic breast cancer: a method for early therapy evaluation? *J. Clin. Oncol.*, *13*: 1470–1477, 1995.
22. Sonoda, Y., Kumabe, T., Takahashi, T., Shirane, R., and Yoshimoto, T. Clinical usefulness of ^{11}C -MET PET and ^{201}Tl SPECT for differentiation of recurrent glioma from radiation necrosis. *Neurol. Med. Chir. (Tokyo)*, *38*: 342–347, discussion 347–348, 1998.
23. Voges, J., Herholz, K., Holzer, T., Wurker, M., Bauer, B., Pietrzyk, U., Treuer, H., Schroder, R., Sturm, V., and Heiss, W. D. ^{11}C -Methionine and ^{18}F -2-fluorodeoxyglucose positron emission tomography: a tool for diagnosis of cerebral glioma and monitoring after brachytherapy with ^{125}I seeds. *Stereotact. Funct. Neurosurg.*, *69*: 129–135, 1997.
24. Wurker, M., Herholz, K., Voges, J., Pietrzyk, U., Treuer, H., Bauer, B., Sturm, V., and Heiss, W. D. Glucose consumption and methionine uptake in low-grade gliomas after iodine-125 brachytherapy. *Eur. J. Nucl. Med.*, *23*: 583–586, 1996.
25. Muhr, C. PET in neuroendocrinology. *In*: C. D. F. F. Casanueva (ed.), *Recent Advance in Basic and Clinical Neuroendocrinology*, pp. 313–319. Amsterdam: Elsevier Science Publishers B.V. (Biomedical Division), 1989.
26. Muhr, C. Positron emission tomography applied in the study of pituitary adenomas. *J. Endocrinol. Investig.*, *14*: 509–528, 1991.
27. Långström, B. Synthesis of L-, and D-(methyl- ^{11}C) methionine. *J. Nucl. Med.*, *28*: 1037–1040, 1987.
28. Holte, S., Eriksson, L., and Dahlbom, M. A preliminary evaluation of the Scanditronix PC2048-15B brain scanner. *Eur. J. Nucl. Med.*, *15*: 719–721, 1989.
29. Bergstrom, M., Litton, J., Eriksson, L., Bohm, C., and Blomqvist, G. Determination of object contour from projections for attenuation correction in cranial positron emission tomography. *J. Comput. Assist. Tomogr.*, *6*: 365–372, 1982.
30. WHO Classification of Tumor of the Central Nervous System, 2nd Ed. Berlin: Springer-Verlag, 1993.
31. Andersson, T., Wilander, E., Eriksson, B., Lindgren, P. G., and Oberg, K. Effects of interferon on tumor tissue content in liver metastases of human carcinoid tumors. *Cancer Res.*, *50*: 3413–3415, 1990.
32. Slaton, J. W., Perrotte, P., Inoue, K., Dinney, C. P., and Fidler, I. J. Interferon- α -mediated down-regulation of angiogenesis-related genes and therapy of bladder cancer are dependent on optimization of biological dose and schedule. *Clin. Cancer Res.*, *5*: 2726–2734, 1999.
33. Clemens, M. J. Regulation of cell proliferation and differentiation by interferons. *Biochem. J.*, *226*: 345–360, 1985.
34. Friedman, R. M., Grimley, P., and Baron, S. Biological effects of the interferons and other cytokines. *Biotherapy*, *8*: 189–198, 1996.
35. Vedantham, S., Gamliel, H., and Golomb, H. M. Mechanism of interferon action in hairy cell leukemia: a model of effective cancer biotherapy. *Cancer Res.*, *52*: 1056–1066, 1992.
36. Buzaid, A. C., and Legha, S. S. Combination of chemotherapy with interleukin-2 and interferon- α for the treatment of advanced melanoma. *Semin. Oncol.*, *21*: 23–28, 1994.
37. Richner, J., Joss, R. A., Goldhirsch, A., and Brunner, K. W. Phase II study of continuous subcutaneous interferon- α combined with cisplatin in advanced malignant melanoma. *Eur. J. Cancer*, *28A*: 1044–1047, 1992.
38. Wadler, S. The role of interferons in the treatment of solid tumors. *Cancer (Phila.)*, *70*: 949–958, 1992.
39. Zhang, Z. J., Wang, J. L., Muhr, C., and Smits, A. Synergistic inhibitory effects of interferon- α and 5-fluorouracil in meningioma cells *in vitro*. *Cancer Lett.*, *100*: 99–105, 1996.
40. Jones, G., and Itri, L. Safety and tolerance of recombinant interferon α -2a (Roferon-A) in cancer patients. *Cancer (Phila.)*, *57*: 1709–1715, 1986.
41. Hagberg, H. Does α -interferon in conjunction with radiotherapy increase the risk of complications in the central nervous system? *Ann Oncol.*, *1*: 449–451, 1990.