

# Genetic Changes in Paired Atypical and Usual Ductal Hyperplasia of the Breast by Comparative Genomic Hybridization<sup>1</sup>

Gyungyub Gong, Sandy DeVries, Karen L. Chew, Imok Cha, Britt-Marie Ljung, and Frederic M. Waldman<sup>2</sup>

Cancer Center [S. D., K. C., F. M. W.] and Departments of Pathology [I. C., B-M. L.] and Laboratory Medicine [F. M. W.], University of California San Francisco, San Francisco, California 94143-0808, and Department of Pathology, Asan Medical Center, University of Ulsan College of Medicine, Seoul, Korea 138-736 [G. G.]

## ABSTRACT

**Purpose:** Breast cancer is thought to develop from non-invasive precursor lesions, although the earliest steps of neoplastic transformation are still undefined. Usual ductal hyperplasia (UDH) is considered to represent a benign proliferation of ductal epithelial cells, whereas atypical ductal hyperplasia (ADH) may represent the first clonal neoplastic expansion of these cells. The aim of this study was to examine genetic alterations in UDH and ADH and to determine the relationship between these lesions in the same breast biopsy.

**Experimental Design:** Comparative genomic hybridization analysis was used to define copy number alterations in DNA extracted from archival sections of 18 patients. Nine patients showed ADH with adjacent UDH, and nine showed pure UDH. None showed evidence of invasive cancer or ductal carcinoma *in situ*.

**Results:** Five of the nine ADH lesions showed chromosome copy number alterations. 16q loss (five cases) and 17p loss (two cases) were the most frequent changes. The associated UDH lesions in these five patients also showed copy number alterations, always a subset of the changes present in the paired ADH. In one other patient, the UDH showed eight chromosomal alterations, whereas the paired ADH showed no changes. Only one of nine cases with pure UDH showed comparative genomic hybridization abnormalities.

**Conclusions:** These data support the likelihood that UDH is a precursor of ADH, at least in some cases representing neoplastic growth. The frequencies of 16q and 17p losses suggest that alterations of candidate genes located in these chromosomal regions may play a role early in breast carcinogenesis.

## INTRODUCTION

Ductal breast carcinoma is thought to evolve through a sequential progression from normal to proliferative epithelium, to *in situ* carcinoma, and finally to invasive disease. UDH,<sup>3</sup> observed in 26% of benign breast biopsies, is associated with a mildly elevated risk for subsequent breast cancer (relative risk = 1.6), whereas ADH, identified in only 4% of benign biopsy specimens, is associated with a higher risk for subsequent cancer (relative risk = 4.4 for the general population; Refs. 1, 2). Previous studies of proliferative ductal lesions presenting in the absence of *in situ* or invasive cancer have shown a low frequency of genetic alterations (defined by LOH) in UDH, with increased numbers of alterations in ADH (3–7). The significance of UDH as a precursor to ADH is unknown. It may represent a field defect in the individual patient or a direct precursor of ADH and eventual carcinoma. In this study, we use CGH to identify clonal alterations in UDH and ADH appearing in the same breast biopsy.

## MATERIALS AND METHODS

**Tissue Samples.** Archival samples from 18 patients were collected from the Departments of Pathology at the University of California San Francisco and California Pacific Medical Center. The study was approved by the Institutional Review Board. Nine patients showed ADH with adjacent UDH (group I), and nine showed pure UDH (group II). None of the patients in either group showed DCIS or invasive cancer in the biopsy specimen. Five of the group I patients were biopsied by needle localization based on abnormal mammographic findings, whereas the remainder were biopsied for suspicious masses. For group II patients, all needle-localized biopsies performed at the University of California San Francisco over a period of 4 years were reviewed, and nine showing UDH with no evidence of ADH were selected. Patients ranged in age from 36 to 65 years. Follow-up was available for five of the nine ADH group I patients (mean, 2.6 years) and seven of the nine UDH group II patients (mean, 5.1 years; Table 1).

Each case was reviewed independently by four pathologists (G. G., F. W., I. C., B-M. L.), and only those cases that all four pathologists agreed on unanimously as ADH or UDH were used. For the definitions of ADH and UDH, criteria published by Page *et al.* (8) were used. ADH was defined as a ductal lesion in which the epithelial cells displayed cytological atypia similar to the cytological features of one of the nonnecrotic variants of DCIS. This pattern typically showed monotonous, rounded epithelial cells with an increased nuclear/cytoplasmic ratio, with round, often centrally located nuclei, not necessarily displaying

Received 1/16/01; revised 3/14/01; accepted 4/30/01.

The costs of publication of this article were defrayed in part by the payment of page charges. This article must therefore be hereby marked *advertisement* in accordance with 18 U.S.C. Section 1734 solely to indicate this fact.

<sup>1</sup> Supported by National Cancer Institute Grant PO1 CA44768 and the Komen Foundation (2000-378).

<sup>2</sup> To whom requests for reprints should be addressed, at UCSF Cancer Center, San Francisco, CA 94143-0808. Phone: (415) 476-3821; Fax: (415) 476-8218; E-mail: waldman@cc.ucsf.edu.

<sup>3</sup> The abbreviations used are: UDH, usual ductal hyperplasia; ADH, atypical ductal hyperplasia; LOH, loss of heterozygosity; CGH, comparative genomic hybridization; DCIS, ductal carcinoma *in situ*.

Table 1 Clinical summary

Cases <sup>a</sup>	Age (yr)	Presentation	Follow-up (months)
<b>Group I</b>			
1	43	Mass	6; alive, NED <sup>b</sup>
2	52	Mass	Lost to FU <sup>c</sup>
3	60	Mammography	Lost to FU
4	70	Mammography	DCIS at 24 months
5	58	Mammography	Alive; NED at 36 months Died of renal disease, 24 months; NED
6	49	Mass	Lost to FU
7	86	Mammography	6; alive, NED
8	65	Mass	84; alive, NED
9	58	Mammography	Lost to FU
<b>Group II</b>			
1	65	Mammography	72; alive, NED
2	44	Mammography	70; alive, NED
3	53	Mammography	65; alive, NED
4	63	Mammography	60; alive, NED
5	37	Mammography	Lost to FU
6	36	Mammography	6; alive, NED
7	39	Mammography	Lost to FU
8	48	Mammography	72; alive, NED
9	46	Mammography	78; alive, NED

<sup>a</sup> Group I, patients with paired ADH and UDH; group II, patients with pure UDH only.

<sup>b</sup> NED, no evidence of disease.

<sup>c</sup> Lost to FU, lost to follow-up. Hospital cancer registry had no record of further malignant diagnosis.

appreciable nuclear hyperchromasia. For ADH, a single duct displaying features of nonnecrotic DCIS was required to be <2 mm in greatest diameter. Alternatively, multiple ducts showing only partial involvement also were consistent with a diagnosis of ADH (Fig. 1; Ref. 9)

UDH was defined as ducts with at least four layers of epithelial cells lining the ductal spaces. The epithelial cells were generally polymorphous and had low nuclear-to-cytoplasmic ratios (Fig. 2).

**Microdissection and DNA Extraction.** CGH analysis of DNA extracted from thin paraffin sections was performed as described previously (10). The middle section of each of five adjacent 5- $\mu$ m archival sections was stained with H&E, and the remaining sections were stained with methyl green (0.1%). Regions of interest were identified on the methyl green sections, using the adjacent H&E section for orientation, and were scraped from the slides with a no. 15 blade under a droplet of DNA extraction buffer [10 mM Tris-HCl (pH 8.0), 1.5 mM MgCl<sub>2</sub>, 50 mM KCl, 0.5% Tween 20 (Fisher Scientific, Pittsburgh, PA), and 0.4 mg/ml proteinase K (Sigma Chemical Co., St. Louis, MO)] after surrounding unwanted tissue was first scraped away. The dissected tissue was transferred into 15  $\mu$ l of DNA extraction buffer (per 500-1000 cells). Mineral oil (20  $\mu$ l) was placed over the sample, which was then incubated at 55°C overnight in a shaking water bath. Fresh proteinase K (0.3  $\mu$ l of 20 mg/ml stock) was added daily for 2 more days and was finally inactivated at 95°C for 15 min. The underlying buffer was then stored at 4°C.

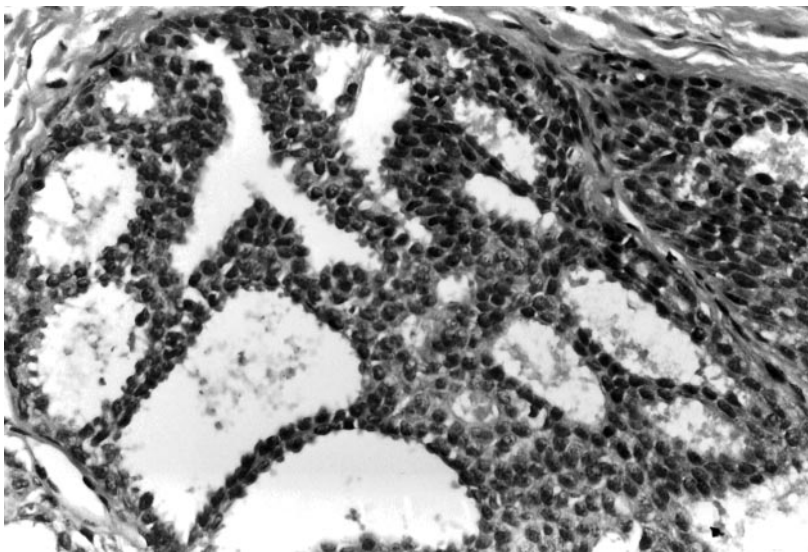
**PCR Amplification.** Amplification of microdissected DNA was based on the degenerate oligonucleotide-primed PCR

as described previously (10). The primer used was 5'-CCGACTCGAGNNNNNNATGTGG-3'. A 1-2- $\mu$ l aliquot of microdissected DNA was added to 5  $\mu$ l of 1 $\times$  PCR buffer and pretreated with 0.1  $\mu$ l of TOPO isomerase I (Promega, Madison WI) at 37°C for 30 min. The TOPO pretreatment was followed by five cycles of sequenase treatment (1 min at 94°C, 2 min at 30°C with addition of fresh sequenase in each cycle, and 2 min at 37°C). Pre-amplification was followed by heating at 95°C for 10 min, and 45  $\mu$ l of 1 $\times$  PCR buffer with 2 units of Taq DNA polymerase (Boehringer Mannheim, Indianapolis, IN) were then added. This was followed by 35 cycles at 94°C for 1 min, 56°C for 1 min, and 72°C for 3 min, with a final extension at 72°C for 5 min. Each PCR run included samples of normal female genomic DNA, MPE600 (a breast cancer cell line with known CGH aberrations), and a blank to check for contamination. Microdissected DNA yielded up to 1  $\mu$ g of PCR product, averaging 600 bp in size (range, 200 bp to 2 kbp). Fifty nanograms of reference and MPE600 cell line DNA produced ~2-3  $\mu$ g of amplified DNA.

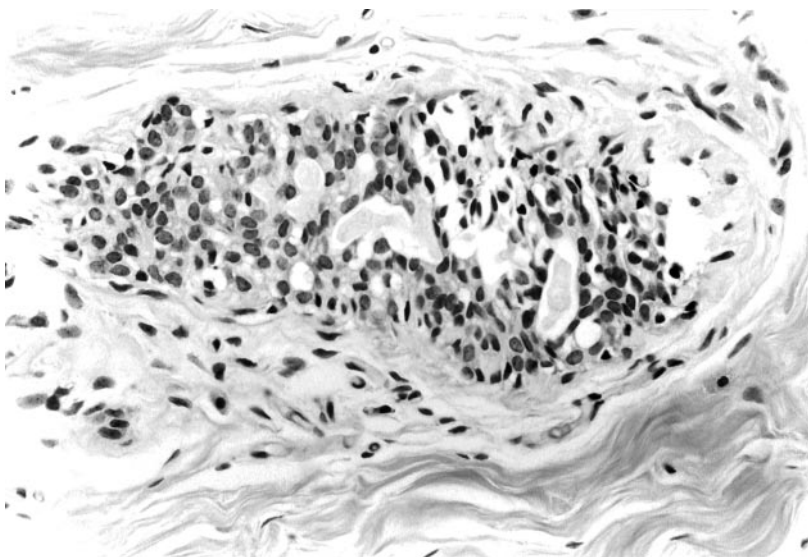
**Chromosomal CGH.** Each sample was hybridized in duplicate with different fluorochromes. PCR-amplified normal reference DNA was labeled by nick translation with fluorescein-12-dUTP (DuPont NEN, Boston, MA) for the first hybridization and indirectly with biotin-14-dATP and avidin-FITC (Life Technologies, Inc., Gaithersburg, MD) for the confirmatory hybridization. The MPE600 cell line and PCR-amplified test DNA were labeled with digoxigenin-11-dUTP (Boehringer Mannheim) followed by antidigoxigenin-rhodamine (Boehringer Mannheim). Forty  $\mu$ l of PCR-amplified DNA were used per 50- $\mu$ l nick translation. Nick-translated PCR products were close to the original PCR product size. Probes >2 kb in size tended to yield more granular hybridization, and smaller probes tended to yield less than optimum, dim, or granular CGH.

CGH was performed as described previously (11, 12). Samples were hybridized onto normal male metaphase spreads. Successful hybridizations were judged by the intensity of the tumor and normal signals, by the granularity and smoothness of the signals, by the homogeneity of the signal over the entire metaphase, and by the banding intensity of the 4',6-diamidino-2-phenylindole signals used for chromosome identification. At least five metaphase spreads were chosen for image acquisition based on these criteria. Acquisition was performed using our Quantitative Image Processing System (QUIPS) analysis system (13).

High-level amplification was defined as a peak intensity ratio >2.0, involving less than a whole chromosome arm. Low-level gain and loss were defined as chromosome regions that had a ratio >1.25 or <0.8, respectively. The inverse pair was examined together to allow better discrimination of significant changes. All changes had to be seen in both the forward and inverse hybridizations, and the ratio value had to be beyond the threshold in one of the hybridizations. Interpretation of changes at 1pter, 19 and 22 (and 4 and 13 in the opposite direction) required careful examination of all chromosome profiles because these loci were likely to show more variability in their ratios. Definition of changes at these loci required the cut point to be exceeded in both hybridizations. Each hybridization included MPE600 (showing 1p36.1-, 1q+, 9p-, 11q14-qter-, 13q12+, 13q32-qter+, 16q-, and 17q+) and normal *versus*



*Fig. 1* ADH. Monomorphic epithelial cells with increased nuclear-to-cytoplasmic ratios are seen in a cribriform growth pattern with attenuated "streaming" bridges.



*Fig. 2* UDH. Polymorphous epithelial cells with low nuclear-to-cytoplasmic ratios. The spaces between the hyperplastic cells vary both in shape and size.

normal controls. DNA extracted from paraffin sections of normal ductal epithelium was also analyzed to confirm the absence of chromosomal alterations.

**RESULTS**

CGH copy number alterations for group I patients are summarized in Table 2. Five of the nine ADH lesions showed copy number alterations (mean number of alterations, 3.6 for these five cases). 16q loss and 17p loss were the most frequent changes (in five and two cases, respectively). In the UDH lesions present concurrently with the ADH, chromosomal alterations were detected in these same five patients. In each case, a subset of changes present in the ADH were also present in the UDH. In addition, in one patient, the ADH lesion showed no changes, whereas the UDH microdissected from the same biopsy showed eight chromosomal alterations. The UDH from this

patient (case 7) was reanalyzed (remicrodissection, DNA extraction, and CGH) to confirm these unexpected findings. This patient, an 86-year-old woman, has shown no further breast abnormality in the brief 6-month follow-up to her biopsy.

Only one of nine patients with pure UDH showed CGH abnormalities. Three alterations were detected, involving gain of 1q32-42, 16q loss, and gain of 17q21. This patient had no evidence of disease after a 65 months of follow-up.

**DISCUSSION**

A history of proliferative breast disease is a significant risk factor for development of invasive breast cancer. UDH carries a mild relative risk of invasive cancer, whereas hyperplasia with atypical changes is associated with greater risk. These two lesions are distinguished by their histological appearance. Previous studies using allelic imbalance to define genetic alter-

Table 2 Genetic changes of ADH and adjacent UDH (group I)

Case	Distance <sup>a</sup> (mm)	ADH	UDH	Concurrence <sup>b</sup> (%)
1	3	3q11-q21-, 8p12-pter-, 16q-, 20-	8p12-pter-, 16q-	50
2	7	No change	No change	
3	4	1q+, 10+, 11q12-13+, 16p+, 16q-	1q+, 16q-	40
4	1.5	16q-, 20p-	16q-, 20p-	100
5	3	16q-, 17p-, 21q11-q21-	16q-, 17p-, 21q11-q21-	100
6	5	No change	No change	
7	6.5	No change	8-, 9-, 10p-, 11q14-qter-, 12+, 18-, 20+, X-	0
8	1.5	No change	No change	
9	1.5	8q21-qter+, 14q+, 16q-, 17p-	16q-, 17p-	50

<sup>a</sup> Distance between ADH and UDH on the same slide.

<sup>b</sup> Concurrence calculated as the fraction of changes in ADH also seen in accompanying UDH.

ations have shown abnormalities in a minority of proliferative lesions. In this study, we compared genetic alterations as defined by CGH in ADH and paired UDH to define their clonal relationships.

Frequent sharing of genetic changes between ADH and UDH in the same biopsy was seen in this study. UDH showed 40–100% concurrence (mean, 68%) with its paired ADH in the five patients showing changes in the ADH lesion. This degree of overlap between UDH and ADH clearly suggests a precursor-product relationship. The striking finding that 16q loss was present in both UDH and ADH in these cases strongly suggests that this is the earliest clonal alteration in these lesions.

Genetic alterations were detected by CGH in 44% of the ADH lesions examined. This is in agreement with a larger study by O'Connell *et al.* (6), who found at least one LOH alteration in 42% of 26 patients with ADH in the absence of DCIS or invasive cancer. Interestingly, there was little increase (44%) in ADH changes in the presence of cancer in that study. Rosenberg *et al.* (14) reported that 6 of 15 ADH cases (40%), also with no coincident or previous breast malignancy, showed evidence of LOH. This group also found that there was little difference in the frequency of genomic alterations in ADH in patients with concurrent cancer. Lakhani *et al.* (4, 5) detected LOH in three of five patients with ADH in the absence of cancer, and in two of four patients with carcinoma. In contrast, Lizard-Nacol *et al.* (15) did not detect LOH at any of the examined loci in 50 benign breast lesions.

In our study, only one of nine cases of pure UDH showed genetic changes, although an additional patient in group I also showed changes in UDH in the absence of changes in the paired ADH. O'Connell *et al.* (6) reported 37% of UDH (in the absence of DCIS or invasive disease) with LOH alterations, and Lakhani *et al.* (4, 5) reported 0–13% for individual LOH loci in pure UDH. It is clear from these studies that in a small fraction of cases, pure UDH shows sufficient clonal outgrowth to exhibit allelic imbalance. It is interesting to note that the patient in Group I with multiple changes in her UDH was 86 years of age and that her UDH was at some distance (6.5 mm) from the ADH showing no CGH alterations.

It is not clear whether analysis by CGH or by allelic imbalance is more sensitive to detection of clonal alterations. Both techniques use the average DNA content to define abnormalities. LOH measurements are dependent on equal PCR am-

plification of multiple alleles, and so may show artifactual imbalances. CGH uses degenerate oligonucleotides for PCR, which may amplify GC-rich regions differentially from AT regions. In either case, it is important to reproduce analyses (as done in this study) to avoid overinterpretation of technical artifacts. This is especially true when amplifying DNA that has been extracted from paraffin tissues.

This study is in agreement with previous analyses of pre-invasive lesions in finding a substantial rate of 16q loss (56%) and 17p loss (22%) in both ADH and the paired UDH. Candidate genes that might be responsible for some of these losses include *E-cadherin* on 16q and *p53* on 17p. Reduced or altered expression of E-cadherin has been found in 50% of invasive breast carcinomas and at very high frequency in invasive lobular cancers (16). Chen *et al.* (17) reported that 89% of DCIS showed allelic losses at one or more loci on 16q, confirming that chromosome 16q is one of the first altered in the development of breast cancer (18, 19). Radford *et al.* (20) reported 28.6% LOH of 16q and 37.5% LOH of 17p in DCIS. Vos *et al.* (21) found LOH on chromosome 17 in 70% of poorly differentiated DCIS and 17% of well-differentiated DCIS. They also found that 66% of the loss on chromosome 16 was associated with well- to intermediate-differentiated DCIS. The *p53* gene is abnormal in several premalignant lesions. Relatively little is known about *p53* alterations in UDH and ADH, but there are a few reports of up to 40 and 10% rates of mutation/overexpression in comedo and noncomedo DCIS, respectively (22, 23). Inactivation of the two tumor suppressor genes *p53* and *E-cadherin* may be an early step in malignant transformation.

This study shows that genetic changes are already present in preinvasive lesions of the breast. The changes present suggest that UDH often is a precursor of ADH and that many of these lesions represent neoplastic growth.

## REFERENCES

- Dupont, W. D., and Page, D. L. Risk factors for breast cancer in women with proliferative breast disease. *N. Engl. J. Med.*, 312: 146–151, 1985.
- Fitzgibbons, P. L., Henson, D. E., and Hutter, R. V. Benign breast changes and the risk for subsequent breast cancer: an update of the 1985 consensus statement. Cancer Committee of the College of American Pathologists. *Arch. Pathol. Lab. Med.*, 122: 1053–1055, 1998.
- Chuaqui, R. F., Zhuang, Z., Emmert-Buck, M. R., Liotta, L. A., and Merino, M. J. Analysis of loss of heterozygosity on chromosome 11q13

- in atypical ductal hyperplasia and *in situ* carcinoma of the breast. *Am. J. Pathol.*, *150*: 297–303, 1997.
4. Lakhani, S. R., Collins, N., Stratton, M. R., and Sloane, J. P. Atypical ductal hyperplasia of the breast: clonal proliferation with loss of heterozygosity on chromosomes 16q and 17p. *J. Clin. Pathol.*, *48*: 611–615, 1995.
  5. Lakhani, S. R., Slack, D. N., Hamoudi, R. A., Collins, N., Stratton, M. R., and Sloane, J. P. Detection of allelic imbalance indicates that a proportion of mammary hyperplasia of usual type are clonal, neoplastic proliferations. *Lab. Invest.*, *74*: 129–135, 1996.
  6. O'Connell, P., Pekkel, V., Fuqua, S. A., Osborne, C. K., Clark, G. M., and Allred, D. C. Analysis of loss of heterozygosity in 399 premalignant breast lesions at 15 genetic loci. *J. Natl. Cancer Inst. (Bethesda)*, *90*: 697–703, 1998.
  7. Rosenberg, C. L., de las Morenas, A., Huang, K., Cupples, L. A., Faller, D. V., and Larson, P. S. Detection of monoclonal microsatellite alterations in atypical breast hyperplasia. *J. Clin. Investig.*, *98*: 1095–1100, 1996.
  8. Page, D. L., Dupont, W. D., Rogers, L. W., and Rados, M. S. Atypical hyperplastic lesions of the female breast. A long-term follow-up study. *Cancer (Phila.)*, *55*: 2698–2708, 1985.
  9. Tavassoli, F. A., and Norris, H. J. A comparison of the results of long-term follow-up for atypical intraductal hyperplasia and intraductal hyperplasia of the breast. *Cancer (Phila.)*, *65*: 518–529, 1990.
  10. Willenbacher, R. F., Zelman, S. J., Ferrell, L. D., Moore, D. H., Jr., and Waldman, F. M. Chromosomal alterations in ulcerative colitis-related neoplastic progression. *Gastroenterology*, *113*: 791–801, 1997.
  11. Kallioniemi, A., Kallioniemi, O. P., Sudar, D., Rutovitz, D., Gray, J. W., Waldman, F., and Pinkel, D. Comparative genomic hybridization for molecular cytogenetic analysis of solid tumors. *Science (Wash. DC)*, *258*: 818–821, 1992.
  12. Waldman, F. M., DeVries, S., Chew, K. L., Moore, D. H., Jr., Kerlikowske, K., and Ljung, B.-M. Chromosomal alterations in ductal carcinomas *in situ* and their *in situ* recurrences. *J. Natl. Cancer Inst. (Bethesda)*, *92*: 313–320, 2000.
  13. Piper, J., Rutovitz, D., Sudar, D., Kallioniemi, A., Kallioniemi, O. P., Waldman, F. M., Gray, J. W., and Pinkel, D. Computer image analysis of comparative genomic hybridization. *Cytometry*, *19*: 10–26, 1995.
  14. Rosenberg, C. L., Larson, P. S., Romo, J. D., de las Morenas, A., and Faller, D. V. Microsatellite alterations indicating monoclonality in atypical hyperplasias associated with breast cancer. *Hum. Pathol.*, *28*: 214–219, 1997.
  15. Lizard-Nacol, S., Lidereau, R., Collin, F., Arnal, M., Hahnel, L., Roinot, P., Cuisenier, J., and Guerrin, J. Benign breast disease: absence of genetic alterations at several loci implicated in breast cancer malignancy. *Cancer Res.*, *55*: 4416–4419, 1995.
  16. Gamallo, C., Palacios, J., Suraz, A., Navarro, P., Quintanilla, M., and Cano, A. Correlation of E-cadherin expression with differentiation grade and histologic type in breast carcinoma. *Am. J. Pathol.*, *142*: 987–993, 1993.
  17. Chen, T., Sahuin, A., and Aldaz, C. M. Deletion map of chromosome 16q in ductal carcinoma *in situ* of the breast: refining a putative tumor suppressor gene region. *Cancer Res.*, *56*: 5605–5609, 1996.
  18. Dutrillaux, B., Gerbault-Seureau, M., and Zafrani, B. Characterization of chromosomal anomalies in human breast cancer: comparison of 30 paradiploid cases with few chromosome changes. *Cancer Genet. Cytogenet.*, *49*: 203–217, 1990.
  19. Pandis, N., Heimi, S., Bardi, G., Idvall, I., Mandahl, N., and Mitelman, F. Whole-arm t(1:16) and i(1q) as sole anomalies identify gain of 1q as a primary chromosomal abnormality in breast cancer. *Genes Chromosomes Cancer*, *5*: 235–238, 1992.
  20. Radford, D. M., Fair, K. L., Philips, N. J., Ritter, J. H., Steinbrueck, T., Holt, M. S., and Donis-Keller, H. Allelotyping of ductal carcinoma *in situ* of the breast: deletion of loci 8p, 13q, 16q, 17p and 17q. *Cancer Res.*, *55*: 3399–3405, 1995.
  21. Vos, C. B., ter Haar, N. T., Rosenberg, C., Peterse, J. L., Cleton-Jansen, A. M., Cornelisse, C. J., and van de Vijver, M. J. Genetic alterations on chromosome 16 and 17 are important features of ductal carcinoma *in situ* of the breast and associated with histologic type. *Br. J. Cancer*, *81*: 1410–1418, 1999.
  22. Davidoff, A. M., Kerns, B. J. M., Iglehart, J. C., and Marks, J. R. Maintenance of p53 alterations throughout breast cancer progression. *Cancer Res.*, *51*: 2605–2610, 1991.
  23. Poller, D. N., Roberts, J. A., Bell, R. A., Elston, C. W., Balamey, R. W., and Ellis, I. O. P53 protein expression in mammary ductal carcinoma *in situ*: relationship to immunohistochemical expression of estrogen receptor and c-erbB2 protein. *Hum. Pathol.*, *24*: 463–468, 1993.