

Overexpression of Cyclooxygenase-2 in Carcinoma of the Pancreas¹

Jiro Okami, Hirofumi Yamamoto, Yoshiyuki Fujiwara, Masaki Tsujie, Motoi Kondo, Shingo Noura, Satoshi Oshima, Hiroaki Nagano, Keizo Dono, Koji Umeshita, Osamu Ishikawa, Masato Sakon, Nariaki Matsuura, Shoji Nakamori,² and Morito Monden

Department of Surgery II, Osaka University Medical School, Osaka 565-0871, Japan [J. O., H. Y., Y. F., M. T., M. K., S. No., S. O., H. N., K. D., K. U., M. S., S. Na., M. M.]; Department of Surgery, Osaka Medical Center for Cancer and Cardiovascular Disease, Osaka 537-8511, Japan [O. I.]; and Department of Pathology, School of Allied Health Science, Faculty of Medicine, Osaka University, Osaka 565-0871, Japan [N. M.]

ABSTRACT

The level of cyclooxygenase (COX)-2 has been investigated recently in various human carcinomas. In the present study, we examined the distribution and extent of COX-2 protein in human pancreatic tumors using immunohistochemistry. A strong expression of COX-2 protein was present in 23 of 52 (44%) pancreatic carcinomas, a moderate expression was present in 24 of 52 (46%) pancreatic carcinomas, and a weak expression was present in 5 of 52 (10%) pancreatic carcinomas. In contrast, benign tumors showed weak expression or no expression of COX-2, and only islet cells displayed COX-2 expression in normal pancreatic tissues. Overexpression of COX-2 in carcinoma tissues was also confirmed by Western blot analysis. Furthermore, consistent with the results at protein levels, reverse transcription-PCR analyses indicated that COX-2 mRNA was overexpressed in 7 of 13 (54%) carcinomas, but in none of 3 benign tumors. Our findings suggest that COX-2 inhibitors might be potentially effective against pancreatic carcinomas and that COX-2 may be involved in certain biological processes in pancreatic islets.

INTRODUCTION

The incidence of carcinoma of the pancreas is associated with a high mortality rate. In the United States, the 5-year

overall survival has increased from 1% in 1961 to only 3–5% in 1991. The annual incidence in Western societies is nearly 10 per 100,000 total population (1). The incidence in most developed countries is similar to that of the United States, particularly among urban and socioeconomically disadvantaged populations. Several factors have been implicated for the recent rise in the frequency of pancreatic carcinoma, including cigarette smoking, gallstones, a diet high in animal fat, and chronic calcific pancreatitis (2). Although few studies have suggested the possible role of *K-ras* oncogenes, tumor suppressor genes (p16, p53, and DPC4), and growth factors (epidermal growth factor, basic fibroblast growth factor, and insulin-like growth factor I) in carcinoma of the pancreas, the exact pathogenic mechanisms and progression of this neoplasm remain to be clarified, and no effective strategy for treatment of this disease has been established thus far (3–7).

COX³ is a rate-limiting enzyme involved in the conversion of arachidonic acid to prostaglandin H₂, the precursor of several molecules including prostaglandins, prostacyclin, and thromboxanes. Two COX genes, COX-1 and COX-2, have been identified that share a >60% identity at the amino acid level (8). COX-1 is constitutively expressed in many tissues and is responsible for various physiological functions including the cytoprotection of the stomach, vasodilatation in the kidney, and the production of a proaggregatory prostanoid, thromboxane, by the platelets. On the other hand, COX-2 is an inducible immediate early gene and was originally found to be induced by inflammation and ovulation or by a variety of other stimuli, such as mitogens, cytokines, and growth factors (9–11). Overexpression of COX-2 has been demonstrated in human inflammatory diseases, including rheumatoid arthritis, Crohn's disease, ulcerative colitis, and *Helicobacter pylori*-infectious gastritis (12–14).

Recent studies have highlighted the potential role of COX-2 in carcinogenesis. In 1994, the induction of COX-2 was reported in carcinomas of the colon, and in subsequent years, increased levels of COX-2 were found in carcinomas of the stomach, breast, esophagus, and lung (15–21). In contrast, the levels of COX-1 are mostly similar between normal and tumor tissues. Importantly, overexpression of COX-2 in human carcinomas appears to be of functional significance because double knockout mice for adenomatous polyposis coli and COX-2 genes showed a reduction in the size and frequency of intestinal polyps (22). There is also cumulative evidence that selective COX-2 inhibitors prevent carcinogenesis in experimental animals (23) and that these compounds induce apoptosis in several types of carcinoma cells (24). These findings suggest that COX-2 may be associated with carcinogenesis and/or the progression of certain types of human malignancies. In fact, various

Received 3/19/99; revised 5/25/99; accepted 5/25/99.

The costs of publication of this article were defrayed in part by the payment of page charges. This article must therefore be hereby marked *advertisement* in accordance with 18 U.S.C. Section 1734 solely to indicate this fact.

¹ Supported in part by Grants-in-Aid for Cancer Research for New 10-Year Strategy for Cancer Control from the Ministry of Health and Welfare of Japan (to S. Na.), by Grants-in-Aid for Specially Promoted Research from the Ministry of Education, Science, Sports and Culture of Japan (to S. Na.), and by a Grant-in-Aid for Basic Research from the Ministry of Education, Science, Sports and Culture of Japan (to M. M.).

² To whom requests for reprints should be addressed, at Department of Surgery II, Osaka University Medical School, 2-2 Yamada-oka, Suita City, Osaka 565-0871, Japan.

³ The abbreviations used are: COX, cyclooxygenase; NSAID, nonsteroidal anti-inflammatory drug; PBGD, porphobilinogen deaminase; RT-PCR, reverse transcription-PCR; T:N, tumor:normal.

studies are currently being conducted based on the potential effect of COX-2 inhibitors on the prevention and/or therapy of cancers (25–27).

Little is known about the expression of COX-2 in human pancreatic carcinoma. In the present study, we examined the expression of COX-2 mRNA by RT-PCR and determined the distribution of COX-2 protein by immunohistochemistry in human pancreatic tumors.

MATERIALS AND METHODS

Cell Lines and Tissue Samples. Three pancreatic adenocarcinoma cell lines were used in this study. The BxPC3 and PSN1 cell lines were obtained from the Japanese Cancer Research Resources Bank. The PCI6 cell line was a gift from Dr. H. Ishikura (Hokkaido University, Sapporo, Japan; Ref. 28). Cells were cultured in RPMI 1640 supplemented with 10% FCS at 37°C. We also examined pancreatic tissue samples obtained from 56 patients after surgery at either the Department of Surgery II, Osaka University Medical School or the Osaka Medical Center for Cancer and Cardiovascular Disease. Tissue samples were fixed in 10% neutral buffered formalin, processed through graded ethanol solutions, and embedded in paraffin. A series of 48 adenocarcinomas, including 4 intraductal papillary adenocarcinomas and 1 cystadenocarcinoma, 4 adenosquamous carcinomas, and 4 benign serous cystadenomas, together with matching adjacent nontumor tissues, were immunostained for COX-2. A piece from each tissue sample was immediately frozen in liquid nitrogen and stored at –80°C. A subset of paired nontumor and tumor tissues was further examined by RT-PCR and Western blot analysis.

Reagents. Rabbit polyclonal antihuman COX-2 antibody and its blocking peptide, which was used as an immunogen (17 amino acids, position 251–267) for generation of this antibody, were obtained from Immuno-Biological Laboratories, Co. (Gunma, Japan; Ref. 20). Recombinant COX-2 protein was obtained from Cayman Chemical (Ann Arbor, MI) and used as a positive control in Western blot analysis.

Immunohistochemistry. Tissue sections (4- μ m thick) were deparaffinized in xylene and rehydrated. Heat antigen retrieval was performed as described previously (29). Slides were then processed for immunohistochemistry on the Teck Mate Horizon automated staining system (DAKO, Carpinteria, CA; Refs. 30 and 31) using the Vectastain ABC peroxidase kit (Vector Laboratories, Burlingame, CA; Ref. 29). In the primary antibody reaction step, slides were incubated with the COX-2 antibody (final concentration, 5 μ g/ml) for 1 h at room temperature. For positive controls, sections of colon cancer expressing the COX-2 protein were included in each staining procedure. For negative controls, nonimmunized rabbit IgG (Vector Laboratories) or Tris-buffered saline was used as a substitute for the primary antibody to distinguish false positive responses from nonspecific binding to IgG or the secondary antibody. In addition, preabsorbed antibody with an excess amount of immunogens abolished the staining. Staining was repeated twice to avoid possible technical errors, but similar results were obtained.

Evaluation of COX-2 Immunostaining. All immunostained sections were coded and evaluated without prior knowl-

edge of the clinical and pathological parameters. In each section, five high-power fields were selected at random, and a total number of at least 700 cells were evaluated. The results were expressed as the percentage of positively stained cells. The intensity of staining was estimated on a scale from 0–3 (0, negative; 1, weak; 2, moderate; and 3, strong). Pancreatic islets that showed intense COX-2 expression served as an internal control. All slides were interpreted by two investigators (J. O. and H. Y.) on three different occasions. Evaluations were mostly similar, and <10% disagreement between the investigators was noted. In case of disagreement, the final evaluation of such sections was determined by consensus using a multihead microscope.

Semiquantitative RT-PCR. RNA extraction was carried out with Trizol reagent using a single-step method, and cDNA was generated with avian myeloblastosis virus reverse transcriptase (Promega, Madison, WI), as described previously (32). Semiquantitative analysis of the expression of COX-2 or COX-1 mRNA was performed using the multiplex RT-PCR technique. In this assay, we used a housekeeping gene, PBGD, as an internal standard. This gene is favored over β -actin or glyceraldehyde-3-phosphate dehydrogenase as a reference gene for competitive PCR amplification because the presence of pseudogenes for the latter housekeeping genes can produce false positive signals from genomic DNA contamination (33, 34). In addition, to minimize possible inter-PCR differences, PCR was performed with COX-2 or COX-1 and PBGD primers in an identical tube, in an unsaturated condition. PCR was performed in a 25- μ l reaction mixture containing 1 μ l of cDNA template, 1 \times Perkin-Elmer PCR buffer, 1.5 mM MgCl₂, 0.8 mM deoxynucleotide triphosphates, 0.8 μ M of each primer for COX-2 or 80 nM of each primer for COX-1, and 80 nM PBGD, and 1 unit of Taq DNA polymerase (AmpliTaq Gold; Roche Molecular Systems, Inc.). The PCR primers used for detection of COX-1, COX-2, and PBGD cDNAs were synthesized as described previously, and amplified products were 303, 305, and 127 bp, respectively (35, 36). The conditions for multiplex PCR were one cycle of denaturing at 95°C for 12 min, followed by 40 cycles of 95°C for 1 min, 62°C for 1 min, and 72°C for 1 min, and a final extension at 72°C for 10 min. The electrophoresed PCR products were scanned by densitometry, and the relative value of the COX-2 or COX-1 band as compared to the PBGD band was calculated in each sample.

Western Blot Analysis. Western blot analysis was performed as described previously (37). Briefly, 100 μ g of the total protein from tissues and 2.5 μ g/ml COX-2 antibody were used for this assay.

Statistical Analysis. Statistical analysis was performed using the Statview J software (version 4.5). The χ^2 and Fisher's exact tests were used to examine the association between COX-2 expression and clinicopathological parameters. $P < 0.05$ denoted the presence of a statistically significant difference.

RESULTS

Immunohistochemistry

COX-2 Expression in Normal Pancreatic Tissues. Only normal pancreatic tissues without significant inflammation were examined. COX-2 expression was not detected in epithe-

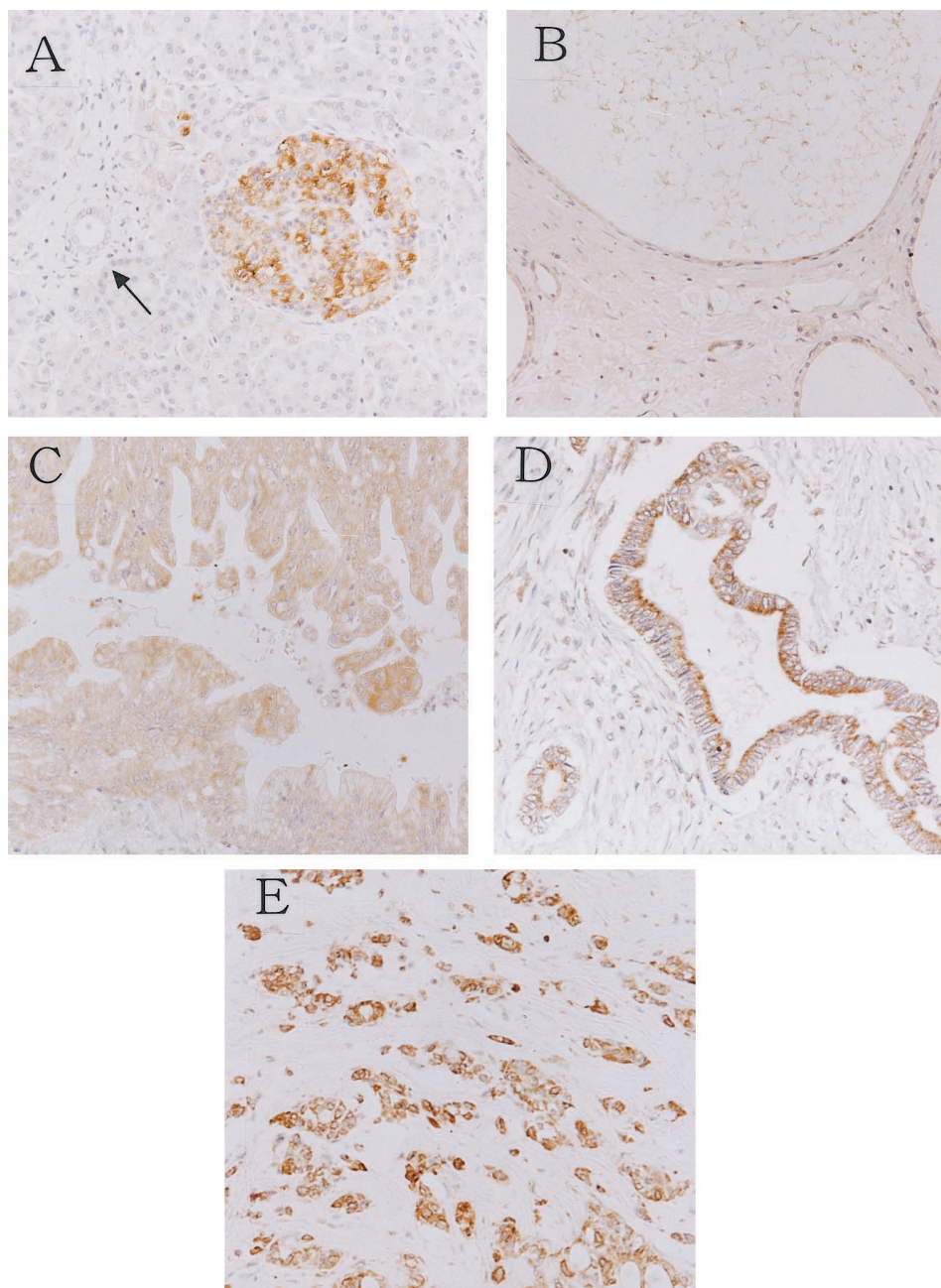


Fig. 1 Immunostaining for COX-2 in pancreatic tissues. *A*, normal pancreatic tissue. Islets cells display a strong staining, whereas epithelial cells of the pancreatic duct (*arrow*) or acinar cells are negative for COX-2. *B*, pancreatic serous cystadenoma. Note the weakly positive staining for COX-2 in adenoma cells of the cyst wall. *C*, intraductal papillary adenocarcinoma. *D*, well-differentiated adenocarcinoma. *E*, poorly differentiated adenocarcinoma. Magnification, $\times 50$ (*A–E*).

lial cells of normal pancreatic ducts or in normal acinar cells. In contrast, pancreatic islets exclusively displayed a strong expression of COX-2 (Fig. 1A).

COX-2 Expression in Pancreatic Tumors. Four benign tumors (cystadenomas) and 52 carcinomas (48 adenocarcinomas and 4 adenosquamous carcinomas) were examined. In benign tumor specimens, a weak COX-2 staining or no COX-2 staining was detected (Fig. 1B; Table 1). In contrast, a moderate to strong expression of COX-2 was noted in most carcinomas. Specifically, a strong expression of COX-2 protein was present in 23 of 52 (44%) pancreatic carcinomas, moderate expression was present in 24 of 52 (46%) pancreatic carcinomas, and weak expres-

sion was present in 5 of 52 (10%) pancreatic carcinomas. The level of COX-2 expression in benign tumors was significantly different from that in malignant tumors (Table 1; $P < 0.05$). When COX-2 expression was analyzed according to the histology of pancreatic carcinoma, we found that moderate to strong expression of this enzyme was detected in most cases, irrespective of histological type or grade (Fig. 1, C–E; Table 2). We also determined the percentage of COX-2-positive cells because several carcinomas displayed a heterogeneous expression of COX-2, as described in “Materials and Methods.” The results of this analysis are summarized in Table 2.

To confirm the specificity of COX-2 antibody staining, we

Table 1 COX-2 expression in pancreatic tumors

	Intensity				
	0	1	2	3	
Benign tumors	1	3	0	0] $P < 0.05^a$
Malignant tumors	0	5	24	23	

^a Cases were divided between intensity 1 and 2. The difference in COX-2 expression was significant between benign tumors and carcinomas.

examined the expression of COX-2 in three sets of paired normal and carcinoma tissues by Western blot analysis using a recombinant COX-2 protein as a positive control. COX-2 protein was clearly expressed by carcinoma tissues, but normal pancreatic tissues expressed scarce bands (data not shown). In addition, preabsorbed antibody with an excess amount of the immunogens eliminated the band corresponding to COX-2 (data not shown), indicating that the antibody was specific for COX-2.

We then determined the immunoreactive score for each individual carcinoma case by multiplying the percentage of positive cells by the staining intensity, as reported previously (38, 39). The immunoreactive score ranged from 10–300, with an average value of 180. Based on this analysis, patients with malignant tumors were classified into two groups: (a) 27 high expressers; and (b) 25 low expressers, using a cutoff value equivalent to the above median value. Using this classification, we did not find any significant difference between the two groups based on various clinicopathological parameters, such as age, sex, histological grade, tumor size, nodal involvement, metastasis, stage (UICC, the International Union Against Cancer, classification), and site of the tumor (Table 2).

RT-PCR

To examine the level of mRNA for COX-2, a RT-PCR assay was performed using the BxPC3, PCI6, and PSN1 pancreatic carcinoma cell lines and 16 paired nontumor and tumor tissues (13 malignant tumors and 3 benign tumors). Each of the three carcinoma cell lines expressed a 305-bp band for COX-2 and a 303-bp band for COX-1, with constitutive expression of PBGD (Fig. 2, *top* and *bottom panels*). To estimate the expression of COX-2 in tumor tissues relative to that in the matched normal tissues, we calculated the T:N ratio representing the expression of COX-2 in the tumor (COX-2/PBGD) relative to that in normal tissue (COX-2/PBGD). In the three benign samples, the COX-2 T:N ratio was 1.00, 0.43, and 0.39. In 13 carcinoma samples, the value ranged from 0.46–37.0 (<1.0, two cases; 1.0–2.0, four cases; and >2.0, seven cases). When overexpression of COX-2 mRNA was defined as a T:N ratio of >2.0, COX-2 mRNA was overexpressed in 7 of 13 (54%) carcinoma cases. There was no significant difference in the level of COX-1 mRNA between normal and tumor tissues, in benign tumors as well as malignant tumors (Fig. 2, *bottom panel*). These assays were repeated at least twice, and concordant results were obtained.

Table 2 COX-2 expression and clinicopathological parameters in pancreatic carcinomas

	Intensity		
	1	2	3
Histological type and grade			
Adenocarcinoma			
Well differentiated	3	10	10
Moderately differentiated	2	10	5
Poorly differentiated	0	4	4
Adenosquamous carcinoma	0	0	4
Tumor size			
T ₁ /T ₂	5	10	9
T ₃ /T ₄	0	14	14
Nodal involvement			
Negative	5	7	8
Positive	0	17	15
Metastasis			
M ₀	5	23	22
M ₁	0	1	1
Stage			
I/II	5	7	8
III/IV	0	17	18
Localization			
Head	4	20	18
Body/tail	1	4	5
Positivity (%) ^a			
0–49	2	1	0
50–79	2	18	6
80–100	1	5	17

^a Positivity was determined as the percentage of positively stained cells. In each section, five high-powered fields were selected at random, and a total number of at least 700 cells were evaluated.

DISCUSSION

Epidemiological studies indicate that the administration of NSAIDs results in a marked reduction in adenoma size and number and not infrequently leads to a complete regression of colonic polyps in patients with familial adenomatous polyposis (40–42). NSAIDs also reduce the risk of sporadic colorectal, breast, and lung cancers (43, 44). These effects of NSAIDs on the inhibition of carcinogenesis have also been demonstrated in animal experiments, including a pancreatic neoplasm in *N*-nitrosobis(2-oxopropyl)amine-treated hamsters (45). Several lines of evidence indicate that the antitumor effects of NSAIDs may be due in part to the inhibition of COX-2 activity (22, 46–48). Indeed, in carcinomas of the colon and lung and also in gastric and esophageal carcinomas, the level of COX-2 expression is significantly increased. These findings suggest that up-regulation of this enzyme might be a common mechanism for carcinogenesis of cells of an epithelial origin. Pancreatic carcinoma is one of the most stressful diseases for patients and physicians, and most pancreatic carcinomas (approximately 90–95%) are ductal adenocarcinomas derived from epithelial cells of the pancreatic ducts. The present study was performed to investigate the involvement of COX-2 in a variety of pancreatic tumors.

In pancreatic carcinoma tissues, the cellularity of the carcinoma cells was relatively low (approximately 10–50%), but we still found that COX-2 expression was increased at both the RNA and protein levels in most of the pancreatic carcinomas

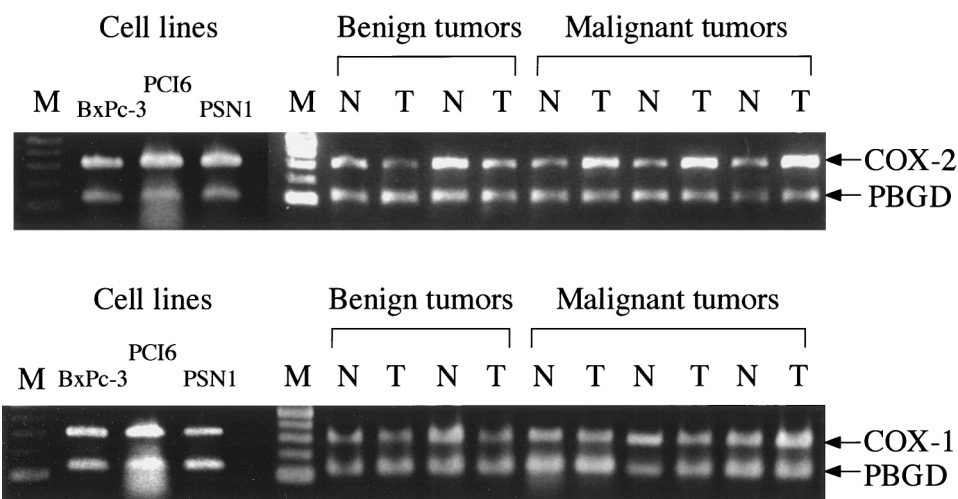


Fig. 2 Semiquantitative RT-PCR analysis of COX-2 (top panel) and COX-1 (bottom panel) mRNA expression in pancreatic carcinoma cell lines, benign tumors, and malignant tumors (carcinomas). The co-amplified *PBGD* gene served as an internal control. Representative samples, two paired benign tumors and three paired malignant tumors, are shown. PCR product sizes are as follows: COX-2, 303 bp; COX-1, 305 bp; and *PBGD*, 127 bp. *M*, marker; *N*, normal pancreatic tissue; *T*, corresponding tumor.

compared with paired normal tissues by RT-PCR and Western blot analyses. RT-PCR analyses indicated that 7 of 13 (54%) carcinoma cases displayed an overexpression of COX-2 mRNA. In contrast, the expression of COX-1 mRNA was similar in cancer and normal tissues. Furthermore, the results of mRNA analysis paralleled those of immunohistochemistry. Thus, approximately 44% of the carcinoma samples exhibited a strong expression of the COX-2 protein, whereas normal pancreatic ducts or acinar cells showed little or no COX-2 expression. Up to 90% of carcinoma cases showed moderate to strong COX-2 expression (intensity 2 or 3). Furthermore, although a clinicopathological survey displayed no correlation between COX-2 expression and several clinical parameters, COX-2 was expressed in various histological types of carcinomas, *i.e.*, poorly differentiated adenocarcinoma as well as moderately to well differentiated adenocarcinoma and adenosquamous carcinoma, intraductal papillary adenocarcinoma, and cystadenocarcinoma. Because several mechanistic studies suggest that carcinoma cells overexpressing COX-2 (but not those lacking COX-2) are sensitive to COX-2 inhibitors (49, 50), it is potentially important that COX-2 is expressed in the majority of human pancreatic carcinomas, irrespective of histological type. This aspect may be characteristic of pancreatic carcinomas because in carcinomas of the colon, lung, and liver (16, 20, 21, 51), COX-2 expression is dependent on the histological grade or type. During the preparation of the manuscript, other investigators showed that COX-2 expression was increased in 9 of 10 biopsy specimens of pancreatic carcinoma (52). The present study extended their findings with a number of pancreatic carcinomas ($n = 52$) that had various clinicopathological features. Furthermore, our data revealed that COX-2 expression was not affected by several parameters that were associated with tumor progression, such as tumor size, lymph node or distant metastasis, and clinical stage. We also examined COX-2 expression in a subset of benign tumor samples. Compared to malignant tumors, these benign tumors expressed lower levels of COX-2 mRNA and protein. These findings suggest that COX-2 may be a marker for the malignant potential of pancreatic tumors, although its function remains to be clarified.

Previous studies have shown a low basal level of COX-2 mRNA in normal pancreatic tissues (36). Consistent with this finding, the present data indicated that COX-2 protein was localized exclusively to islets that occupied a minimal area of the normal pancreas, but not in epithelial cells of the duct or in acinar cells. Our immunohistochemical data on COX-2 expression in the islets are consistent with recent reports from other laboratories (53, 54), and islet cells served well as inner controls for COX-2 staining in a series of sections. The significance of COX-2 expression in the islets is unclear at present. Experiments using COX-2 inhibitors may allow a better understanding of the possible role of COX-2 in pancreatic islet physiology and the pathogenesis of diabetes mellitus because prostaglandin E_2 negatively regulates pancreatic islet function, *i.e.*, glucose-induced insulin secretion. During the observation of COX-2 staining in carcinomatous tissues, we found that islet cells always showed a high expression of COX-2, even when acinar cells changed into fibrous tissues. This finding is of potential importance with regard to the association of COX-2 with carcinogenesis because we have previously demonstrated that the transplantation of pancreatic islets to the submandibular glands led to carcinoma formation in *N*-nitrosobis(2-oxopropyl)amine-treated hamsters (55).

In conclusion, we report overexpression of COX-2 in various histological types of pancreatic carcinomas. Our data suggest that COX-2 inhibitors might be potentially effective against the development and/or progression of human pancreatic carcinoma.

ACKNOWLEDGMENTS

We thank Dr. H. Ishikura for the generous supply of human pancreatic carcinoma cell line PCI6.

REFERENCES

1. Boring, C. C., Squires, T. S., Tong, T., and Montgomery, S. Cancer statistics, 1994. *CA Cancer J. Clin.*, 44: 7–26, 1994.
2. Warsaw, A. L., and Fernandez-DelCatillo, C. Pancreatic carcinoma. *N. Engl. J. Med.*, 326: 455–456, 1992.

3. Caldas, C., Hahn, S. A., da Costa, L. T., Redston, M. S., Schutte, M., Seymour, A. B., Weinstein, C. L., Hruban, R. H., Yeo, C. J., and Kern, S. E. Frequent somatic mutations and homozygous deletions of the p16 (*MTS1*) gene in pancreatic adenocarcinoma. *Nat. Genet.*, 8: 27–32, 1994.
4. Scarpa, A., Capelli, P., Mukai, K., Zamboni, G., Oda, T., Iacono, C., and Hirohashi, S. Pancreatic adenocarcinomas frequently show p53 gene mutations. *Am. J. Pathol.*, 142: 1534–1543, 1993.
5. Nakamori, S., Yashima, K., Murakami, Y., Ishikawa, O., Ohigashi, H., Imaoka, S., Yaegashi, S., Konishi, Y., and Sekiya, T. Association of p53 gene mutations with short survival in pancreatic adenocarcinoma. *Jpn. J. Cancer Res.*, 86: 174–181, 1995.
6. Hahn, S. A., Schutte, M., Hoque, A. T., Moskaluk, C. A., da Costa, L. T., Rozenblum, E., Weinstein, C. L., Fischer, A., Yeo, C. J., Hruban, R. H., and Kern, S. E. *DPC4*, a candidate tumor suppressor gene at human chromosome 18q21.1. *Science (Washington DC)*, 271: 350–353, 1996.
7. Bergmann, U., Funatomi, H., Yokoyama, M., Beger, H. G., and Korc, M. Insulin-like growth factor I overexpression in human pancreatic cancer: evidence for autocrine and paracrine roles. *Cancer Res.*, 55: 2007–2011, 1995.
8. Hla, T., and Neilson, K. Human cyclooxygenase-2 cDNA. *Proc. Natl. Acad. Sci. USA*, 89: 7384–7388, 1992.
9. Jones, D. A., Carlton, D. P., McIntyre, T. M., Zimmerman, G. A., and Prescott, S. M. Molecular cloning of human prostaglandin endoperoxide synthase type II and demonstration of expression in response to cytokines. *J. Biol. Chem.*, 268: 9049–9054, 1993.
10. Hamasaki, Y., Kitzler, J., Hardman, R., Nettesheim, P., and Eling, T. E. Phorbol ester and epidermal growth factor enhance the expression of two inducible prostaglandin H synthase genes in rat tracheal epithelial cells. *Arch. Biochem. Biophys.*, 304: 226–234, 1993.
11. DuBois, R. N., Awad, J., Morrow, J., Roberts, L. N., and Bishop, P. R. Regulation of eicosanoid production and mitogenesis in rat intestinal epithelial cells by transforming growth factor- α and phorbol ester. *J. Clin. Investig.*, 93: 493–498, 1994.
12. Kang, R. Y., Freire, M. J., Sigal, E., and Chu, C. Q. Expression of cyclooxygenase-2 in human and an animal model of rheumatoid arthritis. *Br. J. Rheumatol.*, 35: 711–718, 1996.
13. Singer, I. I., Kawka, D. W., Schloemann, S., Tessner, T., Riehl, T., and Stenson, W. F. Cyclooxygenase 2 is induced in colonic epithelial cells in inflammatory bowel disease. *Gastroenterology*, 115: 297–306, 1998.
14. Sawaoka, H., Kawano, S., Tsuji, S., Tsuji, M., Sun, W., Gunawan, E. S., and Hori, M. *Helicobacter pylori* infection induces cyclooxygenase-2 expression in human gastric mucosa. *Prostaglandins Leukotrienes Essent. Fatty Acids*, 59: 313–316, 1998.
15. Eberhart, C. E., Coffey, R. J., Radhika, A., Giardiello, F. M., Ferrenbach, S., and DuBois, R. N. Up-regulation of cyclooxygenase 2 gene expression in human colorectal adenomas and adenocarcinomas. *Gastroenterology*, 107: 1183–1188, 1994.
16. Sano, H., Kawahito, Y., Wilder, R. L., Hashiramoto, A., Mukai, S., Asai, K., Kimura, S., Kato, H., Kondo, M., and Hla, T. Expression of cyclooxygenase-1 and -2 in human colorectal cancer. *Cancer Res.*, 55: 3785–3789, 1995.
17. Ristimaki, A., Honkanen, N., Jankala, H., Sipponen, P., and Harkonen, M. Expression of cyclooxygenase-2 in human gastric carcinoma. *Cancer Res.*, 57: 1276–1280, 1997.
18. Hwang, D., Scollard, D., Byrne, J., and Levine, E. Expression of cyclooxygenase-1 and cyclooxygenase-2 in human breast cancer. *J. Natl. Cancer Inst.*, 90: 455–460, 1998.
19. Wilson, K. T., Fu, S., Ramanujam, K. S., and Meltzer, S. J. Increased expression of inducible nitric oxide synthase and cyclooxygenase-2 in Barrett's esophagus and associated adenocarcinomas. *Cancer Res.*, 58: 2929–2934, 1998.
20. Hida, T., Yatabe, Y., Achiwa, H., Muramatsu, H., Kozaki, K., Nakamura, S., Ogawa, M., Mitsudomi, T., Sugiura, T., and Takahashi, T. Increased expression of cyclooxygenase 2 occurs frequently in human lung cancers, specifically in adenocarcinomas. *Cancer Res.*, 58: 3761–3764, 1998.
21. Wolff, H., Saukkonen, K., Anttila, S., Karjalainen, A., Vainio, H., and Ristimaki, A. Expression of cyclooxygenase-2 in human lung carcinoma. *Cancer Res.*, 58: 4997–5001, 1998.
22. Oshima, M., Dinchuk, J. E., Kargman, S. L., Oshima, H., Hancock, B., Kwong, E., Trzaskos, J. M., Evans, J. F., and Taketo, M. M. Suppression of intestinal polyposis in Apc $\Delta 716$ knockout mice by inhibition of cyclooxygenase 2 (COX-2). *Cell*, 87: 803–809, 1996.
23. Boolbol, S. K., Dannenberg, A. J., Chadburn, A., Martucci, C., Guo, X. J., Ramonetti, J. T., Abreu, G. M., Newmark, H. L., Lipkin, M. L., DeCosse, J. J., and Bertagnolli, M. M. Cyclooxygenase-2 overexpression and tumor formation are blocked by sulindac in a murine model of familial adenomatous polyposis. *Cancer Res.*, 56: 2556–2560, 1996.
24. Liu, X. H., Yao, S., Kirschenbaum, A., and Levine, A. C. NS398, a selective cyclooxygenase-2 inhibitor, induces apoptosis and down-regulates bcl-2 expression in LNCaP cells. *Cancer Res.*, 58: 4245–4249, 1998.
25. Taketo, M. M. Cyclooxygenase-2 inhibitors in tumorigenesis (Part II). *J. Natl. Cancer Inst.*, 90: 1609–1620, 1998.
26. Hong, W. K., and Sporn, M. B. Recent advances in chemoprevention of cancer. *Science (Washington DC)*, 278: 1073–1077, 1997.
27. DuBois, R. N. Nonsteroidal anti-inflammatory drug use and sporadic colorectal adenomas. *Gastroenterology*, 108: 1310–1314, 1995.
28. Sugiura, H., Ishikura, H., Omi, M., Kaji, M., Iwai, K., Kishimoto, K., Takahashi, T., Kimura, C., Kato, H., and Yoshiki, T. Lymphokine-activated killer cytotoxicity against pancreas adenocarcinoma cell lines and vascular endothelial cells. *Pathol. Int.*, 44: 688–696, 1994.
29. Ciaparrone, M., Yamamoto, H., Yao, Y., Sgambato, A., Cattoretti, G., Tomita, N., Monden, T., Rotterdam, H., and Weinstein, I. B. Localization and expression of p27^{KIP1} in multistage colorectal carcinogenesis. *Cancer Res.*, 58: 114–122, 1998.
30. Short, B. G., Zimmerman, D. M., and Schwartz, L. W. Automated double labeling of proliferation and apoptosis in glutathione S-transferase-positive hepatocytes in rats. *J. Histochem. Cytochem.*, 45: 1299–1305, 1997.
31. Myers, J., Mehta, P., Hunter, A. W., Bernstein, S. A., and Erickson, P. A. Automated double-label immunohistochemistry. *J. Surg. Pathol.*, 1: 105–113, 1995.
32. Chomczynski, P., and Sacchi, N. Single-step method of RNA isolation by acid guanidinium thiocyanate-phenol-chloroform extraction. *Anal. Biochem.*, 162: 156–159, 1987.
33. Chretien, S., Dubart, A., Beaupain, D., Raich, N., Grandchamp, B., Rosa, J., Goossens, M., and Romeo, P. H. Alternative transcription and splicing of the human porphobilinogen deaminase gene result either in tissue-specific or in housekeeping expression. *Proc. Natl. Acad. Sci. USA*, 85: 6–10, 1988.
34. Nagel, S., Schmidt, M., Thiede, C., Huhn, D., and Neubauer, A. Quantification of Bcr-Abl transcripts in chronic myelogenous leukemia (CML) using standardized, internally controlled, competitive differential PCR (CD-PCR). *Nucleic Acids Res.*, 24: 4102–4103, 1996.
35. Finke, J., Fritzen, R., Ternes, P., Lange, W., and Dolken, G. An improved strategy and a useful housekeeping gene for RNA analysis from formalin-fixed, paraffin-embedded tissues by PCR. *Biotechniques*, 14: 448–453, 1993.
36. O'Neill, G. P., and Ford, H. A. Expression of mRNA for cyclooxygenase-1 and cyclooxygenase-2 in human tissues. *FEBS Lett.*, 330: 156–160, 1993.
37. Yamamoto, H., Soh, J. W., Shirin, H., Xing, W. Q., Lim, J. T., Yao, Y., Slosberg, E., Tomita, N., Schieren, I., and Weinstein, I. B. Comparative effects of overexpression of p27^{KIP1} and p21^{Cip1/Waf1} on growth and differentiation in human colon carcinoma cells. *Oncogene*, 18: 103–115, 1999.
38. Zimmermann, K. C., Sarbia, M., Weber, A. A., Borchard, F., Gabbert, H. E., and Schror, K. Cyclooxygenase-2 expression in human esophageal carcinoma. *Cancer Res.*, 59: 198–204, 1999.
39. Krajewska, M., Krajewski, S., Epstein, J. I., Shabaik, A., Sauvageot, J., Song, K., Kitada, S., and Reed, J. C. Immunohistochemical

- analysis of bcl-2, bax, bcl-X, and mcl-1 expression in prostate cancers. *Am. J. Pathol.*, 148: 1567–1576, 1996.
40. Giardiello, F. M., Hamilton, S. R., Krush, A. J., Piantadosi, S., Hylind, L. M., Celano, P., Booker, S. V., Robinson, C. R., and Offerhaus, G. J. Treatment of colonic and rectal adenomas with sulindac in familial adenomatous polyposis. *N. Engl. J. Med.*, 328: 1313–1316, 1993.
41. Labayle, D., Fischer, D., Vielh, P., Drouhin, F., Pariente, A., Bories, C., Duhamel, O., Troussset, M., and Attali, P. Sulindac causes regression of rectal polyps in familial adenomatous polyposis. *Gastroenterology*, 101: 635–639, 1991.
42. Tonelli, F., and Valanzano, R. Sulindac in familial adenomatous polyposis. *Lancet*, 342: 1120, 1993.
43. Thun, M. J., Namboodiri, M. M., and Heath, C. J. Aspirin use and reduced risk of fatal colon cancer. *N. Engl. J. Med.*, 325: 1593–1596, 1991.
44. Schreinemachers, D. M., and Everson, R. B. Aspirin use and lung, colon, and breast cancer incidence in a prospective study. *Epidemiology*, 5: 138–146, 1994.
45. Takahashi, M., Furukawa, F., Toyoda, K., Sato, H., Hasegawa, R., Imaida, K., and Hayashi, Y. Effects of various prostaglandin synthesis inhibitors on pancreatic carcinogenesis in hamsters after initiation with *N*-nitrosobis(2-oxopropyl)amine. *Carcinogenesis (Lond.)*, 11: 393–395, 1990.
46. Levy, G. N. Prostaglandin H synthases, nonsteroidal anti-inflammatory drugs, and colon cancer. *FASEB J.*, 11: 234–247, 1997.
47. Reddy, B. S., Rao, C. V., and Seibert, K. Evaluation of cyclooxygenase-2 inhibitor for potential chemopreventive properties in colon carcinogenesis. *Cancer Res.*, 56: 4566–4569, 1996.
48. Takahashi, M., Fukutake, M., Yokota, S., Ishida, K., Wakabayashi, K., and Sugimura, T. Suppression of azoxymethane-induced aberrant crypt foci in rat colon by nimesulide, a selective inhibitor of cyclooxygenase 2. *J. Cancer Res. Clin. Oncol.*, 122: 219–222, 1996.
49. Goldman, A. P., Williams, C. S., Sheng, H., Lamps, L. W., Williams, V. P., Pairet, M., Morrow, J. D., and DuBois, R. N. Meloxicam inhibits the growth of colorectal cancer cells. *Carcinogenesis (Lond.)*, 19: 2195–2199, 1998.
50. Tsujii, M., Kawano, S., Tsuji, S., Sawaoka, H., Hori, M., and DuBois, R. N. Cyclooxygenase regulates angiogenesis induced by colon cancer cells. *Cell*, 93: 705–716, 1998.
51. Koga, H., Sakisaka, S., Ohishi, M., Kawaguchi, T., Taniguchi, E., Sasatomi, K., Harada, M., Kusaba, T., Tanaka, M., Kimura, R., Nakashima, Y., Nakashima, O., Kojiro, M., Kurohiji, T., and Sata, M. Expression of cyclooxygenase-2 in human hepatocellular carcinoma: relevance to tumor dedifferentiation. *Hepatology*, 29: 688–696, 1999.
52. Tucker, O. N., Dannenberg, A. J., Yang, E. K., Zhang, F., Teng, L., Daly, J. M., Soslow, R. A., Masferrer, J. L., Woerner, B. M., Koki, A. T., and Fahey, T. R. Cyclooxygenase-2 expression is up-regulated in human pancreatic cancer. *Cancer Res.*, 59: 987–990, 1999.
53. Sorli, C. H., Zhang, H. J., Armstrong, M. B., Rajotte, R. V., Maclouf, J., and Robertson, R. P. Basal expression of cyclooxygenase-2 and nuclear factor-interleukin 6 are dominant and coordinately regulated by interleukin 1 in the pancreatic islet. *Proc. Natl. Acad. Sci. USA*, 95: 1788–1793, 1998.
54. Zeldin, D. C., Foley, J., Boyle, J. E., Moomaw, C. R., Tomer, K. B., Parker, C., Steenbergen, C., and Wu, S. Predominant expression of an arachidonate epoxygenase in islets of Langerhans cells in human and rat pancreas. *Endocrinology*, 138: 1338–1346, 1997.
55. Ishikawa, O., Ohigashi, H., Imaoka, S., Nakai, I., Mitsuo, M., Weide, L., and Pour, P. M. The role of pancreatic islets in experimental pancreatic carcinogenicity. *Am. J. Pathol.*, 147: 1456–1464, 1995.