

Active Matrix Metalloproteinase 9 Expression Is Associated with Primary Glioblastoma Subtype¹

Gheeyoung Choe, Jun K. Park,
Lisa Jouben-Steele, Thomas J. Kremen,
Linda M. Liau, Harry V. Vinters,
Timothy F. Cloughesy, and Paul S. Mischel²

Departments of Pathology and Laboratory Medicine [G. C., J. K. P., L. J.-S., H. V. V., P. S. M.] and Neurosurgery [T. J. K., L. M. L.] and the Henry E. Singleton Brain Tumor Program [T. J. K., L. M. L., T. F. C., P. S. M.], University of California Los Angeles, Los Angeles, California 90095-1732; Miami Dade Medical Examiners Office, Miami, Florida [L. J.-S.]; and Department of Pathology, Seoul National University College of Medicine, Seoul 110-744, Korea [G. C.]

ABSTRACT

Purpose: Glioblastoma multiforme (GBM) is an aggressive cancer characterized by extensive brain invasion. Matrix metalloproteinase (MMP)-9 plays a major role in this process. GBMs can be divided into two subtypes based on distinct clinical and molecular features. Primary GBMs arise *de novo* and frequently overexpress the epidermal growth factor receptor (EGFR) and its ligand-independent variant, EGFR variant III (EGFRvIII); secondary GBMs progress from a lower grade glioma and commonly harbor p53 mutations. Because EGFR signaling promotes MMP-9 expression and activation in other cancer cell types, we analyzed whether MMP-9 was associated with primary GBM subtype.

Experimental Design: Autopsies were performed on 20 GBM patients, and MMP expression was assessed by gelatin zymography in the tumor and the adjacent normal brain. EGFR, EGFRvIII, p53, and activated mitogen-activated protein kinase/extracellular signal-regulated kinase were assessed by immunohistochemistry, and associations between molecular phenotype and MMP-9 expression were analyzed.

Received 11/26/01; revised 4/19/02; accepted 6/3/02.

The costs of publication of this article were defrayed in part by the payment of page charges. This article must therefore be hereby marked *advertisement* in accordance with 18 U.S.C. Section 1734 solely to indicate this fact.

¹ Supported by Grant U01 CA88127 from the National Cancer Institute and Grant K08NS43147-01 from the National Institute of Neurological Disorders and Stroke, NIH (to P. S. M.). P. S. M. was also supported by a Henry E. Singleton Brain Tumor Fellowship, a Stop Cancer Award, a generous donation from the Kevin Riley family to the University of California Los Angeles Comprehensive Brain Tumor Program, and the Harry Allgauer Foundation through The Doris R. Ullmann Fund for Brain Tumor Research Technologies. G. C. was supported by a postdoctoral fellowship from Korea Science & Engineering Foundation.

² To whom requests for reprints should be addressed, at Department of Pathology and Laboratory Medicine, University of California Los Angeles, 10833 Le Conte Avenue, Los Angeles, California 90095-1732.

Results: Latent MMP-9 was detected in 90% of tumors, and active MMP-9 was found in 50% of tumors. MMP-9 was not detected in any of the normal brain samples ($P < 0.001$). More importantly, primary GBMs were significantly more likely than secondary GBMs to contain active MMP-9 (69% of primary and 14% of secondary GBMs contained active MMP-9; $P = 0.027$). Active MMP-9 was observed in 73% of EGFR-overexpressing/wild-type p53-staining tumors but in only 20% of EGFR-negative/aberrant p53-staining tumors ($P = 0.072$). Active MMP-9 expression was even more strongly correlated with EGFRvIII expression, occurring in 83% of the EGFRvIII-immunopositive tumors but in none of the EGFRvIII-negative tumors ($P = 0.0004$). Extracellular signal-regulated kinase activation was also strongly correlated with EGFRvIII expression ($P < 0.0001$) and with MMP-9 activation ($P = 0.003$).

Conclusions: These results identify a novel association between MMP-9 activation and primary GBM subtype and suggest that primary GBM patients, especially those whose tumors express EGFRvIII, may benefit from anti-MMP therapy.

INTRODUCTION

GBM³ is a highly aggressive cancer characterized by extensive brain invasion. This infiltrative nature makes curative surgical resection nearly impossible and contributes to the short median survival of GBM patients. Recent studies focusing on the mechanisms of GBM invasion suggest that MMPs play a critical role in this process. MMPs enhance tumor cell invasion by degrading extracellular matrix proteins, by activating signal transduction cascades that promote motility (1), and by solubilizing extracellular matrix-bound growth factors (2, 3). In addition, MMPs can cleave and activate other growth factors, such as transforming growth factor β (2, 4), that are also implicated in GBM motility and proliferation. MMPs also regulate tumor angiogenesis and may be required for the angiogenic switch that occurs during tumor neovascularization (5). MMP-9 and MMP-2 are secreted by GBM cells, and their mRNA and protein levels are elevated in patient biopsy tissue (6–14). Furthermore, the levels of these two MMPs are highly correlated with the histological grade of malignancy (13). MMP-9 and MMP-2 promote GBM invasion *in vitro* and in xenograft models (8, 11, 12, 15–20), and their inhibition dramatically reduces the invasive phenotype (15, 16).

Despite identical histopathology, GBMs are not a homo-

³ The abbreviations used are: GBM, glioblastoma multiforme; MMP, matrix metalloproteinase; EGFR, epidermal growth factor receptor; EGFRvIII, EGFR variant III; ERK, extracellular signal-regulated kinase; MAPK, mitogen-activated protein kinase; phospho-, phosphorylated; PI3'K, phosphatidylinositol 3-kinase.

Table 1 Patient characteristics

| Case | Sex | Age (yrs) | Type | Survival (DSD) ^a | Radiation therapy | Chemotherapy ^b |
|------|-----|-----------|-----------|-----------------------------|-------------------|---------------------------|
| 1 | M | 69 | Primary | 479 | + | 1, 7, 12, 14 |
| 2 | M | 39 | Secondary | 3634 | + | 1, 2, 12 |
| 3 | M | 25 | Secondary | 4512 | + | 1, 4, 6, 8, 12, 15 |
| 4 | F | 65 | Primary | 259 | + | 12 |
| 5 | F | 48 | Primary | 519 | + | 1, 3, 6, 10, 12 |
| 6 | M | 75 | Primary | 238 | + | 1 |
| 7 | F | 24 | Secondary | 1865 | + | 6, 8, 12, 13 |
| 8 | M | 40 | Primary | 671 | + | 1, 3, 6, 8, 12, 13, 16 |
| 9 | M | 51 | Primary | 652 | + | 1, 3, 6, 12, 13 |
| 10 | M | 54 | Primary | 533 | + | 1, 2, 3, 6, 12, 13 |
| 11 | M | 58 | Primary | 461 | + | 6, 12 |
| 12 | M | 66 | Primary | 429 | + | 1, 3, 6, 12, 13 |
| 13 | F | 69 | Primary | 539 | + | 1, 10, 12 |
| 14 | M | 67 | Primary | 38 | + | |
| 15 | F | 31 | Secondary | 2703 | + | 2, 6, 8, 11, 13, 17 |
| 16 | M | 29 | Secondary | 849 | + | 3, 8, 12 |
| 17 | M | 27 | Secondary | 1383 | + | 8, 12, 13 |
| 18 | M | 60 | Primary | 207 | + | 12 |
| 19 | M | 45 | Primary | 430 | + | 1, 3, 5, 6, 12, 13 |
| 20 | M | 27 | Secondary | 1349 | + | 2, 6, 9, 13 |

^a DSD, days since diagnosis.

^b 1, acutane; 2, BCNU, carmustine; 3, caroplatin; 4, CCNU, lomustine; 5, cereport; 6, CPT-11, irinotecan; 7, hydroxyurea; 8, PCV, procarbazine/lomustine/vincristine; 9, procarbazine; 10, SU101 or procarbazine; 11, SU5416; 12, tamoxifen; 13, temodal; 14, TNP-470; 15, vincristine; 16, VP-16; 17, 6-thioguanine.

geneous group of tumors. There are at least two GBM subtypes with distinct clinical and molecular features. Primary GBMs are *de novo* high-grade tumors that exhibit a high frequency of EGFR overexpression and/or amplification (21, 22). Primary GBMs also commonly express EGFRvIII, a constitutively active mutant EGFR (23–26). In contrast, secondary GBMs present as lower grade gliomas that progress into GBMs. They have a high incidence of p53 mutations but rarely contain EGFR abnormalities (21, 27, 28).

EGFR activation may promote MMP-9 expression and activation in other cancer cell types (29–34). Therefore, we hypothesized that MMP-9 expression and activation may be associated with primary GBMs. We performed autopsies on 20 GBM patients and analyzed MMP expression as well as EGFR, EGFRvIII, p53, and phospho-ERK status in the tumor and the adjacent normal brain. We then analyzed the associations between MMP expression and clinical and molecular GBM subtype, and we determined the prognostic effect of MMP expression on overall survival.

MATERIALS AND METHODS

Patient Tissue Specimens. Twenty consecutive brain autopsies of GBM patients were examined. Informed consent for brain autopsy was obtained from each subject's guardian in accordance with UCLA Institutional Review Board Policies. The patient characteristics are listed in Table 1. Autopsies were performed within 24 h of death. At the time of autopsy, brains were transversely cut, photographed, and analyzed by a neuropathologist (P. S. M., L. J-S., and H. V. V.). Non-necrotic samples were taken from multiple sites within the tumor and normal brain tissue. Samples were snap frozen in liquid nitrogen and stored at -80°C . Subsequently, brains were fixed in 10% buffered formalin, and 1-cm-thick transverse slices were examined.

Sections were processed for histological examination, stained with H&E, and examined by a neuropathologist (G. C. or P. S. M.). The presence of viable tumor in the samples and the lack of tumor in the corresponding normal brain tissue were verified histologically (Fig. 1, B and C).

Gelatin Zymography. Gelatin zymography was performed as described previously (12). Snap-frozen tissues were thawed and weighed. Samples were homogenized using the Tissue Tearer in radioimmunoprecipitation assay lysis buffer. Sample protein concentrations were normalized after quantitation with the BCA Protein Assay Kit (Pierce Chemical Co., Rockford, IL). Ten μg of total protein were electrophoresed on 10% denaturing SDS polyacrylamide gels containing 1 mg/ml gelatin. After electrophoresis, the gels were rinsed twice in 2.5% Triton X-100 and incubated overnight at 37°C in activation buffer [50 mM Tris (pH 8.0) and 10 mM CaCl_2]. The gels were stained with 0.5% Coomassie Blue and destained in H_2O . The latent form of MMP-9 was detected as a clear band at M_r 92,000 zymogen. In addition, a M_r 97,000 form of latent MMP-9 was also found in some central nervous system tumors (19). The active form of MMP-9 was detected as a clear band at M_r 83,000. MMP-2 was secreted as a M_r 72,000 zymogen, which is cleaved into a M_r 66,000 active form. The identity of all MMP bands observed by gelatin zymography was confirmed by Western blot analysis (data not shown).

Quantitation of MMP Expression and Activation Levels. Densitometric analysis was performed using the AlphaImager and AlphaEase software (Alpha Innotech, San Leandro, CA). The densities of bands representing MMP-2 and MMP-9 pro- and active forms were compared between the tumor and the corresponding normal sample from each patient. Conditioned medium from U87MG cells was also run on each gel so that MMP levels in different gels could be normalized and com-

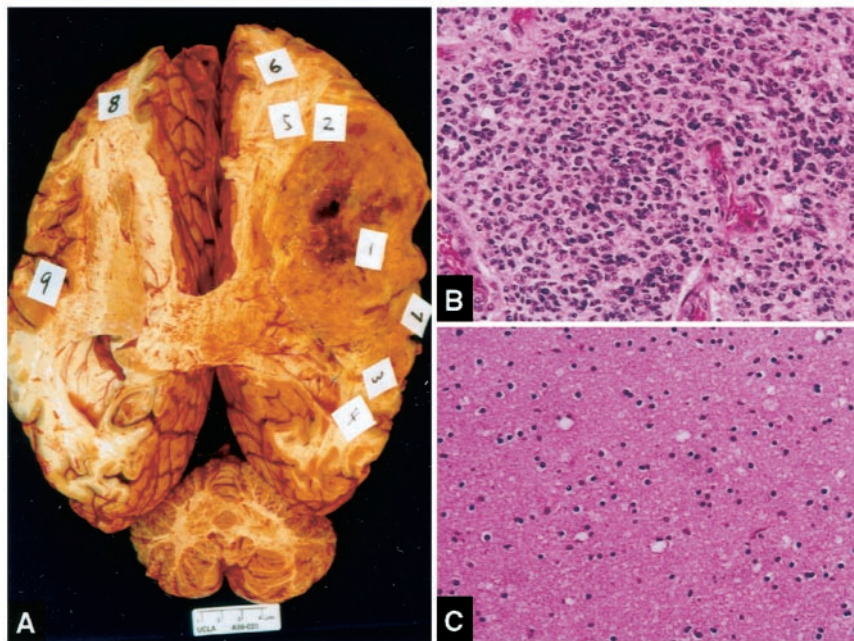


Fig. 1 Topographic dissection of GBM autopsy brains. Multiple regions from each tumor including the center (1) and contralateral normal brain tissue (8) were taken, snap frozen, and subsequently analyzed for MMP expression (A). Histological examination of the tissue taken from the center of the tumor (1; B) and contralateral normal brain tissue (8; C), demonstrating the presence of viable tumor in the center of the lesion and the absence of tumor in the contralateral brain tissue.

pared. For characterization of MMP-9 as a dichotomous variable, a sample was considered to have activated MMP-9 when the densitometric ratio of tumor:U87MG conditioned medium was >0.75 . This corresponded with clear visual identification of the band. In addition, we also analyzed densitometry by comparing density of tumor and density of normal brain tissue. This alternative method of calculating MMP level showed essentially the same results (data not shown).

Immunohistochemistry. Formalin-fixed, paraffin-embedded blocks, which corresponded to the frozen samples for gelatin zymography, were selected for examination. Tumor and normal brain tissue were stained in every case. Paraffin-embedded specimens were sectioned at $4\ \mu\text{m}$ and immunostained with mouse monoclonal antibodies EGFR (clone 31G7; Zymed, San Francisco, CA), EGFRvIII (clone L8A4; a generous gift from Dr. Darell Bigner), and p53 Ab-2 (clone 1801; Calbiochem, La Jolla, CA) and with a rabbit polyclonal anti-phospho-ERK antibody (Cell Signaling, Beverly, MA). Sections were baked at 60°C and deparaffinized with xylenes and graded ethanols. Slides were then treated with 3% hydrogen peroxide in methanol to quench endogenous peroxidase activity and with heat-induced antigen retrieval [for p53, EGFRvIII, and phospho-ERK, $0.01\ \text{M}$ citrate buffer (pH 6) for 25 min in vegetable steamer; for EGFR, pronase ($0.03\ \text{g/ml}$ of $0.05\ \text{M}$ Tris buffer, pH 7.4) at 37°C for 8 min]. Immunostaining involved sequential applications of primary antibody (EGFR at 1:150, EGFRvIII at 1:400, p53 at 1:300, and phospho-ERK at 1:200) for 16 h at 4°C , followed by antimouse or antirabbit biotinylated immunoglobulins (Vector) at 1:100 dilution for 1 h and, finally, avidin-biotin complex (Elite ABC; Vector Laboratories) for 1 h. Negative control slides received normal mouse serum (DAKO) as the primary antibody. Diaminobenzidine tetrahydrochloride was used as the enzyme substrate to visualize specific antibody localization, and Harris hematoxylin was used as a nuclear

counterstain. For EGFR immunohistochemistry, tumors demonstrating strong EGFR immunopositivity in $>20\%$ of tumor cells were considered to be positive (30). For EGFRvIII, tumors that contained at least focal moderate to strong immunoreactivity were considered positive, and for p53 immunohistochemistry, nuclear staining of $>5\%$ of tumor cells was regarded as positive (35). For phospho-ERK, tumors that focally contained $>5\%$ positive nuclear staining were considered positive.

Statistical Analysis. Statistical analysis was performed using the PC-SAS for Windows software program, version 8.01 (SAS Institute Inc., Cary, NC). Univariate analysis of survival probability was performed as outlined by Kaplan and Meier. Log-rank test was performed using the LIFETEST procedure. Fisher's exact test was used to analyze the associations between dichotomous pathological variables (*i.e.*, active MMP-9 status, p53 status, primary *versus* secondary GBM subtype). Fisher's exact tests were performed using software available on the Simple Interactive Statistical website.⁴ All tests were two-tailed.

RESULTS

Analysis of Autopsy Brains from GBM Patients.

Whole brain autopsies were performed on 20 consecutive GBM patients. Patient and disease characteristics and treatments administered are presented in Table 1. Thirteen of 20 patients were diagnosed with a GBM on their initial biopsy (primary GBMs). Seven of 20 patients initially presented with lower grade astrocytomas that progressed to GBMs, as verified by a subsequent biopsy (secondary GBMs). At the time of autopsy, tissue was taken from multiple regions within the tumor and contralateral

⁴ <http://home.clara.net/sisa/index.htm>.

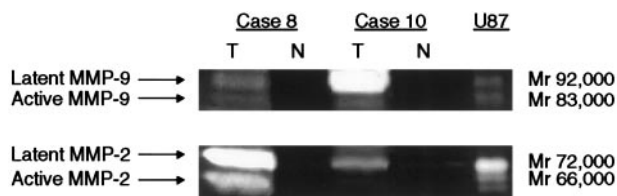


Fig. 2 Gelatin zymographic analysis of MMP expression. Gelatin zymogram of lysates from the tumor (T) or contralateral normal brain tissue (N) of two representative cases.

Table 2 MMP expression

| Sample | Latent MMP-9 | Active MMP-9 | Latent MMP-2 | Active MMP-2 |
|--------------|--------------|--------------|--------------|--------------|
| Tumor | 18/20 | 10/20 | 5/20 | 3/20 |
| Normal brain | 0/20 | 0/20 | 0/20 | 0/20 |
| <i>P</i> | 0.0001 | 0.0002 | 0.02 | 0.12 |

normal brain tissue (Fig. 1A), and the presence or absence of tumor was confirmed microscopically by a board-certified neuropathologist (P. S. M.; Fig. 1, B and C). Only samples that did not contain significant amounts of necrotic tissue were used for analysis.

MMP Expression in Tumors. Samples were analyzed for MMP-9 expression and activation by gelatin zymography, as described previously (12). Because multiple regions of each brain were sampled at the time of autopsy, MMP expression and activation in each tumor sample were compared with those of the contralateral normal brain tissue (Fig. 2). Latent MMP-9 was detected in 18 of 20 (90%) tumor samples but was not found in any of the 20 contralateral normal brain tissue samples (Fisher's exact test, $P < 0.0001$; Table 2). Similarly, the active form of MMP-9 was detected in 10 of 20 tumor samples (50%) but was not found in any of the 20 contralateral normal brain samples (Fisher's exact test, $P = 0.0002$). Therefore, MMP-9 expression was significantly elevated in the tumor samples. In addition to MMP-9, MMP-2 was detected in 5 of 20 tumor samples (25%). In contrast, latent MMP-2 was barely detectable or absent in all of the 20 normal brain samples (Fisher's exact test, $P = 0.02$). Active MMP-2 was observed in the tumor in 3 of 20 patients but was not detected in any of the normal brain samples (Fisher's exact test, $P = 0.12$; Fig. 2; Table 2).

Association between MMP Expression and GBM Subtype. Primary GBMs have a high incidence of EGFR overexpression and amplification, and studies of other cancer cell types suggest that EGFR activation may promote MMP-9 expression and activation (30–35). However, the possible association of MMPs with GBM subtype has not been well defined. In our study population, 13 patients presented with *de novo* GBM (primary GBMs), and 7 patients had GBMs that progressed from lower grade gliomas (secondary GBMs; Table 1). Active MMP-9 was found in 9 of 13 (69%) primary GBMs and only 1 of 7 (14%) secondary GBMs (Fisher's exact test, $P = 0.027$; Table 3). Thus, active MMP-9 expression was significantly associated with primary GBM subtype. Expression of latent MMP-9 showed a trend toward correlation with primary GBM

Table 3 Association between active MMP-9 and primary GBMs^a

| | + Active MMP-9 | – Active MMP-9 |
|----------------|----------------|----------------|
| Primary GBMs | 9 | 4 |
| Secondary GBMs | 1 | 6 |

^a $P = 0.027$.

subtype, although it did not reach statistical significance ($P = 0.21$).

To explore the possible association between MMP expression and EGFR, EGFRvIII, and/or p53 mutations, we performed EGFR and p53 immunohistochemical analysis. Diffuse strong EGFR immunoreactivity was observed in 11 of 13 primary GBMs (86%) and 2 of 7 secondary GBMs (29%; Fisher's exact test, $P = 0.02$; Fig. 3; Table 4). Because p53 expression is tightly regulated, wild-type p53 is not detectable by immunohistochemistry, whereas mutant p53 accumulates in cells (36). Abnormal p53 immunopositivity was detected in 1 of 13 primary GBMs (8%) and 6 of 7 secondary GBMs (85.7%; Fisher's exact test, $P = 0.001$; Fig. 3; Table 4). Therefore, EGFR and p53 immunoreactivity were significantly associated with primary and secondary GBMs, respectively. Active MMP-9 was observed in 8 of 13 (62%) EGFR-positive tumors and 2 of 7 (29%) EGFR-negative tumors ($P = 0.15$). Active MMP-9 was detected in 9 of 13 (69%) p53-immunonegative tumors and 1 of 7 (14%) p53-immunopositive tumors ($P = 0.027$). Next, we asked whether tumors that were EGFR+/p53– differed from EGFR–/p53+ tumors in their MMP-9 activation. Active MMP-9 was detected in 8 of 11 EGFR+/p53– tumors (73%) but in only 1 of 5 EGFR–/p53+ tumors (20%; $P = 0.072$; Table 5). Therefore, active MMP-9 expression was also associated with the molecular phenotype of primary GBMs.

Because EGFR-overexpressing GBMs usually also express the variant ligand-independent EGFRvIII mutant (26), we next assessed EGFRvIII expression by immunohistochemistry. EGFRvIII was diffusely positive in 8 of 20 GBMs and focally positive in an additional 4 cases. Active MMP-9 was detected in 10 of 12 (83%) EGFRvIII-expressing tumors but in none of the EGFRvIII-negative tumors (Fig. 4; Table 5; Fisher's exact test, $P = 0.0004$). In GBM cells, EGFRvIII promotes constitutive MAPK/ERK activation (26, 37). Therefore, to determine a potential link between constitutive receptor-induced signaling and MMP-9 activation, we analyzed MAPK/ERK activation by immunohistochemistry. Phosphorylated ERK was detected in 11 of 12 (92%) EGFRvIII-expressing tumors and 0 of 8 EGFRvIII-negative tumors (Fisher's exact test, $P < 0.0001$). ERK activation was also strongly correlated with MMP-9 activation; active MMP-9 was detected in 9 of 11 (82%) phospho-ERK-positive cases but only 1 of 9 (11%) ERK-negative cases (Fig. 4; Table 5; Fisher's exact test, $P = 0.003$).

MMP-9 Expression: Prognostic Implications. In patients whose tumors contained active MMP-9, median overall survival was 470 days, compared with a median survival of 1116 days for patients whose tumors did not contain detectable levels of active MMP-9 (log-rank test, $P = 0.0085$). Therefore, expression of active MMP-9 was significantly associated with shorter overall survival from time of initial biopsy. However, primary GBMs arise as high-grade lesions, whereas secondary

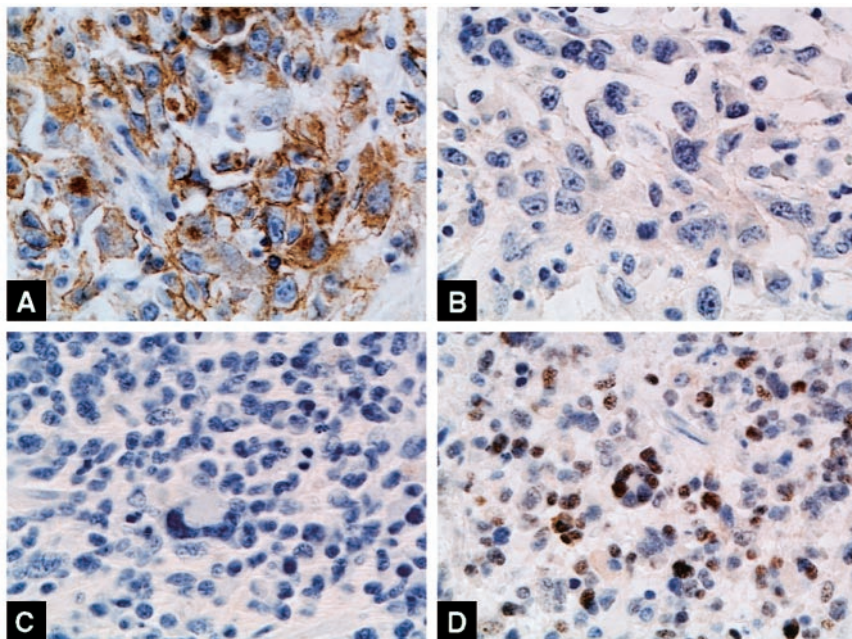


Fig. 3 EGFR and p53 immunohistochemical analysis. Representative images demonstrating diffuse EGFR immunopositivity (A) and lack of p53 immunoreactivity (B) in a primary GBM and lack of EGFR immunopositivity (C) with accumulation of aberrant p53 (D) in a secondary GBM.

Table 4 Association of GBM subtype with EGFR and p53 immunohistochemical staining

| Immunostain | GBM subtype | Positive (%) | P |
|-------------|-------------|--------------|-------|
| EGFR | Primary | 11/13 (85%) | 0.02 |
| | Secondary | 2/7 (29%) | |
| p53 | Primary | 1/13 (8%) | 0.001 |
| | Secondary | 6/7 (86%) | |

Table 5 Association of active MMP-9 expression with EGFR, p53, EGFRvIII, and phospho-ERK immunohistochemical staining

| Immunohistochemical status | Active MMP-9 (%) | P |
|----------------------------------|------------------|--------|
| EGFR positive | 8/13 (62%) | 0.15 |
| EGFR negative | 2/7 (29%) | |
| p53 positive (aberrant staining) | 1/7 (14%) | 0.027 |
| p53 negative (wild-type) | 9/13 (69%) | |
| EGFR+/p53- | 8/11 (73%) | 0.072 |
| EGFR-/p53+ | 1/5 (20%) | |
| EGFRvIII positive | 10/12 (83%) | 0.0004 |
| EGFRvIII negative | 0/8 (0%) | |
| Phospho-ERK positive | 9/11 (82%) | 0.003 |
| Phospho-ERK negative | 1/9 (11%) | |

GBMs arise as lower grade lesions; therefore, the overall survival from time of initial diagnosis is shorter in primary GBM patients. Thus, we hypothesized that the prognostic effect of active MMP-9 on survival was due to its association with primary GBM subtype. As expected, the median overall survival of the primary GBM patients was 461 days, compared with 1865 days for patients with secondary GBMs (log-rank test, $P < 0.001$). Therefore, we compared the mortality rates of primary GBM patients \pm active MMP-9 expression. The mortality rate for primary GBM patients whose tumors expressed active

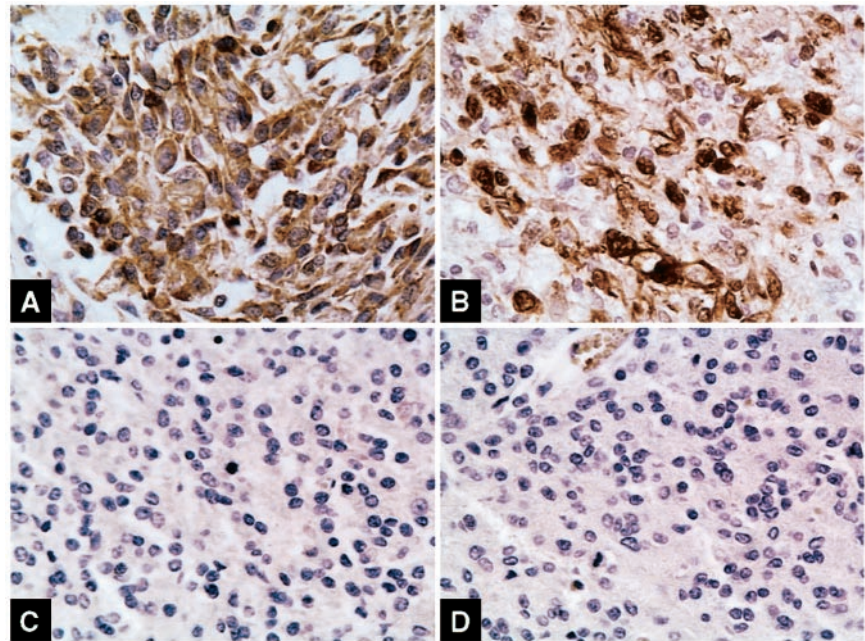
MMP-9 was 7.29 ± 2.43 deaths/100 person-months, whereas the mortality rate for patients with active MMP-9-negative primary GBMs was 6.38 ± 3.19 deaths/100 person-months. Thus, the prognostic significance of active MMP-9 on overall survival is largely the result of its association with primary GBM subtype.

DISCUSSION

GBMs aggressively invade the surrounding brain, making curative surgical resection almost impossible. As a result, survival times for GBM patients are among the shortest of all cancers (38). However, GBM patients are not a homogeneous group. Despite identical histopathology, there are at least two GBM subtypes with distinct clinical and molecular features. Primary GBMs are *de novo* high-grade lesions that harbor a high incidence of EGFR overexpression. Secondary GBMs progress from lower grade gliomas and are associated with p53 mutations (21, 28). It is not known whether MMP expression and activation are associated with a particular GBM subtype, and a possible association between MMPs expression and EGFR and/or p53 mutations has yet to be defined. In this study, we demonstrate that latent and active MMP-9 are significantly elevated in GBMs and show that MMP-9 activation is significantly associated with primary GBM subtype. Furthermore, we demonstrate that MMP-9 activation is strongly associated with the molecular phenotype of primary GBM subtype, particularly with EGFRvIII expression.

We analyzed MMP expression and activation in 20 GBMs and found that latent and active MMP-9 were significantly elevated in GBMs (Fig. 2; Table 2). We also observed that MMP-2 was elevated in tumor samples, but to a lesser degree than MMP-9. These findings are consistent with clinical studies demonstrating that MMP-9 is elevated in glioma biopsies (6–14). Our findings are also in line with experimental observations

Fig. 4 EGFRvIII and phospho-ERK immunohistochemical analysis. Representative images demonstrating diffuse EGFRvIII immunopositivity (A) and abundant phospho-ERK immunoreactivity (B) in an active MMP-9-positive primary GBM and a lack of EGFRvIII immunopositivity (C) and phospho-ERK staining (D) in a primary GBM lacking MMP-9 activity.



demonstrating the role for MMP-9 and MMP-2 in glioma invasion *in vitro* and in animal invasion models (6–9, 15, 16, 39–44).

More importantly, we show that active MMP-9 was significantly associated with primary GBMs (Table 3). To the best of our knowledge, this is the first demonstration of an association between MMP expression and GBM subtype. In support of this, we found that patients whose tumors contain active MMP-9 have a significantly shorter overall median survival from the time of initial diagnosis relative to patients whose tumors do not contain active MMP-9. This prognostic effect was dramatic, but it appears to be almost entirely dependent upon the association between active MMP-9 expression and primary GBM subtype.

Because a possible association between EGFR overexpression and p53 mutation and MMP-9 has not yet been defined, we performed p53 and EGFR immunohistochemical analysis. As expected, we found that EGFR immunoreactivity was significantly associated with primary GBMs and that aberrant p53 immunoreactivity was associated with secondary GBMs (Table 4; Fig. 3). These results are consistent with previous studies (28). Having established that immunostaining was correlated with clinical subtype, we analyzed the potential association between active MMP-9 expression and EGFR and p53 immunohistochemical expression. EGFR+/p53– tumors were much more likely to contain active MMP-9 than EGFR–/p53+ tumors were (Table 5). Although this result did not quite reach statistical significance ($P = 0.072$), it suggests a link between MMP-9 activation and the molecular phenotype of primary GBMs. EGFR-overexpressing tumors usually also overexpress the EGFRvIII variant, which is capable of ligand-independent signaling (25). We therefore also analyzed the association between EGFRvIII expression and MMP-9 activation. EGFRvIII expression was highly correlated with MMP-9 activation. In GBM cells, EGFRvIII leads to constitutive ERK activation (26,

37, 45), and ERK activation has recently been shown to play a critical role in MMP-9 activation in GBM cells (40). Our finding that EGFRvIII-expressing GBMs are significantly associated with ERK activation and MMP-9 expression suggests a potential pathway linking these membrane-bound events with downstream MMP-9 activation.

Our results suggesting an association between EGFR signaling and MMP-9 activation are consistent with the work of Cox *et al.* (30), who showed that a significant proportion of non-small cell lung cancers coexpress MMP-9 and EGFR. Our results are also in line with other reports demonstrating that EGFR signaling promotes MMP-9 activation in human cancer cell lines (29–34). There are multiple potential mechanisms that may be involved in EGFR-mediated MMP-9 activation, including: (a) regulation of MMP-9 transcription; (b) localization of pro-MMP-9 to the leading edge of invasive cells; and (c) proteolytic cleavage of the pro-enzyme (29–34). In squamous cancer cells, EGFR signaling promotes MMP-9 expression via persistent activation of the ERK pathway (46) and possibly via p38 MAPK activation (47). Ellerbroek *et al.* (34) recently demonstrated a role for EGFR-mediated activation of PI3'K in promoting MMP-9 expression in ovarian cancer cells. Therefore, multiple signaling pathways downstream of EGFR may enhance MMP-9 expression and activation in cancer cells.

Careful analysis of our data reveals that there is a significantly stronger association between primary GBM subtype and active MMP-9 expression than there is between primary GBM subtype and expression of pro-MMP-9. This result raises two alternative possibilities. First, we identified a weak association between primary GBM and latent MMP-9 expression ($P = 0.21$). It is possible that latent MMP-9 expression might also be significantly associated with primary GBM subtype in a larger study cohort. Alternatively, it is possible that some of the factors that regulate MMP-9 activation are more highly expressed in

primary GBMs. A number of proteases including trypsin, chymase, tissue kallikrein, plasmin, and other MMPs promote MMP-9 activation (48), and recent studies suggest that a converging cascade activated by the urokinase-type plasminogen activator/plasmin system and MMP-3 enhances MMP-9 activation and tumor cell invasion (48). This pathway is antagonized by thrombospondin 1 (49), suggesting an additional route by which MMP-9 activation can be regulated. In the future, it will be important to determine the contribution of these proteolytic cascades in regulating the preferential activation of MMP-9 in primary GBMs. In addition, EGFR signaling may promote MMP-9 activation by enhancing its cell surface association, which appears to be PI3'K dependent (34). Because the PI3'K pathway is often constitutively activated in primary GBMs either by EGFR overexpression or phosphatase and tensin homologue (PTEN) loss, it will be important to determine the role of PI3'K signaling in promoting MMP-9 activation and GBM invasion in primary GBMs.

In conclusion, our study demonstrates that active MMP-9 is significantly associated with primary GBM subtype and suggests that EGFRvIII overexpression may promote MMP-9 activation, possibly via activation of MAPK/ERK. This work further demonstrates that, despite identical microscopic appearance, primary and secondary GBMs are biologically distinct tumors and suggests that primary GBM patients may specifically benefit from anti-MMP therapy. In the future, it will be important to directly determine the effect of EGFRvIII signaling on MMP-9 activation in GBM cells and to assess the role of ERK activation in promoting this event.

ACKNOWLEDGMENTS

We gratefully acknowledge Dr. Jeffrey A. Gornbein for assistance with statistical analyses and Dr. Peter Shintaku for assistance with immunohistochemistry. We also thank Dr. Deborah M. Kado, Shane G. Smith, and Kan V. Lu for helpful discussions and critical reading of the manuscript. We are grateful to Dr. Darell Bigner for the generous gift of the L8A4 anti-EGFRvIII antibody.

REFERENCES

- Giannelli, G., Falk-Marzillier, J., Schiraldi, O., Stetler-Stevenson, W. G., and Quaranta, V. Induction of cell migration by matrix metalloproteinase-2 cleavage of laminin-5. *Science (Wash. DC)*, *277*: 225–228, 1997.
- McCawley, L. J., and Matrisian, L. M. Matrix metalloproteinases: they're not just for matrix anymore! *Curr. Opin. Cell Biol.*, *13*: 534–540, 2001.
- Dong, J., Opreko, L. K., Dempsey, P. J., Lauffenburger, D. A., Coffey, R. J., and Wiley, H. S. Metalloproteinase-mediated ligand release regulates autocrine signaling through the epidermal growth factor receptor. *Proc. Natl. Acad. Sci. USA*, *96*: 6235–6240, 1999.
- Platten, M., Wick, W., and Weller, M. Malignant glioma biology: role for TGF- β in growth, motility, angiogenesis, and immune escape. *Microsc. Res. Tech.*, *52*: 401–410, 2001.
- Bergers, G., Brekken, R., McMahon, G., Vu, T. H., Itoh, T., Tamaki, K., Tanzawa, K., Thorpe, P., Itohara, S., Werb, Z., and Hanahan, D. Matrix metalloproteinase-9 triggers the angiogenic switch during carcinogenesis. *Nat. Cell Biol.*, *2*: 737–744, 2000.
- Nakada, M., Nakamura, H., Ikeda, E., Fujimoto, N., Yamashita, J., Sato, H., Seiki, M., and Okada, Y. Expression and tissue localization of membrane-type 1, 2, and 3 matrix metalloproteinases in human astrocytic tumors. *Am. J. Pathol.*, *154*: 417–428, 1999.
- Rooprai, H. K., Van Meter, T., Rucklidge, G. J., Hudson, L., Everall, L., Everall, I. P., and Pilkington, G. J. Comparative analysis of matrix metalloproteinases by immunocytochemistry, immunohistochemistry and zymography in human primary brain tumors. *Int. J. Oncol.*, *13*: 1153–1157, 1998.
- Kachra, Z., Beaulieu, E., Delbecchi, L., Mousseau, N., Berthelet, F., Mouldjian, R., Del Maestro, R., and Beliveau, R. Expression of matrix metalloproteinases and their inhibitors in human brain tumors. *Clin. Exp. Metastasis*, *17*: 555–566, 1999.
- Forsyth, P. A., Wong, H., Laing, T. D., Rewcastle, N. B., Morris, D. G., Muzik, H., Leco, K. J., Johnston, R. N., Brasher, P. M., Sutherland, G., and Edwards, D. R. Gelatinase-A (MMP-2), gelatinase-B (MMP-9) and membrane type matrix metalloproteinase-1 (MT1-MMP) are involved in different aspects of the pathophysiology of malignant gliomas. *Br. J. Cancer*, *79*: 1828–1835, 1999.
- Raithatha, S. A., Muzik, H., Muzik, H., Rewcastle, N. B., Johnston, R. N., Edwards, D. R., and Forsyth, P. A. Localization of gelatinase-A and gelatinase-B mRNA and protein in human gliomas. *Neuro-Oncol.*, *2*: 145–150, 2000.
- Lampert, K., Machein, U., Machein, M. R., Conca, W., Peter, H. H., and Volk, B. Expression of matrix metalloproteinases and their tissue inhibitors in human brain tumors. *Am. J. Pathol.*, *153*: 429–437, 1998.
- Yamamoto, M., Mohanam, S., Sawaya, R., Fuller, G. N., Seiki, M., Sato, H., Gokaslan, Z. L., Liotta, L. A., Nicolson, G. L., and Rao, J. S. Differential expression of membrane-type matrix metalloproteinase and its correlation with gelatinase A activation in human malignant brain tumors *in vivo* and *in vitro*. *Cancer Res.*, *56*: 384–392, 1996.
- Rao, J. S., Steck, P. A., Mohanam, S., Stetler-Stevenson, W. G., Liotta, L. A., and Sawaya, R. Elevated levels of *M*_{92,000} type IV collagenase in human brain tumors. *Cancer Res.*, *53*: 2208–2211, 1993.
- Pagenstecher, A., Wussler, E. M., Opendakker, G., Volk, B., and Campbell, I. L. Distinct expression patterns and levels of enzymatic activity of matrix metalloproteinases and their inhibitors in primary brain tumors. *J. Neuropathol. Exp. Neurol.*, *60*: 598–612, 2001.
- Kondraganti, S., Mohanam, S., Chintala, S. K., Kin, Y., Jasti, S. L., Nirmala, C., Lakka, S. S., Adachi, Y., Kyritsis, A. P., Ali-Osman, F., Sawaya, R., Fuller, G. N., and Rao, J. S. Selective suppression of matrix metalloproteinase-9 in human glioblastoma cells by antisense gene transfer impairs glioblastoma cell invasion. *Cancer Res.*, *60*: 6851–6855, 2000.
- Deryugina, E. I., Bourdon, M. A., Luo, G.-X., Reisfeld, R. A., and Strongin, A. Matrix metalloproteinase-2 activation modulates glioma cell migration. *J. Cell Sci.*, *110*: 2473–2482, 1997.
- Rooprai, H. K., Rucklidge, G. J., Panou, C., and Pilkington, G. J. The effect of exogenous growth factors on matrix metalloproteinase secretion by human brain tumour cells. *Br. J. Cancer*, *82*: 52–55, 2000.
- Sawaya, R. E., Yamamoto, M., Gokaslan, Z. L., Wang, S. W., Mohanam, S., Fuller, G. N., McCutcheon, I. E., Stetler-Stevenson, W. G., Nicolson, G. L., and Rao, J. S. Expression and localization of 72 kDa type IV collagenase (MMP-2) in human malignant gliomas *in vivo*. *Clin. Exp. Metastasis*, *14*: 35–42, 1996.
- Gokaslan, Z. L., Chintala, S. K., York, J. E., Boyapati, V., Jasti, S., Sawaya, R., Fuller, G., Wildrick, D. M., Nicolson, G. L., and Rao, J. S. Expression and role of matrix metalloproteinases MMP-2 and MMP-9 in human spinal column tumors. *Clin. Exp. Metastasis*, *16*: 721–728, 1998.
- Forsyth, P. A., Dickinson Laing, T., Gibson, A. W., Rewcastle, N. B., Brasher, P., Sutherland, G., Johnston, R. N., and Edwards, D. R. High levels of gelatinase-B and active gelatinase-A in metastatic glioblastoma. *J. Neuro-Oncol.*, *36*: 21–29, 1998.
- Kleihues, P., and Ohgaki, H. Primary and secondary glioblastomas: from concept to clinical diagnosis. *Neuro-Oncol.*, *1*: 44–51, 1999.
- Smith, J. S., Tachibana, I., Passe, S. M., Huntley, B. K., Borell, T. J., Iturria, N., O'Fallon, J. R., Schaefer, P. L., Scheithauer, B. W., James, C. D., Buckner, J. C., and Jenkins, R. B. PTEN mutation, EGFR amplification, and outcome in patients with anaplastic astrocytoma and glioblastoma multiforme. *J. Natl. Cancer Inst. (Bethesda)*, *93*: 1246–1256, 2001.

23. Nishikawa, R., Ji, X. D., Harmon, R. C., Lazar, C. S., Gill, G. N., Cavenee, W. K., and Huang, H. J. A mutant epidermal growth factor receptor common in human glioma confers enhanced tumorigenicity. *Proc. Natl. Acad. Sci. USA*, *91*: 7727–7731, 1994.
24. Frederick, L., Eley, G., Wang, X. Y., and James, C. D. Analysis of genomic rearrangements associated with EGFRvIII expression suggests involvement of Alu repeat elements. *Neuro-Oncol.*, *2*: 159–163, 2000.
25. Wikstrand, C. J., McLendon, R. E., Friedman, A. H., and Bigner, D. D. Cell surface localization and density of the tumor-associated variant of the epidermal growth factor receptor, EGFRvIII. *Cancer Res.*, *57*: 4130–4140, 1997.
26. Nagane, M., Lin, H., Cavenee, W. K., and Huang, H. J. Aberrant receptor signaling in human malignant gliomas: mechanisms and therapeutic implications. *Cancer Lett.*, *162* (Suppl.): S17–S21, 2001.
27. Fujisawa, H., Reis, R. M., Nakamura, M., Colella, S., Yonekawa, Y., Kleihues, P., and Ohgaki, H. Loss of heterozygosity on chromosome 10 is more extensive in primary (*de novo*) than in secondary glioblastomas. *Lab. Investig.*, *80*: 65–72, 2000.
28. Watanabe, K., Tachibana, O., Sata, K., Yonekawa, Y., Kleihues, P., and Ohgaki, H. Overexpression of the EGF receptor and p53 mutations are mutually exclusive in the evolution of primary and secondary glioblastomas. *Brain Pathol.*, *6*: 217–223, 1996.
29. Alper, O., Bergmann-Leitner, E. S., Bennett, T. A., Hacker, N. F., Stromberg, K., and Stetler-Stevenson, W. G. Epidermal growth factor receptor signaling and the invasive phenotype of ovarian carcinoma cells. *J. Natl. Cancer Inst. (Bethesda)*, *93*: 1375–1384, 2001.
30. Cox, G., Jones, J. L., and O'Byrne, K. J. Matrix metalloproteinase 9 and the epidermal growth factor signal pathway in operable non-small cell lung cancer. *Clin. Cancer Res.*, *6*: 2349–2355, 2000.
31. O-Charoenrat, P., Rhys-Evans, P., Court, W. J., Box, G. M., and Eccles, S. A. Differential modulation of proliferation, matrix metalloproteinase expression and invasion of human head and neck squamous carcinoma cells by c-erbB ligands. *Clin. Exp. Metastasis*, *17*: 631–639, 1999.
32. O-Charoenrat, P., Rhys-Evans, P., Modjtahedi, H., Court, W., Box, G., and Eccles, S. Overexpression of epidermal growth factor receptor in human head and neck squamous carcinoma cell lines correlates with matrix metalloproteinase-9 expression and *in vitro* invasion. *Int. J. Cancer*, *86*: 307–317, 2000.
33. O-Charoenrat, P., Modjtahedi, H., Rhys-Evans, P., Court, W. J., Box, G. M., and Eccles, S. A. Epidermal growth factor-like ligands differentially up-regulate matrix metalloproteinase-9 in head and neck squamous carcinoma cells. *Cancer Res.*, *60*: 1121–1128, 2000.
34. Ellerbroek, S. M., Halbleib, J. M., Benavidez, M., Warmka, J. K., Wattenberg, E. V., Stack, M. S., and Hudson, L. G. Phosphatidylinositol 3-kinase activity in epidermal growth factor-stimulated matrix metalloproteinase-9 production and cell surface association. *Cancer Res.*, *61*: 1855–1861, 2001.
35. Simmons, M. L., Lamborn, K. R., Takahashi, M., Chen, P., Israel, M. A., Berger, M. S., Godfrey, T., Nigro, J., Prados, M., Chang, S., Barker, F. G., II, and Aldape, K. Analysis of complex relationships between age, p53, epidermal growth factor receptor, and survival in glioblastoma patients. *Cancer Res.*, *61*: 1122–1128, 2001.
36. Geisler, H. E., Geisler, J. P., Miller, G. A., Geisler, M. J., Wiemann, M. C., Zhou, Z., and Crabtree, W. p21 and p53 in ovarian carcinoma: their combined staining is more valuable than either alone. *Cancer (Phila.)*, *92*: 781–786, 2001.
37. Lorimer, L. A., and Lavictoire, S. J. Activation of extracellular-regulated kinases by normal and mutant EGF receptors. *Biochim. Biophys. Acta*, *1538*: 1–9, 2001.
38. Preston-Martin, S. Epidemiology. In: M. S. Berger and C. B. Wilson (eds.), *The Gliomas*, pp. 2–11. Philadelphia: W. B. Saunders Co., 1999.
39. Wild-Bode, C., Weller, M., and Wick, W. Molecular determinants of glioma cell migration and invasion. *J. Neurosurg.*, *94*: 978–984, 2001.
40. Lakka, S. S., Jasti, S. L., Kyritsis, A. P., Yung, W. K., Ali-Osman, F., Nicolson, G. L., and Rao, J. S. Regulation of MMP-9 (type IV collagenase) production and invasiveness in gliomas by the extracellular signal-regulated kinase and jun amino-terminal kinase signaling cascades. *Clin. Exp. Metastasis*, *18*: 245–252, 2000.
41. Sawaya, R. G., Kyritsis, A. P., Uhm, J., Venkaiah, B., Mohanam, S., Gokaslan, Z. L., and Rao, J. S. Elevated levels of M_r 92,000 type IV collagenase during tumor growth *in vivo*. *Biochem. Biophys. Res. Commun.*, *251*: 632–636, 1998.
42. Tonn, J. C., Kerkau, S., Hanke, A., Bouterfa, H., Mueller, J. G., Wagner, S., Vince, G. H., and Roosen, K. Effect of synthetic matrix-metalloproteinase inhibitors on invasive capacity and proliferation of human malignant gliomas *in vitro*. *Int. J. Cancer*, *80*: 764–772, 1999.
43. Uhm, J. H., Dooley, N. P., Villemure, J. G., and Yong, V. W. Glioma invasion *in vitro*: regulation by matrix metalloproteinase-2 and protein kinase C. *Clin. Exp. Metastasis*, *14*: 421–433, 1996.
44. Deryugina, E. I., Bourdon, M. A., Reisfeld, R. A., and Strongin, A. Remodeling of collagen matrix by human tumor cells requires activation and cell surface association of matrix metalloproteinase-2. *Cancer Res.*, *58*: 3743–3750, 1998.
45. Chu, C. T., Everiss, K. D., Wikstrand, C. J., Batra, S. K., Kung, H. J., and Bigner, D. D. Receptor dimerization is not a factor in the signalling activity of a transforming variant epidermal growth factor receptor (EGFRvIII). *Biochem. J.*, *324*: 855–861, 1997.
46. McCawley, L. J., Li, S., Wattenberg, E. V., and Hudson, L. G. Sustained activation of the mitogen-activated protein kinase pathway. A mechanism underlying receptor tyrosine kinase specificity for matrix metalloproteinase-9 induction and cell migration. *J. Biol. Chem.*, *274*: 4347–4353, 1999.
47. Simon, C., Goepfert, H., and Boyd, D. Inhibition of the p38 mitogen-activated protein kinase by SB 203580 blocks PMA-induced M_r 92,000 type IV collagenase secretion and *in vitro* invasion. *Cancer Res.*, *58*: 1135–1139, 1998.
48. Ramos-DeSimone, N., Hahn-Dantona, E., Siple, J., Nagase, H., French, D. L., and Quigley, J. P. Activation of matrix metalloproteinase-9 (MMP-9) via a converging plasmin/stromelysin-1 cascade enhances tumor cell invasion. *J. Biol. Chem.*, *274*: 13066–13076, 1999.
49. Rodriguez-Manzanique, J. C., Lane, T. F., Ortega, M. A., Hynes, R. O., Lawler, J., and Iruela-Arispe, M. L. Thrombospondin-1 suppresses spontaneous tumor growth and inhibits activation of matrix metalloproteinase-9 and mobilization of vascular endothelial growth factor. *Proc. Natl. Acad. Sci. USA*, *98*: 12485–12490, 2001.