

Spontaneous Coronary Artery Dissection: A Rare Threat to Young Women

Linda Griego Martinez, RN, MSN, ACNS-BC, CMC

Spontaneous coronary artery dissection not associated with underlying coronary artery disease is rare. When the dissection does occur, it most often is manifested as an acute ST-elevation myocardial infarction in young women. Although the condition can occur in men, most often it involves women who are in their third trimester of pregnancy or the early postpartum period or are engaging in vigorous exercise. Because little is known about spontaneous coronary artery dissection in this population of women, recommendations for treatment are the same as for treatment of acute myocardial infarction associated with atherosclerotic coronary disease. (*Critical Care Nurse*. 2012;32[4]:e19-e26)

Case Study 1

For MB, the day started out as usual with a vigorous workout. This 41-year-old, physically fit, young woman considered herself to be in the best of health. While doing push-ups, part of her usual workout at a local gym, MB began to have severe, crushing pain across the anterior chest wall. She also experienced a cold sweat. She called someone to help her, and the local emergency medical service was activated. She was still experiencing pain when the emergency team arrived.

Initial assessment revealed the following: blood pressure 124/64 mm Hg, heart rate 64/min, respirations 20/min, and temperature

36.8°C. A 12-lead electrocardiogram (ECG) revealed an acute injury pattern across the anterior, septal, and lateral walls of the heart (Figure 1). Because MB was still experiencing pain across the chest, she was given 3 sublingual nitroglycerin tablets, 0.4 mg each, 5 minutes apart, and 2 chewable, 81-mg aspirin by the emergency team, but her level of pain did not change. The ECG tracing was electronically conveyed to the emergency department. On the basis of evidence of ST elevation in leads I, aVL, and V₂ through V₅, an acute ST-elevation myocardial infarction (MI) was suspected. MB was taken directly to the cardiac catheterization laboratory by ambulance.

A quick assessment of cardiac risk factors was done on arrival in

the laboratory. MB had none of the usual risk factors for coronary artery disease, such as hypertension, smoking, diabetes mellitus, dyslipidemia, or premature coronary artery disease (CAD) in her immediate family. She also had no history of cocaine or methamphetamine use, drugs that have been implicated in acute MI and/or congestive heart failure.¹⁻³ MB was given 4 mg of morphine sulfate on arrival in the cardiac catheterization laboratory, and the amount of pain she was experiencing lessened.

Angiography revealed a subtotal occlusion of the mid left anterior descending (LAD) coronary artery with an extensive mid LAD dissection. The dissection extended down the artery toward the apex of the heart. The interventional cardiologist performed a percutaneous coronary intervention (PCI) that included the deployment of 2 long intracoronary stents. Thrombolysis in MI (TIMI) grade 3 flow was established. Table 1 describes the TIMI grading system of coronary blood flow.⁴ A left-sided ventriculogram showed a large, anteroapical dyskinctic area with markedly reduced left ventricular

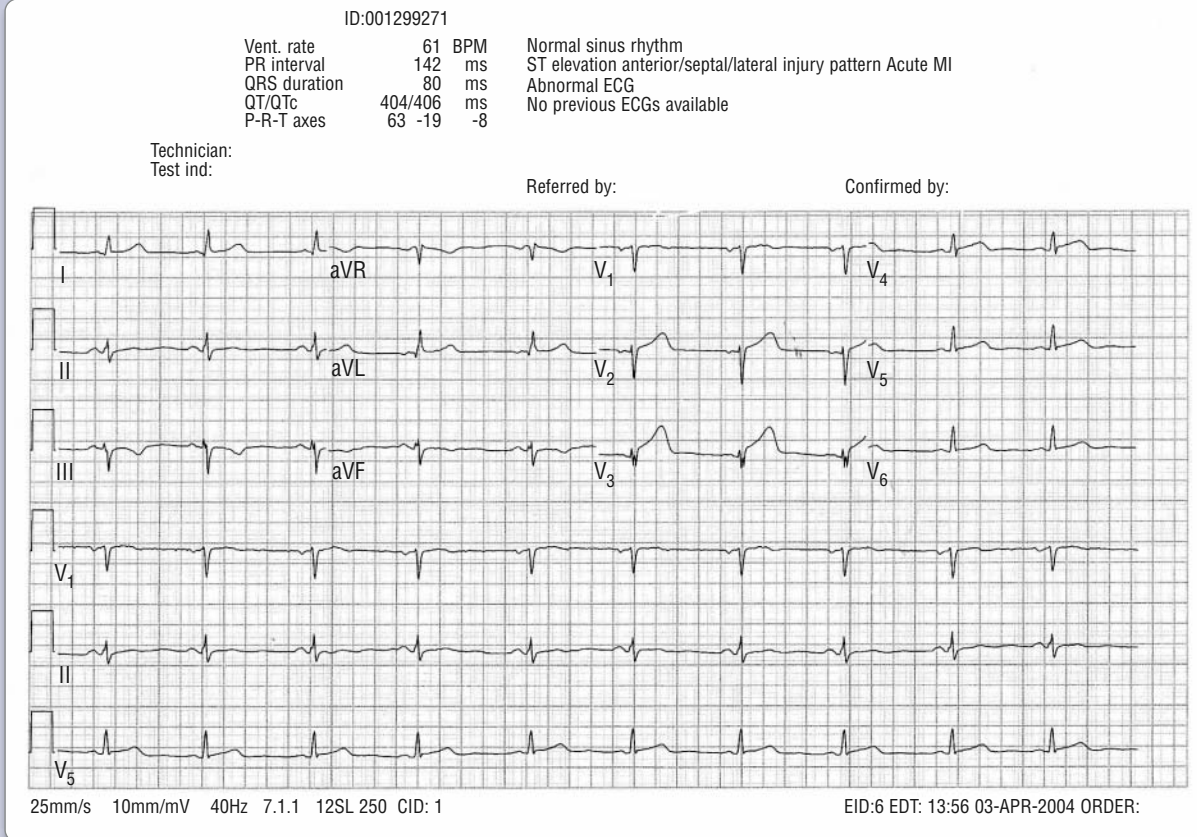


Figure 1 MB's initial electrocardiogram.

Table 1 Grade of blood flow as defined by the Thrombolysis in Myocardial Infarction study group⁴

Grade	Description
0	Absence of antegrade blood flow beyond a coronary occlusion
1	Faint blood flow beyond a coronary occlusion with incomplete distal bed filling
2	Sluggish or delayed blood flow beyond a coronary occlusion with complete distal bed filling
3	Normal blood flow beyond a coronary occlusion with complete distal bed filling

Author

Linda Griego Martinez has been an acute and critical care nurse for 35 years. She is currently employed as a clinical nurse specialist in Hospital at Home/Medical House Calls at Presbyterian Healthcare Services in Albuquerque, New Mexico.

Corresponding author: Linda Griego Martinez, RN, MSN, ACNS-BC, CMC, Presbyterian Healthcare Services, 1100 Central SE, Albuquerque, NM 87106 (e-mail: limarti@phs.org).

To purchase electronic or print reprints, contact The InnoVision Group, 101 Columbia, Aliso Viejo, CA 92656. Phone, (800) 899-1712 or (949) 362-2050 (ext 532); fax, (949) 362-2049; e-mail, reprints@aacn.org.

function. The estimated ejection fraction was 35%. An intra-aortic balloon pump was placed as prophylaxis to support left ventricular function and improve blood flow to the coronary arteries. MB became pain-free immediately after the PCI. At the end of the procedure, her blood pressure was 100/64 mm Hg, her heart rate was 84/min, and she was in normal sinus rhythm.

She was admitted to the cardiac care unit for further monitoring and care. She did not require the use of vasopressors. She received the standard therapy for acute MI with reduced ejection fraction recommended by the guidelines⁵ of the American Heart Association and the American College of Cardiology

for the care of patients with ST-elevation MI. Treatment included β -blockade with oral metoprolol tartrate 25 mg twice daily, oral lisinopril (an inhibitor of angiotensin-converting enzyme) 10 mg daily, oral aspirin 81 mg daily, and oral clopidogrel 75 mg daily. She continued to be pain-free, her hemodynamic status was stable, and she had no signs or symptoms of heart failure and no cardiac arrhythmias throughout the first day. The intra-aortic balloon pump was removed after 24 hours. MB continued to recover quickly, and by discharge on the fourth day, estimated left ventricular function was 50% to 55% (normal, 55%-70%)⁶ according to an echocardiogram. At discharge, she was taking the same medications and had appointments for follow-up care by her primary care physician within 2 weeks and her cardiologist within 4 weeks.

MB also received education on heart-healthy behaviors, such as eating a low-fat diet, a recommendation that she gradually resume exercise, and information about her medications. She was not prescribed a cholesterol-lowering agent because except for a slightly elevated level of low-density lipoprotein, her lipid profile was within the reference range (Table 2). The attending cardiologist thought that because the ST-elevation MI was not due to CAD, MB could be treated according to the guidelines for someone at low risk for CAD.

Case Study 2

AM, a 31-year-old mother of a 4-day-old infant and 4 older children, was sitting at home when she experienced a sudden onset of severe, sharp chest discomfort in the substernal

Table 2 Fasting lipid profile of case study 1 compared with normal values

Lipid	Lipid level, mg/dL ^a	
	Normal	Case 1
Total cholesterol	<200	131
Triglycerides	<150	79
High-density lipoprotein	Women: \geq 50	59
Low-density lipoprotein	<130 (if no risk factors for coronary artery disease are present)	109

^a To convert to mmol/L, multiply by 0.0259 for cholesterol and high- and low-density lipoprotein, and multiply by 0.0113 for triglycerides.

area that radiated into her back. The discomfort was associated with mild shortness of breath but no nausea or vomiting. She had never experienced this type of pain before and knew something was wrong. Her husband drove her and the infant to the emergency department. The triage nurse did a quick assessment. AM had had a normal, spontaneous vaginal delivery 4 days earlier and had never experienced any complications with her pregnancy. She had no history of high blood pressure, diabetes, family history of coronary disease, deep-vein thrombosis, or pulmonary embolism. She had never smoked or used any recreational drugs. She had never had her lipid profile determined.

Her initial vital signs were blood pressure 103/69 mm Hg, heart rate 77/min, respirations 20/min, and temperature 36.9°C. Oxygen saturation was 96% on room air. The initial ECG findings were abnormal, with 2- to 3-mm ST elevation in the inferolateral leads II, III, aVF, I, aVL, V₅, and V₆ and deep ST depressions in the precordial leads V₁ through V₄ (Figure 2). Because of the chest pain, the abnormal ECG findings, and postpartum state, the initial differential diagnosis included occult

CAD, spontaneous coronary dissection, coronary spasm, and abrupt thrombosis associated with a hypercoagulable state. The initial level of troponin I in the emergency department was 13.2 μ g/L (nor-

mal <0.046 μ g/L). This level would be consistent with myocardial muscle damage. No other laboratory results, including a complete blood cell count, complete metabolic profile, and prothrombin and partial thromboplastin times, were abnormal.

AM was taken to the cardiac catheterization laboratory. Coronary angiography showed a dissection of the left main coronary artery extending to the LAD and first diagonal arteries (Figure 3). A left-sided ventriculogram indicated mild hypokinesis with an estimated ejection fraction of 60%. Because of the extent of the dissection, the invasive cardiologist determined that the abnormality was not amenable to PCI. An intra-aortic balloon pump was inserted, and AM was taken to the operating suite for emergent coronary artery bypass grafting (CABG). She had a reverse saphenous-vein-graft bypass of both the LAD and the first diagonal arteries. Her postoperative course was uneventful, and she was discharged home 5 days later. At that time, she was taking aspirin, carvedilol 6.25 mg twice daily, and oxycodone/acetaminophen 5/325 mg every 6 hours as needed.

She was given the usual education for a patient recovering from

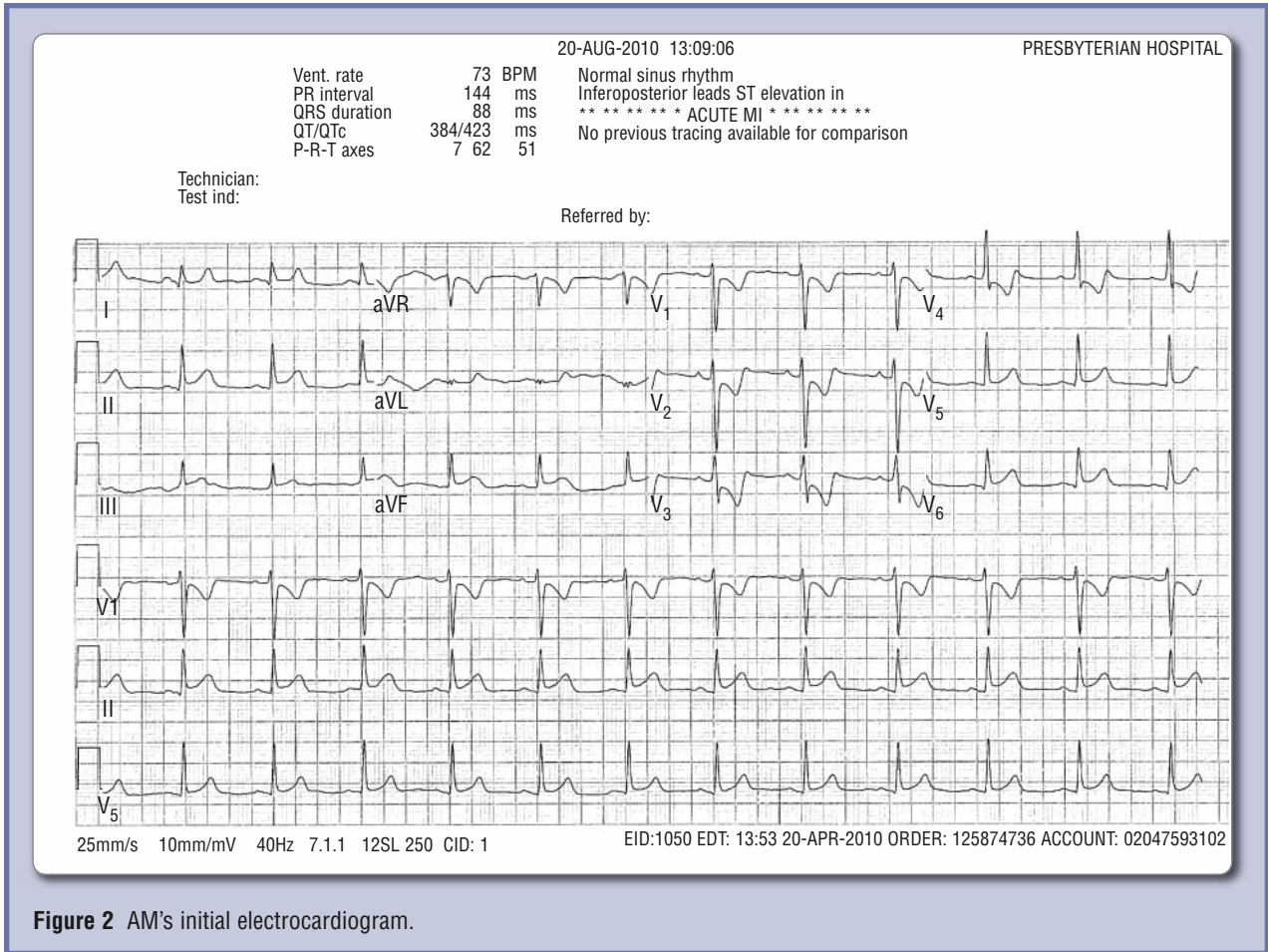


Figure 2 AM's initial electrocardiogram.

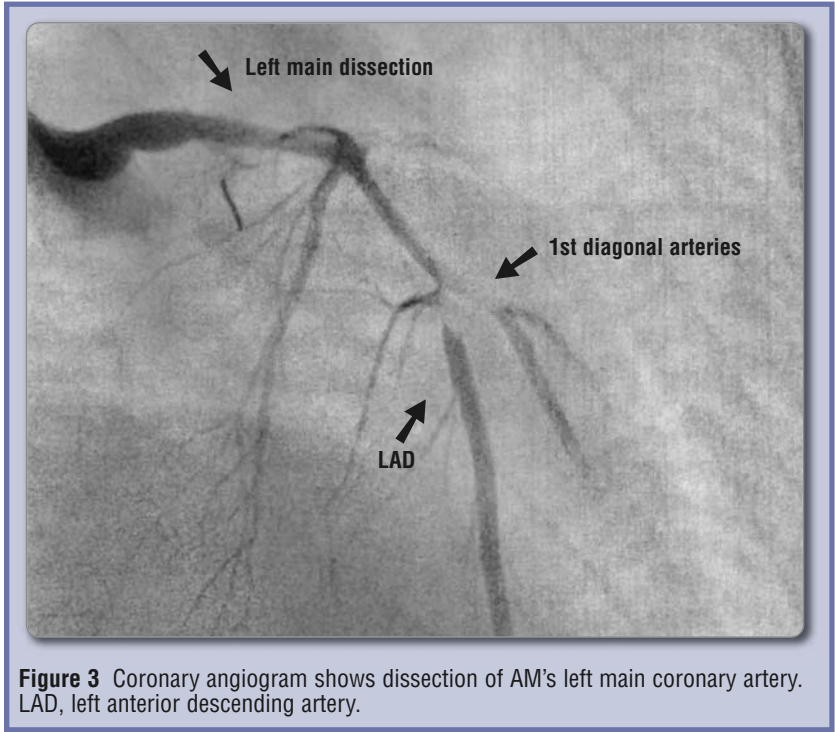


Figure 3 Coronary angiogram shows dissection of AM's left main coronary artery. LAD, left anterior descending artery.

CABG. The discharge instructions included a restriction of no lifting of anything greater than 4.5 kg (10 lb) for 6 weeks. Because her infant weighed 4.3 kg (9.5 lb) at birth, she needed people to hand the baby to her once she got home. Initially, her nursing care included pumping her breasts every 3 hours because she was breastfeeding the infant. Because the safety of breastfeeding when the mother is taking carvedilol is unknown, AM was later restricted from breastfeeding her infant. She described a strong support system including her husband and parents. She mentioned that relatives had temporarily moved in with her family to help care for the children. This available help alleviated

Downloaded from <http://aenjournal.org/online/article-pdf/32/4/e19> pdf by guest on 22 March 2023

much of her anxiety about going home to recover.

Spontaneous Coronary Artery Dissection

In the cases just described, 2 apparently healthy young women had spontaneous coronary artery dissection (SCAD) manifested as an acute coronary syndrome. SCAD is rare; the incidence is 0.28% to 1.1%.^{2,3,7,8} A total of 70% of the cases occur in women with no apparent risk factors for CAD.^{2,3,7,9} The remaining 30% involve persons with underlying CAD, persons who engage in vigorous exercise, and patients with coronary spasm or connective tissue disorders. The mean age at the time of diagnosis is 35 to 42 years.^{3,9}

In a review of 440 cases of SCAD between 1931 and 2008, Shamloo et al⁹ found that the diagnosis was made after death in 21.5% of cases and that 64% of cases were manifested as MI. The initial signs and symptoms are usually the same as those of an acute coronary syndrome or resemble those of sudden cardiac death. Of the cases reviewed by Shamloo et al, 26% were associated with pregnancy. Of the pregnancy-associated cases, 83.8% occurred in the postpartum period, usually within the first 2 weeks after delivery. Contraceptive use was also associated with 5.8% of the cases. Women who were participating in intense physical activities accounted for 3.9% of the cases. Only 30% of the cases involved men, and 15.3% of the men were participating in activities that involved heavy exertion.

Other reports^{2,3,8-13} support the findings of Shamloo et al. In peripartum women, SCAD most often occurred between a range of the

third trimester of pregnancy and 4 months postpartum.⁹ This timing suggests a possible female hormonal influence on blood vessels.^{2,3,7,9-12} In women, the LAD is affected in about 80% of cases; the right coronary artery is the affected vessel in most of the remaining 20%.^{2,3,7,9-12} In contrast, men who have SCAD more commonly have involvement of the right coronary artery (73% of cases) rather than the LAD, and they most likely are participating in vigorous exercise.^{2,3,8,13} Although the etiology of SCAD and the predisposing factors are not fully understood, some diseases and conditions have been associated with the dissection, including peripartum state, coronary atherosclerosis, hypertension, coronary spasm related to cocaine use, Prinzmetal angina, and connective tissues disorders.^{2,3}

Pathophysiology

The pathophysiology of SCAD is poorly understood, especially SCAD that is not associated with atherosclerosis. SCAD associated with atherosclerosis occurs when inflammation and rupture of atherosclerotic plaque cause disruption of the intimal-medial junction of the involved artery.^{2,3,7-10} This disruption results in a false lumen, usually between the intima and media of the arterial wall. Intramural hemorrhage and hematoma within the false lumen compress the true coronary lumen, causing obstruction or restriction of blood flow within the true lumen, leading to myocardial ischemia, MI, or sudden cardiac death.^{2,3,7-10}

The pathophysiology of SCAD during the peripartum period appears to have a different mechanism.^{2,3,7-10}

The dissections that occur in the peripartum state are primarily dissections involving the media and adventitia of the arterial wall.^{2,3,7-10} Eosinophilic infiltration of the media and adventitia of the coronary arterial wall and increased levels of collagenase have been reported in cases discovered after death that involved pregnancy and the peripartum period.^{2,3,7-9,11} During labor and the peripartum period, eosinophils infiltrate the uterus, and serum collagenase levels increase. These changes occur as a part of normal uterine involution.¹² Possibly, eosinophilic granules found in the coronary arteries in autopsy studies of SCAD indicate a systemic manifestation of this process.^{2,12} Eosinophilic granules contain numerous lytic substances, including collagenase, peroxidase, and acid phosphatase. These substances may break down the medial-adventitial layers of the arterial wall, leading to a propensity for dissection.^{2,3,9}

In addition, high estrogen and progesterone levels associated with normal pregnancy and the peripartum period may contribute to the risk for SCAD. Normally, levels of both of these hormones increase rapidly and decrease quickly after delivery. High levels of estrogen, in particular, are thought to change the normal architecture of the arterial wall, resulting in hypertrophy of the smooth muscle cells and loosening of the intercellular matrix in response to an increase in acid mucopolysaccharides and decreased collagen production in the media of the arterial wall.^{2,3,7,9} The changes occurring in the arterial wall combined with the hyperdynamic state of pregnancy, including increased

blood volume, increased cardiac output, and the extreme exertion of labor, may predispose women to coronary dissection.^{2,3,7,9}

The hypothesis of eosinophilic infiltration of the arterial wall as the primary cause of dissection was not supported in the review by Shamloo et al.⁹ They did not find a statistically significant difference in eosinophilic infiltration in pregnant vs nonpregnant women who had SCAD. Further study of the possible role of eosinophilic infiltration is needed. Also, in contrast, Skelding and Hubbard¹² think that decreased levels of estrogen, rather than elevated levels, may play a role in coronary dissection. Estrogen specifically can stimulate the release of nitric oxide from the endothelium of blood vessels, leading to vasodilatation.¹⁴ Levenson et al¹⁴ found a greater fluctuation in shear stress in blood vessel walls in women than in men, a finding attributed to estrogen. Increased vasoconstriction of coronary blood vessels associated with decreased production of nitric oxide when estrogen levels are low may lead to increased shear stress in vessel walls.¹⁴ This increased stress in turn may lead to an increased propensity for spontaneous dissection.¹² This propensity may explain cases that occur in the postpartum period but not the cases that occur during pregnancy when estrogen levels are high.

Intense physical exercise has also been described as a precipitating factor for SCAD.^{2,3,9-12} The possible explanation is that the elevated blood pressure that occurs with vigorous exercise, and perhaps coronary spasm that increases shear force on blood vessel walls, may be factors in the propensity for coronary dissection

in cases of SCAD associated with exercise.² Elevated blood pressure and coronary spasm have been implicated as the cause in the few case reports of SCAD associated with use of cocaine.² Vasculitis has been attributed as the cause in the rare cases involving patients with known autoimmune connective tissue diseases, such as Marfan syndrome and Ehlers-Danols syndrome type IV.²

Treatment

Treatment of SCAD remains unclear because of the lack of evidence-based trials. In their article on 440 cases of SCAD, Shamloo et al⁹ restricted their review of treatment to cases that occurred after the advent of PCI. Hence, they analyzed 344 cases diagnosed after 1990, when coronary intervention was widespread. Of these cases, 156 were treated with conventional medical treatment for an acute ST-elevation MI. This treatment included the use of 162 to 325 mg of aspirin to prevent further clotting of the involved artery. β -Blockade was used to block the effects of circulating catecholamines and thus reduce shear force. An angiotensin-converting enzyme inhibitor was also used in patients with reduced left ventricular dysfunction to prevent ventricular remodeling.⁹ Among patients treated initially with medical management, 21.2% required further surgical or catheter-based intervention. In contrast, the other 188 cases were initially treated with a catheter or surgical intervention, and only 2.5% of those patients required any intervention other than the initial invasive therapy. On the basis of their findings, Shamloo et al⁹ concluded that early coronary artery

intervention with CABG or catheter-based intervention is superior to conservative medical management.

This recommendation is consistent with the findings of Adlam et al¹⁰ in their review of the management of spontaneous coronary dissection. They, too, suggest that in cases that involve dissections of large-caliber or major epicardial coronary vessels (left main, LAD, right coronary, or circumflex) with changes evident on ECGs, revascularization with PCI or CABG is indicated. Adlam et al also concluded that small-caliber vessels (nondominant vessels) with TIMI grade 3 blood flow can be treated with conservative medical management rather than PCI or CABG.

Successful outcomes after revascularization with PCI with intravascular intervention and CABG have been described in individual case reports of SCAD.^{2,3,7,9-14} Sherif et al¹⁵ described a case in a 34-year-old woman who was 34 weeks' pregnant who had a successful outcome after a cesarean delivery followed by immediate CABG. Thrombolysis has also been used without complication; however, extension of the dissection due to the thrombolysis has also been reported.^{2,3,9,10}

Currently, no formal guidelines for the treatment of SCAD exist. The information in reviews of case reports^{2,3,5,9-13,15} suggests that patients who receive the standard treatment for ST elevation MI as recommended by the American Heart Association and the American College of Cardiology have beneficial outcomes. The prognosis for complete recovery is good.^{2,3,9-13} Recurrent spontaneous dissections have been reported, but these are rare.⁹⁻¹²

Table 3 Nursing care of patients after acute ST-segment elevation myocardial infarction

Potential problems	Nursing interventions
Potential for unstable hemodynamic status	Monitor for any life-threatening dysrhythmias. If present, treat per Advanced Cardiac Life Support (ACLS) guidelines. Alert physician.
Potential for fluid overload related to reduced left ventricular function	Monitor for any signs or symptoms that might indicate the development of congestive heart failure, such as tachycardia, S ₃ bilateral pulmonary rales, or edema of feet, ankles or sacral area. Alert physician immediately.
Potential for extension of infarct or abrupt closure of stent	Monitor for signs and symptoms of ongoing ischemia such as ongoing chest pain, persistent ST elevation in affected leads. Alert physician immediately.
Potential for ruptured papillary muscle or development of ventricular septal defect	Monitor for new murmur associated with rapid deterioration in hemodynamic status. Alert physician immediately.
Knowledge deficit regarding postinfarct recovery	Educate patient on the rationale of medications and potential common side effects to report to their physician. Educate on a heart-healthy diet such as low fat, low salt, and high fiber, emphasizing the consumption of fruits and vegetables. Educate and provide guidelines for activity and the resumption of activity, including resumption of sexual activity.
Grieving	Allow expression of feelings. Validate that the patient may experience anger, sadness or anxiety over change in health.

^a Based on information from Neumar et al¹⁶ and Martinez and Bucher.¹⁷

Table 4 Special considerations for patients with spontaneous coronary artery dissection peripartum

Situation	Considerations
Women who have not yet delivered	Care must be coordinated in collaboration with cardiology and obstetrics services and, often, neonatal intensive care.
Women who are in the immediate postdelivery period, <48 h	Risk of hemorrhage is high because of anticoagulants and antiplatelet agents used in conjunction with percutaneous coronary intervention. Monitor and/or massage fundus to ensure proper uterine contraction. Evaluate number of perineal pads used and observe quality of lochia.
Women who are postpartum	An assessment must be made of the patient's social support system. Questions should be asked, such as Is there someone to care for the newborn infant or other children in the home? A social worker may need to be consulted.
Mothers who are bonding with their infant	Providing an opportunity for the patient to see and be with the infant is important for the development of the infant. Encourage the patient to touch, caress, and talk to her infant. If the patient has lifting restrictions, have someone place the infant in her arms.
Mothers who are breastfeeding	Certain cardiac drugs may be contraindicated during breastfeeding. Consult a lactation specialist to help provide advice. The patient may need a breast pump. The patient may possibly continue breastfeeding at discharge, depending on the drugs prescribed.

Patients can have successive pregnancies without recurrence of SCAD.¹¹

Nursing Implications

Because most cases of SCAD are manifested as an acute coronary syndrome resulting in MI, nursing care of patients with SCAD is comparable to the care of any patient with acute MI (Table 3). Care involves

monitoring for any signs or symptoms of unstable hemodynamic status and/or complications and is summarized in the guidelines⁵ of the American Heart Association and the American College of Cardiology for the care of patients with acute ST-elevation MI.

Because SCAD often occurs in women postpartum, special consid-

erations must be addressed (Table 4). For a postpartum patient, promoting and/or maintaining the maternal-infant bond is important to the mother and to the development of the infant.¹⁵ If the mother undergoes open heart surgery, as did AM, the woman in Case 2, the lifting restriction while the sternum heals may impede the ability of the

woman to lift her own infant. Providing periods when the infant can be placed in the mother's arms or next to her are important. She should be encouraged to touch and caress her infant.¹⁸ Nurses should explore the patient's fears with her and encourage her to make a plan that provides mutual gratification for maternal and child support.

Conclusion

SCAD is a rare, potentially fatal cause of sudden cardiac death and acute coronary syndromes in young women and men. SCAD should be suspected in any young person who has signs and symptoms of an acute coronary syndrome, especially anyone without the traditional risk factors for CAD.^{2,3,7-10} The pathophysiology of SCAD is poorly understood, but following the guidelines⁵ of the American Heart Association and the American College of Cardiology for the care of patients with ST-elevation MI seems to be effective and to result in beneficial patient outcomes.⁹ With timely treatment, the prognosis is good for complete recovery.^{2,3,9-13} Nursing care of patients with SCAD is comparable to the care given to anyone who has MI. Special consideration for the needs of women in the postpartum period should include prevention of hemorrhage and promotion of the maternal-infant bond. CCH

eLetters

Now that you've read the article, create or contribute to an online discussion about this topic using eLetters. Just visit www.ccnonline.org and click "Submit a response" in either the full-text or PDF view of the article.

Financial Disclosures
None reported.

References

1. Chen JP. Methamphetamine-associated acute myocardial infarction and cardiogenic shock with normal coronary arteries: refractory global coronary microvascular spasm. *J Invasive Cardiol.* 2007;19(4):E89-E92.
2. Kamran M, Amrit G, Bogal M. Spontaneous coronary artery dissection: case series and review. *J Invasive Cardiol.* 2008; 20(10): 553-559.
3. Tanis W, Stella PR, Kirkels JH, Pijlman AH, Peters RH, de Man FH. Spontaneous coronary artery dissection: current insights and therapy. *Neth Heart J.* 2008;16(10):344-349.
4. The TIMI Study Group. The Thrombolysis in Myocardial Infarction (TIMI) trial: phase I findings. *N Engl J Med.* 1985;312(14): 932-936.
5. Antman EM, Anbe DT, Armstrong PW, et al; American College of Cardiology; American Heart Association; Canadian Cardiovascular Society. ACC/AHA guidelines for the management of patients with ST-elevation myocardial infarction—executive summary. A report of the American College of Cardiology/American Heart Association Task Force on Practice Guidelines (Writing Committee to revise the 1999 guidelines for the management of patients with acute myocardial infarction) [published correction appears in *J Am Coll Cardiol.* 2005;45(8):1376]. *J Am Coll Cardiol.* 2004;44(3):671-719.
6. American Heart Association. Ejection fraction heart failure measurement. http://www.heart.org/HEARTORG/Conditions/HeartFailure/SymptomsDiagnosisofHeartFailure/Ejection-Fraction-Heart-Failure-Measurement_UCM_306339_Article.jsp. American Heart Association Web site. Updated March 29, 2012. Accessed May 20, 2012.
7. Almafragi A, Convens C, Heuvel PV. Spontaneous healing of spontaneous coronary artery dissection. *Cardiol J.* 2010;17(1):92-95.
8. Kansara P, Graham S. Spontaneous coronary artery dissection: case series with extended follow up. *J Invasive Cardiol.* 2011; 23(2):76-80.
9. Shamloo BK, Chintala RS, Nasur A, et al. Spontaneous coronary artery dissection: aggressive vs conservative therapy. *J Invasive Cardiol.* 2010;22(5):222-228.
10. Adlam D, Cuculi F, Lim C, Banning A. Management of spontaneous coronary artery dissection in the primary percutaneous coronary intervention era. *J Invasive Cardiol.* 2010;22(11):549-553.
11. Goland S, Schwarz ER, Siegel RJ, Czer SC. Pregnancy-associated spontaneous coronary artery dissection. *Am J Obstet Gynecol.* 2007;197(6):e11-e13.
12. Skelding KA, Hubbard CR. Spontaneous coronary dissection related to menstruation. *J Invasive Cardiol.* 2007;19(16):E174-E177.
13. Ferrai E, Tozz P, von Segessor K. Spontaneous coronary artery dissection in a young woman: from emergency coronary bypass grafting to heart transplantation. *Eur J Cardiothorac Surg.* 2008;28:349-351.
14. Levenson J, Pessana F, Gariepy J, Armentano R, Simon A. Gender differences in wall shear-mediated brachial artery vasoconstriction and vasodilatation. *J Am Coll Cardiol.* 2001;38(6):1668-1674.
15. Sherif HMF, Nguyen HC, Sarter BH, et al. Spontaneous coronary dissection in late pregnancy: a multidisciplinary approach to management. *J Thorac Surg.* 2008;85(5): 1793-1794.
16. Neumar KW, Otto CW, Link MS, et al. Part 8: adult advanced cardiovascular life support: 2010 American Heart Association Guidelines for Cardiopulmonary Resuscitation and Emergency Cardiovascular Care [published correction appears in *Circulation.* 2011;123(6):e236]. *Circulation.* 2010; 122(18 suppl 3):S729-S767.
17. Martinez LG, Bucher L. Nursing management: coronary artery disease and acute coronary syndrome. In: Lewis S, Heitkemper M, Dirksen S, O'Brien PG, Bucher L, eds. *Medical-Surgical Nursing: Assessment and Management of Clinical Problems.* 7th ed. St Louis, MO: Mosby/Elsevier; 2007:784-820.
18. Duhn L. The importance of touch in the development of attachment. *Adv Neonatal Care.* 2010;10(6):294-300.