



Optimal disease management and health monitoring in adults with sickle cell disease

Jo Howard¹ and Swee Lay Thein²

¹Department of Haematology, Guy's and St Thomas' Hospitals NHS Foundation Trust, London, United Kingdom; and ²Sickle Cell Branch, National Heart, Lung, and Blood Institute/National Institutes of Health, Bethesda, MD

In countries with access to organized health care, survival of children with sickle cell disease (SCD) has greatly improved, resulting in a growing population of adults with SCD. Transition from pediatric to adult care presents many challenges for the patient, who now faces the reality of emerging complications in many organs that are cumulative, adding to other age-related nonsickle conditions that interact and add to the disease morbidity. We recommend regular comprehensive annual assessments, monitoring for early signs of organ damage and joint clinics with relevant specialists, if applicable. While maintaining a low threshold for intervention with disease-modifying therapies, we should always keep in mind that there is no single complication that is pathognomonic of SCD, and nonsickle comorbidities should always be excluded and treated if present. We need to reevaluate our approach to managing adults with SCD by putting a greater emphasis on multidisciplinary care while proactively considering curative options (hematopoietic stem cell transplant and gene therapy) and experimental pharmacological agents for adults with SCD of all ages before complications render the patients ineligible for these treatments.

Learning Objectives

- Highlight the importance of regular comprehensive reviews and monitoring for early signs of organ damage in adults with sickle cell disease
- Recognize the contributions of age-related nonsickle conditions that interact and add to the burden of sickle cell disease
- Become more patient-centric in managing the older adult with sickle cell disease

Introduction

With improvements in health care over the past 3 decades, the majority of children with sickle cell disease (SCD) now survive to adulthood, but significant early mortality remains; the mean life expectancy is still around the fourth to fifth decade. As a result, SCD has evolved into a chronic and debilitating disorder with an accumulation of end-organ dysfunction as patients age. Here, we consider management of the adult patient from the point of transition from pediatric care, with focus on the care of older adults in whom the results of a lifetime of SCD on chronic organ dysfunction interact with the comorbidities of normal physiological aging, leading to complex clinical situations. In some ways, SCD can be considered an accelerated aging process with outcomes of end organ damage (eg, end-stage renal failure [ESRF], neurological impairment, chronic cardiorespiratory disease) that are manifested a decade or so earlier relative to people without SCD. There has been little study of the outcomes of older adults with SCD and, of course, these outcomes may change (and improve) over time as the effects of early treatment

(eg, hydroxyurea [HU]) and improved comprehensive care become apparent.

Clinical case (first visit)

Patient A is a 22-year-old woman with HbSS recently transitioned from pediatric care where she has received comprehensive care since birth. At her first visit in the adult clinic, it was noted that she was started on HU at the age of 6 years and since then has experienced pain crises needing hospital admission about once a year; a silent infarct was detected on a routine magnetic resonance imaging (MRI) brain scan at the age of 7 years; and she has a history of mild asthma, controlled on inhaler therapy, and microalbuminuria. Following this initial review, she was offered regular outpatient follow-ups, including blood monitoring for HU therapy and comprehensive annual reviews. She is worried that she is likely to die early because she has family members with SCD who died in their 40s. She wants to know how to keep well and what treatments are available.

First consultation with the adult provider and annual reviews

At the first consultation, the patient should be introduced to the adult multidisciplinary team, and the provision of emergency and outpatient care should be discussed. Important issues of management include the development of an acute pain plan (ie, a management plan with the types and dosages of analgesic agents and appropriate adjuvants). The patient carries this plan in paper or electronic form, and it can be shared with the emergency care provider, if needed. Indications for attendance at the Emergency Room (ER) or local Infusion Center (if available) should be discussed; “red-flag”

Conflict-of-interest disclosure: J.H. and S.L.T. declare no competing financial interests.

Off-label drug use: None disclosed.

symptoms include severe uncontrolled pain, temperature > 38°C, chest pain, or neurological symptoms. The patient should be given the contact details for the sickle cell specialist team for clinical queries.

The importance of long-term comprehensive care and the role of the outpatient follow-up should be discussed in the context of the multiorgan complications associated with SCD and the screening that will be offered. This first consultation also offers an opportunity to discuss work and education, psychological and welfare support, reproductive issues, and therapeutic options. These discussions can be repeated at subsequent annual visits. It is often helpful to have a clinical pro forma, either paper-based or electronic, to ensure that all elements of the comprehensive review are captured and to guide junior and nonmedical staff in completing the review (Table 1).

Clinical case (10 years later)

Patient A attends intermittently over the next 10 years; she is working full-time as an administrator. She reattends clinic because she has not been feeling so well over the last 12 months, having had 4 hospital admissions with pain crisis. For the past 18 months, she has been having chronic pain in her right hip and worsening shortness of breath on exertion. Further investigations reveal proteinuria of 100 mg/mmol. Radiograph of the hip is normal, but hip MRI reveals avascular necrosis. Oxygen saturations on air are 91%, and she is referred for further investigation.

Complications and specific morbidities of SCD

However mild their symptoms appear to be, all patients with SCD are continuously undergoing some degree of end-organ deterioration. The rate of the development of chronic disease complications is modulated by the SCD genotype (patients with HbSC and HbS/mild β thalassemia exhibit less deterioration than do those with HbSS and HbS/severe β thalassemia), genetic background, lifestyle, including compliance with medication, health care access, and environment.

Pain

Pain is the most common symptom for which patients seek medical attention. There are considerable differences in the frequency and intensity of acute sickle pain between adults and children; in children, acute pain is episodic with shorter hospital stays,¹ whereas adults are likely to have more frequent acute pain, and return to the pain-free state takes longer.² With age, pain becomes increasingly chronic. A daily diary study in adults (16 years and older) showed that 55% reported pain on >50% of the days,³ whereas a similar study in children showed that the patients reported pain on only 8.4% of diary days.⁴ Initially, patients usually try to manage their acute pain at home; however, if pain escalates, attendance at infusion clinics instead of the ER is often preferred because pain relief is provided by specialist providers in a timely fashion, and this can prevent hospital admissions or reduce the length of a hospital stay.⁵ In older adults, differentiating acute pain from chronic pain can be very challenging, and overlap is often seen. The complexity of chronic pain in adults is further illustrated by the persistence of pain, despite successful reversal of sickle hematology after hematopoietic stem cell transplant (HSCT) in a subgroup that had chronic pain pretransplant.⁶ Chronic pain is debilitating, and its management is often frustrating for provider and patient alike; in some cases, opioid-induced hyperalgesia may contribute to the chronic pain.⁷ It is very important that the adult with SCD is educated that chronic pain may become a part of their daily life and that they should work with a multidisciplinary team that includes a pain-management specialist,

Table 1. Comprehensive review and screening for complications in adults with SCD

- I. Identify a primary care physician to coordinate total patient care
- II. Comprehensive multisystem review to evaluate complications
 - Pain: days off work because of pain
 - i. Acute pain: frequency of hospital admissions or ER or Infusion Center visits, frequency of pain at home
 - ii. Chronic pain: including use of opiate analgesia
 - iii. Individualized pain plan for acute and chronic pain
 - Medical history/details of comorbidities
 - i. Sickle related:
 1. Renal dysfunction (proteinuria, hematuria)
 2. Cardiorespiratory symptoms
 3. Neurological: any memory concerns
 4. Leg ulcers
 5. Visual: ophthalmologic symptoms and previous review
 6. Priapism
 7. History of thrombosis and anticoagulant therapy
 - ii. Nonsickle related: diabetes, hypertension, gout
 - Medication: consider HU if applicable, vaccinations
 - Transfusion history (to include frequency, transfusion reaction)
 - Vital signs (blood pressure, pulse oximetry, weight)
 - Baseline laboratory testing (complete blood count, biochemistry, hemolysis panel, liver panel, Hb electrophoresis and HbF percentage, iron studies to include ferritin and iron saturation, vitamin D, urinalysis)
 - Investigation: ECHO, pulmonary function, sleep study
- III. Evaluate for evidence of organ dysfunction*
 - Proteinuria with or without hematuria → renal consult
 - Cardiorespiratory symptoms → ECHO, TRV \geq 2.5 ms → 6MWD, and NT-proBNP → cardiopulmonary consult
 - Liver function, evidence of intrahepatic cholestasis → hepatology consult
 - Avascular necrosis → orthopedic consult
 - Headaches, cognitive decline → neurology consult/neuropsychology assessment
 - Visual symptoms → yearly ophthalmology review
 - Daytime or nocturnal hypoxia → sleep/respiratory consult
 - Stuttering priapism or acute priapic episodes → urology consult
- IV. Emotional/psychological review and whether support needed for education/work
- V. Reproductive review
- VI. Discussion of treatment options and potential new therapies
- VII. Management of other comorbidities, if applicable

ECHO, echocardiogram; Hb, hemoglobin; 6MWD, 6-minute walk distance; NT-ProBNP, N-terminal pro b-type natriuretic peptide; TRV, tricuspid regurgitant jet velocity. *If specialist review is recommended, referral should be made to a specialist with an interest/expertise in SCD or to a joint hematology/specialist clinic where these are available.

psychological support, and physiotherapy to develop adequate coping mechanisms.

Renal dysfunction

All patients with SCD suffer some degree of renal dysfunction manifesting as glomerular hyperfiltration and hyposthenuria (the inability to concentrate urine) from early childhood and progressing to microalbuminuria (albumin/creatinine ratio [ACR] persistently > 40 mg/g), which is seen in 20% of children, as well as in >60% of adults older than 46 years.⁸ Renal damage is insidious; at the minimum, renal function should be monitored annually with ACR. Once ACR is persistently >40 mg/g, this should be replaced by the protein/creatinine ratio, which is more accurate at higher levels of proteinuria. Proteinuria and the less common presentation of nephrotic syndrome (seen in ~4% of patients) are associated with poor outcome

and increased mortality.⁹ Recent cohort studies have confirmed a decline in estimated glomerular filtration rate (eGFR) over time in adults with SCD,¹⁰ and this decline is associated with markers of disease severity (eg, anemia, recurrent pain episodes). In a small number of patients (4-12%), renal function progressively declines, leading to ESRF requiring renal-replacement therapy.⁹ Almost 1 in 4 adults older than 60 years of age have chronic kidney disease (CKD) (stage III-IV), and ESRF has been identified as the cause of death in 45%.¹¹ Once patients with SCD develop ESRF and require dialysis, their long-term outcome is poor compared with non-SCD patients on dialysis.¹²

Further investigation is indicated for those patients with significant proteinuria or worsening renal function (eGFR decrease >10% per year or eGFR < 60 mL/min per 1.73 m²), and this would include immunology for lupus nephritis, virus serology, myeloma screen, and renal tract ultrasound, with subsequent referral to a specialist nephrologist. The decision for renal biopsy should be made after discussion with a renal specialist, and it should take into account the patient's wishes. Biopsy should be considered if there are any indications that this is not sickle cell nephropathy (SCN).⁸

Observational data suggest that the proteinuria in patients with sickle nephropathy responds to angiotensin-converting enzyme inhibitors (ACEis) or angiotensin receptor blockers (ARBs). ACEi may also slow loss of kidney function in SCD,¹³ although this needs confirmation in a randomized trial. Small observational trials suggest that HU may reduce albuminuria, although there is no evidence that it improves long-term outcomes.¹⁴

We consider ACEi or ARB treatment when the protein/creatinine ratio is persistently >50 mg/mmol (500 mg/g); it should be introduced cautiously because of the risk for postural hypotension and hyperkalemia, which are both more common in SCD patients. We also discuss HU alongside ACEi/ARB treatment, particularly in those patients with rapidly deteriorating renal function.⁸ Systemic hypertension and diabetes, common comorbidities that can accelerate deterioration of renal impairment, should be rigorously controlled (maintaining a blood pressure < 130/80 mmHg). Worsening anemia is often apparent in patients with CKD as a result of the declining ability of the kidney to synthesize erythropoietin; erythropoiesis-stimulating agents (ESAs) can be used in this situation in combination with HU. Hemoglobin (Hb) target should be <10 g/L to reduce the risk of vaso-occlusion, stroke, and venous thromboembolism. Once patients are approaching stage V CKD, renal-replacement therapy (hemodialysis or peritoneal dialysis) and early referral for transplantation should be discussed with them.⁸ These points are summarized in Table 2.

Avascular necrosis

Bone problems, such as osteopenia/osteoporosis, chronic arthritis, and osteonecrosis (or avascular necrosis [AVN]), are common in SCD; the frequency and severity increase with age.¹⁵ AVN is most common in the hip joints, but it can also occur in the shoulder, knees, feet, and back, can often affect multiple joints, and manifests as intermittent and progressive pain. A review of discharge databases in California found that 22% of patients had a diagnosis of AVN (based on imaging) of the femoral head that was made at a median age of 27 years.¹⁶ Imaging findings ranged from early changes of diffuse sclerosis and cysts to collapse of the femoral head and acetabular osteoarthritic changes. If the plain radiograph is normal, an MRI should be considered because it has the highest sensitivity and specificity for AVN.¹⁷ AVN of the hips is progressive, and >75% of

Table 2. Key points in management of adults with SCN

Annual ACR and protein/creatinine ratio
Patients with SCN are more likely to develop AKI during intercurrent illnesses
Avoid NSAIDs in patients with SCN
Further investigation if protein/creatinine ratio > 50 mg/mmol or eGFR < 60 mL/min
ACEi/ARB if persistent proteinuria (>50 mg/mmol)
Consider HU if proteinuria and/or CKD
Meticulous blood pressure control (<130/80 mmHg)
Consider ESAs and HU if anemia is worsening
Consider early renal transplantation in ESRF

AKI, acute kidney injury; NSAIDs, nonsteroidal anti-inflammatory agents.

hips with early disease will progress to collapse within 10 years.¹⁸ AVN in nonweight-bearing joints is thought to progress more slowly; a longitudinal study of patients with symptomatic osteonecrosis of the humeral head showed that 86% progressed to collapse, and 61% needed surgery over the 15- to 24-year follow-up.¹⁹

Management of AVN is challenging given the limited evidence for standardized guidelines in most surgical procedures in SCD. Early (noncollapsed) disease of the femoral head may respond to conservative treatment with physical therapy, pain management and injection with local anesthetic, although progression is inevitable. A randomized trial showed that core decompression was not superior over physical therapy,²⁰ but this study included a mix of patients with early and radiographic changes; there may be a role for this intervention in carefully selected younger adults with early noncollapsed disease. Once there is evidence of femoral head collapse, prognosis is poor, and the only effective management is total hip arthroplasty (THA). There have been some early studies with injection of stem cells (osteoblasts) into the avascular lesions in the femoral head, but these need further investigation.²¹

Early studies showed high rates of failure and revision surgery of THA, but modern techniques with cementless ceramic prosthetic devices and joint management by an experienced surgeon and hematologist have improved outcomes of THA in SCD, prompting earlier intervention.^{22,23} Patients should be referred for consideration of THA once they have a collapsed hip with pain impacting on their daily lives regardless of age.

Hypoxia in adults with SCD

Hypoxia and impaired exercise tolerance are common in adults with SCD and are associated with an increased risk for death; the etiology is multifactorial due to chronic damage to the respiratory and cardiovascular systems.²⁴ With aging, sickle cell patients accumulate a combination of standard categories of pulmonary disease: pulmonary arterial hypertension, chronic thrombotic pulmonary hypertension (PH), pulmonary fibrosis due to parenchymal damage from recurrent acute chest syndrome (ACS), reactive airway disease, and others. "Chronic sickle lung disease" has been used as an umbrella term for these pulmonary complications; however, because they are not unique to SCD, the use of this term should be discontinued.

Airway hyperreactivity is seen in >70% of pediatric patients and is also apparent in adults, albeit at a lower rate. Adults with SCD are more likely to show a restrictive defect on lung function testing, which was apparent in >70% in 1 study, in addition to evidence for impaired gas diffusion.²⁵ These defects worsen with age and are associated with interstitial lung disease and fibrosis or with PH and

with a history of ACS. PH (defined as mean pulmonary arterial pressure > 25 mmHg at rest by right heart catheterization), which affects 6% to 11% of adults with SCD, should certainly be considered a cause of hypoxia. Transthoracic echocardiography (ECHO) is a useful noninvasive screening test for PH; a tricuspid regurgitant jet velocity (TRV) > 2.5 ms (present in ~30% of adults with HbSS) is associated with an increased risk for death and a higher incidence of PH.²⁶ The role of regular routine screening using ECHO in adults with SCD is still not clear; the recent American Society of Hematology (ASH) guideline recommended against screening ECHOs, although clinicians should have a low threshold for ECHO in any patient with symptoms suggestive of PH (dyspnea, chest pain, or exertional hypoxia). Venous thromboembolism occurs in young and older adults with SCD; it is common during episodes of ACS and as a cause of death. Pulmonary thrombosis can cause hypoxia as a result of ventilation-perfusion mismatch and can lead to PH. A recent study found very high rates of pulmonary thrombosis in patients with SCD and PH, as well as that ventilation-perfusion scanning was more effective in identifying pulmonary thrombosis than were computed tomography (CT) pulmonary angiograms.²⁷ An increased incidence of obstructive sleep apnea (OSA) and nocturnal hypoxia as causes of sleep disordered breathing is reported in adults. Routine screening for sleep disordered breathing in the asymptomatic adult is not indicated, but any patient with daytime hypoxia, a history of ACS, priapism, or symptoms of OSA should undergo an overnight sleep study.

For our patient with low saturations and symptoms of dyspnea, investigations should include pulmonary function testing, overnight sleep study, ECHO, and chest CT (consider computer tomography pulmonary angiogram [CTPA] or ventilation-perfusion). She should be referred to a cardiologist/pulmonologist with an interest in SCD or to a joint clinic with a hematologist. A TRV > 2.9 ms on ECHO merits further examination with cardiac catheterization to delineate the cause for further specific treatment. In those with an intermediate TRV of 2.5 to 2.9 ms, the N-terminal pro b-type natriuretic peptide (NT-proBNP) and 6-minute walk distance are useful additional noninvasive tests.²⁶ Those with abnormalities on overnight sleep study should be treated accordingly (eg, continuous positive airway pressure for those with OSA and overnight oxygen therapy for those with nocturnal hypoxia). Additionally, we should consider introducing HU.

Discussion of disease-modifying treatment in adults with SCD

When should we treat adults with SCD with HU?

HU has been the only available drug treatment for the prevention of complications in SCD for >30 years. Following the outcome of the BABY-HUG study, which treated unselected asymptomatic infants with HU,²⁸ guidelines from the United States and United Kingdom recommend that young children with HbSS should be offered HU, regardless of clinical severity, to reduce sickle cell complications.^{29,30} Although there is no comparable randomized trial in asymptomatic adults, HU should be discussed with all adults with HbSS. Key considerations when discussing HU therapy with the patient are summarized in Table 3. We also note that the doses of HU tolerated by patients decrease with increasing age, with an increased risk for myelosuppression, which may develop even in patients on a stable dose of HU for many years. We recommend a starting dose of 15 mg/kg HU in adults (compared with 20 mg/kg in children) and regular monitoring of full blood count.

Table 3. Key considerations when discussing HU with an adult with SCD

- HU should be discussed with all adults with SCD.
- HU reduced acute SCD complications in a placebo-controlled randomized trial.⁵⁴ Adults with SCA with ≥ 3 severe pain crises in a year, with pain that interferes with daily activities, or with severe or recurrent ACS should be treated with HU.
- Long-term use of HU in nonrandomized studies demonstrated enhanced survival in patients with HbSS/HbS β^0 thalassemia disease.^{55,56}
- HU improves Hb and reduces the frequency of blood transfusion and should be offered to patients with symptomatic anemia.
- There is insufficient evidence about the efficacy of HU in primary or secondary stroke prevention in adults.
- HU should be offered to patients with SCN and should be given in combination with ESAs if there is renal-related anemia.
- There is a lack of evidence from randomized controlled trials about the beneficial effect of HU on progression of end organ damage in adults. The increase in Hb with an accompanying increase in HbF could only be beneficial; thus, HU can be considered in PH, priapism, and chronic hypoxia, but the benefits and risks should be discussed thoroughly with patients.
- The majority of evidence pertains to patients with HbSS/S β^0 thalassemia, so most recommendations are for these genotypes. However, adults with HbSC should be offered HU if they have frequent acute pain or ACS.
- HU may have a detrimental effect on spermatogenesis and may be teratogenic. Male patients should be considered for sperm analysis and cryopreservation prior to starting HU treatment. Male and female patients are advised to use contraception while on HU and to stop 3 months pre-conception. In women whose disease severity is alleviated by HU and are not able to receive blood transfusion, clinicians may consider ongoing HU therapy during pregnancy, with provision of appropriate counseling about fetal risks.
- HU has also recently been found to be relatively safe in settings with high infectious disease burden, increasing our confidence in broadening the clinical use of this drug.^{57,58}

Based on National Heart, Lung, and Blood Institute guidelines.²⁹

What are the indications for blood transfusion in adults with SCD?

The majority of randomized trials of long-term blood transfusion involve children rather than adults, but observational evidence for indications for blood transfusion in adults has been reviewed and is summarized in Figure 1.^{29,31,32}

When should we consider curative or experimental therapies in adults with SCD?

When standard therapy (HU, regular blood transfusion, Endari, and supportive care) has failed in limiting disease progression, other interventions, such as fully matched or haploidentical HSCT, gene therapy, or experimental drug therapy, should be considered, even in the older adult with SCD.³³ Although outcomes are poorer in those older than 16 years of age,³⁴ a reduction in the intensity of conditioning and improved peri-transplant care outcomes have expanded allogeneic HSCT as a treatment option for adults with preexisting organ damage.^{35,36} The ASH guidelines suggest that HSCT should be considered in adults with a history of stroke, silent stroke, abnormal transcranial doppler, recurrent ACS, or frequent pain if they have an HLA-matched sibling, although there is a low certainty of evidence for these recommendations. For those without a matched sibling donor, data on outcomes using haploidentical donors are more limited.³⁷ Gene addition using the antisickling β -globin vector containing the HbAT87Q mutation (bluebird bio) for SCD is still in its early stages, but preliminary

Indications for which Blood Transfusion have been used in adults with SCD

Acute/episodic	Regular long-term management
<ul style="list-style-type: none"> • Acute exacerbation of Anemia (S) <ul style="list-style-type: none"> - sequestration (splenic or hepatic) - hemolytic (eg Malaria, DHTR) - aplastic (HPV-B19) - severe VOC causing symptomatic anemia • Acute Stroke or other Neurological deficit (E) • Acute chest syndrome (S or E) • Multiple-organ failure (E) • Preoperative management (selected cases eg major surgery) (S) • Mesenteric / girdle syndrome (E) • Acute intrahepatic cholestasis (S or E) • Severe sepsis (E) 	<ul style="list-style-type: none"> • Primary and secondary stroke prevention (S or E) • Prevention of SCI, to continue in adults if started in childhood, to consider if progressive (S or E) • Recurrent acute chest syndrome not controlled by Hydroxyurea (S or E) • Progressive organ failure (cardiac, pulmonary, renal) (S or E) • Complicated pregnancy (S) • Frequent acute pain not responsive or intolerant to HU (S or E) • Recalcitrant leg ulcers if other treatment ineffective (S or E) • Recurring priapism (S or E) • Recurrent intrahepatic cholestasis (S or E) • Post-Renal transplantation (S or E)_

Figure 1. Indications for blood transfusion in adults with SCD. Blood transfusion is increasingly used as a disease-modifying therapy in a number of acute and chronic complications, the majority of which have low to moderate quality or no evidence base. The highest-quality evidence is from randomized controlled trials on primary prevention of stroke in children.^{52,53} Transfusion increases the Hb level and, therefore, the oxygen-carrying capacity, and it decreases the proportion of HbS in the circulation. Because sickled red blood cells increase viscosity, it is recommended that transfusion should not exceed a threshold of 10 g/dL.²⁹ It provides effective treatment of many of the complications of SCD. The list here is not exhaustive; a frequent use of blood transfusion is for symptomatic anemia in VOC when Hb falls below 20% of baseline, which again is not evidence based. Details of when and how to transfuse in SCD has been reviewed in ASH Education 2016.³² Transfusion can be Simple (S) or Exchange (E) blood transfusion. Note: acute splenic sequestration is common and life threatening, and it can be recurrent; if so, consideration should be given to splenectomy. In progressive organ failure (cardiac, renal, and pulmonary), chronic transfusion can be considered an alternative when there is no response to HU or when HU cannot be used. DHTR, delayed hemolytic transfusion reaction; HPV-B19, human parvovirus B19; SCI, silent cerebral infarction; VOC, vasoocclusive crisis.

reports have revealed therapeutic expression of the antisickling HbAT87Q with reduction in the frequency of acute sickle pain and an increase in Hb.³⁸

Pharmacy-grade L-glutamine (Endari) was approved by the U.S. Food and Drug Administration in July of 2017 for use in SCD patients older than 5 years of age to reduce the frequency of acute pain, and it came at a time when HU has been the sole disease-modifying agent for SCD for >30 years. Its mechanism is unclear, but it is thought to improve the NAD/NADH intracellular ratio, enhancing the redox potential within the red cells. L-Glutamine is also thought to decrease adhesion of sickled red cells to the endothelium and, thus, the likelihood of vasoocclusive crisis (VOC). In the 1 phase 3 study, which included 152 patients in the treatment group and 78 patients in the placebo group, there was a significant reduction in acute pain (25%), hospitalization (30%), and ACS (8 vs 23%) in the treatment group.³⁹ The high drop-out rate (36% L-glutamine arm, 24% placebo arm) makes it difficult to interpret the results. There are concerns about increased mortality with L-glutamine use among critically ill patients⁴⁰; therapeutic vigilance is needed if it is prescribed for SCD patients who are at risk for renal impairment, hepatic dysfunction, or multiorgan failure. Endari is supplied in 5-g packets of powder, and the treatment dose is 1 to 3 packets twice a day. Currently, it is reasonable to consider L-glutamine a second option in patients who cannot tolerate or fail to respond to HU.⁴¹ Other agents currently in phase 3 clinical trials include antiselectins, crizanlizumab,⁴² rivipansel,⁴³ and small molecule antisickling agents (eg, GBT440 [voxelotor]).⁴⁴

Management and monitoring of iron overload

Patients with SCD can become iron loaded secondary to regular transfusion therapy or with repeated intermittent transfusions. Although liver iron loading should be assessed every 1 to 2 years by liver MRI (R2, T2*, or R2*), compared with serial monitoring of ferritin levels alone in all patients on regular transfusions, the ASH

guideline recommends against adding routine screening for cardiac iron content by T2* MRI. However, cardiac MRI should be considered in the subgroup with evidence of very high liver iron (liver iron concentration > 15 mg/g dry weight), evidence of end organ damage due to transfusional iron overload, or evidence of cardiac dysfunction. Automated red cell exchange causes less iron overload than simple transfusion or manual exchange transfusion, and if the ferritin level is <1000 ng/mL, liver MRI screening is unlikely to be needed (ASH guidelines). Patients with an increased liver iron concentration should be treated with iron chelation therapy.

Clinical case (20 years later)

In view of her frequent acute pain episodes, Patient A was restarted on HU. She was started on an ACEi for treatment of her proteinuria and was referred to the orthopedic team for her AVN and consideration of hip replacement surgery. Her ECHO was normal, pulmonary function testing showed a mild restrictive defect, and chest CT showed changes consistent with parenchymal damage secondary to SCD. An overnight sleep study revealed nocturnal hypoxia, and the patient was started on overnight oxygen therapy.

Patient A remained well for the next 10 years. She was considering pregnancy with her partner and asked for advice about conception and pregnancy. At the age of 42 years, she presented acutely with a left hemiparesis and was transferred to an acute stroke unit where she was treated with thrombolytic therapy and, subsequently, an exchange blood transfusion. MRI showed an acute ischemic stroke on the background of silent infarcts and she was referred to a neurologist for discussion of ongoing care.

Pregnancy in SCD

Pregnant women with SCD are at increased risk for preeclampsia, pregnancy-induced hypertension, thromboembolism, and cesarean section and have increased rates of sickle complications (eg, acute pain crisis, acute chest crisis, infection). They experience increased

Table 4. Key messages in the management of an adult with SCD

SCD causes multiorgan damage that accumulates with increasing age. Emerging SCD-related morbidity includes PH, chronic hypoxia, ESRF, bony damage, chronic pain, and neurological impairment.

Regular outpatient comprehensive care allows early identification and treatment of these sickle-related morbidities and is likely to improve long-term outcome.

Clinicians should exclude nonsickle etiologies (eg, autoimmune hepatitis, lupus, rheumatoid arthritis) that add to disease burden and should be treated.

Regular outpatient comprehensive care also allows early detection and treatment of nonsickle aging-related comorbidities that add to the disease burden.

Current disease-modifying therapy is limited to HU, transfusion, and L-glutamine, and patients should be offered these therapies before they develop severe complications. However, the provider should also be alert to complications related to the therapy itself (eg, secondary iron overload).

Clinicians should be proactive in considering and discussing curative therapies, including HSCT, experimental drug therapy, or gene therapy, early in the disease course, prior to the development of disease complications.

Management of the adult with SCD includes holistic care with psychological and social support.

rates of miscarriage, premature labor, and restriction of fetal growth.⁴⁵ These risks can be reduced by optimization of care prior to conception and scrupulous joint care during the antenatal, perinatal, and postnatal periods. We recommend that women are seen regularly and jointly by an obstetrician and hematologist and, if admitted, should be under the joint care of a specialist obstetrician and hematologist.

Women should be advised to take folic acid prior to conception and should be offered partner screening. If the couple is at risk for having a child with SCD, genetic counseling should be offered, including options for preimplantation genetic diagnosis and invasive prenatal diagnosis. Current evidence does not allow firm recommendations on the role of prophylactic transfusion throughout pregnancy, but certainly transfusion should be offered for symptomatic anemia or acute sickle complications. In view of the increased thrombotic risk,

thromboprophylaxis should be prescribed postpartum and considered in the third trimester.⁴⁶

Neurological disease in adults

Historical data show high rates of acute ischemic stroke in adults (11% by 20 years and 24% by 45 years), but there are fewer data on the rates of new or recurrent strokes in the era of childhood stroke screening and the increasing use of HU. Unlike in the pediatric SCD population, in which strokes are almost invariably due to sickle-related vasculopathy, adults with SCD often have other comorbidities that contribute to stroke risk, including hypertension, diabetes, hyperlipidemia, and renal dysfunction; investigation for these causes is mandatory for any adult SCD patient presenting with stroke. Acute hemorrhagic stroke is also seen at increased rates in adults with SCD, in part because of the high rate of cerebral aneurysms (reported in up to 11% of adults), which can rupture.⁴⁷

The main dilemma in acute stroke management in adults with SCD is the role of exchange blood transfusion vs the need for early thrombolysis. It is important that the algorithms for managing acute stroke recognize the relevance of a diagnosis of SCD and consider the need for acute transfusion therapy. In children there is observational evidence that early treatment with exchange transfusion is associated with improved outcomes, and it is probable that these data will also apply to adults with sickle-related stroke. Equally, sickle vasculopathy may not be the cause of acute ischemic thrombotic stroke in adults, and thrombolytic therapy may be more appropriate. A recent study showed that coexistent SCD does not affect the outcome of thrombolytic therapy in adults with SCD⁴⁸ who, therefore, may benefit from both thrombolysis and exchange transfusion. Nevertheless, discussion with a stroke physician is necessary.

Children with SCD who have experienced a stroke are at a high risk for recurrent stroke, and this risk is reduced with long-term transfusion therapy. It is likely that this is also true in adults and that transfusion will be most beneficial in those with no traditional risk factors for stroke and with previous silent infarcts or evidence of sickle vasculopathy on magnetic resonance angiography (MRA). We recommend a discussion among the neurologist, the hematologist,

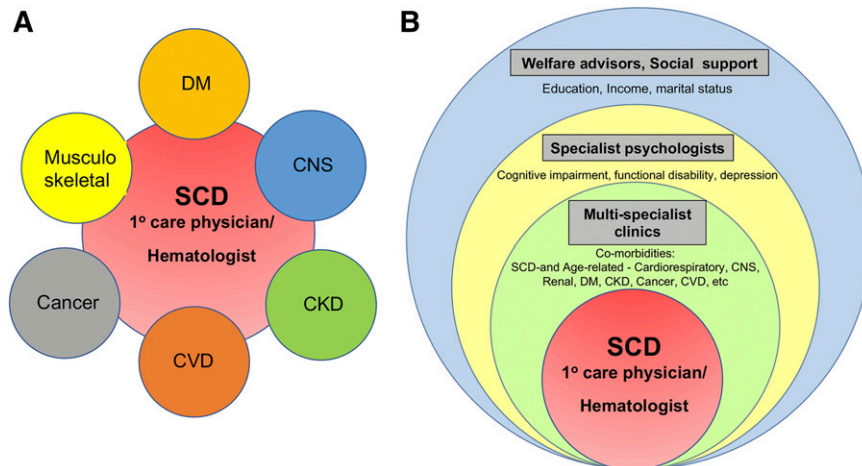


Figure 2. Proposed model for managing SCD in an adult. (A) The traditional single disease-focused framework of comorbidity in which comorbid conditions are considered disease pairs, such as SCD and diabetes mellitus, SCD and cardiovascular disease, and SCD and kidney disease. Most clinical practice guidelines are based on this framework. (B) Multimorbid conceptual framework demonstrating a more patient-centric approach to managing the adult with SCD in the context of physiological aging conditions adding to the accumulating sickle-related complications and social determinants of health. CNS, central nervous system; CVD, cardiovascular disease; DM, diabetes mellitus.

and the patient with outcomes of poststroke work-up to decide on the need for long-term transfusion.

Necessary investigations include imaging with MRI/MRA to look for evidence of sickle-related vasculopathy and previous silent infarcts, ECHO to look for patent foramen ovale (increased incidence in SCD), and traditional stroke risk factors, including lipids, diabetic screening, electrocardiogram.

Silent cerebral infarctions (SCIs) are common in SCD; they increase with increasing age and contribute to the neurocognitive decline.⁴⁹ There is evidence that intervention with regular transfusion therapy in children with SCI prevents progression of silent infarcts or the development of overt stroke,⁵⁰ but there is no evidence that such an intervention prevents progression of neurocognitive decline or overt stroke in adults with SCI. The ASH guidelines recommend that adults have a 1-time MRI screen for SCIs to identify individuals with an increased risk for cognitive impairment and to facilitate occupational therapy and resource input, although there was a low certainty of evidence for this recommendation. If SCIs are found on MRI scan, we recommend regular follow-up scanning and intervention with HU or transfusion. It is prudent to continue with ongoing transfusion therapy if started in childhood; transfusion therapy should also be considered if the SCIs are progressive, and HU cannot be used. We also recommend that adults with evidence of SCI, particularly if progressive, be referred for neuropsychological assessment and additional appropriate support. Clinicians should be asking about memory concerns as part of the comprehensive annual review and referring for MRI scanning and neuropsychological testing, if indicated.⁵¹

Clinical case (patient in her 50s)

Further investigations in patient A found no traditional risk factors for stroke; she was normotensive with normal lipid studies, had no evidence of cardiac disease, and her ECHO was normal. She was advised to continue on long-term blood transfusion therapy as secondary stroke prevention. She was monitored regularly for iron overload. Annual brain MRI/MRA was performed to ensure that there was no progression of neurological disease. Patient A remained well for the next decade, being seen regularly for automated exchange blood transfusion, until an acute admission with confusion and acute kidney injury. A provisional diagnosis of “sickle crisis” was made, but subsequent investigation revealed a blood glucose of 32 mmol/L, leading to a new diagnosis of insulin-dependent diabetes. She was treated appropriately and discharged on insulin therapy, as well as the ongoing transfusion therapy.

Conclusions

As adults with SCD grow older, they are likely to have multiple aging comorbidities, adding to the cumulative complications of a chronic disease that affects multiple organ systems. Thus, it is imperative that any coexisting cause is identified accurately and treated appropriately. Given the impairment in multiple organs, an adult with SCD also tends to have a medication regimen that increases in complexity and needs careful consideration and appropriate dosage adjustments. Cognitive dysfunction that increases with age impacts adherence to the prescribed drug regimen and management plans. Key messages in managing the adult with SCD are summarized in Table 4. As more adults with SCD live longer, it is time to shift the traditional care practice of SCD as a single disease to a more patient-centered framework in a multidisciplinary team, with a primary care physician/hematologist coordinating

care of the patient. Additionally, due diligence should be paid to routine screening tests for diabetes and cancers (Figure 2).

Acknowledgment

This work was supported by the Intramural Research Program of the National Heart, Lung, and Blood Institute, National Institutes of Health (S.L.T.).

Authorship

Contribution: S.L.T. and J.H. cowrote the article.

Correspondence

Swee Lay Thein, Sickle Cell Branch, National Heart, Lung and Blood Institute, The National Institutes of Health, Building 10-CRC, Room 6S241, 10 Center Dr, Bethesda, MD 20892; e-mail:sl.thein@nih.gov.

References

1. Panepinto JA, Brousseau DC, Hillery CA, Scott JP. Variation in hospitalizations and hospital length of stay in children with vaso-occlusive crises in sickle cell disease. *Pediatr Blood Cancer*. 2005;44(2):182-186.
2. Ballas SK, Lusardi M. Hospital readmission for adult acute sickle cell painful episodes: frequency, etiology, and prognostic significance. *Am J Hematol*. 2005;79(1):17-25.
3. Smith WR, Penberthy LT, Bovbjerg VE, et al. Daily assessment of pain in adults with sickle cell disease. *Ann Intern Med*. 2008;148(2):94-101.
4. Dampier C, Ely B, Brodecki D, O'Neal P. Characteristics of pain managed at home in children and adolescents with sickle cell disease by using diary self-reports. *J Pain*. 2002;3(6):461-470.
5. Lanzkron S, Carroll CP, Hill P, David M, Paul N, Haywood C Jr. Impact of a dedicated infusion clinic for acute management of adults with sickle cell pain crisis. *Am J Hematol*. 2015;90(5):376-380.
6. Darbari DS, Liljencrantz J, Ikechi A, et al. Pain and opioid use after reversal of sickle cell disease following HLA-matched sibling haematopoietic stem cell transplant. *Br J Haematol*. 2019;184(4):690-693.
7. Ruscheweyh R, Sandkühler J. Opioids and central sensitisation: II. Induction and reversal of hyperalgesia. *Eur J Pain*. 2005;9(2):149-152.
8. Sharpe CC, Thein SL. How I treat renal complications in sickle cell disease. *Blood*. 2014;123(24):3720-3726.
9. Drawz P, Ayyappan S, Nouraie M, et al. Kidney disease among patients with sickle cell disease, hemoglobin SS and SC. *Clin J Am Soc Nephrol*. 2016;11(2):207-215.
10. Derebail VK, Ciccone EJ, Zhou Q, Kilgore RR, Cai J, Ataga KI. Progressive decline in estimated GFR in patients with sickle cell disease: an observational cohort study. *Am J Kidney Dis*. 2019;74(1):47-55.
11. Serjeant GR, Serjeant BE, Mason KP, Hambleton IR, Fisher C, Higgs DR. The changing face of homozygous sickle cell disease: 102 patients over 60 years. *Int J Lab Hematol*. 2009;31(6):585-596.
12. Nielsen L, Canoui-Poittrine F, Jais JP, et al. Morbidity and mortality of sickle cell disease patients starting intermittent haemodialysis: a comparative cohort study with non-sickle dialysis patients. *Br J Haematol*. 2016;174(1):148-152.
13. Thrower A, Ciccone EJ, Maitra P, Derebail VK, Cai J, Ataga KI. Effect of renin-angiotensin-aldosterone system blocking agents on progression of glomerulopathy in sickle cell disease. *Br J Haematol*. 2019;184(2):246-252.
14. Bartolucci P, Habibi A, Stehlé T, et al. Six months of hydroxyurea reduces albuminuria in patients with sickle cell disease. *J Am Soc Nephrol*. 2016;27(6):1847-1853.
15. Almeida A, Roberts I. Bone involvement in sickle cell disease. *Br J Haematol*. 2005;129(4):482-490.
16. Adesina O, Brunson A, Keegan THM, Wun T. Osteonecrosis of the femoral head in sickle cell disease: prevalence, comorbidities, and surgical outcomes in California. *Blood Adv*. 2017;1(16):1287-1295.
17. Choi HR, Steinberg ME, Y Cheng E. Osteonecrosis of the femoral head: diagnosis and classification systems. *Curr Rev Musculoskelet Med*. 2015; 8(3):210-220.

18. Hernigou P, Habibi A, Bachir D, Galacteros F. The natural history of asymptomatic osteonecrosis of the femoral head in adults with sickle cell disease. *J Bone Joint Surg Am.* 2006;88(12):2565-2572.
19. Pognard A, Flouzat-Lachaniette CH, Amzallag J, Galacteros F, Hernigou P. The natural progression of symptomatic humeral head osteonecrosis in adults with sickle cell disease. *J Bone Joint Surg Am.* 2012;94(2):156-162.
20. Neumayr LD, Aguilar C, Earles AN, et al; National Osteonecrosis Trial in Sickle Cell Anemia Study Group. Physical therapy alone compared with core decompression and physical therapy for femoral head osteonecrosis in sickle cell disease. Results of a multicenter study at a mean of three years after treatment. *J Bone Joint Surg Am.* 2006;88(12):2573-2582.
21. Sadat-Ali M, Azam MQ, Elshabouri EM, Tantawy AM, Acharya S. Stem cell therapy for avascular necrosis of femoral head in sickle cell disease: report of 11 cases and review of literature. *Int J Stem Cells.* 2017;10(2):179-183.
22. Jack CM, Howard J, Aziz ES, Kesse-Adu R, Bankes MJ. Cementless total hip replacements in sickle cell disease. *Hip Int.* 2016;26(2):186-192.
23. Ilyas I, Alrumaih HA, Rabbani S. Noncemented total hip arthroplasty in sickle-cell disease: long-term results. *J Arthroplasty.* 2018;33(2):477-481.
24. Machogu EM, Machado RF. How I treat hypoxia in adults with hemoglobinopathies and hemolytic disorders. *Blood.* 2018;132(17):1770-1780.
25. Klings ES, Wyszynski DF, Nolan VG, Steinberg MH. Abnormal pulmonary function in adults with sickle cell anemia. *Am J Respir Crit Care Med.* 2006;173(11):1264-1269.
26. Gordeuk VR, Castro OL, Machado RF. Pathophysiology and treatment of pulmonary hypertension in sickle cell disease. *Blood.* 2016;127(7):820-828.
27. Mehari A, Igbineweka N, Allen D, Nichols J, Thein SL, Weir NA. Abnormal ventilation-perfusion scan is associated with pulmonary hypertension in sickle cell adults. *J Nucl Med.* 2019;60(1):86-92.
28. Wang WC, Ware RE, Miller ST, et al; BABY HUG investigators. Hydroxycarbamide in very young children with sickle-cell anaemia: a multicentre, randomised, controlled trial (BABY HUG). *Lancet.* 2011;377(9778):1663-1672.
29. Yawn BP, Buchanan GR, Afeniyi-Annan AN, et al. Management of sickle cell disease: summary of the 2014 evidence-based report by expert panel members. *JAMA.* 2014;312(10):1033-1048.
30. Qureshi A, Kaya B, Panchar S, et al; British Society for Haematology. Guidelines for the use of hydroxycarbamide in children and adults with sickle cell disease: A British Society for Haematology Guideline. *Br J Haematol.* 2018;181(4):460-475.
31. Davis BA, Allard S, Qureshi A, et al; British Society for Haematology. Guidelines on red cell transfusion in sickle cell disease. Part II: indications for transfusion. *Br J Haematol.* 2017;176(2):192-209.
32. Howard J. Sickle cell disease: when and how to transfuse. *Hematology (Am Soc Hematol Educ Program).* 2016;2016:625-631.
33. Thein SL, Tisdale J. Sickle cell disease-unanswered questions and future directions in therapy. *Semin Hematol.* 2018;55(2):51-52.
34. Gluckman E, Cappelli B, Bernaudin F, et al; Eurocord, the Pediatric Working Party of the European Society for Blood and Marrow Transplantation, and the Center for International Blood and Marrow Transplant Research. Sickle cell disease: an international survey of results of HLA-identical sibling hematopoietic stem cell transplantation. *Blood.* 2017;129(11):1548-1556.
35. Guilcher GMT, Truong TH, Saraf SL, Joseph JJ, Rondelli D, Hsieh MM. Curative therapies: allogeneic hematopoietic cell transplantation from matched related donors using myeloablative, reduced intensity, and nonmyeloablative conditioning in sickle cell disease. *Semin Hematol.* 2018;55(2):87-93.
36. Ozdogu H, Boga C, Yeral M, et al. Allogenic peripheral stem cell transplantation from HLA-matched related donors for adult sickle cell disease: remarkable outcomes from a single-center trial. *Bone Marrow Transplant.* 2018;53(7):880-890.
37. Fitzhugh CD, Walters MC. The case for HLA-identical sibling hematopoietic stem cell transplantation in children with symptomatic sickle cell anemia. *Blood Adv.* 2017;1(26):2563-2567.
38. Ribeil JA, Haccin-Bey-Abina S, Payen E, et al. Gene therapy in a patient with sickle cell disease. *N Engl J Med.* 2017;376(9):848-855.
39. Nihara Y, Miller ST, Kanter J, et al; Investigators of the Phase 3 Trial of L-Glutamine in Sickle Cell Disease. A phase 3 trial of L-glutamine in sickle cell disease. *N Engl J Med.* 2018;379(3):226-235.
40. Heyland D, Muscedere J, Wischmeyer PE, et al; Canadian Critical Care Trials Group. A randomized trial of glutamine and antioxidants in critically ill patients [published correction appears in *N Engl J Med.* 2013;368(19):1853]. *N Engl J Med.* 2013;368(16):1489-1497.
41. Quinn CT. L-Glutamine for sickle cell anemia: more questions than answers. *Blood.* 2018;132(7):689-693.
42. Ataga KI, Kutlar A, Kanter J, et al. Crizanlizumab for the prevention of pain crises in sickle cell disease. *N Engl J Med.* 2017;376(5):429-439.
43. Telen MJ, Wun T, McCavit TL, et al. Randomized phase 2 study of GMI-1070 in SCD: reduction in time to resolution of vaso-occlusive events and decreased opioid use. *Blood.* 2015;125(17):2656-2664.
44. Blyden G, Bridges KR, Bronte L. Case series of patients with severe sickle cell disease treated with voxelotor (GBT440) by compassionate access. *Am J Hematol.* 2018;93(8):E188-E190.
45. Oteng-Ntim E, Meeks D, Seed PT, et al. Adverse maternal and perinatal outcomes in pregnant women with sickle cell disease: systematic review and meta-analysis. *Blood.* 2015;125(21):3316-3325.
46. D'Alton ME, Friedman AM, Smiley RM, et al. National Partnership for Maternal Safety: consensus bundle on venous thromboembolism. *J Obstet Gynecol Neonatal Nurs.* 2016;45(5):706-717.
47. Birkeland P, Gardner K, Kesse-Adu R, et al. Intracranial aneurysms in sickle-cell disease are associated with the hemoglobin SS genotype but not with moyamoya syndrome. *Stroke.* 2016;47(7):1710-1713.
48. Adams RJ, Cox M, Ozark SD, et al. Coexistent sickle cell disease has no impact on the safety or outcome of lytic therapy in acute ischemic stroke: findings from Get With The Guidelines-Stroke. *Stroke.* 2017;48(3):686-691.
49. Mackin RS, Insel P, Truran D, et al; Neuropsychological Dysfunction and Neuroimaging Adult Sickle Cell Anemia Study Group. Neuroimaging abnormalities in adults with sickle cell anemia: associations with cognition. *Neurology.* 2014;82(10):835-841.
50. DeBaun MR, Kirkham FJ. Central nervous system complications and management in sickle cell disease. *Blood.* 2016;127(7):829-838.
51. Vichinsky E. Chronic organ failure in adult sickle cell disease. *Hematology (Am Soc Hematol Educ Program).* 2017;2017:435-439.
52. Gebreyohannis M, Adams RJ. Sickle cell disease: primary stroke prevention. *CNS Spectr.* 2004;9(6):445-449.
53. U.S. Department of Health and Human Services. Evidence-based management of sickle cell disease. https://www.nhlbi.nih.gov/sites/default/files/media/docs/sickle-cell-disease-report%20020816_0.pdf.
54. Charache S, Terrin ML, Moore RD, et al; Investigators of the Multicenter Study of Hydroxyurea in Sickle Cell Anemia. Effect of hydroxyurea on the frequency of painful crises in sickle cell anemia. *N Engl J Med.* 1995;332(20):1317-1322.
55. Steinberg MH, McCarthy WF, Castro O, et al; Investigators of the Multicenter Study of Hydroxyurea in Sickle Cell Anemia and MSH Patients' Follow-Up. The risks and benefits of long-term use of hydroxyurea in sickle cell anemia: a 17.5 year follow-up. *Am J Hematol.* 2010;85(6):403-408.
56. Voskaridou E, Christoulas D, Bilalis A, et al. The effect of prolonged administration of hydroxyurea on morbidity and mortality in adult patients with sickle cell syndromes: results of a 17-year, single-center trial (LaSHS). *Blood.* 2010;115(12):2354-2363.
57. Opoka RO, Ndugwa CM, Latham TS, et al. Novel use of hydroxyurea in an African region with malaria (NOHARM): a trial for children with sickle cell anemia. *Blood.* 2017;130(24):2585-2593.
58. Tshilolo L, Tomlinson G, Williams TN, et al; REACH Investigators. Hydroxyurea for children with sickle cell anemia in sub-Saharan Africa. *N Engl J Med.* 2019;380(2):121-131.