

## The Class II Carriere Motion appliance: A 3D CBCT evaluation of the effects on the dentition

Daniel Areepong<sup>a</sup>; Ki Beom Kim<sup>b</sup>; Donald R. Oliver<sup>c</sup>; Hiroshi Ueno<sup>d</sup>

### ABSTRACT

**Objectives:** To determine three-dimensional treatment changes produced by the Class II Carriere Motion appliance (CMA) in Class II adolescent patients with Class I and Class II skeletal relationships.

**Materials and Methods:** The sample included 59 adolescents (16 boys and 43 girls) with unilateral or bilateral Class II molar and bilateral Class II canine relationship. They were divided into group 1 with skeletal Class I (N = 27; ANB 2.90° ± 1.40°; 13.30 ± 1.53 years) and group 2 with skeletal Class II (N = 32; ANB 6.06° ± 1.64°; 13.26 ± 1.76 years). Cone beam computed tomography images were traced with Invivo software pretreatment (T1) and post-CMA usage (T2). The treatment changes in 36 measurements were calculated in each group, and the changes in 16 measurements were compared between them.

**Results:** In group 1 and 2, maxillary first molars underwent significant distal movement (1.92 mm ± 0.80 mm and 1.67 mm ± 1.56 mm, respectively) with distal tipping and rotation, maxillary canines underwent significant distal movement (2.34 mm ± 1.07 mm and 2.24 mm ± 1.91 mm, respectively) with distal tipping and rotation, and mandibular molars underwent significant mesial movement (−1.37 mm ± 1.23 mm and −2.51 mm ± 1.51 mm, respectively) with mesial tipping. Between the groups, there were significant differences in mandibular molar mesial movement and the U1-SN changes ( $P < .05$ ).

**Conclusions:** The CMA corrected Class II malocclusion through distal tipping and rotational movement of maxillary canines and molars and corrected mesial tipping of mandibular molars. Significantly more mandibular molar mesial movement and maxillary incisor flaring were observed in patients with skeletal Class II. (*Angle Orthod.* 2020;90:491–499.)

**KEY WORDS:** Class II malocclusion; Class II; Carriere Motion appliance; Carriere distalizer, CBCT evaluation; 3D evaluation

### INTRODUCTION

Class II correction appliances have received careful review in the orthodontic literature. Among them,

Class II elastics were shown to be effective in correcting Class II malocclusion.<sup>1,2</sup> Other frequently used Class II appliances include, but are not limited to, extraoral appliances such as headgear,<sup>3–5</sup> intra-maxillary appliances,<sup>6–8</sup> and intermaxillary appliances.<sup>2,9–13</sup> However, most of these methods procline mandibular incisors.<sup>6,8–11,13,14</sup>

The introduction of the Class II Carriere Motion appliance (CMA) has raised many questions from the orthodontic community about its treatment effects. The appliance was designed to be an intermaxillary, nonextraction, Class II corrector.<sup>15</sup> It consists of mold-injected, nickel-free stainless steel that runs from the maxillary canine to the first molar. It has a ball-and-socket design on the molar pad to allow tipping and rotation of the molar and a hook on the canine pad for elastic wear to the mandibular first molar, where anchorage is required.<sup>15</sup> A “shorty” model is also

<sup>a</sup> Private practice, Walnut, Calif, USA.

<sup>b</sup> Associate Professor, Department of Orthodontics, Saint Louis University, Saint Louis, Mo, USA.

<sup>c</sup> Clinical Professor, Department of Orthodontics, Saint Louis University, Saint Louis, Mo, USA.

<sup>d</sup> Assistant Professor, Department of Orthodontics, Saint Louis University, Saint Louis, Mo, USA.

Corresponding author: Dr Hiroshi Ueno, Department of Orthodontics, Center for Advanced Dental Education, Saint Louis University, 3320 Rutger Street, Dreiling Marshall Hall, St Louis, MO 63104  
(e-mail: hueno.thk@gmail.com)

Accepted: December 2019. Submitted: August 2019.

Published Online: March 5, 2020

© 2020 by The EH Angle Education and Research Foundation, Inc.

**Table 1.** Demographics and Molar Relationships in Group 1 and Group 2

			Group 1 (N = 27)	Group 2 (N = 32)
Age			13.30 ± 1.53	13.26 ± 1.76
Boys:girls			20:7	23:9
ANB			2.90° ± 1.40°	6.06° ± 1.64°
Class II molar relationship	Bilateral	Total	16	26
		Full-step	3	4
		Full-step and End-on	3	10
	Unilateral	End-on	10	12
		Total	11	6
		Full-step	4	1
		End-on	7	5

available, which runs from the maxillary first premolar instead of the maxillary canine.<sup>15</sup>

Carriere claimed that the appliance produced “distal rotational movement of the maxillary first molars around their palatal roots.”<sup>15</sup> Distal movement was demonstrated through photos displayed in case reports.<sup>16,17</sup> Rodriguez<sup>17</sup> demonstrated unilateral usage of a shorty model of the CMA, which showed distal movement of the entire maxillary posterior segment. However, without any measurements, there can only be speculation as to the effects of the appliance.

No study has specifically examined whether distal molar rotations were the reason behind the distal movements previously observed. Thus, this study aimed to determine the three-dimensional (3D) treatment changes of the CMA, including distal rotation of maxillary molars, in Class II adolescent patients.

## MATERIALS AND METHODS

### Subjects

The study protocol was approved by the Saint Louis University Institutional Review Board. The sample comprised 59 adolescents (16 boys and 43 girls) who were treated at three private orthodontic offices. Records were collected retrospectively based on the following inclusion criteria: adolescent patients age 10–17 years, unilateral or bilateral Class II molar relationship, bilateral Class II canine relationship, bilateral use of the CMA for Class II correction, availability of pretreatment (T1) and post-CMA use (T2) cone beam computed tomography (CBCT) measurements, non-extraction treatment, Essix retainer in the mandibular arch for anchorage, and permanent or late mixed dentition. The sample excluded those with the following: posterior crossbite and syndromes or skeletal deformities.

Based on skeletal classification, two groups were formed, group 1 with skeletal Class I (N = 27; ANB 2.90° ± 1.40°; 13.30 ± 1.53 years) and group 2 with skeletal Class II (N = 32; ANB 6.06° ± 1.64°; 13.26 ±

1.76 years), to examine whether skeletal Class II patients (ANB >4°) had different treatment changes compared to skeletal Class I patients (ANB 0°–4°). The demographic characteristics and molar relationships in each group are described in Table 1.

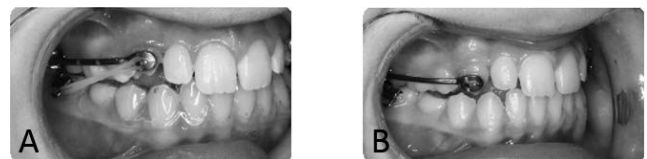### Treatment Protocol

Treatment protocol with the CMA was the same at all three offices. A CBCT was taken within 1–3 months before treatment (T1). Then, the CMA was placed (regular or shorty model) bilaterally along with a hook or molar bracket on the mandibular first molar (Figure 1A). An Essix retainer was used as anchorage on the mandibular dentition (Figure 1A). In addition, 1/4” 6 oz elastics were used for the first month followed by 3/16” 8 oz elastics after the first month until both Class I molar and canine relationships were achieved bilaterally (Figure 1B). A CBCT image was taken at the completion of CMA usage after the achievement of bilateral Class I molar and canine relationships (T2).

If a patient had a unilateral Class I molar and Class II canine on the Class I molar side, the CMA was still bonded and used until a Class I canine relationship was achieved on that side. However, the elastic protocol was to use 1/4” 6 oz elastics for the Class I molar side.

### CBCT Analysis

Pretreatment and post-CMA CBCTs were taken with the iCAT FLX (Kavo Kerr, Brea, Calif) at a field of view size of 16 cm × 13 cm or 23 cm × 17 cm, and traced by



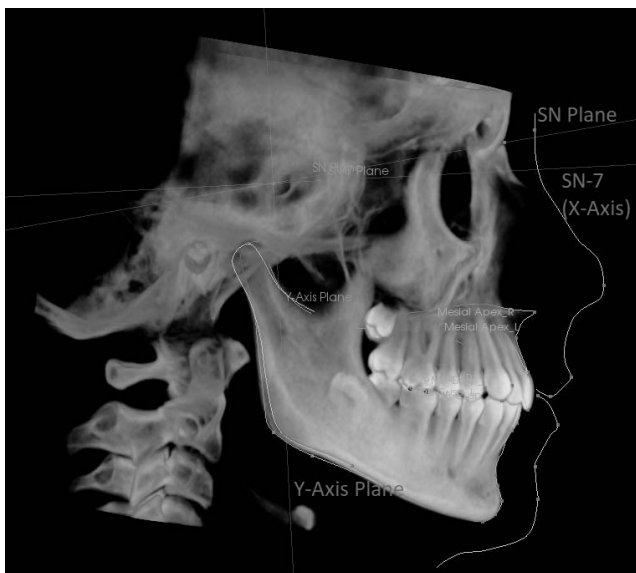
**Figure 1.** Carriere Motion appliance (A) before Class II correction and (B) after Class II correction.

**Table 2.** Landmarks, Abbreviations, and Definitions Used

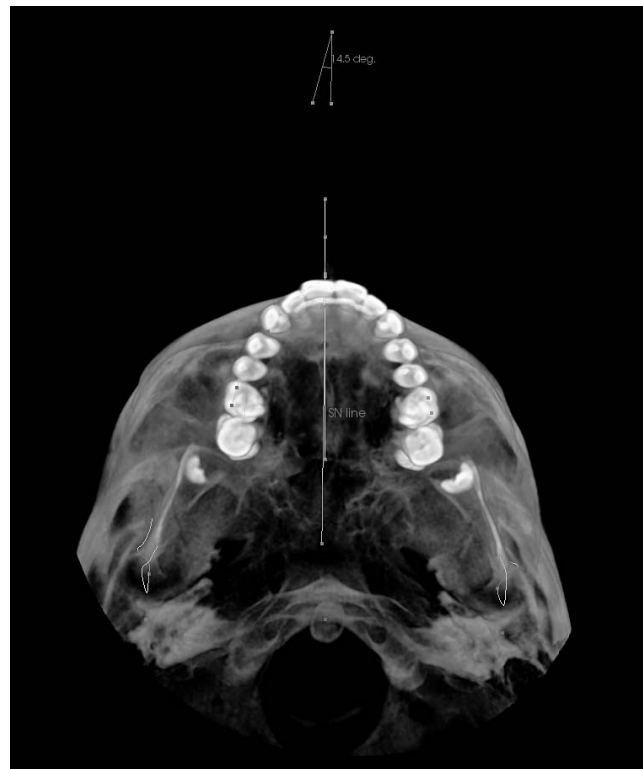
Landmarks	Abbreviations	Operational Definitions
Subspinale/A point	A	The most posterior midline point in the concavity between the anterior nasal spine and the prosthion on the midsagittal plane
Supramentale/B point	B	The most posterior midline point in the concavity of the mandible between the most superior point on the alveolar bone overlying the lower incisors and pogonion on the midsagittal plane
Nasion	N	Most anterior on the frontonasal suture in the midsagittal plane
Sella	S	Geometric center of of the pituitary fossa located by visual inspection
Posterior nasal spine	PNS	The posterior spine of the palatine bone constituting the hard plane
Anterior nasal spine	ANS	The anterior tip of the sharp bony process of the maxilla at the lower margin of the anterior nasal opening
Gonion (anatomical)	Go	A point on the curvature of the angle of the mandible located by bisecting the angle formed by the lines tangent to the posterior ramus and the inferior border of the mandible
Condylion	Co, Cd	The highest point on the curvature of the averaged condyles of the mandible
Incision superius	U1	The incisal tip of the most anterior maxillary incisor
Incision inferius	L1	The incisal tip of the most labial mandibular anterior incisor
Maxillary molar mesiobuccal cusp tip	U6 MB cusp	The mesiobuccal cusp tip of the maxillary first molar (right and left)
Maxillary molar distobuccal cusp tip	U6 DB cusp	The distobuccal cusp tip of the maxillary first molar (right and left)
Mandibular molar mesiobuccal cusp tip	L6 MB cusp	The mesiobuccal cusp tip of the mandibular first molar (right and left)
Mandibular molar distobuccal cusp tip	L6 DB cusp	The distobuccal cusp tip of the mandibular first molar (right and left)
Maxillary molar mesiobuccal root apex	U6 MB root	The mesiobuccal root apex of the maxillary first molar (right and left)
Mandibular molar mesial root apex	L6 M root	The mesial root apex of the mandibular first molar (right and left)

the principal investigator (Dr Areepong) with use of Invivo 6.0 and 3D Analysis software (Anatomage, San Jose, Calif). Accuracy of landmark identification was noted, and no clinical significance between CBCT tracings and lateral cephalometric tracings was found.<sup>18</sup> Bilateral structures were traced separately to identify 16 landmarks (Table 2) and averaged for comparison between groups. Frankfort horizontal was created by using SN-7 to represent the X-axis and a perpendicular to represent the Y-axis in order to measure distal and mesial movement of the maxillary molar, maxillary canine, and mandibular molar (Figure

2). The rotational movements of the maxillary canine and molar were measured from the SN line (Figure 3). Thirty-six linear and angular measurements were generated through the 3D Analysis software from the traced points (Table 3).



**Figure 2.** Cone beam computed tomography analysis in the AP and vertical dimensions.



**Figure 3.** Cone beam computed tomography analysis in the transverse dimension.

**Table 3.** Measurements, Abbreviations, and Definitions Used and Error Analysis

Measurements	Abbreviations	Operational Definitions	Cronbach $\alpha$
AP dental	U1-SN (°)	The angle measured through the long axis of the right central incisor to the SN plane viewed from the lateral	0.995
	IMPA (°)	The angle measured through the long axis of the right mandibular central incisor in relation to the right Gonion-Menton line viewed from the lateral	0.969
	Overjet (mm)	The horizontal distance from the maxillary right central incisor cusp tip to the mandibular right central incisor tip when projected and viewed from the lateral	0.985
	U3 AP position (mm)	The horizontal distance from the canine cusp tip to the Y-axis and parallel to SN-7 (right and left)	Right: 0.949 Left: 0.967
	U6 AP position (mm)	The horizontal distance from the mesiobuccal cusp tip of the maxillary first molar to the Y-axis and parallel to SN-7 (right and left)	Right: 0.961 Left: 0.986
	L6 AP position (mm)	The horizontal distance from the mesiobuccal cusp tip of the mandibular first molar to the Y-axis and parallel to SN-7 (right and left)	Right: 0.962 Left: 0.986
	U3 angle (°)	The angle measured through the long axis of the canine (cusp tip to root apex) in relation to the Sella-Nasion line viewed from the lateral (right and left)	Right: 0.989 Left: 0.935
	U6 angle (°)	The angle measured through the long axis of the mesiobuccal cusp to the mesiobuccal root apex of the maxillary first molar in relation to the Sella-Nasion line viewed from the lateral (right and left)	Right: 0.962 Left: 0.964
	L6 angle (°)	The angle measured through the long axis of the mesiobuccal cusp to the mesial root apex of the mandibular first molar in relation to the Sella-Nasion line viewed from the lateral (right and left)	Right: 0.975 Left: 0.980
	Vertical dental	Overbite (mm)	The vertical distance from the maxillary right central incisor cusp tip to the mandibular right central incisor tip when projected and viewed from the lateral
OP-SN (°)		The angle measured by the occlusal plane (bisecting the molars and incisors) to the SN plane	0.985
U3 vertical position (mm)		The vertical distance from the X-axis (SN-7 plane) to the cusp tip of the canine (right and left)	Right: 0.992 Left: 0.996
Transverse dental	U3 rotation (°)	The angle measured from the plane created from the anatomic mesial point of the canine to the anatomic distal point of the canine in relation to the Sella-Nasion line viewed from the occlusal (right and left)	Right: 0.978 Left: 0.987
	U6 rotation (°)	The angle measured from the plane created from the mesiobuccal cusp to the distobuccal cusp of the maxillary first molar in relation to the Sella-Nasion line viewed from the occlusal (right and left)	Right: 0.895 Left: 0.932
Vertical skeletal	MP-SN (°)	The angle measured by the mandibular plane (gonion to menton) to the SN plane	0.988

## Statistical Methods

Reliability was judged using Cronbach alpha (Table 3). Descriptive statistics were calculated for 36 measurements in both groups at T1 and T2. The Wilcoxon signed-rank test was performed to test significance between T1 and T2 in each group, as the population was not assumed to be normally distributed. A Welch *t*-test was performed to compare groups 1 and 2 after left and right measurements were combined into averages. Treatment time was compared between groups 1 and 2 with a paired *t*-test. All analyses were performed using the software R (version 3.4.2).

## RESULTS

Groups 1 and 2 had mean treatment durations of 150 days (4.9 months) and 129 days (4.2 months), respectively, which were not significantly different. The 36 measurements at T1 and T2 are described in Table 4 for group 1 and Table 5 for group 2.

### Treatment Changes from T1 to T2 in Group 1

Group 1 showed statistically significant changes in all 36 variables except for U1-SN, Right U3 rotation, and MP-SN (Table 4). The maxillary canines underwent statistically significant distal movement of  $2.34 \pm 1.07$  mm (right:  $2.57 \pm 1.28$  mm; left:  $2.12 \pm 1.19$  mm), as they tipped distally by  $6.34 \pm 3.22^\circ$  (right:  $7.50$



**Table 4.** Changes in Measurements From T1 to T2 in Group 1

		T1		T2		Difference		
		Mean	Standard Deviation	Mean	Standard Deviation	Mean	Standard Deviation	
AP dental	U1-SN (°)	105.00	10.58	104.92	8.72	0.07	2.95	
	IMPA (°)	95.36	5.58	98.86	6.12	-3.50 <sup>a</sup>	2.62	
	Overjet (mm)	5.15	2.08	3.45	1.87	1.70 <sup>a</sup>	1.28	
	U3 AP position (mm)	Average	58.53	4.14	56.18	4.42	2.34 <sup>a</sup>	1.07
		Right	59.05	4.30	56.48	4.49	2.57 <sup>a</sup>	1.28
		Left	58.01	4.11	55.89	4.47	2.12 <sup>a</sup>	1.19
	U6 AP position (mm)	Average	38.71	4.27	36.79	4.35	1.92 <sup>a</sup>	0.80
		Right	38.81	4.52	36.80	4.54	2.01 <sup>a</sup>	1.05
		Left	38.60	4.15	36.77	4.26	1.83 <sup>a</sup>	0.84
	L6 AP position (mm)	Average	37.96	4.06	39.33	4.46	-1.37 <sup>a</sup>	1.23
		Right	37.57	4.36	39.14	4.78	-1.57 <sup>a</sup>	1.44
		Left	38.35	3.88	39.52	4.24	-1.17 <sup>a</sup>	1.14
	U3 angle (°)	Average	95.47	5.42	89.13	6.16	6.34 <sup>a</sup>	3.22
		Right	97.24	5.99	89.74	7.02	7.50 <sup>a</sup>	3.74
		Left	93.70	5.52	88.52	5.85	5.18 <sup>a</sup>	3.74
	U6 angle (°)	Average	78.15	5.57	73.56	6.24	4.59 <sup>a</sup>	2.46
		Right	77.87	5.59	73.01	5.78	4.86 <sup>a</sup>	2.95
		Left	78.43	6.45	74.10	7.29	4.32 <sup>a</sup>	3.18
	L6 angle (°)	Average	65.04	5.48	61.34	6.67	3.68 <sup>a</sup>	3.21
		Right	64.54	5.66	60.47	6.28	4.07 <sup>a</sup>	3.31
Left		65.54	6.12	62.25	7.85	3.29 <sup>a</sup>	3.74	
Vertical dental	Overbite (mm)	3.53	1.81	1.98	1.53	1.55 <sup>a</sup>	1.71	
	OP-SN (°)	13.13	5.28	14.79	4.98	-1.66 <sup>a</sup>	1.79	
	U3 vertical position (mm)	Average	63.44	3.96	64.98	3.68	-1.54 <sup>a</sup>	1.17
		Right	63.40	4.02	65.05	3.73	-1.65 <sup>a</sup>	1.30
		Left	63.49	4.09	64.90	3.83	-1.42 <sup>a</sup>	1.26
	L6 vertical position (mm)	Average	60.30	3.00	62.00	3.13	-1.69 <sup>a</sup>	0.96
Right		60.47	2.89	62.01	3.04	-1.55 <sup>a</sup>	1.04	
Left		60.14	3.20	61.98	3.31	-1.84 <sup>a</sup>	1.08	
Transverse dental	U3 rotation (°)	Average	28.97	9.28	25.78	10.90	3.19 <sup>b</sup>	6.98
		Right	28.70	9.99	25.24	11.42	3.46	10.04
		Left	29.24	12.35	26.32	12.61	2.92 <sup>b</sup>	6.94
	U6 rotation (°)	Average	12.98	6.09	9.40	6.60	3.58 <sup>a</sup>	8.44
		Right	14.39	7.38	10.46	8.22	3.93 <sup>b</sup>	6.77
		Left	11.57	7.21	8.34	7.35	3.22 <sup>b</sup>	6.98
Vertical skeletal	MP-SN (°)	28.68	4.67	29.22	5.25	-0.54	1.60	

<sup>a</sup> Wilcoxon signed-rank test for equality of means was significant at the 0.01 level (two-tailed).

<sup>b</sup> Wilcoxon signed-rank test for equality of means was significant at the 0.05 level (two-tailed).

± 3.74°; left: 5.18 ± 3.74°), rotated distally by 3.19 ± 6.98° (right: 3.46 ± 10.04°; left: 2.92 ± 6.94°), and extruded by 1.54 ± 1.17 mm (right: 1.65 ± 1.30 mm; left: 1.42 ± 1.26 mm). Similarly, the maxillary first molars underwent statistically significant distal movement by 1.92 ± 0.80 mm (right: 2.01 ± 1.05 mm; left: 1.83 ± 0.84 mm), as they tipped distally by 4.59 ± 2.46° (right: 4.86 ± 2.95°; left: 4.32 ± 3.18°) and rotated distally by 3.58 ± 8.44° (right: 3.93 ± 6.77°; left: 3.22 ± 6.98°).

The mandibular first molars underwent statistically significant mesial movement by 1.37 ± 1.23 mm (right: 1.57 ± 1.44 mm; left: 1.17 ± 1.14 mm), as they tipped mesially by 3.68 ± 3.21° (right: 4.07 ± 3.31°; left: 3.29 ± 3.74°) and extruded by 1.69 ± 0.96 mm (right: 1.55 ± 1.04 mm; left: 1.84 ± 1.08 mm). The mean IMPA significantly increased by 3.50 ± 2.62°.

### Treatment Changes from T1 to T2 in Group 2

As shown in Table 5, all variables except MP-SN were statistically significantly changed. The maxillary canines underwent statistically significant distal movement by 2.24 ± 1.91 mm (right: 2.25 ± 2.15 mm; left: 2.24 ± 1.80 mm), as they tipped distally by 7.44 ± 5.56° (right: 7.46 ± 5.96°; left: 7.41 ± 5.85°), rotated distally by 6.47 ± 5.27° (right: 4.87 ± 6.65°; left: 8.07 ± 7.23°), and extruded by 1.87 ± 1.36 mm (right: 2.03 ± 1.55 mm; left: 1.71 ± 1.28 mm). Similarly, the maxillary first molars underwent statistically significant distal movement by 1.67 ± 1.56 mm (right: 1.81 ± 1.77 mm; left: 1.53 ± 1.63 mm), as they tipped distally by 6.45 ± 4.75° (right: 6.98 ± 5.56°; left: 5.91 ± 4.50°) and rotated distally by 4.64 ± 5.72° (right: 4.17 ± 6.65°; left: 5.12 ± 7.23°).

**Table 5.** Changes in Measurements From T1 to T2 in Group 2

		T1		T2		Difference		
		Mean	Standard Deviation	Mean	Standard Deviation	Mean	Standard Deviation	
AP dental	U1-SN (°)	98.87	9.11	100.73	7.80	-1.86 <sup>a</sup>	3.26	
	IMPA (°)	99.08	6.76	103.13	6.41	-4.06 <sup>a</sup>	3.28	
	Overjet (mm)	4.76	1.92	2.73	1.78	2.03 <sup>a</sup>	1.61	
	U3 AP position (mm)	Average	59.40	4.19	57.16	4.46	2.24 <sup>a</sup>	1.91
		Right	59.61	4.36	57.35	4.61	2.25 <sup>a</sup>	2.15
		Left	59.19	4.18	56.96	4.44	2.24 <sup>a</sup>	1.80
	U6 AP position (mm)	Average	38.48	4.24	36.81	4.38	1.67 <sup>a</sup>	1.56
		Right	38.67	4.44	36.87	4.45	1.81 <sup>a</sup>	1.77
		Left	38.29	4.19	36.76	4.42	1.53 <sup>a</sup>	1.63
	L6 AP position (mm)	Average	37.23	4.43	39.74	4.53	-2.51 <sup>a</sup>	1.51
		Right	37.16	4.53	39.71	4.54	-2.55 <sup>a</sup>	1.44
		Left	37.31	4.45	39.77	4.62	-2.46 <sup>a</sup>	1.76
	U3 angle (°)	Average	95.34	4.87	87.91	6.64	7.44 <sup>a</sup>	5.56
		Right	95.75	6.20	88.29	7.18	7.46 <sup>a</sup>	5.96
		Left	94.94	4.89	87.52	6.80	7.41 <sup>a</sup>	5.85
	U6 angle (°)	Average	75.31	5.69	68.87	8.30	6.45 <sup>a</sup>	4.75
		Right	76.31	6.31	69.33	8.67	6.98 <sup>a</sup>	5.56
		Left	74.32	5.63	68.41	8.36	5.91 <sup>a</sup>	4.50
L6 angle (°)	Average	62.05	5.16	58.38	6.38	3.67 <sup>a</sup>	3.61	
	Right	62.08	5.15	58.05	6.78	4.03 <sup>a</sup>	4.47	
	Left	62.03	5.54	58.72	6.48	3.31 <sup>a</sup>	3.57	
Vertical dental	Overbite (mm)	3.45	1.56	1.45	1.27	2.00 <sup>a</sup>	1.38	
	OP-SN (°)	17.16	3.94	18.67	3.95	-1.51 <sup>a</sup>	2.19	
	U3 vertical position (mm)	Average	63.94	4.80	65.80	4.25	-1.87 <sup>a</sup>	1.36
		Right	63.91	4.79	65.94	4.12	-2.03 <sup>a</sup>	1.55
		Left	63.96	4.91	65.67	4.49	-1.71 <sup>a</sup>	1.28
	L6 vertical position (mm)	Average	60.07	3.43	61.86	3.61	-1.79 <sup>a</sup>	1.26
Right		60.12	3.40	61.94	3.61	-1.82 <sup>a</sup>	1.40	
Left		60.01	3.56	61.77	3.69	-1.76 <sup>a</sup>	1.22	
Transverse dental	U3 rotation (°)	Average	31.76	10.95	25.29	11.62	6.47 <sup>a</sup>	5.27
		Right	29.66	10.90	24.79	11.86	4.87 <sup>a</sup>	6.65
		Left	33.86	12.76	35.79	13.89	8.07 <sup>a</sup>	7.23
	U6 rotation (°)	Average	13.88	6.53	9.24	5.42	4.64 <sup>a</sup>	5.72
		Right	13.81	7.10	9.64	6.87	4.17 <sup>b</sup>	6.65
		Left	13.95	8.42	8.83	5.94	5.12 <sup>a</sup>	7.23
Vertical skeletal	MP-SN (°)	32.75	5.11	33.22	4.99	-0.47	1.47	

<sup>a</sup> Wilcoxon signed-rank test for equality of means was significant at the 0.01 level (two-tailed).

<sup>b</sup> Wilcoxon signed-rank test for equality of means was significant at the 0.05 level (two-tailed).

The mandibular first molars underwent statistically significant mesial movement by  $2.51 \pm 1.51$  mm (right:  $2.55 \pm 1.44$  mm; left:  $2.46 \pm 1.76$  mm), as they tipped mesially by  $2.51 \pm 1.51^\circ$  (right:  $2.55 \pm 1.44^\circ$ ; left:  $2.46 \pm 1.76^\circ$ ) and extruded by  $1.79 \pm 1.26$  mm (right:  $1.82 \pm 1.40$  mm; left:  $1.76 \pm 1.22$  mm). The mean IMPA significantly increased by  $4.06 \pm 3.28^\circ$ .

### Comparisons Between Group 1 and Group 2

As shown in Table 6, the T1–T2 changes of 16 measurements were compared between groups 1 and 2. The lower first molars underwent statistically significantly more mesial movement in group 2 than group 1. Group 2 showed statistically significantly more proclination of the maxillary central incisors than group 1.

### DISCUSSION

This research focused on the dentoalveolar treatment effects, which were mainly expected with the CMA.<sup>19</sup> Class II correction was achieved in a mean treatment time of 4.9 and 4.2 months in group 1 and group 2, respectively, which was similar to the 4.4 months reported by Sandifer et al.,<sup>19</sup> and shorter than 8.5 months when only Class II elastics were used.<sup>20</sup> As shown in Table 1, group 2 with skeletal Class II (ANB  $> 4^\circ$ ) had a more severely Class II molar relationship at T1. Interestingly, the results suggested that CMA can successfully correct these molar and canine relationships, similarly to the less severe presentation in patients in group 1 with skeletal Class I relationships (ANB  $0$ – $4^\circ$ ).

Previous reports available on CMA did not use CBCT to assess canine or molar movements.<sup>19</sup> It is

**Table 6.** Comparison of the Treatment Changes Between Group 1 and Group 2

			T1-T2 Difference				Significance
			Group 1		Group 2		
			Mean	Standard Deviation	Mean	Standard Deviation	
Dental	AP	U1-SN (°)	0.073	2.95	-1.859	3.26	.021 <sup>a</sup>
		IMPA (°)	-3.502	2.62	-4.057	3.28	.477
		Overjet (mm)	1.702	1.28	2.025	1.61	.399
		U3 AP position average (mm)	2.345	1.070	2.244	1.91	.802
		U6 AP position average (mm)	1.921	0.80	1.669	1.56	.434
		L6 AP position average (mm)	-1.370	1.23	-2.507	1.51	.019 <sup>a</sup>
		U3 angle average (°)	6.340	3.22	7.435	5.56	.354
		U6 angle average (°)	4.592	2.46	6.446	4.75	.063
	Vertical	L6 angle average (°)	3.676	3.21	3.672	3.61	.995
		Overbite (mm)	1.555	1.71	2.001	1.38	.285
		OP-SN (°)	-1.665	1.79	-1.513	2.19	.773
		U3 extrusion (mm)	-1.535	1.17	-1.870	1.36	.320
	Transverse	L6 extrusion (mm)	-1.693	0.96	-1.788	1.26	.745
		U3 rotation (°)	3.191	6.98	6.471	5.27	.052
Skeletal	Vertical	U6 rotation (°)	3.577	8.44	4.644	5.72	.477
		MP-SN (°)	-0.536	1.60	-0.474	1.47	.881

<sup>a</sup> Welch *t*-test for equality of means was significant at the .05 level (two-tailed).

also worth noting the rotational changes can be observed with CBCT but not with conventional lateral cephalometric analysis. This report has also shown the similar treatment changes in the left and right canines and molars, as shown in Tables 4 and 5. This is probably because bilateral Class II molar relationships were more often observed than unilateral Class II in both groups, and a similar elastic protocol was used for both sides.

### Treatment Changes from T1 to T2

**Maxillary canine movements.** The distal movement of maxillary canines showed components of tipping and rotation in both groups. This data did not correlate directly with the manufacturer's claim of "distal movement of the canine along the alveolar ridge without tipping"<sup>15</sup> as the data showed tipping of the maxillary canine in groups 1 and 2 ( $6.34 \pm 3.22^\circ$  and  $7.44 \pm 5.56^\circ$ , respectively).

Extrusion of maxillary canines in both groups was similar (1.54 mm in group 1 and 1.87 mm in group 2), suggesting that CMA may be beneficial if maxillary canines require extrusion.

Both canine to molar (regular) CMA and premolar to molar (shorty) CMA were included in this study to increase the sample size. Group 1 included 4 bilateral shorty CMA patients and 23 bilateral regular CMA patients, while group 2 included 8 bilateral shorty CMA patients, 23 bilateral regular CMA patients, and one combination patient. If patients with shorty CMA were excluded in this study, more movement of the canines could have been expected.

**Maxillary molar movements.** On average, with the CMA, distal movement of the maxillary first molars was 1.80 mm (1.92 mm in group 1 and 1.67 mm in group 2), approximately the same as previously reported by Sandifer et al.,<sup>19</sup> while only Class II elastics did not show any significant maxillary molar movements.<sup>20</sup> The CMA produced significant distal rotation and tipping of the maxillary first molars. This confirmed the manufacturer's claim that the appliance produces "distal rotation around the palatal root."<sup>15</sup>

Although not statistically significant, the data suggested that, in skeletal Class II patients, the amount of tipping and rotation of maxillary molars may be greater than skeletal Class I patients ( $6.45^\circ$  tipping and  $4.64^\circ$  rotation in group 2, and  $4.59^\circ$  tipping and  $3.58^\circ$  rotation in group 1).

In this study, when a patient had a unilateral Class II canine on the Class I molar side, the CMA was still bonded and used until a Class I canine relationship was achieved on that side. However, the elastic protocol was to use 1/4" 6 oz elastics for the Class I molar side, not 3/16" 8 oz elastics. As shown in Table 1, bilateral Class II molar relationships were found less often in group 1 than group 2. In addition, a full-step Class II molar relationship was found less often in group 1 than group 2. Thus, although not significant, the differences in distal tipping and rotation of the first molars between the groups may be related to these variations.

**Mandibular molar movements.** The amounts of mesial tipping, rotation, and extrusion of lower molars were almost identical between the groups. This suggested that the Essix retainers provided enough

anchorage in group 2, which had more severe Class II molar relationships than group 1. Meanwhile, the correction of the Class II malocclusion in skeletal Class II patients came more from the mesial movement of the mandibular molars (2.51 mm in group 2 and 1.37 mm in group 1). The mesial movement shown in this study was more than the 1.2 mm found when only Class II elastics were used.<sup>20</sup> It is hard to conclude whether the whole dentition moved mesially in the mandible as lower incisor AP position was not measured.

**Maxillary incisor.** The difference in change of the U1-SN in group 1 compared with group 2 was statistically significant. In group 2, the maxillary incisor was shown to have flared by 1.86°, compared with 0.07° of uprighting in group 1. Although there was no significant difference in IMPA changes between the groups, the lower incisors may have advanced more in group 2, thereby causing the upper incisors to tip forward. Further research is required to investigate changes in the AP position of lower incisors with the use of CMA.

**Mandibular incisors.** The increase in IMPA was not significantly different between groups 1 and 2 (3.50° and 4.06°, respectively). This may suggest that, as an anchorage unit, an Essix retainer is better than a lower lingual holding arch (4.6°) but worse than fixed appliances (1.2°).<sup>19</sup>

Overjet is typically observed in Class II malocclusions. From the data, although fixed appliances were not used on the anterior teeth, group 1 showed a mean 1.70 mm of overjet reduction, while group 2 showed a mean 2.03 mm reduction, similar to the 1.87 mm reported previously<sup>19</sup> but less than the 5.8 mm when only Class II elastics were used in combination with fixed appliances.<sup>20</sup>

Both groups showed decreases in overbite (1.55 mm in group 1 and 2.00 mm in group 2), similar to the 1.78 mm reduction previously reported<sup>19</sup> but less than the 3.0 mm shown when only Class II elastics were used in combination with fixed appliances.<sup>20</sup> The overbite reduction observed was probably due to the extrusion of lower molars, distal tipping of upper molars, and flaring of the lower incisors with the use of CMA.

**MP-SN and OP-SN.** Mandibular and occlusal plane angles underwent similar changes between the two groups. Mean mandibular plane changes were -0.54° and -0.47° in groups 1 and 2, respectively. Mean occlusal plane changes were -1.66° and -1.51°, respectively. Clinicians may observe that the mandibular plane angle likely does not change or increases slightly, and occlusal plane angles may increase slightly, with the use of CMA.

## Limitations

The limitations of this research included the following: (1) there was no comparison to a nontreated sample, (2) there were no reports available regarding patient compliance, and (3) overall treatment was not completed at the time of data collection. Additionally, SN-7 was used as a reference line instead of FH plane because some of the CBCT images did not include the external auditory meatus.

## CONCLUSIONS

- The Class II CMA was effective at correcting Class II malocclusions before fixed appliance treatment in a mean time of 4.6 months.
- The maxillary canine showed distal movement with distal tipping, distal rotation, and extrusion.
- The maxillary first molar showed distal movement with distal tipping and rotation.
- The mandibular first molar showed mesial movement with mesial tipping and extrusion.
- Lower incisor proclination was evident even with the use of an Essix retainer as anchorage in the lower arch.
- When comparing skeletal Class I and Class II patients, mandibular molar mesial movement appeared to be the difference in the added correction observed in skeletal Class II patients.
- Maxillary incisor flaring after CMA was more evident in skeletal Class II patients than in skeletal Class I patients.

## ACKNOWLEDGMENTS

The authors wish to acknowledge Dr David Paquette, Dr Becky Schreiner, and Dr Shipley Thomas for providing the sample.

## REFERENCES

1. Rogers A. Henry Albert Baker. *Am J Orthod.* 1958;44:940–942.
2. Janson G, Sathler R, Fernandes TMF, Branco NCC, de Freitas MR. Correction of Class II malocclusion with Class II elastics: a systematic review. *Am J Orthod Dentofacial Orthop.* 2013;143:383–392.
3. Baumrind S, Molthen R, West EE, Miller DM. Distal displacement of the maxilla and the upper first molar. *Am J Orthod.* 1979;75:630–640.
4. Firouz M, Zernik J, Nanda R. Dental and orthopedic effects of high-pull headgear in treatment of Class II, division 1 malocclusion. *Am J Orthod Dentofacial Orthop.* 1992;102:197–205.
5. Keeling SD, Wheeler TT, King GJ, et al. Anteroposterior skeletal and dental changes after early Class II treatment with bionators and headgear. *Am J Orthod Dentofacial Orthop.* 1998;113:40–50.



6. Antonarakis GS, Kiliaridis S. Maxillary molar distalization with noncompliance intramaxillary appliances in Class II malocclusion: a systematic review. *Angle Orthod.* 2008;78:1133–1140.
7. Papadopoulos MA. Overview of the intra-maxillary non-compliance appliances with absolute anchorage. In: *Orthodontic Treatment for the Class II Non-compliant Patient: Current Principles and Techniques*. Edinburgh, Scotland: Elsevier, Mosby; 2006:341–344.
8. Papadopoulos MA. Orthodontic treatment of Class II malocclusion with miniscrew implants. *Am J Orthod Dentofacial Orthop.* 2008;134:604.e1–. e16.
9. Franchi L, Alvetro L, Giuntini V, Masucci C, Defraia E, Baccetti T. Effectiveness of comprehensive fixed appliance treatment used with the Forsus Fatigue Resistant Device in Class II patients. *Angle Orthod.* 2011;81:678–683.
10. Jones G, Buschang PH, Kim KB, Oliver DR. Class II non-extraction patients treated with the Forsus Fatigue Resistant Device versus intermaxillary elastics. *Angle Orthod.* 2008;78:332–338.
11. Pancherz H. Treatment of Class II malocclusions by jumping the bite with the Herbst appliance: a cephalometric investigation. *Am J Orthod.* 1979;76:423–442.
12. Ludwig B, Glasl B, Kinzinger G, Walde KC, Lisson JA. The skeletal frog appliance for maxillary molar distalization. *J Clin Orthod.* 2011;45:77–84; quiz 91.
13. Paulose J, Antony PJ, Sureshkumar B, George SM, Mathew MM, Sebastian J. PowerScope a Class II corrector—a case report. *Contemp Clin Dent.* 2016;7:221.
14. Zymperdikas VF, Koretsi V, Papageorgiou SN, Papadopoulos MA. Treatment effects of fixed functional appliances in patients with Class II malocclusion: a systematic review and meta-analysis. *Eur J Orthod.* 2015;38:113–126.
15. Carrière L. A new Class II distalizer. *J Clin Orthod.* 2004;38:224–231.
16. Rodríguez H. Nonextraction treatment of a Class II open bite in an adult patient. *J Clin Orthod.* 2012;46:367–371.
17. Rodríguez H. Unilateral application of the Carriere distalizer. *J Clin Orthod.* 2011;45:177–180.
18. Grauer D, Cevidanes LS, Styner MA, et al. Accuracy and landmark error calculation using cone-beam computed tomography-generated cephalograms. *Angle Orthod.* 2010;80:286–294.
19. Sandifer CL, English JD, Colville CD, Gallerano RL, Akyalcin S. Treatment effects of the Carrière distalizer using lingual arch and full fixed appliances. *World J Orthod.* 2014;3:e49–e54.
20. Guilherme J, Renata S, Thais Maria Freire F, Nuria Cabral Castello B, Marcos Robertp de F. Correction of Class II malocclusion with Class II elastic: a systemic review. *Am J Orthod Dentofacial Orthop.* 2013;143:383–392.