

# Long-term follow-up of intersegmental displacement after orthognathic surgery using cone-beam computed tomographic superimposition

Jae-Yeol Lee<sup>a</sup>; Seung-Min Lee<sup>b</sup>; Sung-Hun Kim<sup>c</sup>; Yong-Il Kim<sup>d</sup>

## ABSTRACT

**Objectives:** To evaluate intersegmental displacement during long-term follow-up after bilateral sagittal split osteotomy (BSSO) by mandibular body area superimposition.

**Materials and Methods:** Cone-beam computed tomography (CBCT) images of 23 patients ages 18–37 years with class III malocclusion before orthognathic surgery were obtained. A three-dimensional (3D) CBCT examination was performed at four stages: surgery (T0), 6 months after surgery (T1), 1 year after surgery (T2), and long-term follow-up ( $6.1 \pm 2.1$  years, T3). The CBCT datasets were superimposed on the symphyseal area and the lower part of the distal segment of the mandible between T0 and the other time points (T1, T2, and T3). The reference points (both condyle, coronoid, and sigmoid) were estimated by the CBCT analyzed program.

**Results:** The coronoid, condylion, and sigmoid showed changes within 6 months after surgery, but there was no significant change in the intersegmental displacement between 6 months and 6 years after surgery. The distances between the left and right coronoid, condylion, and sigmoid from T0 to T3 were noted.

**Conclusions:** The change in intersegmental displacement between T0 and T3 affecting relapse after orthognathic surgery was not significantly different. This suggests that the mandible itself may have a stable morphology during the follow-up period. (*Angle Orthod.* 2020;90:548–555.)

**KEY WORDS:** Orthognathic surgery; Long-term follow-up; Intersegmental displacement; Cone-beam computed tomography

## INTRODUCTION

Bilateral sagittal split osteotomy (BSSO) is commonly performed to correct mandibular prognathism. Despite adequate experience with this procedure,

relapse or movement of an anatomic point from the immediate postsurgical position is always encountered.<sup>1</sup> The possible factors resulting in the anatomic changes after orthognathic surgery include the extent of movement and rotation of the proximal segment, positional and morphological changes of the condyles, muscle tension, and residual growth.<sup>2–4</sup>

The first two authors contributed equally to this work.

<sup>a</sup> Associate Professor, Department of Oral and Maxillofacial Surgery, Pusan National University Dental Hospital, Yangsan, South Korea.

<sup>b</sup> Resident, Department of Orthodontics, Dental Research Institute, Pusan National University Dental Hospital, Yangsan, South Korea.

<sup>c</sup> Clinical Assistant Professor, Department of Orthodontics, Pusan National University Dental Hospital, Yangsan, South Korea.

<sup>d</sup> Associate Professor, Dental and Life Science Institute, School of Dentistry, Pusan National University, Busan, South Korea.

Corresponding author: Yong-Il Kim, PhD, Department of Orthodontics, Dental and Life Science Institute, School of Dentistry, Pusan National University, Dental Research Institute, Pusan National University Dental Hospital, Geumoro20, Mulgeu-meup, Yangsan 626-787, South Korea (e-mail: kimyongil@pusan.ac.kr)

Accepted: December 2019. Submitted: June 2019.

Published Online: March 5, 2020

© 2020 by The EH Angle Education and Research Foundation, Inc.

Changes in the proximal segment and condyle after BSSO can influence postoperative stability. Many studies have been published on the various positional and angular changes of the condyle and proximal segment following BSSO.<sup>5–8</sup> To compare condylar morphology and angulation changes after surgery, superimposition of three-dimensional (3D) cone-beam computed tomography (CBCT) models using voxel-based registration on the unaltered region of the anterior cranial base could be the best method. It allows quantification of the roll, yaw, and pitch movements of the distal and proximal segments and condylar morphological changes following BSSO, which are not possible to assess by two-dimensional (2D) radiographs.<sup>7,8</sup>

However, postoperative changes may occur at the site of the osteotomy as well as at the mandibular condyles due to changes in condylar positioning and postoperative remodeling.<sup>5,9</sup> Evaluation of intersegmental displacements or mandibular morphological changes is possible when the CBCT datasets are superimposed on the mandibular body area.<sup>10</sup> Also, most previous studies assessing stability after mandibular setback surgery have used a follow-up period of  $\leq 2$  years.<sup>1-3,6-10</sup> A few studies have used a follow-up period of 3-5 years.<sup>11,12</sup> Although many previous studies have reported that most of the relapse occurs within 1 year of surgery, it is important to understand the long-term skeletal changes for successful treatment prediction and completion of the procedure. The aim of this study was to evaluate post-BSSO intersegmental displacement during the long-term ( $6.1 \pm 2.1$  years) follow-up periods using CBCT superimposition on the mandibular body area.

Condyle positioning during orthognathic surgery is one of the important processes. Though surgeons try to position the condyle in a stable position, it often changes after the operation. This would make it difficult to discern condylar instability from intersegmental movements following surgery if radiographic superimposition is performed using only the anterior cranial base as a stable structure. Mandibular superimposition using stable structures inside the mandible is more reliable as surgical condylar positioning changes would not affect the analysis of intersegmental displacement using those structures. Nguyen et al.<sup>13</sup> reported that the mandibular symphysis was a stable structure. So in this study, the structures of the proximal segment: condyle, coronoid and sigmoid, were analyzed using mandibular anterior structure superimposition.

## MATERIALS AND METHODS

In this retrospective study, the subjects included 23 patients (nine males and 14 females; mean age,  $22.5 \pm 4.5$  years; range, 18-37 years) with mandibular prognathism who underwent BSSO with Le Fort I at the Pusan National University Dental Hospital between January 2007 and December 2015. Six subjects underwent BSSO only and 17 subjects underwent Le Fort I osteotomy and BSSO. The exclusion criteria were severe facial asymmetry, any syndrome, or cleft lip and or palate. All patients who had followed up for more than 4 years, including the 1-year follow-up appointment, were selected as subjects. This study was reviewed and approved by the Institutional Review Board of Pusan National University Dental Hospital.

Standard BSSO with mandibular setback was performed on the patients. Mandibular fixation was achieved by bicortical screws or mini plates through an

intraoral approach. Bicortical screws were applied in 12 subjects, plates were applied in eight subjects, and plate-screw combinations were applied in three subjects.

After a week of maxillo-mandibular fixation, the patients underwent physiotherapy for mouth opening. After that, intermaxillary elastics were used for proper occlusion. CBCT images (Pax-Zenith3D; Vatech Co., Seoul, Korea) were obtained to evaluate the intersegmental displacements immediately after surgery (T0), 6 months after surgery (T1), 1 year after surgery (T2), and long-term follow-up ( $6.1 \pm 2.1$  years, T3). The subjects sat upright in maximum intercuspation with reposed lips. The scanner settings were as follows: field of view,  $20 \times 19$  cm; tube voltage, 90 kVp; tube current, 4.0 mA; and scan time, 24 seconds. The CBCT raw data were reformatted to 3D images using 3D imaging software (OnDemand3D; Cybermed Co., Seoul, Korea).

To measure the maxillary surgical change, the changes in the distance from A point to N perpendicular were recorded. To assess the mandible surgical amount, the changes in the distance from Pogonion point to N perpendicular were recorded.

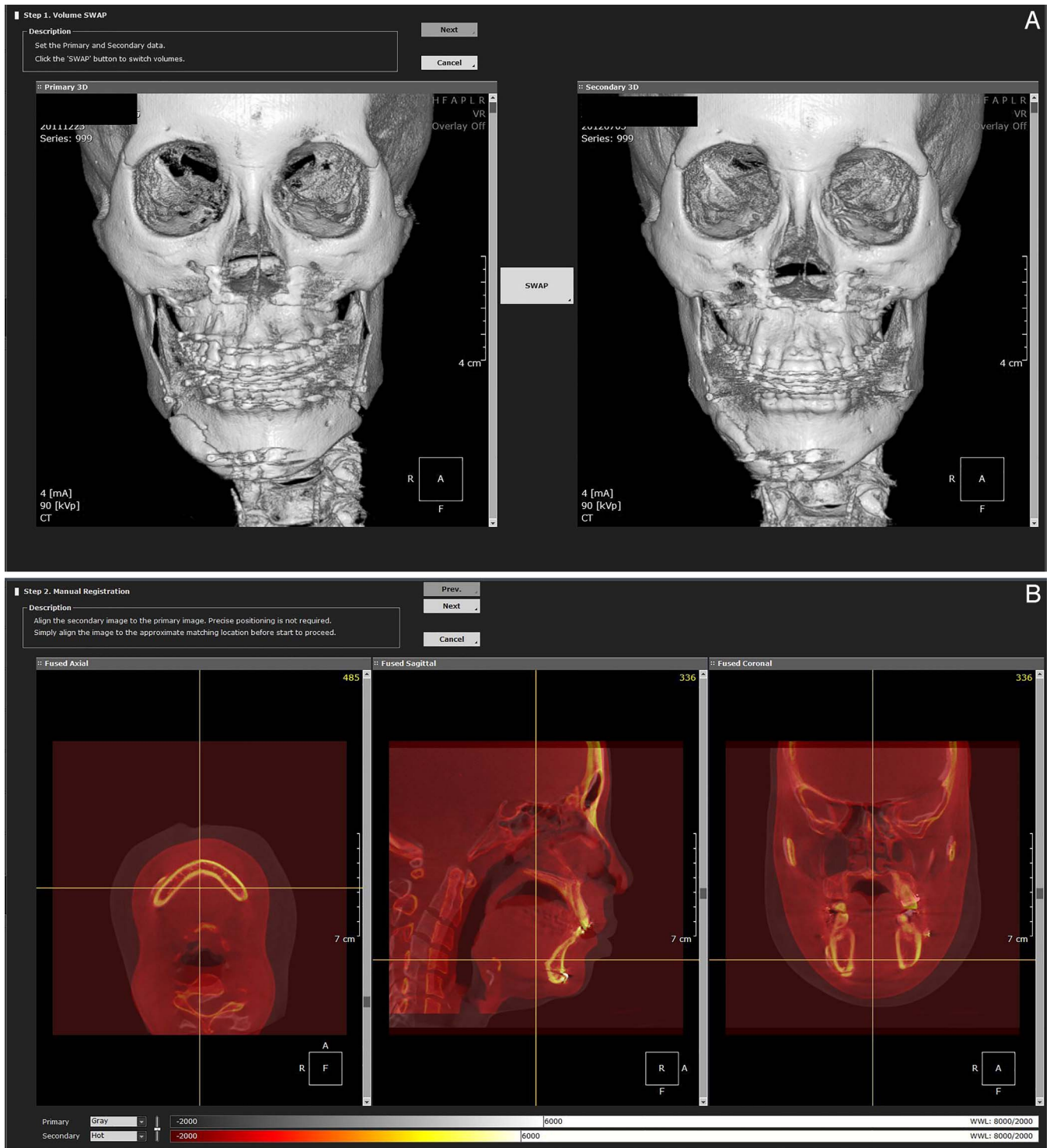
The CBCT datasets were superimposed on the symphyseal area and the lower part of the distal segment of the mandible between T0 and the other time points (T1, T2, and T3) using a 3D cephalometric module (OnDemand 3D; Cybermed) (Figure 1). The reference points and planes on the superimposed CBCT volumes were defined (Table 1). Both mental foramen (BMF) planes were constructed by both points of the mental foramen and B-point. The midsagittal reference (MSR) plane was perpendicular to the BMF plane passing through the right mental foramen. On the superimposed 3D images, the coordinate system (X, Y, Z) was reoriented with the zero point (0, 0, 0) at the right mental foramen. The positive directions were mesial, anterior, and superior for the X, Y, and Z axes, respectively (Figure 2).

## Statistical Analysis

The data were analyzed with a statistical software program (R program, version 3.5.1, R Foundation for Statistical Computing, Vienna, Austria). To determine the difference in distance among timepoints (T0, T1, T2, and T3), analysis of variance (ANOVA) with Duncan's multiple range test was used ( $P < .05$ ).

## RESULTS

The intraobserver reliability was very good. The mean intraclass correlation coefficient (ICC) for the X, Y, Z coordinate system ranged from 0.92 to 0.96. The ICC for condylion was 0.94 (0.88-0.97) for the X axis,



Downloaded from <http://meridian.allenpress.com/angle-orthodontist/article-pdf/90/4/548/2538671/0003-3219-90-4-548.pdf> by guest on 23 September 2020

**Figure 1.** (A) Setting the primary (T1) and secondary data (T0, T2, or T3), (B) Setting volume-of-interest (VOI) in the axial, sagittal, and coronal planes. The CBCT datasets were superimposed on the symphysis area and the lower part of the distal segment of the mandible. (C) Manual registration. Aligning the secondary (T0, T2, or T3) image to the primary (T1) image. (D) The MPR (multiplanar reconstruction) image.

0.93 (0.86–0.97) for the Y-axis, and 0.93 (0.86–0.97) for the Z-axis. The ICC for the sigmoid was 0.92 (0.84–0.96) for the X-axis, 0.93 (0.85–0.97) for the Y-axis, and 0.95 (0.89–0.98) for the Z-axis. The ICC for the

coronoid was 0.92 (0.84–0.96) for the X-axis, 0.96 (0.92–0.98) for the Y-axis, and 0.94 (0.87–0.97) for the Z-axis. The maxillary surgical changes averaged  $-0.2 \pm 2.2$  mm and the mandibular surgical changes



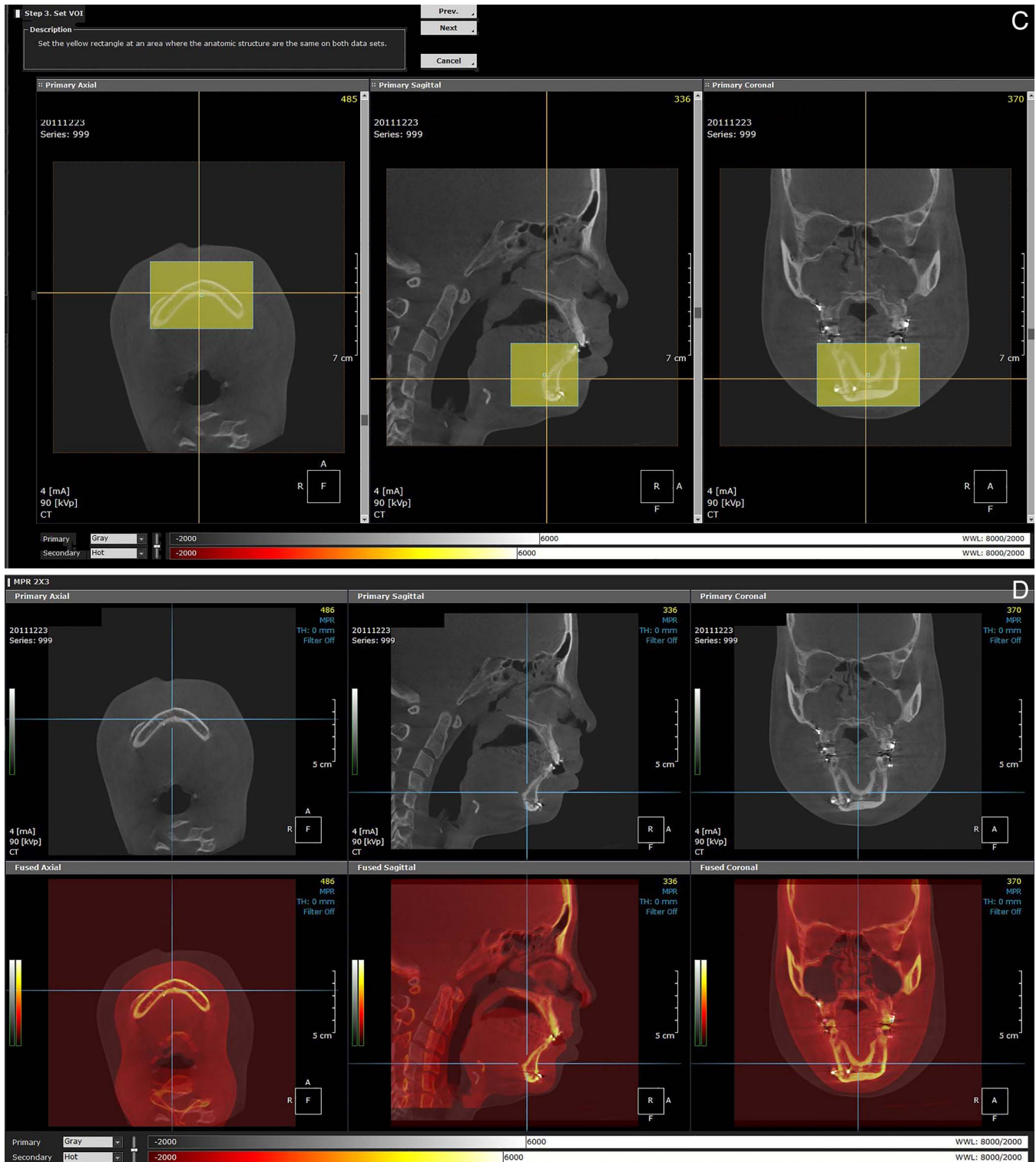


Figure 1. Continued.

averaged  $-8.5 \pm 4.5\text{mm}$ . There were no differences among different fixation groups.

Condylion moved inferiorly at T1 compared with T0, and there were no significant differences among T1,

T2, and T3. The sigmoid moved anteriorly and inferiorly at T1 compared to T0, and there were no significant differences among T1, T2, and T3. The coronoid moved anteriorly and inferiorly at T1 compared to T0,

**Table 1.** Reference Point and Reference Plane

Landmark	Description
Mental foramen	The anterior and superior point of the mental foramen
B-point	The most anterior point of the bony chin
Both mental foramen plane	Constructed by both points of mental foramen and B point
Midsagittal reference plane	Perpendicular to BMF plane passing through the right mental foramen and B-point bracket point
Condylion	The point at the top of the mandibular condyle
Sigmoid	The most concave point on the superior surface of the mandibular ramus between the coronoid and the condyloid processes
Coronoid	The point at the top of the mandibular coronoid

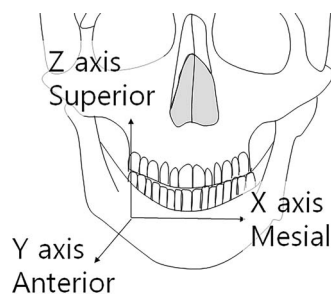
and there were no significant differences among T1, T2, and T3 (Table 2) (Figure 3).

The distances between the right and left condylion at T0, T1, T2, and T3 were  $102.8 \pm 7.7$  mm,  $103.8 \pm 7.6$  mm,  $102.5 \pm 7.5$  mm, and  $102.4 \pm 7.8$  mm, respectively, which were not significantly different. The distances between the right and left sigmoid at T0, T1, T2, and T3 were  $99.3 \pm 6.7$  mm,  $96.7 \pm 6.6$  mm,  $96.8 \pm 6.3$  mm, and  $97.8 \pm 6.3$  mm, respectively, which were not significantly different; it decreased at T1 compared with T0 and then increased over time. The distances between the right and left coronoid at T0, T1, T2, and T3 were  $98.7 \pm 6.3$  mm,  $93.4 \pm 8.5$  mm,  $93.3 \pm 7.1$  mm, and  $94.7 \pm 6.8$  mm, respectively, which were not significantly different; it decreased at T1 compared with T0 and then increased over time.

## DISCUSSION

This study was undertaken to evaluate the intersegmental changes after BSSO in Class III malocclusion patients. The condylion, sigmoid, and coronoid point displacements in the proximal segment were assessed by CBCT images during the long-term follow-up periods.

3D CBCT volume superimposition, compared with the 2D cephalometric alternative, has certain advantages including reduced operator error and increased subvoxel accuracy. Previous studies have reported



**Figure 2.** Reference axes established on the original point (right mental foramen): A midsagittal line (z coordinate: vertical axis), a parallel line to the floor (y coordinate: anteroposterior axis), and a parallel line to a line connecting both mental foramina (x coordinate: mesiodistal axis).

superimposition at different time points and all post-surgical models were registered using the cranial base of the presurgery volume as the reference.<sup>14–16</sup> Using the cranial base as a stable anatomical reference may be a good superimposition method for evaluating surgical changes of the proximal segment since it is assumed to remain unchanged after surgery. However, it cannot predict the morphological changes of the mandible after BSSO. When occlusal interferences are seen preoperatively, removal of occlusal interferences by postoperative orthodontic treatment can lead to counterclockwise rotation of the mandible.<sup>17</sup> It could appear as proximal segment movement including the condyle of the mandible when using a cranial base superimposition method; however, there is no morphological change in the mandible. To overcome this limitation, the lower parts of the distal segment of the mandible were used as a reference for superimposition in the current study.

Asymmetric morphology of the temporomandibular joint, disharmony of mandibular movements, and a high incidence of temporomandibular joint disorders have been reported in patients with mandibular deviation in addition to asymmetric facial morphology.<sup>18–20</sup> With an asymmetric setback BSSO in a patient with mandibular deviation, little is known regarding the changes of the condyles or disk position after surgery. Kawakami et al. reported that there was no significant change in the disk position after differential setback of the mandible.<sup>21</sup> On the other hand, Kim et al. found that the deviated side of the condyle tended to move back to its presurgical position and the nondeviated side moved toward the midline. They commented that such movement was consistent with the direction in which the postsurgical asymmetric relapse occurred.<sup>22</sup> Therefore, in the present study, changes in the proximal segment after surgery were examined using subjects having skeletal class III malocclusion without any severe mandibular deviation.

Kim et al. reported that the condylar rotation in the axial view showed inward rotation of the proximal segment after orthognathic surgery.<sup>23</sup> Park et al. also reported that the axial condylar angle to midsagittal reference plane was significantly decreased after

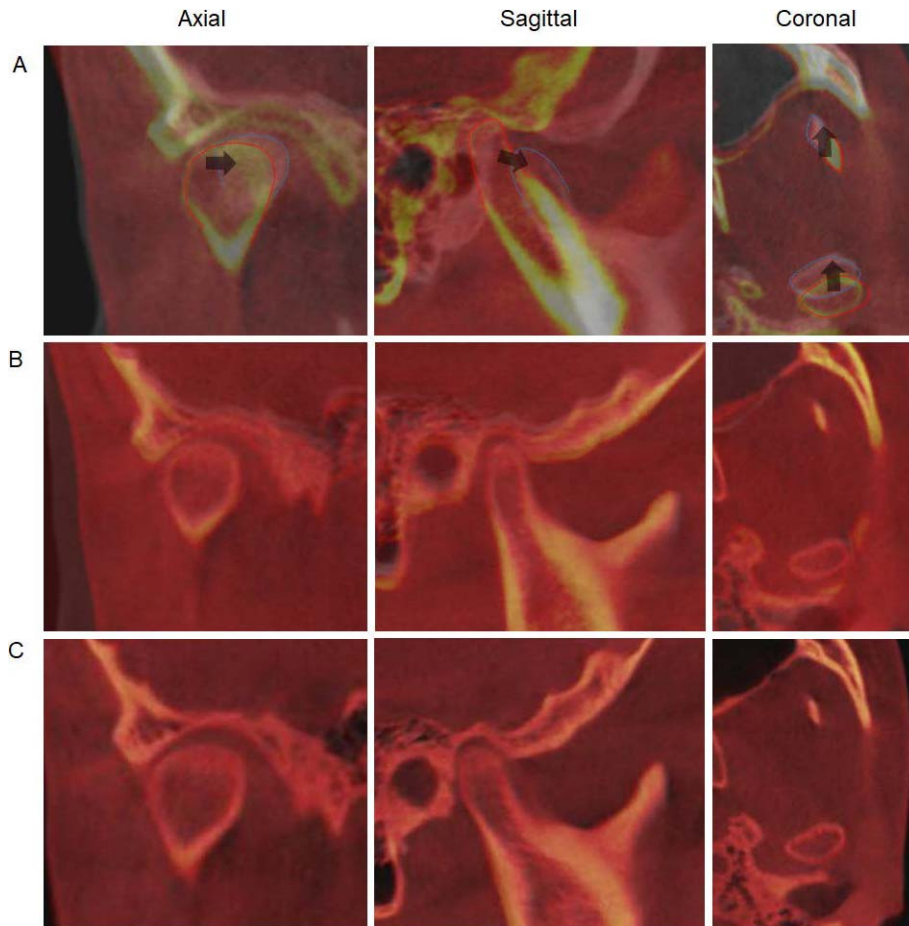
**Table 2.** 3D Cephalometric Changes in Position of Condylion, Sigmoid, and Coronoid Between Timepoints: T0–T1, T1–T2, and T2–T3\*

		Difference Among Each Stage (Mean ± SD)								
		T0–T1			T1–T2			T2–T3		
Condylion	Δx	0.5	±	2.8	–0.7	±	2.4	–0.0	±	2.6
	Δy	4.8	±	4.7	0.5	±	3.8	–1.2	±	3.9
	Δz	–9.2	±	5.7	1.6	±	4.0	–1.3	±	6.4
Sigmoid	Δx	–1.3	±	2.1	0.1	±	2.1	0.5	±	1.7
	Δy	4.0	±	3.9	–0.3	±	2.5	–0.5	±	3.0
	Δz	–9.2	±	4.3	1.7	±	3.4	0.9	±	2.9
Coronoid	Δx	–2.8	±	2.9	0.1	±	2.5	0.7	±	1.9
	Δy	4.0	±	3.4	–0.4	±	1.9	–0.7	±	2.3
	Δz	–8.2	±	6.8	0.6	±	6.5	0.2	±	3.3

\* ANOVA was performed. Significant ranges at the 0.05 Level for Duncan’s multiple comparison test. \*\*\**P* < .001, \*\**P* < .01, \**P* < .05.

setback BSSO.<sup>16</sup> The current study results were consistent with these findings. The changes in the distance between the right and left coronoid were greater than that between the right and left condylion. This implied that the proximal segment rotated inward after surgery. However, the distances between the right and left coronoid were slightly increased during the long-term follow-up period.

According to previous studies, condyles moved anteriorly during surgery and then continuously moved posteriorly to their original position in patients who underwent setback BSSO.<sup>22,24</sup> In the present study, most of the patients underwent posterior impaction Le Fort I osteotomy and setback BSSO. Therefore, condylion, sigmoid, and the coronoid moved anteriorly and inferiorly due to surgery and remained stable



**Figure 3.** (A) The change between T0 and T1 in the axial, sagittal and coronal planes. The red line is T0. The blue line is T1. The black arrow is direction T0 to T1. (B) The change between T1 and T2 in the axial, sagittal, and coronal planes. (C) The change between T2 and T3 in the axial, sagittal, and coronal planes.



during the short and long-term follow-up. These findings might signify that the mandible itself may have stable morphology during the follow-up period. Further, postoperative changes may occur not at the intersegmental osteotomy site but at the condylar portion or at the dentoalveolar portion. The condylar changes after BSSO might reflect condylar distortion in the glenoid fossa or mechanical loading, such as postoperative tension in the muscles, periosteum, or ligaments.<sup>9,16</sup> The movement of the mandibular position might be determined by the balance of the force between condylar movement to its original position and the established occlusion.

The condyle position moved anteriorly, mesially, and inferiorly between the preoperative and postoperative periods. But the condyle position did not change from 6 months to 6 years by mandibular stable structures as a reference for superimposition. This meant that intersegmental bone remodeling did not change from 6 months of postoperative follow-up. This result indicated that the condyle change reported by previous studies was not due to intersegmental change.

Most previous studies on condylar changes after mandibular setback surgery have used a follow-up period of  $\leq 1$  year.<sup>6-10</sup> The current study was conducted on patients who had long-term follow-up data. Long-term follow-up studies are necessary to ascertain whether the postoperative condylar displacement is permanent. Most of the points having proximal segments in this study did not show any significant alteration during the long-term follow-up after surgery and stayed relatively in the same position in relation to the distal segments.

Oral and maxillofacial surgeons and orthodontists are interested in relapse after orthognathic surgery. In particular, they want to identify factors influencing relapse after surgery and prevent it from occurring. Changes within 6 months after surgery are caused by movement at the osteotomy site (osteotomy slippage) or temporomandibular joint sag.<sup>25</sup> The aim of this study was to investigate the postoperative changes due to intersegmental changes during long-term follow-up. On the superimpositions based on stable structures, the symphysis and mandible lower margins on the distal segment, the results of postoperative change were not changed between 6 months and 6 years. In other words, these results suggested that there was stability in the healing and bone remodeling process after fixation between the proximal and distal segments.

This study on long-term follow-up had limitations including a small sample size, and all patients were stable patients who did not raise the issue of relapse. In subsequent studies, it may be necessary to look for other effects of relapse in a comparative study with patients with relapse in the long term. In further studies,

it may be necessary to compare relapse with non-relapse patients to identify other factors of relapse in the long term.

## CONCLUSIONS

- There was no significant intersegmental displacement after orthognathic surgery in the long-term follow-up period. These results suggest that the mandible itself has a stable form during the follow-up period.

## ACKNOWLEDGMENTS

This study was supported by a two-year research grant from Pusan National University.

## REFERENCES

1. de Villa GH, Huang CS, Chen PK, Chen YR. Bilateral sagittal split osteotomy for correction of mandibular prognathism: long-term results. *J Oral Maxillofac Surg.* 2005;63:1584–1592.
2. Ghang MH, Kim HM, You JY, et al. Three-dimensional mandibular change after sagittal split ramus osteotomy with a semirigid sliding plate system for fixation of a mandibular setback surgery. *Oral Surg Oral Med Oral Pathol Oral Radiol.* 2013;115:157–166.
3. Politi M, Costa F, Cian R, Polini F, Robiony M. Stability of skeletal class III malocclusion after combined maxillary and mandibular procedures: rigid internal fixation versus wire osteosynthesis of the mandible. *J Oral Maxillofac Surg.* 2004;62:169–181.
4. Franco JE, van Sickels JE, Thrash WJ. Factors contributing to relapse in rigidly fixed mandibular setbacks. *J Oral Maxillofac Surg.* 1989;47:451–456.
5. Borstlap WA, Stoelinga PJ, Hoppenreijts TJ, van't Hof MA. Stabilisation of sagittal split set-back osteotomies with miniplates: a prospective, multicentre study with 2-year follow-up. *Int J Oral Maxillofac Surg.* 2005;34:487–494.
6. Halvorsen ET, Beddari IY, Schilbred Eriksen E, et al. Relapse and stability after mandibular setback surgery one year postoperatively: a retrospective study. *J Oral Maxillofac Surg.* 2014;72:1181.e1–11.
7. Xi T, de Koning M, Bergé S, Hoppenreijts T, Maal T. The role of mandibular proximal segment rotations on skeletal relapse and condylar remodelling following bilateral sagittal split advancement osteotomies. *J Craniomaxillofac Surg.* 2015; 43:1716–1722.
8. Xi T, Schreurs R, van Loon B, et al. 3D analysis of condylar remodelling and skeletal relapse following bilateral sagittal split advancement osteotomies. *J Craniomaxillofac Surg.* 2015;43:462–468.
9. Chen S, Lei J, Wang X, Fu KY, Farzad P, Yi B. Short- and long-term changes of condylar position after bilateral sagittal split ramus osteotomy for mandibular advancement in combination with Le Fort I osteotomy evaluated by cone-beam computed tomography. *J Oral Maxillofac Surg.* 2013; 71:1956–1966.
10. Kim YI, Park SB, Jung YH, Hwang DS, Lee JY. Evaluation of intersegmental displacement according to osteosynthesis method for mandibular setback sagittal split ramus osteot-

- omy using cone-beam computed tomographic superimposition. *J Oral Maxillofac Surg.* 2012;70:2893–2898.
11. Wisth PJ. What happen to them? Postoperative survey of patients 10 years after surgical correction of mandibular prognathisms. *Am J Orthod.* 1981;80:525–535.
  12. Eriksen ES, Wisth P, Løes S, Moen K. Skeletal and dental stability after intraoral vertical ramus osteotomy: a long-term follow-up. *Int J Oral Maxillofac Surg.* 2017;46:72–79.
  13. Nguyen T, Cevidanes L, Franchi L, Ruellas A, Jackson T. Three-dimensional mandibular regional superimposition in growing patients. *Am J Orthod Dentofacial Orthop.* 2018;153:747–754.
  14. Méndez-Manjón I, Guijarro-Martínez R, Valls-Ontañón A, Hernández-Alfaro F. Early changes in condylar position after mandibular advancement: a three-dimensional analysis. *Int J Oral Maxillofac Surg.* 2016;45:787–792.
  15. Koerich L, Ruellas A, Paniagua B, Styner M, Turvey T, Cevidanes LH. Three-dimensional regional displacement after surgical–orthodontic correction of Class III malocclusion. *Orthod Craniofac Res.* 2016;19:65–73.
  16. Park SB, Yang YM, Kim YI, Cho BH, Jung YH, Hwang DS. Effect of bimaxillary surgery on adaptive condylar head remodeling: metric analysis and image interpretation using cone-beam computed tomography volume superimposition. *J Oral Maxillofac Surg.* 2012;70:1951–1959.
  17. Lee NK, Kim YK, Yun PY, Kim JW. Evaluation of post-surgical relapse after mandibular setback surgery with minimal orthodontic preparation. *J Craniomaxillofac Surg.* 2013;41:47–51.
  18. Akahane Y, Deguchi T, Hunt NP. Morphology of the temporomandibular joint in skeletal class iii symmetrical and asymmetrical cases: a study by cephalometric laminography. *J Orthod.* 2001;28:119–128.
  19. Mimura H, Deguchi T. Relationship between sagittal condylar path and the degree of mandibular asymmetry in unilateral cross-bite patients. *J Craniomandib Pract.* 1994;12:161–166.
  20. Inui M, Fushima K, Sato S. Facial asymmetry in temporomandibular joint disorders. *J Oral Rehabil.* 1999;26:402–406.
  21. Kawakami M, Yamamoto K, Inoue T, Kajihara A, Fujimoto M, Kirita T. Disk position and temporomandibular joint structure associated with mandibular setback in mandibular asymmetry patients. *Angle Orthod.* 2009;79:521–527.
  22. Kim YJ, Lee Y, Chun YS, Kang N, Kim SJ, Kim M. Condylar positional changes up to 12 months after bimaxillary surgery for skeletal Class III malocclusions. *J Oral Maxillofac Surg.* 2014;72:145–156.
  23. Kim YJ, Oh KM, Hong JS, et al. Do patients treated with bimaxillary surgery have more stable condylar positions than those who have undergone single-jaw surgery? *J Oral Maxillofac Surg.* 2012;70:2143–2152.
  24. Kim YI, Jung YH, Cho BH, Kim SS, Son WS, Park SB. The assessment of the short- and long-term changes in the condylar position following sagittal split ramus osteotomy (SSRO) with rigid fixation. *J Oral Rehabil.* 2010;37:262–270.
  25. Hoffmannová J, Foltán R, Vlk M, Klíma K, Pavlíková G, Bulík O. Factors affecting the stability of bilateral sagittal split osteotomy of a mandible. *Prague Med Rep.* 2008;109:286–297.