

Effect of piezocision corticotomy on en-masse retraction: A randomized controlled trial

Abdulkarim A. Hatrom^a; Khalid H. Zawawi^b; Reem M. Al-Ali^c; Hanadi M. Sabban^d; Talal M. Zahid^e;
Ghassan A. Al-Turki^f; Ali H. Hassan^g

ABSTRACT

Objectives: To compare the amount of en-masse retraction with or without piezocision corticotomy, to assess the type of tooth movement, to evaluate root integrity after retraction, and to record reported pain levels.

Materials and Methods: This randomized, controlled clinical trial included 26 orthodontic patients requiring premolar extraction. The patients were divided into two groups: (1) an extraction with piezocision corticotomy group (PCG) and (2) an extraction-only group, which served as the control group (CG). Cone-beam computed tomography images were acquired before and 4 months after the initiation of en-masse retraction utilizing miniscrews. The following variables were assessed: the amount of en-masse retraction, incisor inclination, incisor and canine root resorption, and patient-reported pain.

Results: Twelve and 11 participants completed the entire study in the PCG and CG, respectively. The amount of en-masse retraction was significantly greater in the PCG compared to the CG (mean = 4.8 ± 0.57 mm vs 2.4 ± 0.33 mm, respectively [$P < .001$]). There was also significantly less tipping and root resorption of incisors in the PCG ($P < .05$). The reported pain was significantly higher on the first day in the PCG compared to the CG ($P < .001$); however, it became similar between the groups after 24 hours.

Conclusions: Piezocision corticotomy enhanced the amount of en-masse retraction two times more with less root resorption. However, future studies are required to assess the long-term effects of this technique. (*Angle Orthod.* 2020;90:648–654.)

KEY WORDS: Piezocision; En-masse retraction; Corticotomy; Root resorption

^a Orthodontist, Ministry of Health, Makkah, Saudi Arabia.

^b Professor, Department of Orthodontics, Faculty of Dentistry, King Abdulaziz University, Jeddah, Saudi Arabia.

^c Assistant Consultant, Department of Periodontology, King Khaled National Guard Hospital, Jeddah, Saudi Arabia.

^d Assistant Professor, Department of Oral Diagnostic Sciences, Faculty of Dentistry, King Abdulaziz University, Jeddah, Saudi Arabia.

^e Associate Professor, Department of Periodontology, Faculty of Dentistry, King Abdulaziz University, Jeddah, Saudi Arabia.

^f Assistant Professor, Department of Orthodontics, Faculty of Dentistry, King Abdulaziz University, Jeddah, Saudi Arabia.

^g Professor, Department of Orthodontics, Faculty of Dentistry, King Abdulaziz University; and Dean, Alfarabi Colleges, Jeddah, Saudi Arabia.

Corresponding author: Dr Ali H. Hassan, Professor, Department of Orthodontics, Faculty of Dentistry, King Abdulaziz University; Dean, Alfarabi Private College, PO Box 80209, Jeddah 21589, Saudi Arabia (e-mail: aakbr@kau.edu.sa)

Accepted: January 2020. Submitted: September 2019.

Published Online: March 26, 2020

© 2020 by The EH Angle Education and Research Foundation, Inc.

INTRODUCTION

Most orthodontic patients are interested in safe treatment with reduced duration to achieve their desired esthetic goals.^{1,2} In cases presenting with crowding and/or bimaxillary protrusion, extraction of premolars is the main orthodontic treatment option; with this option spaces are either closed by en-masse retraction or two-step space closure.³ In these cases, treatment time could extend up to 2 years, and even longer in some cases.^{4,5} Recently, several techniques have been introduced to accelerate orthodontic tooth movement while maintaining the quality and safety of orthodontic treatment.⁶ One technique is corticotomy-assisted orthodontic treatment, which was reported^{7,8} to accelerate tooth movement, especially in adult patients. However, this technique is a relatively invasive procedure.⁸

Dibart et al.⁹ proposed a relative minimally invasive procedure called “piezocision,” in which a piezoelectric knife is used to decorticate the alveolar bone after

gaining access through interdental vertical gingival incisions. Recent piezocision studies have yielded contradictory results. Abbas et al.¹⁰ evaluated and compared the efficiency of corticotomy-assisted orthodontics and piezocision during canine retraction using sliding mechanics. They showed that piezocision was an efficient treatment modality with which to accelerate canine retraction. However, Tunçer et al.¹¹ assessed en-masse retraction and space closure using sliding mechanics and found that there was no difference compared to the control group. The differences between these two studies could be attributed to the different models used and the tools used to assess the results.^{10,11}

The objectives of the present study were to (1) assess the effect of piezocision on en-masse retraction, (2) assess the type of movement achieved (bodily or tipping), (3) evaluate root integrity after retraction, and (4) compare the reported pain levels.

MATERIALS AND METHODS

This single-centered, parallel-group, randomized, controlled clinical trial was conducted with an allocation ratio of 1:1 and was approved by the Research Ethics Committee of the Faculty of Dentistry at King Abdulaziz University. It was registered under the Clinicaltrials.gov Clinical Trial Registry (NCT03180151). The study was performed in accordance with the ethical standards of the Declaration of Helsinki.

Patients seeking orthodontic treatment at the outpatient clinic of the Department of Orthodontics of the Faculty of Dentistry at King Abdulaziz University were screened for conformity with the following inclusion criteria: (1) age between 16 and 26 years; (2) Class II division 1 malocclusion with mild or no crowding, requiring extraction of premolars and retraction of anterior teeth; (3) good oral hygiene and healthy gingiva; (4) probing depth values not above 3 mm in the whole dentition; (5) presence of all permanent teeth, excluding the third molars; (6) no history of orthodontic treatment; (7) no history of systemic diseases; and (8) no current intake of medication that could affect bone biology. All patients were given a detailed description of the procedures, and informed consent was obtained from those willing to participate in the study. Next, the patients were randomly assigned into the piezocision corticotomy group (PCG) and the control group (CG) using the opaque sealed-envelope technique. There were no changes to the methods after commencement of the trial.

Sample Size Calculation

A total of 23 participants completed the study in its entirety, with 12 in the PCG and 11 in the CG. Sample

size calculation was based on the post hoc power analysis using G Power,¹² with effect size $d = 2.03$, power $(1 - \beta)$ set at 0.95, and $\alpha = .05$ (two-tailed). The primary outcomes were the amount of tooth retraction and change of angulation. The analysis showed that power reached 0.916 when sample sizes were PCG = 12 and CG = 11 for group differences to reach statistical significance at the .05 level. This analysis showed that the sample size did not compromise the statistical power and was sufficient on effect size observed on the basis of the mean between-group comparison.

Randomization

Patients were randomly assigned to either the PCG or CG using the opaque sealed-envelope technique. Envelopes containing treatment allocation cards were prepared, and the deck of cards was shuffled thoroughly. After shuffling, patients were asked to pick one of the opaque sealed envelopes from a container to allocate the treatment approach. The containers included 13 envelopes with the word "PCG," indicating the piezocision corticotomy treatment group, and 13 envelopes with the word "CG," indicating the control group. Cone-beam computed tomography (CBCT) assessment was blinded.

After obtaining pretreatment records, the miniscrews (3M Unitek, Monrovia, Calif) were inserted, each with a diameter of 1.8 mm and a length of 8 mm, and CBCT (I-CAT Cone Beam 3D Imaging, Imaging Sciences International Hatfield, Pa) images were taken. Placement of miniscrews was performed by one expert investigator. Miniscrews were inserted between the maxillary second premolar and first molar under infiltration local anesthesia. All patients received a modified bidimensional multibracket system: 0.018-inch slots in the incisors and canines and 0.022-inch slots in the premolars and molars (3M Unitek).

After leveling and alignment, patients in the PCG were referred for extraction of both maxillary first premolars and piezocision, and those in the CG were referred for extraction of both maxillary first premolars. Labial piezocision corticotomy without any grafting was performed in the PCG (Figure 1) using the protocol described by Dibart et al.⁹ Briefly, after leveling and alignment, the surgery was performed under local anesthesia (Septanest with adrenaline 1:200,000, Septodont, Saint-Maur-des-Fossés, France). Vertical interproximal microincisions were made below the interdental papilla on the buccal aspect of each jaw using a No. 15 blade (Bard Parker No. 15 scalpel blades, Aspen Surgical, Caledonia, MI). A Piezo surgical knife was used to create the cortical alveolar incision to a depth of approximately 3 mm. The

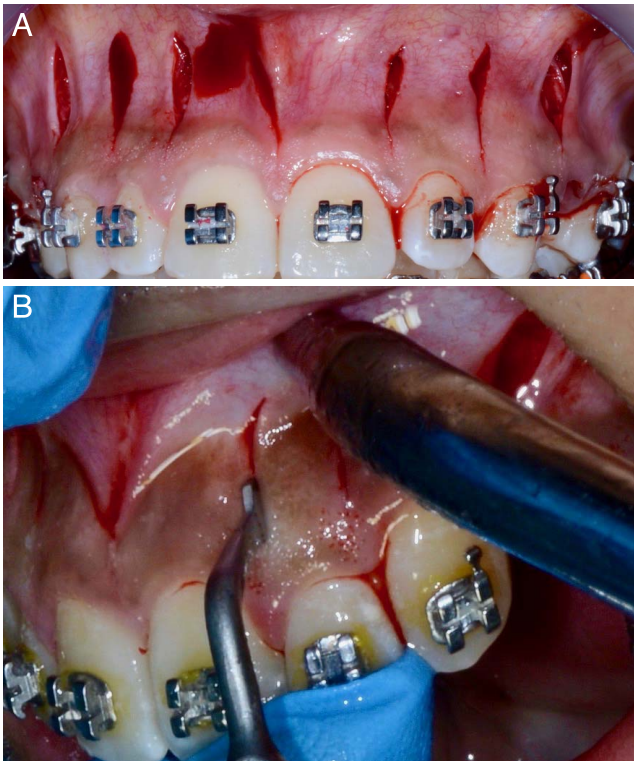


Figure 1. (A, B) Piezocision performed on the buccal side.

extraction was performed simultaneously with piezocision, and additional extraction socket corticotomy was performed in all socket walls. A piezotome was used to remove the bone from the extraction socket distal to the canine root and palatal side of the socket. Suturing was not performed. The piezocision procedure and extractions were performed by one expert investigator for all patients. All patients were advised to take paracetamol (500 mg orally) after the procedure every 6 hours for 2 days.

One week later, en-masse retraction was initiated in both groups on a 0.018 × 0.025-inch stainless-steel arch wire using nickel-titanium closed coil springs (250 g of force, bilaterally) extended between the mini-

screws and power arms crimped mesial to the canines bilaterally (Figure 2). A strain caliper (Dentaurum, Ispringen, Germany) was used to measure and confirm the force used, and en-masse retraction was continued for a period of 4 months after progress records, including photographs, CBCT images, and orthodontic models, were obtained. The treatment was continued for patients in both groups until the treatment objectives were achieved. Final records were then obtained, and the appropriate retention was provided.

Pretreatment (T1) and progress (T2) CBCT images were compared by a single blinded operator to evaluate the amount of space closure, as well as incisor inclination and position, using the Carestream Dental Imaging Software (v. 6.14.7, Carestream Dental LLC, New York, NY). To reduce measurement errors, the CBCT images for 10 subjects were randomly selected to be remeasured by the same investigator 1 month after the first measurement. Intraexaminer reliability of the measurements was assessed using the intraclass correlation coefficient.

To measure the amount of space closure, a coordinate system was constructed on the palatal plane and a perpendicular line passing through the apex of the miniscrews on each side. The perpendicular distance between the vertical line and the cemento-enamel junction of each central incisor was measured (Figure 3). To assess the inclination of incisors, the angle between the long axis line of each central incisor and the palatal plane was measured and compared between pretreatment and progress CBCT scans. The root length was assessed by measuring the length of the long axis of all teeth from canine to canine, and they were compared between the two groups. The amount of extraction space closure was measured on digital models that were constructed using the Maestro Scanner 3D DentalMDS300 (AGE Solutions, Pisa, Italy).

A numerical rating scale for pain level was used at 1, 2, 6, 24, and 48 hours after the respective procedures. The outcomes were independently assessed by two

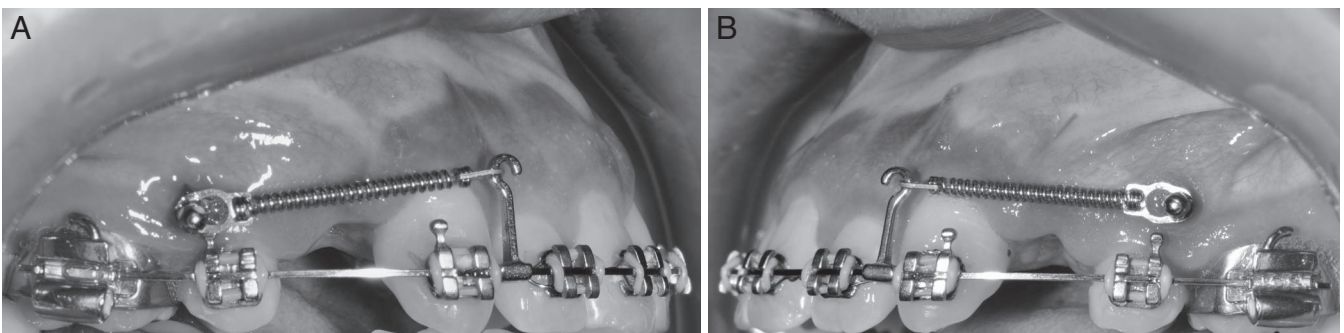


Figure 2. (A, B) Nickel-titanium closed-coil springs (250 g of force) extended between the miniscrews and power arms were used to perform the en-masse retraction.




Figure 3. Cone-beam computed tomography sagittal section showing the assessment of anterior retraction by using a line perpendicular to the palatal plane passing through the apex of the miniscrews. A line drawn at 90° from this line to the cemento-enamel junction was used to measure the amount of retraction.

authors specialized in orthodontics. There were no changes to outcomes after trial commencement.

Statistical Analysis

Means and standard deviations of the differences between the amount of retraction, space closure, degree of inclination, and the length of roots before and after treatment were measured and compared using independent sample *t*-tests. All data were calculated and analyzed using IBM SPSS Statistical Software (IBM Corp. Released 2011. IBM SPSS

Statistics for Macintosh, Version 20.0. Armonk, NY: IBM Corp.) at a significance level of $\alpha = .05$ by a statistician who was blinded to the results.

RESULTS

Intraclass correlation coefficients showed that intra-examiner agreement was reliable (mean, 96.9%; range, 74.9–99.9%) for all measurements. When testing the normality of the main dependent variables, the Shapiro-Wilks test ($P > .05$) showed that they were approximately normally distributed in both groups.

Participant Flow

A total of 26 participants were included in this study, including 13 in the PCG (seven males, six females) and 13 in the CG (six males, seven females) (Figure 4). The enrollment started in September 2016 and ended in January 2018. Out of the 26 patients recruited, 1 patient in the PCG and 2 patients in the CG were excluded after enrollment as a result of miniscrew failure. The mean age of the participants allocated to the PCG and CG at the beginning of the trial was 19.8 ± 3.1 and 20.4 ± 4.1 years, respectively.

Baseline Data

The initial measurements (T1) are shown in Table 1. There were no significant differences between the two groups for any initial measurements, supporting the

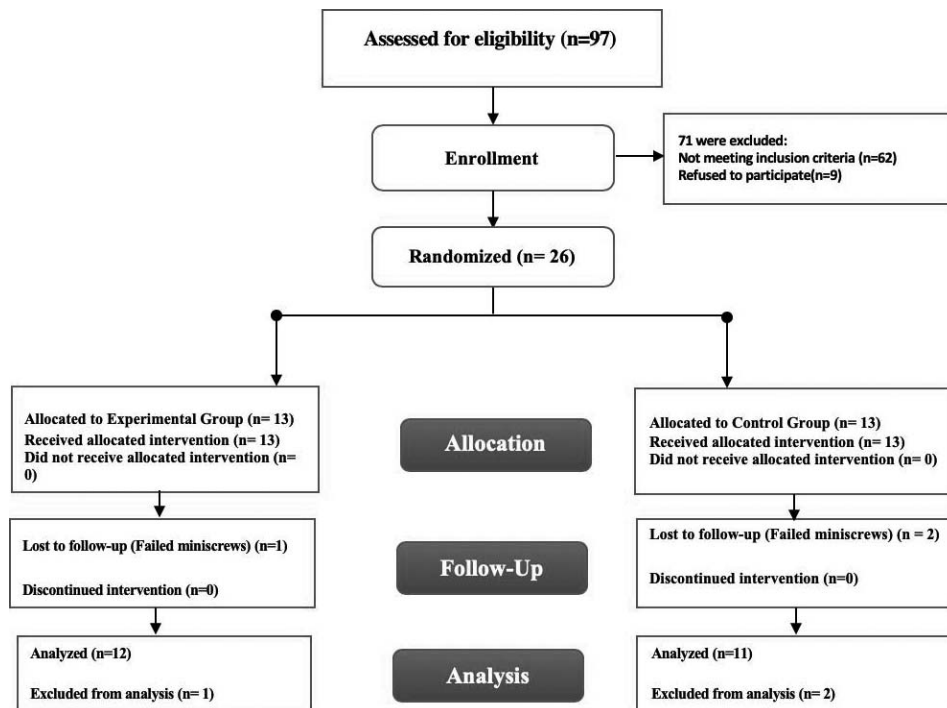


Figure 4. CONSORT flow chart.

Table 1. Descriptive Summary of Both Groups upon Initial Measurement (T1)^a

Variable	Piezocision Group (PCG), Mean ± SD (n = 12)	Control Group (CG), Mean ± SD (n = 11)	P-Value
Age, y	19.8 ± 3.1	20.4 ± 4.1	.72
Gender, n (%)	Male = 6 (50) Female = 6 (50)	Male = 5 (45.5) Female = 6 (54.5)	.99
AP			
Right central incisor AP, mm	27.1 ± 2.5	26.7 ± 1.7	.65
Left central incisor AP, mm	27.1 ± 2.5	26.6 ± 1.7	.61
Inclination			
Right incisor inclination, °	114.7 ± 1.4	115.2 ± 1.4	.39
Left incisor inclination, °	114.7 ± 1.4	115 ± 1.4	.39
Root length			
Right central, mm	25.0 ± 1.0	25.1 ± 1.4	.96
Right lateral, mm	22.9 ± 0.8	23.4 ± 1.5	.33
Right canine, mm	27.3 ± 1.3	27.7 ± 2.2	.59
Left central, mm	25.2 ± 1.0	25.2 ± 1.3	.96
Left lateral, mm	22.9 ± 0.8	23.5 ± 1.7	.27
Left canine, mm	27.1 ± 1.1	27.5 ± 1.8	.60
Space closure			
Extraction space right side, mm	7.6 ± 0.3	7.5 ± 0.2	.85
Extraction space left side, mm	7.6 ± 0.4	7.5 ± 0.2	.80

^a Significance at $P < .05$. Central incisor AP = sagittal distance between the vertical line passing through tip of miniscrews and the cements/enamel junction of central incisor.

fact that both groups were similar at the beginning of the study.

When comparing pretreatment and progress records, there was significantly more retraction and less tipping in the PCG than in the CG ($P < .001$; Figures 5 and 6). The amount of en-masse retraction was significantly greater in the PCG (mean = 4.8 ± 0.57 mm) than in the CG (mean = 2.4 ± 0.33 mm; $P < .001$). There was also more extraction space closure in the PCG than in the CG, as measured on the digital casts ($P < .001$; Figure 7). The rate of space closure per month was 1.2 mm in the PCG and 0.6 mm in the CG. There was a statistically significant difference between the two groups in root length changes of the right and left central incisors and the right canine, which showed significantly less root resorption in the PCG than in the CG. No significant difference was

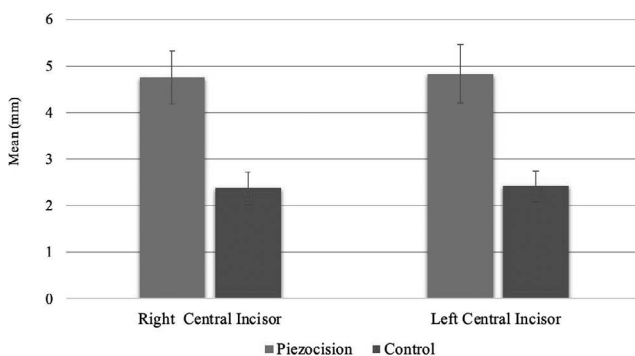


Figure 5. Comparisons of mean change in the amount of incisor retraction (mm) in the piezocision corticotomy group (PCG) and control group (CG) (Δ T1-T2).

observed between the groups in root length changes of other teeth (Table 2). The reported pain level was higher in the PCG than in the CG during the first 24 hours; however, the pain levels were almost equal for both groups (Figure 8).

DISCUSSION

En-masse retraction involved the retraction of anterior teeth on 0.018×0.022 -inch stainless-steel wire fitted in a modified bidimensional fixed orthodontic appliance with 0.022-inch slot posterior brackets and tubes and 0.018-inch slot anterior teeth brackets, including canines. This technique was advocated by some authors^{13,14} to ensure easier retraction with less friction and, simultaneously, reduced tipping of incisors. In addition, a highly reliable method of measurement was chosen to evaluate the outcomes: CBCT and

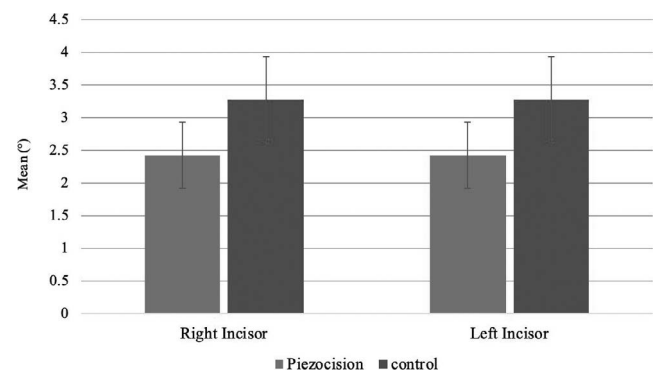


Figure 6. Comparisons of mean change in incisor inclination in the piezocision corticotomy and control groups (Δ T1-T2).

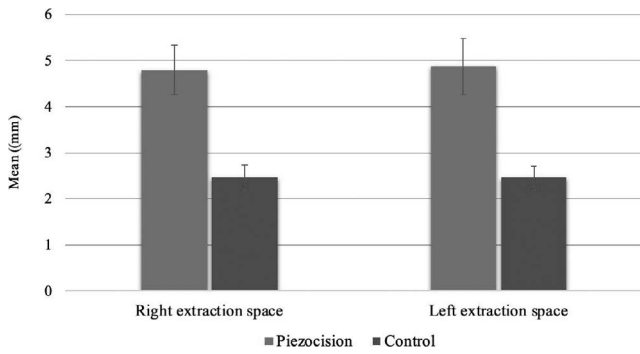


Figure 7. Comparisons of the amount of extraction space closure on the digital model between the piezocision corticotomy and control groups (Δ T1-T2).

digital models. A 4-month period after piezocision was observed, since it was reported¹⁵ to be the optimal time for the maximum effect of the regional acceleratory phenomenon in terms of tooth movement acceleration.

While conventional en-masse retraction is expected to close spaces in a shorter time, tipping of incisors and anchorage loss are expected, which requires additional time during finishing and restricts its use to cases in which anchorage is not critical.^{3,16} Additionally, friction is critical with both types of retraction.^{17,18} The protocol used in the present study overcame these limitations and complications by performing en-masse retraction using a modified bidimensional orthodontic bracket system to ensure less friction posteriorly and maximum torque control anteriorly.¹⁹

The findings agreed with those of two previous studies^{20,21} that showed enhanced en-masse tooth movement after performance of corticotomy and that reported that tooth movement velocity with corticotomy was almost two times faster than with conventional en-masse retraction. However, the current findings were in disagreement with the findings of Tunçer et al.,¹¹ which showed no effect of piezocision on tooth movement during en-masse retraction using bidimensional orthodontic brackets. This disagreement could be attributed to several factors. Unlike the study of Tunçer et al., in which extraction was performed 4 months before

Table 2. Comparisons of the Mean Difference (\pm Standard Deviation [SD]) in Root Lengths (mm) Between Piezocision Group (PCG) and Control Group (CG) (Δ T1-T2)^a

Variable	PCG n = 12	CG n = 11	P-Value
Right central	0.58 \pm 0.27	0.90 \pm 0.40	.03
Right lateral	0.44 \pm 0.30	0.82 \pm 0.60	.07
Right canine	0.58 \pm 0.27	1.00 \pm 0.53	.03
Left central	0.60 \pm 0.26	1.03 \pm 0.63	.04
Left lateral	0.63 \pm 0.25	0.83 \pm 0.34	.13
Left canine	0.64 \pm 0.26	0.81 \pm 0.30	.16

^a T1 indicates time of initial measurement; T2 indicates measurements taken at progress. Significance at $P < .05$.

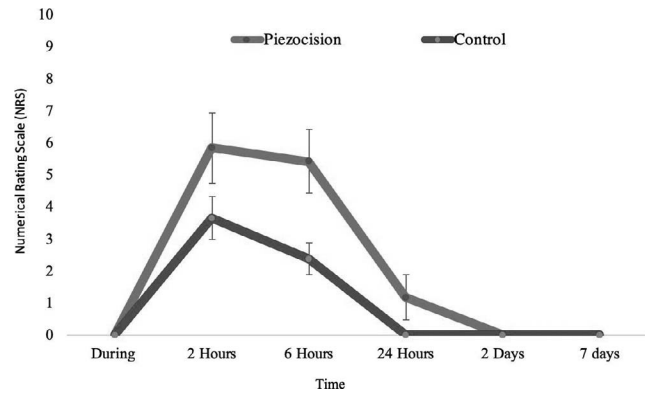


Figure 8. Comparisons of patient-reported pain in both groups.

commencing piezocision and en-masse retraction, extraction was performed simultaneously with piezocision in the current study, and additional extraction socket corticotomy was performed in all socket walls. The piezotome was used to remove the bone from the extraction socket distal to the canine root and on the palatal side of the socket. This was reported²² to be important in order to decrease resistance to tooth movement in a distal direction. In addition, the arch wire used in the Tunçer et al. study during sliding comprised 0.016 \times 0.022-inch stainless steel, which could have allowed more tipping of the teeth during retraction, which also required more time to resolve.

The inclination of the incisors relative to the palatal plane after retraction was within the normal range in the PCG (mean = 112°, \pm standard deviation [SD]) and CG (mean = 111°, \pm SD). This could be attributed to the use of the modified bidimensional orthodontic bracket system with a 0.018 \times 0.022-inch stainless-steel arch wire for maximum torque control anteriorly. This finding was in agreement with that of Li et al.²³

The present study showed that the piezocision corticotomy protocol had less chance of inducing root resorption. Although there was more root resorption in the CG, it was still within the normal range of root resorption after conventional orthodontic treatment, which was in agreement with the study by Charavet et al.²⁴ This was in contrast to Patterson et al.,²⁵ who found a significantly greater amount of root resorption with piezocision. A possible explanation could be that a buccal tipping force was applied in that study against the buccal cortical plate of bone, which was more sclerotic and compact than the cancellous and spongy bone found inside the extraction space in the current study.

Davoody et al.²⁶ reported significant molar tipping to the distal when miniscrews were utilized in en-masse retraction of incisors. However, in the current study, the amount of space closure was not the only parameter measured; the amount of incisor retraction in relation to

the palatal plane was also assessed to further augment the information collected.

Lastly, even though the pain experienced was higher in the PCG than in the CG, pain levels were reported to be moderate. The levels of pain experienced were similar to those previously reported by Charavet et al.²⁴ and Uribe et al.²

Limitations

This study was designed to assess only the short-term effects of piezocision corticotomy. Therefore, future studies are required to assess the long-term effects of this technique.

CONCLUSIONS

- Within the limitations of this randomized clinical trial, it appears reasonable to conclude that en-masse retraction combined with piezocision corticotomy is an effective treatment technique for accelerating tooth movement.
- PCG showed a reduced amount of incisor tipping and root resorption.
- The postoperative pain experienced by patients was moderate.

REFERENCES

1. Pachêco-Pereira C, Pereira JR, Dick BD, Perez A, Flores-Mir C. Factors associated with patient and parent satisfaction after orthodontic treatment: a systematic review. *Am J Orthod Dentofacial Orthop.* 2015;148:652–659.
2. Uribe F, Padala S, Allareddy V, Nanda R. Patients', parents', and orthodontists' perceptions of the need for and costs of additional procedures to reduce treatment time. *Am J Orthod Dentofacial Orthop.* 2014;145(suppl 4):S65–S73.
3. Felemban NH, Al-Sulaimani FF, Murshid ZA, Hassan AH. En masse retraction versus two-step retraction of anterior teeth in extraction treatment of bimaxillary protrusion. *J Orthod Sci.* 2013;2:28–37.
4. Buschang PH, Campbell PM, Ruso S. Accelerating tooth movement with corticotomies: is it possible and desirable? *Semin Orthod* 2012;18:286–294.
5. Pilon JJ, Kuijpers-Jagtman AM, Maltha JC. Magnitude of orthodontic forces and rate of bodily tooth movement. An experimental study. *Am J Orthod Dentofacial Orthop.* 1996;110:16–23.
6. Hassan AH, Al-Fraidi AA, Al-Saeed SH. Corticotomy-assisted orthodontic treatment: review. *Open Dent J.* 2010;4:159–164.
7. Ren A, Lv T, Kang N, Zhao B, Chen Y, Bai D. Rapid orthodontic tooth movement aided by alveolar surgery in beagles. *Am J Orthod Dentofacial Orthop.* 2007;131:160.e1–160.e10.
8. Wilcko WM, Wilcko T, Bouquot JE, Ferguson DJ. Rapid orthodontics with alveolar reshaping: two case reports of decrowding. *Int J Periodont Restor Dent.* 2001;21:9–19.
9. Dibart S, Sebaoun JD, Surmenian J. Piezocision: a minimally invasive, periodontally accelerated orthodontic tooth movement procedure. *Compend Contin Educ Dent.* 2009;30:342–344, 346, 348–350.
10. Abbas NH, Sabet NE, Hassan IT. Evaluation of corticotomy-facilitated orthodontics and piezocision in rapid canine retraction. *Am J Orthod Dentofacial Orthop.* 2016;149:473–480.
11. Tunçer Nİ, Arman-Özçırpıcı A, Oduncuoğlu BF, Göçmen JS, Kantarcı A. Efficiency of piezosurgery technique in mini-screw supported en-masse retraction: a single-centre, randomized controlled trial. *Eur J Orthod.* 2017;39:586–594.
12. Erdfelder E, Faul F, Buchner A. GPOWER: a general power analysis program. *Behav Res Method, Instruments Comput.* 1996;28:1–11.
13. Rinchuse DJ, Rinchuse DJ. Modification of the bidimensional system. *Orthod Art Pract Dentofacial Enhancement.* 2011;12:10–21.
14. Giancotti A, Mozzicato P, Greco M. En masse retraction of the anterior teeth using a modified bidimensional technique. *J Clin Orthod.* 2012;46:267.
15. Frost HM. The regional acceleratory phenomenon: a review. *Henry Ford Hosp Med J.* 1983;31:3–9.
16. Schneider PP, Kim KB, da Costa Monini A, Dos Santos-Pinto A, Gandini LGJ. Which one closes extraction spaces faster: en masse retraction or two-step retraction? A randomized prospective clinical trial. *Angle Orthod.* 2019;89:855–861.
17. Burrow SJ. Friction and resistance to sliding in orthodontics: a critical review. *Am J Orthod Dentofacial Orthop.* 2009;135:442–447.
18. Prashant PS, Nandan H, Gopalakrishnan M. Friction in orthodontics. *J Pharm Bioallied Sci.* 2015;7(suppl 2):S334–S338.
19. Gianelly AA, Bednar JR, Dietz VS. A bidimensional edgewise technique. *J Clin Orthod.* 1985;19:418–421.
20. Bhattacharya P, Bhattacharya H, Anjum A, et al. Assessment of corticotomy facilitated tooth movement and changes in alveolar bone thickness-A CT scan study. *J Clin Diagn Res.* 2014;8:ZC26.
21. Sakthi SV, Vikraman B, Shobana VR, Iyer SK, Krishna-swamy NR. Corticotomy-assisted retraction: an outcome assessment. *Indian J Dent Res.* 2014;25:748–754.
22. Liou EJ, Huang CS. Rapid canine retraction through distraction of the periodontal ligament. *Am J Orthod Dentofacial Orthop.* 1998;114:372–382.
23. Li Y, Tang N, Xu Z, Feng X, Yang L, Zhao Z. Bidimensional techniques for stronger anterior torque control in extraction cases: a combined clinical and typodont study. *Angle Orthod.* 2012;82:715–722.
24. Charavet C, Lecloux G, Bruwier A, et al. Localized piezoelectric alveolar decortication for orthodontic treatment in adults: a randomized controlled trial. *J Dent Res.* 2016;95:1003–1009.
25. Patterson BM, Dalci O, Papadopoulou AK, et al. Effect of piezocision on root resorption associated with orthodontic force: a microcomputed tomography study. *Am J Orthod Dentofacial Orthop.* 2017;151:53–62.
26. Davoody AR, Posada L, Utreja A, et al. A prospective comparative study between differential moments and mini-screws in anchorage control. *Eur J Orthod.* 2012;35:568–576.