

Effects of adhesive flash-free brackets on debonding pain and time: A randomized split-mouth clinical trial

Serpil Çokakoğlu^a; Ayten Tan^b

ABSTRACT

Objectives: To evaluate the effects of adhesive precoated (APC) flash-free brackets on the level of pain, amount of remnant adhesive, and removal time during the debonding procedure.

Materials and Methods: Thirty patients (20 female, 10 male) aged 12 to 18 years undergoing nonextraction fixed orthodontic treatment were included in this study. APC flash-free and conventional ceramic brackets were bonded with a split-mouth study design. Bracket types were randomly allocated to quadrants. During the removal of the brackets, the visual analogue scale (VAS) was used to assess the level of pain for each tooth. The adhesive remnant index (ARI) was used to determine the amount of adhesive remaining on the tooth surface. Adhesive removal times were calculated per quadrant. The data were analyzed using the Wilcoxon test for comparisons between groups.

Results: Pain scores were generally higher for the conventional group than for the flash-free group. There were no differences in VAS scores across most tooth types during debonding. Overall, ARI results showed more adhesive remnants in the conventional bracket group ($P < .001$). Except for the right maxillary quadrant, the times required to remove the adhesive were significantly longer for the flash-free brackets than the conventional brackets ($P \leq .005$).

Conclusions: Although removal time was slightly longer for the flash-free adhesive than for the conventional adhesive, lower pain scores were generally observed for the flash-free adhesive brackets during the debonding procedure. Both time and pain differences could be considered clinically insignificant. (*Angle Orthod.* 2020;90:758–765.)

KEY WORDS: Debonding; Flash-free; Pain

INTRODUCTION

Fixed orthodontic treatment is considered effectively performed by a clinician when the patient remains comfortable from the beginning to the end of treatment. In practice, the use of flash-free brackets not only reduces the application time but also provides sufficient retention during treatment.¹ In addition, the smooth interface between the bracket and enamel with flash-free adhesive can protect the enamel against

demineralization.^{2–4} A recent clinical study concluded that flash-free brackets shortened the debonding time by allowing the adhesive remnant material on the enamel surface to be cleaned more easily at the end of the treatment.⁵ However, a limited number of studies on this topic have been carried out.^{5–7}

Another issue of concern to orthodontic patients is the amount of pain experienced during the debonding procedure. Many previous studies evaluated pain during debonding, but they were frequently focused on a specific technique or method.^{8–14} All studies were performed on metallic brackets regardless of whether they were conventional or adhesive precoated (APC) brackets. Additionally, an assessment of the published literature demonstrated that there was limited information about the level of discomfort patients experienced during ceramic bracket removal using a specially designed debonding instrument.¹⁵

No previous studies evaluated the level of pain experienced during the debonding phase for APC flash-free brackets. Only a few studies evaluated the

^a Assistant Professor, Department of Orthodontics, Faculty of Dentistry, Pamukkale University, Denizli, Turkey.

^b Orthodontic Specialist, Oral and Dental Health Hospital, Sakarya, Turkey.

Corresponding author: Dr Serpil Çokakoğlu, Assistant Professor, Department of Orthodontics, Faculty of Dentistry, Pamukkale University, 20160 Denizli, Turkey (e-mail: serpilcokakoglu@gmail.com)

Accepted: June 2020. Submitted: March 2020.

Published Online: September 03, 2020

© 2020 by The EH Angle Education and Research Foundation, Inc.

process of adhesive removal with flash-free brackets.^{5,6} Grünheid and Larson⁵ reported a shorter debonding duration for flash-free brackets due to the lower material density of flash-free adhesive, despite there being more remnant adhesive on the tooth surface. However, the debonding time was evaluated on maxillary teeth. In addition, the effects of flash-free brackets on the level of pain, amount of remnant adhesive, and removal time for the full mouth have not been investigated in orthodontic patients during the debonding procedure. Therefore, the purpose of this study was to evaluate all parameters related to patient discomfort, including pain, the amount of adhesive remnant, and removal time at the phase of debonding. To that end, the null hypothesis was that flash-free brackets had no effects on these parameters.

MATERIALS AND METHODS

Trial Design and Ethical Approval

This split-mouth randomized clinical study was approved by the Ethics Committee of Pamukkale University (25.12.2018/24). Informed consent was obtained from all participants.

Participants, Eligibility, and Setting

The study population was composed of 30 patients (20 female, 10 male) between 12 and 18 years old who were included based on the following criteria: (1) no systemic problems requiring medication; (2) Class I or Class II malocclusion with mild-to-moderate crowding with indications for nonextraction fixed orthodontic treatment; (3) permanent dentition with no missing teeth; (4) no history of previous orthodontic treatment; and (5) all brackets were bonded in place prior to starting the debonding procedure. Patients with endodontic treatment, large restorations, and buccal restorations were excluded from the study.

Interventions

APC flash-free and conventional ceramic brackets (Clarity Advanced, 3M Unitek, Monrovia, Calif, USA) were bonded with a split-mouth study design by the same researcher (A.T.). During the bonding procedure, 37% phosphoric acid (Pulpdent Etch Royale, Pulpdent Corporation Watertown, Mass, USA) was used for 30 seconds during enamel etching, Transbond XT Primer (3M Unitek) was applied to the etched enamel, and Transbond XT Light Cure Adhesive (3M Unitek) was used to bond the adhesive-free ceramic brackets. The excess adhesive was removed carefully with a scaler for the conventional ceramic brackets and resin was polymerized for 20 seconds. Additionally, patients were instructed to visit the clinic immediately in case of bond

failure. In cases of failure, new brackets were bonded according to the same procedure.

Patients were advised to not take painkillers or corticosteroids within 24 hours prior to the debonding session. A bracket debonding instrument (3M-804-170, 3M Unitek) was used to debond the conventional and flash-free ceramic brackets. First, the archwires were removed, and debonding of the ceramic brackets was performed according to the manufacturers' recommendations. The ledges of the debonding instrument were positioned symmetrically against the labial surfaces of the bracket. Finally, the brackets were gently squeezed until the bracket collapsed and then rocked in the mesial or distal directions until they completely separated from the teeth.

The teeth were randomly selected during the debonding. The visual analogue scale (VAS) was used to rate the level of pain experienced, with a score of 0 indicating "no pain," and a score of 100 indicating "maximum pain." Patients were instructed to record the VAS score on the scale after each bracket was debonded. Additionally, overall and segmental mean VAS scores were calculated. The upper and lower posterior segments included the first and second premolars, while the anterior segments included the central incisor, lateral incisor, and canine teeth.

After debonding, the adhesive remnant index (ARI)¹⁶ was used to assess the adhesive remaining on the tooth surfaces. Then, the adhesive remnants were removed from the surfaces using a new tungsten carbide finishing bur in a low-speed handpiece starting from the upper right quadrant to the lower right quadrant. Adhesive removal was approved with visual inspection under a dental operating light. The time required for adhesive removal per quadrant was calculated in seconds by a digital timer.

Outcomes

Primary outcome measure. The primary outcome measure was the level of pain between the bracket groups during debonding, taking into account the tooth type and region.

Secondary outcome measures. The secondary outcome measures were the amount of remnant adhesive and required removal time after debonding.

Sample Size

Power analysis (SPSS version 24.0, IBM Corp, Armonk, NY, USA) showed that, for a power of 0.80, an effect size of 0.50, and a significance level of $\alpha = 0.05$, 27 patients were required for each group. To account for any missing data, the study sample size was adjusted to 30.

Randomization

Simple quadrant randomization was performed by coin flipping to determine the assignment of study groups.

Blinding

At the end of orthodontic treatment, the pain scores, amount of remnant adhesive, and time required for the removal of the adhesive were recorded by the same researcher (S.C.), who was blinded to the bonding procedure.

Statistical Analysis

The data were statistically analyzed using SPSS version 23.0. The Mann-Whitney U test was used to compare the median age values according to the sex of the patient. The parameters were analyzed using the Wilcoxon nonparametric test. All tests were performed with a significance level of $P < .05$.

RESULTS

Participant Flow

At baseline, thirty patients were included in this trial. Later, two patients were excluded due to lack of cooperation (Figure 1).

Baseline Characteristics

Descriptive statistics are given in Table 1. There was no statistically significant age difference between sexes. For the study population, the duration of treatment ranged from 10–20 months, with a mean duration of 13.96 months.

Pain Measurements

The pain scores were generally higher in the conventional group than in the flash-free group (Table 2). During the removal of flash-free brackets, the highest scores in the upper jaw were found for the left canine and central and lateral incisor teeth. In the same group, the highest scores were recorded for the mandibular right central and lateral incisors. For conventional brackets, the same tooth types showed the highest VAS pain scores on the opposite side of the upper jaw. Additionally, the lower left first premolar and lateral incisor had two of the highest scores.

There were no significant differences in the VAS scores across most tooth types. Removal of the upper left flash-free canine bracket caused significantly more pain than the removal of the conventional bracket ($P = .014$). In contrast, the lower left lateral incisor ($P = .044$) and first premolar ($P = .006$), and lower posterior region

($P = .017$) showed significantly higher VAS scores for conventional brackets than flash-free brackets.

In both groups, the pain scores were higher for the maxillary and mandibular anterior regions than for the posterior region. Regardless of the tooth type, there were statistically significantly higher VAS pain scores in the conventional group overall ($P = .004$).

Remnant Adhesive and Debonding Time Measurements

More adhesive remnants were observed in the conventional bracket group than in the flash-free group (Table 3). The upper right lateral incisor ($P = .003$), left central incisor ($P = .007$) and left premolars ($P = .025$ and $P = .008$, respectively), lower left lateral incisor ($P = .008$), canine ($P = .013$) and second premolar ($P = .022$), and the lower right central incisor ($P = .008$) teeth had significantly more remnant adhesive in the conventional group than in the flash-free group. In addition, the adhesive remnants of the conventional bracket group were significantly higher than those in the flash-free group in the right and left quadrants of the upper and lower jaws ($P \leq .001$).

The times required for the removal of the adhesive are shown in Table 4. Except for the right maxillary quadrant, removal time was significantly longer for the flash-free bracket group than for the conventional group ($P \leq .005$). In terms of average difference, the removal of the flash-free adhesive took significantly more time than the removal of the conventional adhesive by 9 seconds per quadrant ($P < .001$).

DISCUSSION

Pain Measurements

The findings of this study revealed that pain scores showed variability among different tooth types. These differences can be related to the debonding force, which could not be standardized during this study. No standardized method reflects actual clinical conditions. Bishara et al.¹⁷ noted that the debonding force during the removal of ceramic brackets was influenced by the bracket retention mechanism, debonding technique, composition of the adhesive, and enamel conditioning procedure.

Although the teeth were randomly selected during the removal of the brackets, reported pain was significantly greater on the left side, in the upper and lower jaws. Due to the convenience of access, the brackets in the right quadrants were debonded more easily and with acceptable removal forces. Therefore, no significant differences were found between the groups on the right side. On the other hand, it was difficult to explain the significant differences between

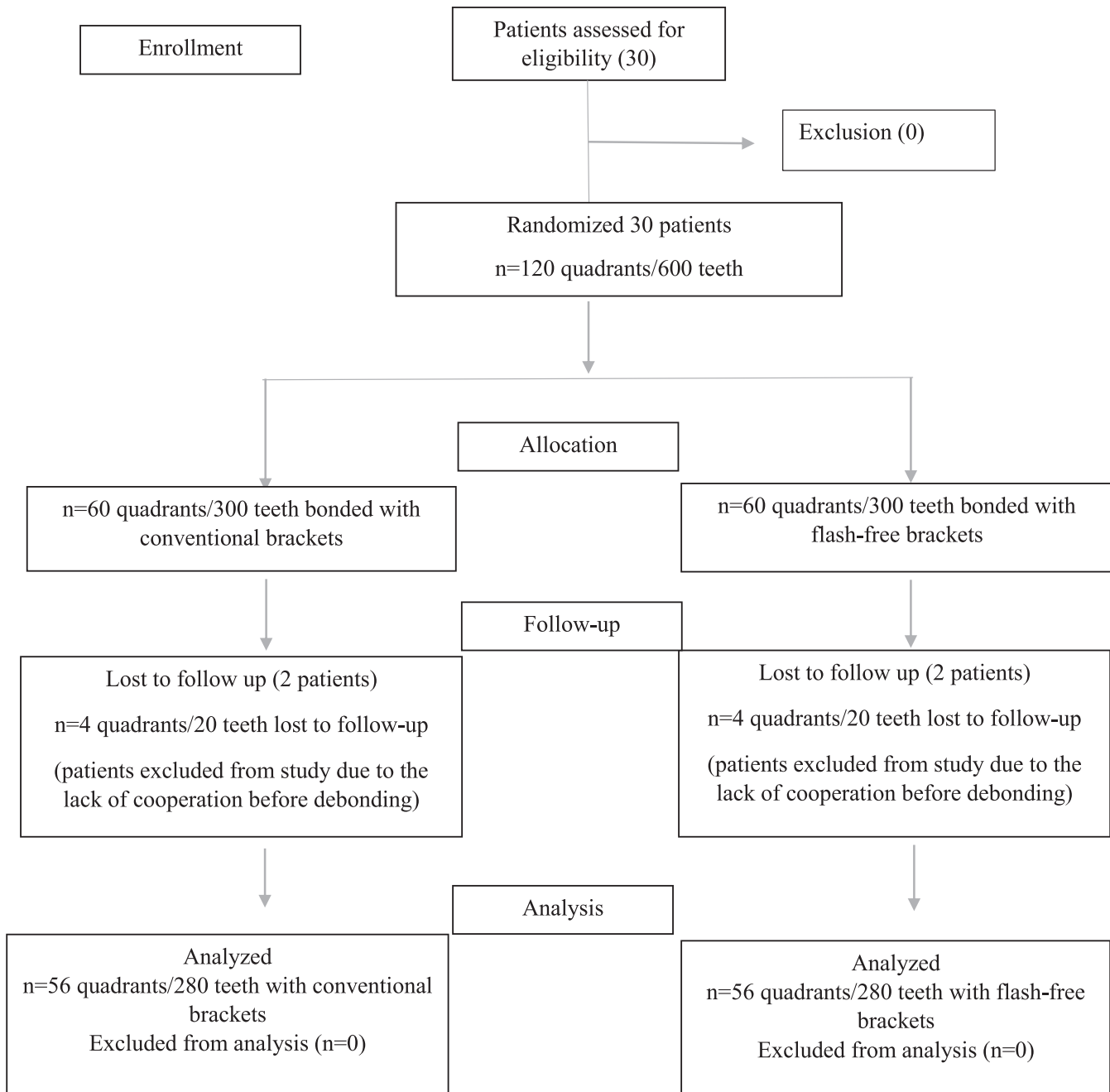


Figure 1. Consort flowchart.

Table 1. Demographic Variables of the Study Sample^{a,*}

	n, %	Age, Mean ± SD
Female/percentage	19 (68)	16.00 ± 2.16
Male/percentage	9 (32)	17.44 ± 3.78
Total	28 (100)	16.46 ± 2.80

^a SD indicates standard deviation.
^{*} No statistically significant age difference between sexes (Mann-Whitney rank-sum test, *P* = .345).

tooth types based solely on the difficulty of access. These differences could be related to non-standardized debonding force and thickness of composite material. For the upper left canine, the higher pain scores with flash-free brackets were difficult to explain. The thickness of the adhesive layer may be considered more uniform due to lower filler content with the flash-free adhesives. Accordingly, a significant difference in favor of the conventional brackets would be expected, as was present in other teeth. Consistent with the findings of Hama et al.,¹⁸ it would be expected that

Table 2. Comparison of VAS Scores Between Bracket Groups^{a,b,*}

Tooth-Region	VAS Pain Score		P
	Flash-free Brackets	Conventional Brackets	
	Mean (Range)	Mean (Range)	
UR-1	8 (1–38)	21.5 (0–79)	ns
UR-2	9.5 (0–86)	20 (1–72)	ns
UR-3	6 (0–56)	27.5 (0–67)	ns
UR-4	6 (0–73)	10.5 (0–72)	ns
UR-5	8 (0–45)	12 (0–78)	ns
UL-1	15 (0–57)	8 (2–52)	ns
UL-2	12 (0–80)	12.5 (2–74)	ns
UL-3	21.5 (4–67)	10 (2–42)	.014*
UL-4	3.5 (0–50)	6.5 (1–63)	ns
UL-5	5 (0–51)	5.5 (2–39)	ns
LL-1	16 (2–83)	17 (0–80)	ns
LL-2	5 (0–45)	20 (3–47)	.044*
LL-3	7 (0–54)	15.5 (2–100)	ns
LL-4	3 (0–60)	32.5 (2–76)	.006*
LL-5	4.5 (0–91)	9.5 (0–52)	ns
LR-1	19 (0–100)	11.5 (0–75)	ns
LR-2	13.5 (0–100)	11.5 (2–71)	ns
LR-3	13 (0–59)	16.5 (1–97)	ns
LR-4	8.5 (0–57)	7 (2–64)	ns
LR-5	6 (0–43)	4 (0–88)	ns
Upper posterior	5 (0–73)	8 (0–78)	ns
Upper anterior	12 (0–86)	12 (0–79)	ns
Lower posterior	5.5 (0–91)	9.5 (0–88)	.017*
Lower anterior	12 (0–100)	16.5 (0–100)	ns
Overall	8 (0–100)	12 (0–100)	.004*

^a U indicates upper; L, lower; R, right; L, left; NS, non-significant.

^b Number indicates tooth type 1, central; 2, lateral; 3, canine; 4, first premolar; 5, second premolar.

* $P < .05$.

decreasing the thickness of orthodontic adhesive would reduce the required removal strength and lead to less severe pain due to the light load applied to the teeth. However, it should be kept in mind that these researchers evaluated the relationship between removal force and the thickness of orthodontic adhesives in bovine teeth without using brackets.

During the debonding procedure, it was observed that fractured parts of the ceramic brackets remained on the tooth surfaces. Because blinding was used in this study, the type of brackets was not recorded. As suggested in the literature, the ceramic brackets remnants were removed with the use of a bur in a high-speed handpiece before the removal time was recorded.^{19,20}

According to the anatomic locations, the pain scores were significantly different only in the lower posterior region. Among all the teeth, the lower left premolar had the highest VAS scores, and these values resulted in significant differences between this region and other regions. Regarding the VAS scores, higher scores were recorded for the conventional brackets than for the flash-free brackets for most tooth types, which caused differences between the groups overall. Before debonding of conventional ceramic brackets, many

researchers suggested that the flash-adhesive materials around the ceramic brackets should be removed first to make removal easier.²⁰ However, the flash-adhesive materials were not removed first in this study because excess adhesive was removed during the bonding stage of the conventional brackets. This process may have led to higher levels of pain perceived for the conventional brackets.

In this study, higher VAS scores were observed in the anterior regions regardless of the tooth type. These findings were in agreement with previous studies evaluating the effects of different debonding techniques and adjunctive procedures.^{8,9,12,13} This can be explained by the gradually increasing tactile sensory threshold from the anterior to the posterior region, as stated previously.⁹

Remnant Adhesive and Removal Time

Because the filler content of the flash-free adhesive is less than that in conventional adhesive, there was a significant difference in ARI scores between groups. In agreement with previous findings,²¹ the adhesive with lesser filler content displayed lower ARI scores for the flash-free group. On the other hand, debonding occurred at the bracket-adhesive interface and led to higher ARI scores in the conventional group. There was more excess resin protecting the enamel from its detachment when removing the adhesive. None of the teeth in this investigation showed any enamel damage or had an ARI of 0.

In one of the first clinical studies, Foersch et al.³ reported that the average ARI for flash-free brackets was 2. This value was close to the current result, which was calculated as 2.3 for flash-free brackets, while the mean ARI was 2.8 for the conventional group. On the other hand, Vig et al.²⁰ demonstrated that the majority of the ARI scores were 3 for flash-free brackets and that bracket type had no significant effect on the ARIs during the clinical part of their trial. These differences could be caused by different non-standardized removal forces related to the study design and fractured parts of the ceramic brackets. Because a bur was used to remove the parts of the brackets remaining on the tooth surface, the ARI scores may also have been affected.

According to the findings, 60% of the teeth in the left maxillary and mandibular region had significantly more adhesive in the conventional group. Significant differences were recorded across the different tooth types. In the right region, the upper lateral and lower central incisor teeth had pronounced remnant adhesive after the removal of the conventional brackets. The differences may be due to the adhesive thickness being affected by the adhesive composition and buccal surface morphology of the teeth.

Table 3. Distribution of ARI Scores Among the Bracket Groups and Comparisons of Groups^{a,b,*}

Tooth/Region	Flash-free Brackets				Conventional Brackets				P
	ARI 0 n (%)	ARI 1 n (%)	ARI 2 n (%)	ARI 3 n (%)	ARI 0 n (%)	ARI 1 n (%)	ARI 2 n (%)	ARI 3 n (%)	
UR-5	0 (0)	4 (29)	6 (43)	4 (29)	0 (0)	3 (21)	5 (36)	6 (43)	ns
UR-4	0 (0)	2 (14)	5 (36)	7 (50)	0 (0)	0 (0)	2 (14)	12 (86)	ns
UR-3	0 (0)	1 (7)	10 (71)	3 (21)	0 (0)	2 (14)	2 (14)	10 (71)	ns
UR-2	0 (0)	0 (0)	10 (71)	4 (29)	0 (0)	0 (0)	1 (7)	13 (93)	.003*
UR-1	0 (0)	0 (0)	6 (43)	8 (57)	0 (0)	1 (7)	2 (14)	11 (79)	ns
UL-1	0 (0)	1 (7)	7 (50)	6 (43)	0 (0)	0 (0)	0 (0)	14 (100)	.007*
UL-2	0 (0)	0 (0)	4 (29)	10 (71)	0 (0)	0 (0)	3 (21)	11 (79)	ns
UL-3	0 (0)	1 (7)	8 (57)	5 (36)	0 (0)	1 (7)	1 (7)	12 (86)	ns
UL-4	0 (0)	1 (7)	5 (36)	8 (57)	0 (0)	1 (7)	0 (0)	13 (93)	.025*
UL-5	0 (0)	6 (43)	5 (36)	3 (21)	0 (0)	1 (7)	2 (14)	11 (79)	.008*
LL-5	0 (0)	4 (29)	6 (43)	4 (29)	0 (0)	1 (7)	1 (7)	12 (86)	.022*
LL-4	0 (0)	1 (7)	6 (43)	7 (50)	0 (0)	1 (7)	3 (21)	10 (71)	ns
LL-3	0 (0)	3 (21)	9 (64)	2 (14)	0 (0)	1 (7)	3 (21)	10 (71)	.013*
LL-2	0 (0)	4 (29)	7 (50)	3 (21)	0 (0)	0 (0)	3 (21)	11 (79)	.008*
LL-1	0 (0)	1 (7)	8 (57)	5 (36)	0 (0)	1 (7)	2 (14)	11 (79)	ns
LR-1	0 (0)	2 (14)	6 (43)	6 (43)	0 (0)	0 (0)	0 (0)	14 (100)	.008*
LR-2	0 (0)	1 (7)	5 (36)	8 (57)	0 (0)	0 (0)	1 (7)	13 (93)	ns
LR-3	0 (0)	1 (7)	7 (50)	6 (43)	0 (0)	2 (14)	1 (7)	11 (79)	ns
LR-4	0 (0)	1 (7)	8 (57)	5 (36)	0 (0)	1 (7)	1 (7)	12 (86)	ns
LR-5	0 (0)	0 (0)	8 (57)	6 (43)	0 (0)	0 (0)	4 (29)	10 (71)	ns
Upper right	0 (0)	7 (10)	37 (53)	26 (37)	0 (0)	6 (9)	12 (17)	52 (74)	.001*
Upper left	0 (0)	9 (13)	29 (41)	32 (46)	0 (0)	3 (4)	6 (9)	61 (87)	<.001*
Lower left	0 (0)	13 (19)	36 (51)	21 (30)	0 (0)	4 (6)	12 (17)	54 (77)	<.001*
Lower right	0 (0)	5 (7)	34 (49)	31 (44)	0 (0)	3 (4)	7 (10)	60 (86)	<.001*
Overall	0 (0)	34 (12)	136 (49)	110 (39)	0 (0)	16 (6)	37 (13)	227 (81)	<.001*

^a ARI 0 indicates no adhesive left on the tooth; ARI 1, less than half of the adhesive left on the tooth; ARI 2, more than half of the adhesive left on the tooth; ARI 3, all adhesive left on the tooth; U, upper; L, lower; R, right; L, left.

^b Number indicates tooth type; 1, central; 2, lateral; 3, canine; 4, first premolar; 5, second premolar; NS, non-significant.

* $P < .05$.

The findings of Hama et al.¹⁸ indicated that a decreased thickness of adhesive reduces the removal strength and, if the load applied by debonding pliers can be reduced, most of the remaining adhesive may be removed without pain. Thus, knowledge about the thickness of the adhesives used under the flash-free and conventional brackets is important.

Contrary to previous findings,^{5,6} the removal of the flash-free adhesive took longer by approximately 10 seconds per quadrant, except in the upper right quadrant, during this study. It should be noted that the adhesive removal process began in the upper right quadrant and continued around the arch to the lower

right segment. For the upper right quadrant, the debonding times were very similar between the two groups, although twice as many teeth had an ARI of 3 in the conventional bracket group than in the flash-free group. This result can be explained by the fact that this quadrant was selected as the first region and the examiner applied relatively more finger pressure at the beginning to remove the conventional adhesive. Another possible explanation for the adhesive removal times being similar in the upper right quadrant was that a new, sharp bur could remove both adhesives at a similar speed. As it dulls, it may have affected the

Table 4. Adhesive Removal Times Per Quadrant Between the Groups and Comparisons of Groups^{a,*}

Region	Debonding Time				P
	Flash-Free Brackets		Conventional Brackets		
	Mean ± SD	Median (Range)	Mean ± SD	Median (Range)	
Upper right	49.6 ± 15.6	47.5 (31–91)	50.8 ± 10	48.5 (38–77)	ns
Upper left	62.6 ± 22.1	57.5 (37–106)	52.7 ± 16	51 (29–84)	.005*
Lower left	67.1 ± 14.5	63.5 (48–95)	57 ± 17.8	49 (36–96)	.005*
Lower right	78.4 ± 17.9	78.5 (50–107)	69.3 ± 21.4	69.3 (36–120)	.004*
Overall	64.4 ± 20.5	62.5 (31–107)	57.4 ± 18.2	53.5 (29–120)	<.001*

^a SD indicates standard deviation; ns, non-significant.

* $P < .05$.

flash-free adhesive removal more than the conventional.

Conflicting results were found in terms of the removal time because the use of flash-free adhesive in the lower arch led to a longer removal process. There was an exception that the removal time for the lower left region was almost the same as that for the upper right region for the conventional brackets. In this case, some adhesive was removed from the enamel surfaces during the cleaning process of the fractured parts of the conventional brackets before the required removal time was recorded. Generally, the time to remove the adhesive was greater in the flash-free group in which less adhesive was adhered to the enamel. For the full mouth, a small removal time difference was recorded between the bracket groups. This difference can be neglected considering the other advantages of flash-free brackets in clinical practice.

Limitations and Generalizability

This study had some limitations: the lack of gender differences between groups, and right and left upper and lower jaw VAS score comparisons. Another limitation was that findings could not be discussed in detail due to the lack of previous studies regarding flash-free brackets and the level of pain perceived during debonding. Hence, it is obvious that additional studies need to be conducted to gain a better understanding of this clinical situation.

According to the results, the null hypothesis that there were no significant differences between flash-free and conventional brackets in terms of patient discomfort was rejected. The removal of flash-free brackets resulted in less pain and a lesser amount of remnant adhesive but a slightly longer removal time.

CONCLUSIONS

- The highest pain scores were observed with the conventional brackets compared to the flash-free brackets.
- There was less adhesive remnants left on the teeth with the flash-free brackets, though removal time was slightly but statistically significantly longer.
- Both the differences in pain and the removal time could be considered clinically insignificant.

REFERENCES

1. Tümoğlu M, Akkurt A. Comparison of clinical bond failure rates and bonding times between two adhesive precoated bracket systems. *Am J Orthod Dentofacial Orthop.* 2019; 155:523–528.
2. Zhu P, Nordine K, Cinader DK, 3M Unitek. APC™ flash-free adhesive: what of the excess? *Orthod Perspect Innova.* 2013;20:13–15.
3. Foersch M, Schuster C, Rahimi RK, Wehrbein H, Jacobs C. A new flash-free orthodontic adhesive system: a first clinical and stereomicroscopic study. *Angle Orthod.* 2015;86:260–264.
4. Almosa NA, Alqasir AM, Aldekhayyil MA, Aljelayel A, Aldosari MA. Enamel demineralization around two different orthodontic bracket adhesive systems: an in vivo study. *Saudi Dent J.* 2019;31:99–104.
5. Grünheid T, Larson BE. A comparative assessment of bracket survival and adhesive removal time using flash-free or conventional adhesive for orthodontic bracket bonding: a split-mouth randomized controlled clinical trial. *Angle Orthod.* 2019;89:299–305.
6. Grünheid T, Sudit GN, Larson BE. Debonding and adhesive remnant cleanup: an in vitro comparison of bond quality, adhesive remnant cleanup, and orthodontic acceptance of a flash-free product. *Eur J Orthod.* 2015;37:497–502.
7. Grünheid T, Larson BE. Comparative assessment of bonding time and 1-year bracket survival using flash-free and conventional adhesives for orthodontic bracket bonding: a split-mouth randomized controlled clinical trial. *Am J Orthod Dentofacial Orthop.* 2018;154:621–628.
8. Normando TS, Calçada FS, Ursi WJ, Normando D. Patients' report of discomfort and pain during debonding of orthodontic brackets: a comparative study of two methods. *World J Orthod.* 2010;11:29–34.
9. Mangnall LA, Dietrich T, Scholey JM. A randomized controlled trial to assess the pain associated with the debond of orthodontic fixed appliances. *J Orthod.* 2013;40: 188–196.
10. Pithon MM, Santos Fonseca Figueiredo D, Oliveira DD, Coqueiro Rda S. What is the best method for debonding metallic brackets from the patient's perspective? *Prog Orthod.* 2015;16:17.
11. Khan H, Chaudhry AR, Ahmad F, Warriach F. Comparison of debonding time and pain between three different debonding techniques for stainless steel brackets. *Pak Oral Dent J.* 2015;35:79–82.
12. Bavbek NC, Tuncer BB, Tortop T, Celik B. Efficacy of different methods to reduce pain during debonding of orthodontic brackets. *Angle Orthod.* 2016;86:917–924.
13. Priya A, Jain RK, Santhosh Kumar MP. Efficacy of different methods to reduce pain during debonding of orthodontic brackets. *Drug Invent Today.* 2018;10:1700–1703.
14. Kiliç DD, Sayar G. Evaluation of pain perception during orthodontic debonding of metallic brackets with four different techniques. *J Appl Oral Sci.* 2019;27:e20180003.
15. Kraut J, Radin S, Trowbridge HI, Emling RC, Yankell SL. Clinical evaluations on thermal versus mechanical debonding of ceramic brackets. *J Clin Dent.* 1991;2:92–96.
16. Artun J, Bergland S. Clinical trials with crystal growth conditioning as an alternative to acid-etch enamel pretreatment. *Am J Orthod.* 1984;85:333–340.
17. Bishara SE, Fehr DE, Jakobsen JR. A comparative study of the debonding strengths of different ceramic brackets, enamel conditioners, and adhesives. *Am J Orthod Dentofacial Orthop.* 1993;104:170–179.
18. Hama T, Namura Y, Nishio Y, Yoneyama T, Shimizu N. Effect of orthodontic adhesive thickness on force required by debonding pliers. *J Oral Sci.* 2014;56:185–190.
19. Johnston NJ, Price R, Day CJ, Sandy JR, Ireland AJ. Quantitative and qualitative analysis of particulate produc-

- tion during simulated clinical orthodontic debonds. *Dent Mater.* 2009;25:1155–1162.
20. Vig P, Atack NE, Sandy JR, Sherriff M, Ireland AJ. Particulate production during debonding of fixed appliances: laboratory investigation and randomized clinical trial to assess the effect of using flash-free ceramic brackets. *Am J Orthod Dentofacial Orthop.* 2019;155:767–778.
21. Faltermeier A, Rosentritt M, Faltermeier R, Reicheneder C, Müssig D. Influence of filler level on the bond strength of orthodontic adhesives. *Angle Orthod.* 2007;77:494–498.